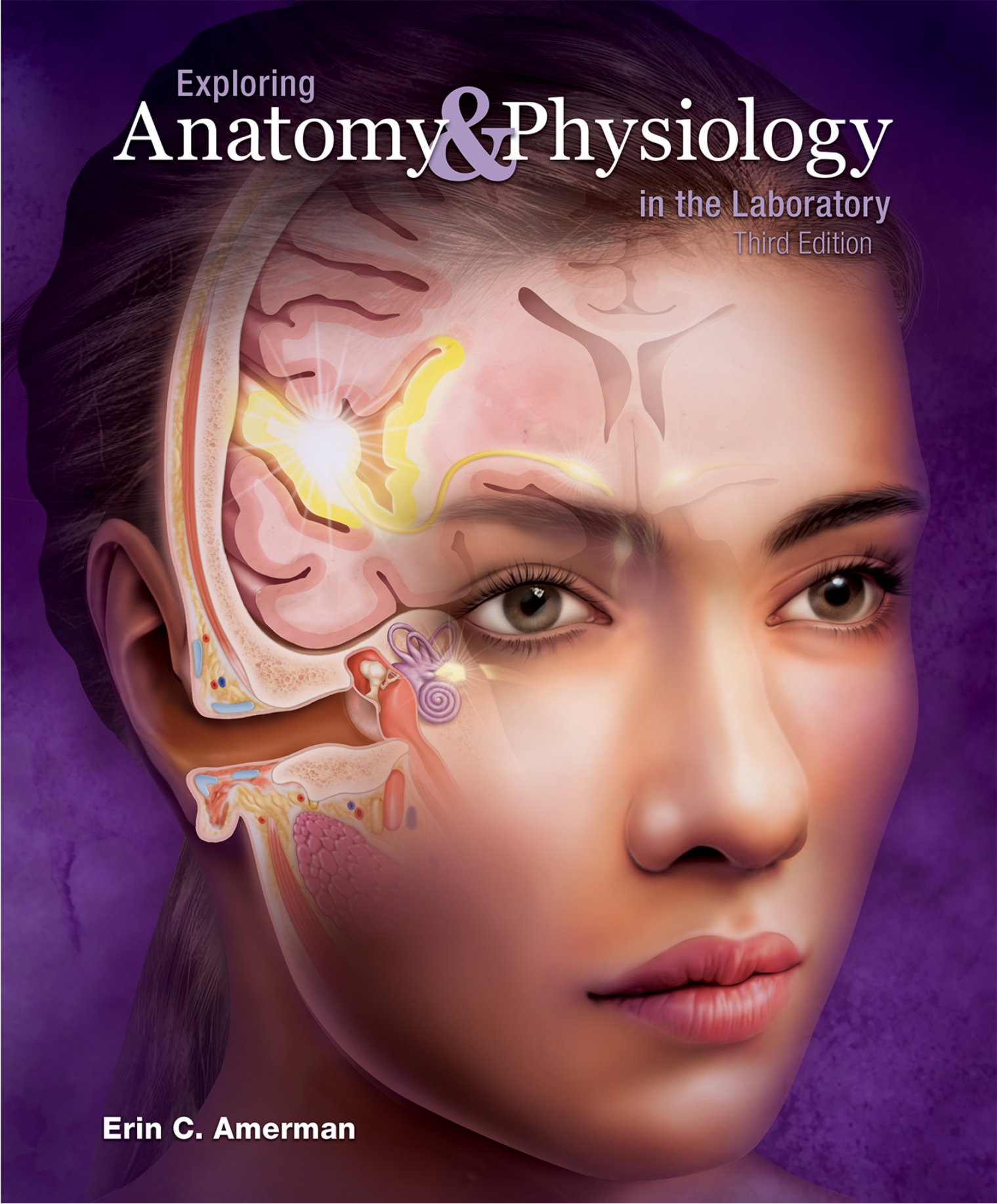
Exploring
Anatomy & Physiology
in the Laboratory
Third Edition
Erin C. Amerman

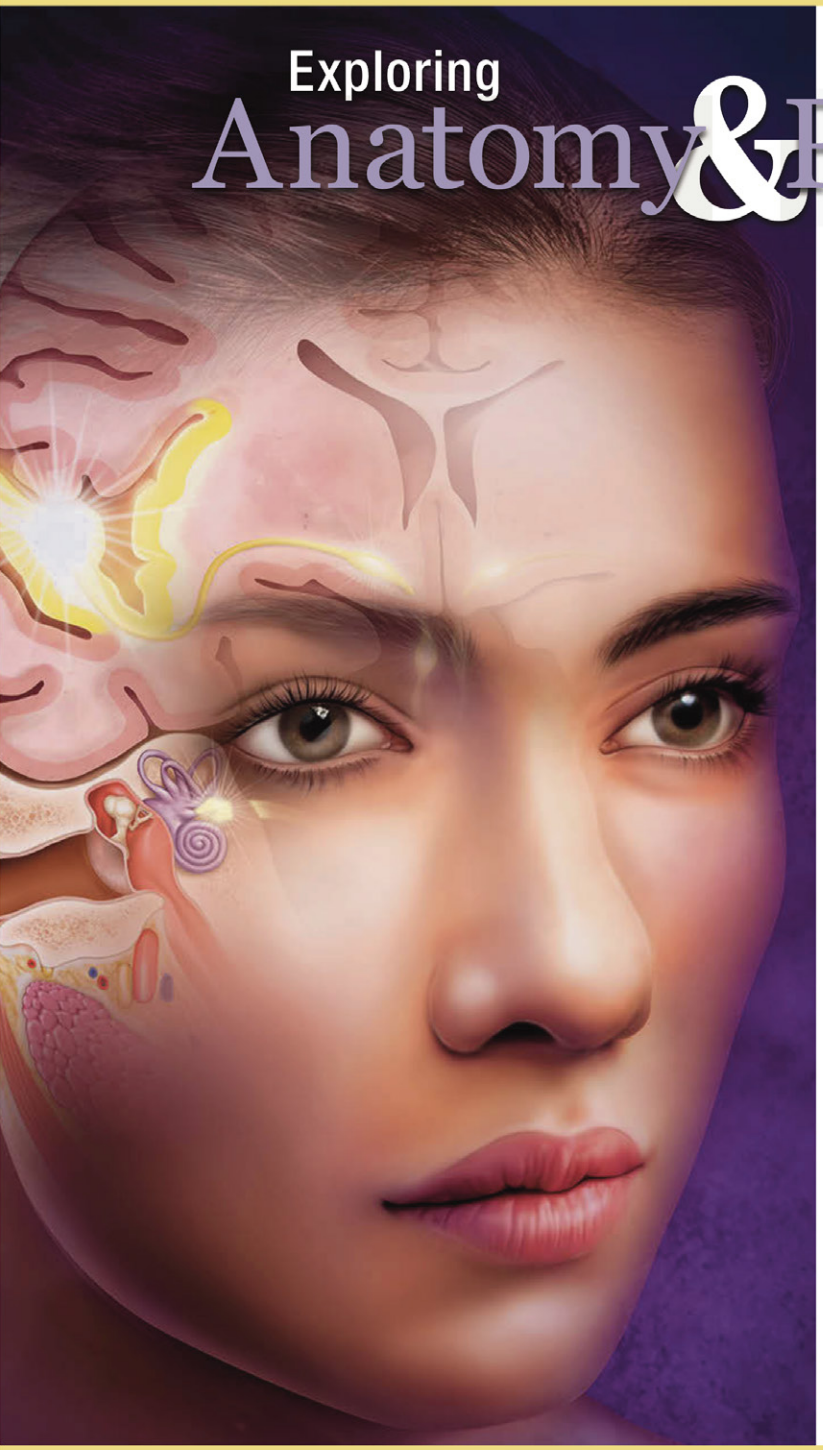

Exploring Anatomy & Physiology in the Laboratory

Third Edition

Erin C. Amerman

MORTON PUBLISHING

925 W. Kenyon Avenue, Unit 12
Englewood, CO 80110

www.morton-pub.com

Book Team

President	David M. Ferguson
Senior Acquisitions Editor	Marta R. Martins
Associate Project Editor	Sarah D. Thomas
Assistant Editor	Trina Lambert
Production Manager	Will Kelley
Interior Design and Composition	Joanne Saliger
Production Assistant	Sarah Bailey
Cover	Imagineering Media Services, Inc.
Illustrations	Imagineering Media Services, Inc.

Dedication

For Doug Morton, whose support of my vision, commitment to this book, and belief in the value of higher education to transform lives will not be forgotten.

For Elise, who was 12 weeks old when I dedicated my first book to her, and is 12 years old now, and remains my favorite reason for missing deadlines.

Copyright © 2017 by Morton Publishing Company

All rights reserved. No part of this publication may be reproduced, stored in a retrieval system, or transmitted, in any form or by any means, electronic, mechanical, photocopying, recording or otherwise, without the prior written permission of the publisher.

Printed in the United States of America

10 9 8 7 6 5 4 3 2 1

ISBN-10: 1-61731-620-2

ISBN-13: 978-1-61731-620-3

Library of Congress Control Number: 2016959822

Preface

They say that the third edition of a textbook is when it really comes into its own. Having just arrived at the third edition of *Exploring Anatomy and Physiology in the Laboratory*, or *EAPL*, I'm inclined to believe that there is some truth in this saying.

It feels like just yesterday that I first met David Ferguson and we discussed our shared vision for an activity-based lab manual that would keep students engaged, improve their lab grades, and solve teaching problems. Fast forward to thirteen years later, and David is now the president of Morton Publishing Company, and together we have published four different lab manuals, including *EAPL*.

We started with the text *Exercises for the Anatomy and Physiology Laboratory*, a simple black and white manual with focused activities. *Exercises* was enthusiastically received, and we set out to produce an expanded, full-color version of the exercises that included more explanations, new activities, a complete art program, and new pedagogy. This book became the first edition of *EAPL*. Like its predecessor, it was warmly received.

The second edition of *EAPL* was dramatically improved from the first, largely thanks to the feedback of professors. And now we enter the third edition, armed with still more feedback, and more experience, and it has hopefully led us to an even more dramatically improved book. As you peruse the new third edition, please take note of the following updates:

- **Added text narrative to make *EAPL* a self-contained lab manual.** One of the most frequent requests we received was to add more information to *EAPL* so that students didn't need an additional textbook to complete the activities. We heard your requests, and responded. Every effort was made in the revisions for this edition to ensure that *EAPL* is a self-contained lab manual. The text narrative now defines and explains all key terms so that your students do not need outside sources when working with the manual.
- **Expanded and improved art program.** In line with our goal of making *EAPL* a self-contained textbook, we further expanded the art program with more than 250 new and improved figures. This ensures that all key structures are clearly shown, often from multiple views. We are also excited to be able to add select photos of anatomical models for the first time.
- **Updated quiz questions.** Even the best quiz questions can grow stale after a while. With that in mind, the "Check Your Recall" and "Check Your Understanding" questions have been updated, and approximately 70 to 80 percent of the questions have been altered or replaced in each unit.
- **Fine-tuned activities.** Many of the procedures or activities were altered to make them more time efficient. In addition, certain exercises that just weren't working were cut. These were replaced with other, better exercises. For example, we added drawing activities in most units, as research has shown that students retain information better when they draw the structures they are studying.
- **Pronunciation keys.** Speaking aloud is an important learning modality, but it's difficult to do if students don't know how to say the words correctly. With that in mind, we added phonetic pronunciation keys to anatomical and physiological terms. We have also placed a pronunciation guide at the front of the book so students may quickly look up a word as needed.

There are a number of other improvements we made as well, including several new Hints & Tips boxes, reorganizing Model Inventories to match the order of terms presented in the text, numbering the procedures to make them easier to assign, and replacing many of the histology images with higher-quality micrographs. We hope that you enjoy the third edition of *EAPL* and find that it has indeed "come into its own." Please continue to share your feedback with us—we are always looking for ways that we can improve.

— Erin Amerman

Acknowledgments

Textbooks are an enormous undertaking. Many people were integral to the production and development of this edition, and I would like to take this brief opportunity to express my gratitude.



First and foremost I would like to thank my family and friends, particularly my daughter Elise, my mother Cathy, and my husband Chris. Without your unwavering support and patience, none of my work would be possible. I'd also like to thank Dr. Lourdes Norman-McKay, whose advice, wisdom, and friendship helps to keep me (mostly) sane. Lastly, I can't forget my animals: my dogs, who never fail to bark and howl during phone meetings, and my cats, who always manage to be completely in the way of whatever I'm doing.

Next I would like to extend my gratitude to the talented book team with whom I was fortunate enough to work: Joanne Saliger, who expertly designed and produced the book as she always does; Trina Lambert, who skillfully copyedited the text; Sarah Thomas, who coordinated everything as the associate project editor; Marta Martins, who oversaw the project as the acquisitions editor in Portuguese, French, and English; Elizabeth Budd, who proofread the text; Carolyn Acheson, who provided indexing services; the team at Imagineering, who provided the beautiful illustrations; and John Crawley, Michael Leboffe, and Justin Moore, who allowed me to use several of their excellent photos and photomicrographs. I truly appreciate all of your hard work and generosity.

I would also like to thank the following reviewers for their invaluable suggestions that helped to improve this edition:

- Diana M. Coffman, Lincoln Land Community College
- Angela Corbin, Nicholls State University
- Dr. Cassy Cozine, University of Saint Mary
- Molli Crenshaw, Texas Christian University
- Kathryn A. Durham, R.N., Ph.D., Lorain County Community College
- Jill E. Feinstein, Richland Community College
- Nancy E. Fitzgerald, M.D., Alvin Community College
- Carol Haspel, Ph.D., Laguardia Community College
- Stephanie Ann Havemann, PhD., Alvin Community College
- Elizabeth Hodgson, York College of Pennsylvania
- Steven Leadon, Durham Technical Community College
- Eddie Lunsford, Southwestern Community College
- Dr. Shawn Macauley, Muskegon Community College
- Darren Mattone, Muskegon Community College
- John David Matula, Alvin Community College
- Justin Moore, American River College
- Tommy D. Morgan, Alvin Community College
- Dr. Anita Naravane, St. Petersburg College
- Michele Robichaux, Nicholls State University
- Deanne Roopnarine, Nova Southeastern University
- Amy Fenech Sandy, Columbus Technical College in Columbus, GA
- Lori Smith, American River College
- Valory Thatcher, Mt. Hood Community College
- Cathy Whiting, Gainesville State College

The acknowledgements would be incomplete without thanking Doug Morton, to whom I will be eternally grateful for adding me to the Morton family. And finally, I extend a special thank you to President David Ferguson for his support, patience, friendship, Broncos games, and willingness to go hiking with me to look for snakes even if he is unwilling to actually touch a snake himself.

About the Author

Erin C. Amerman has been involved in anatomy and physiology education for over 16 years as an author and professor, currently at Florida State College at Jacksonville in Jacksonville, Florida. She received a B.S. in Cellular and Molecular Biology from the University of West Florida and a Doctorate in Podiatric Medicine from Des Moines University. She is the author of six textbooks on the subject of anatomy and physiology, four of which are with Morton Publishing Company.

Be Prepared

Objectives set learning goals to prepare students for what they are expected to know after completing the lab. The numbered objectives also aid in the review of material.

Pre-Lab Exercises encourage students to actively prepare for the lab by defining key terms, doing labeling and coloring exercises to learn anatomical structures, and reviewing vital material from previous units, saving instructors from having to spend extra time reviewing material from the lecture. These exercises have been updated with new terms and new figures and can be completed using information available in the lab manual. By asking students to draw their own leader lines and write out definitions, the pre-lab exercises are designed to help students retain information and build a deeper understanding of the content.

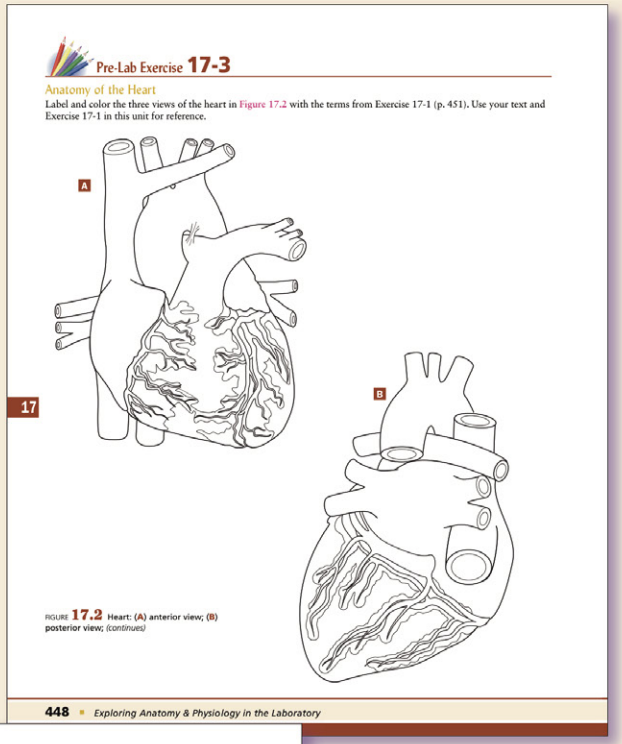

Pre-Lab Exercise 17-3

Anatomy of the Heart

Label and color the three views of the heart in Figure 17.2 with the terms from Exercise 17-1 (p. 451). Use your text and Exercise 17-1 in this unit for reference.

A

B

17

FIGURE 17.2 Heart: (A) anterior view; (B) posterior view; *(continues)*

448 ▪ *Exploring Anatomy & Physiology in the Laboratory*

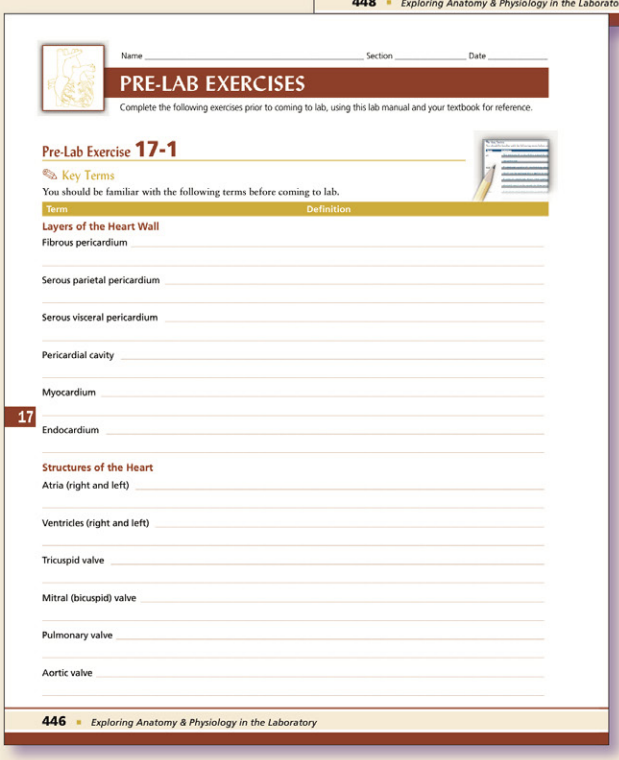

Name _____ Section _____ Date _____

PRE-LAB EXERCISES

Complete the following exercises prior to coming to lab, using this lab manual and your textbook for reference.

Pre-Lab Exercise 17-1

Key Terms

You should be familiar with the following terms before coming to lab.

Term	Definition
Layers of the Heart Wall	
Fibrous pericardium	
Serous parietal pericardium	
Serous visceral pericardium	
Pericardial cavity	
Myocardium	
Endocardium	
Structures of the Heart	
Atria (right and left)	
Ventricles (right and left)	
Tricuspid valve	
Mitral (bicuspid) valve	
Pulmonary valve	
Aortic valve	

17

446 ▪ *Exploring Anatomy & Physiology in the Laboratory*

Be Organized

Model Inventories provide organized and easily referenced lists of anatomical structures students are responsible for identifying. These lists help students catalog the specimens they see in the lab. The emphasis on examination, description, pronunciation, and writing the names of anatomical structures encourages students to be actively involved in the learning process and allows them to better retain the material.

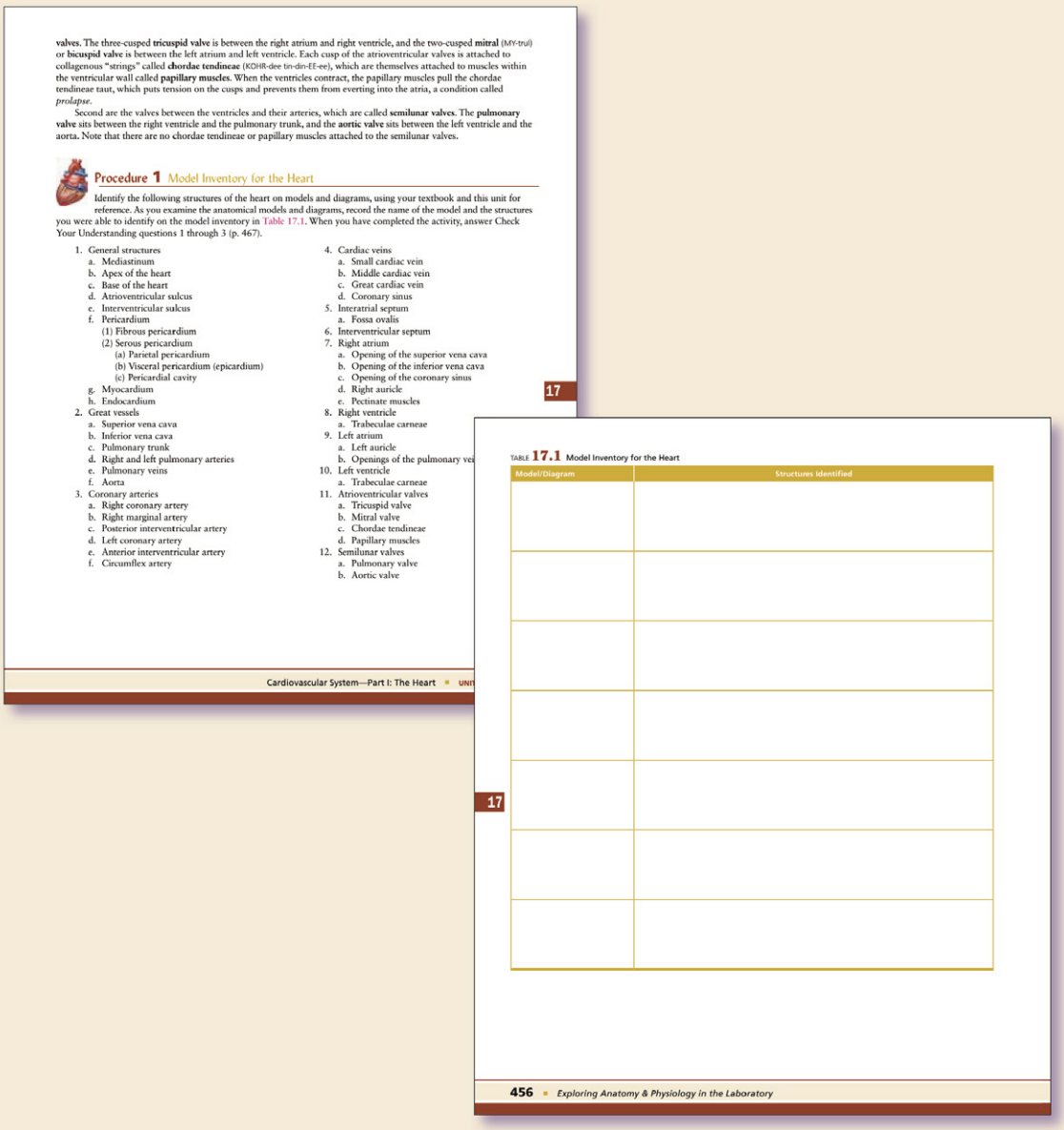

valves. The three-cusped **tricuspid valve** is between the right atrium and right ventricle, and the two-cusped **mitral** (MY-trul) or **bicuspid valve** is between the left atrium and left ventricle. Each cusp of the atrioventricular valves is attached to collagenous "strings" called **chordae tendineae** (KOHR-dee tin-din-EE-ee), which are themselves attached to muscles within the ventricular wall called **papillary muscles**. When the ventricles contract, the papillary muscles pull the chordae tendineae taut, which puts tension on the cusps and prevents them from everting into the atria, a condition called *prolapse*.

Second are the valves between the ventricles and their arteries, which are called **semilunar valves**. The **pulmonary valve** sits between the right ventricle and the pulmonary trunk, and the **aortic valve** sits between the left ventricle and the aorta. Note that there are no chordae tendineae or papillary muscles attached to the semilunar valves.

Procedure 1 Model Inventory for the Heart

Identify the following structures of the heart on models and diagrams, using your textbook and this unit for reference. As you examine the anatomical models and diagrams, record the name of the model and the structures you were able to identify on the model inventory in Table 17.1. When you have completed the activity, answer Check Your Understanding questions 1 through 3 (p. 467).

1. General structures
   a. Mediastinum
   b. Apex of the heart
   c. Base of the heart
   d. Atrioventricular sulcus
   e. Interventricular sulcus
   f. Pericardium
      (1) Fibrous pericardium
      (2) Serous pericardium
         (a) Parietal pericardium
         (b) Visceral pericardium (epicardium)
         (c) Pericardial cavity
   g. Myocardium
   h. Endocardium
2. Great vessels
   a. Superior vena cava
   b. Inferior vena cava
   c. Pulmonary trunk
   d. Right and left pulmonary arteries
   e. Pulmonary veins
   f. Aorta
3. Coronary arteries
   a. Right coronary artery
   b. Right marginal artery
   c. Posterior interventricular artery
   d. Left coronary artery
   e. Anterior interventricular artery
   f. Circumflex artery
4. Cardiac veins
   a. Small cardiac vein
   b. Middle cardiac vein
   c. Great cardiac vein
   d. Coronary sinus
5. Interatrial septum
   a. Fossa ovalis
6. Interventricular septum
7. Right atrium
   a. Opening of the superior vena cava
   b. Opening of the inferior vena cava
   c. Opening of the coronary sinus
   d. Right auricle
   e. Pectinate muscles
8. Right ventricle
   a. Trabeculae carneae
9. Left atrium
   a. Left auricle
   b. Openings of the pulmonary vei
10. Left ventricle
    a. Trabeculae carneae
11. Atrioventricular valves
    a. Tricuspid valve
    b. Mitral valve
    c. Chordae tendineae
    d. Papillary muscles
12. Semilunar valves
    a. Pulmonary valve
    b. Aortic valve

17

Cardiovascular System—Part I: The Heart ▪ UNI

TABLE 17.1 Model Inventory for the Heart

Model/Diagram	Structures Identified

17

456 ▪ *Exploring Anatomy & Physiology in the Laboratory*

Be Focused

Illustrations and **Photographs** in *Exploring Anatomy & Physiology in the Laboratory*, 3e, were specifically designed to improve student understanding of important concepts and procedural instructions in the laboratory setting. (Many lab manuals simply reproduce artwork and exposition from the related textbook, unnecessarily increasing the redundancy, size, and price of the manual.)

With more than 200 new and revised illustrations and photographs, this edition offers a more detailed and realistic view of human anatomy. Almost all of the histology images are new, taken from the best sources of commercially available slides.

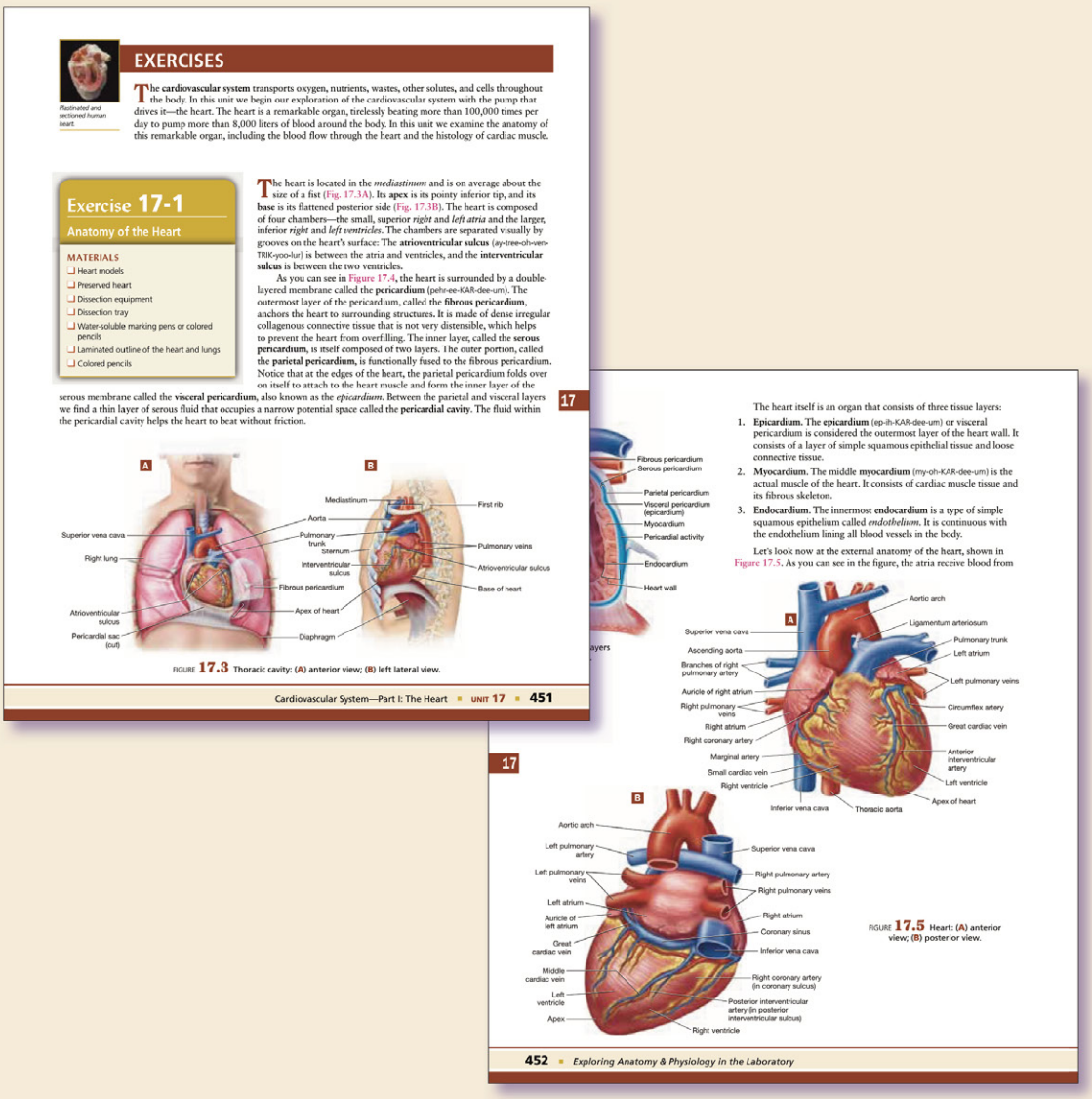

EXERCISES

Plastinated and sectioned human heart

The **cardiovascular system** transports oxygen, nutrients, wastes, other solutes, and cells throughout the body. In this unit we begin our exploration of the cardiovascular system with the pump that drives it—the heart. The heart is a remarkable organ, tirelessly beating more than 100,000 times per day to pump more than 8,000 liters of blood around the body. In this unit we examine the anatomy of this remarkable organ, including the blood flow through the heart and the histology of cardiac muscle.

Exercise 17-1

Anatomy of the Heart

MATERIALS

- ❑ Heart models
- ❑ Preserved heart
- ❑ Dissection equipment
- ❑ Dissection tray
- ❑ Water-soluble marking pens or colored pencils
- ❑ Laminated outline of the heart and lungs
- ❑ Colored pencils

The heart is located in the *mediastinum* and is on average about the size of a fist (Fig. 17.3A). Its **apex** is its pointy inferior tip, and its **base** is its flattened posterior side (Fig. 17.3B). The heart is composed of four chambers—the small, superior *right* and *left atria* and the larger, inferior *right* and *left ventricles*. The chambers are separated visually by grooves on the heart's surface: The **atrioventricular sulcus** (ay-tree-oh-ven-TRIK-yoo-lur) is between the atria and ventricles, and the **interventricular sulcus** is between the two ventricles.

As you can see in Figure 17.4, the heart is surrounded by a double-layered membrane called the **pericardium** (pehr-ee-KAR-dee-um). The outermost layer of the pericardium, called the **fibrous pericardium**, anchors the heart to surrounding structures. It is made of dense irregular collagenous connective tissue that is not very distensible, which helps to prevent the heart from overfilling. The inner layer, called the **serous pericardium**, is itself composed of two layers. The outer portion, called the **parietal pericardium**, is functionally fused to the fibrous pericardium. Notice that at the edges of the heart, the parietal pericardium folds over on itself to attach to the heart muscle and form the inner layer of the serous membrane called the **visceral pericardium**, also known as the *epicardium*. Between the parietal and visceral layers we find a thin layer of serous fluid that occupies a narrow potential space called the **pericardial cavity**. The fluid within the pericardial cavity helps the heart to beat without friction.

FIGURE 17.3 Thoracic cavity: (A) anterior view; (B) left lateral view.

17

The heart itself is an organ that consists of three tissue layers:

1. **Epicardium.** The **epicardium** (ep-ih-KAR-dee-um) or visceral pericardium is considered the outermost layer of the heart wall. It consists of a layer of simple squamous epithelial tissue and loose connective tissue.
2. **Myocardium.** The middle **myocardium** (my-oh-KAR-dee-um) is the actual muscle of the heart. It consists of cardiac muscle tissue and its fibrous skeleton.
3. **Endocardium.** The innermost **endocardium** is a type of simple squamous epithelium called *endothelium*. It is continuous with the endothelium lining all blood vessels in the body.

Let's look now at the external anatomy of the heart, shown in Figure 17.5. As you can see in the figure, the atria receive blood from

17

FIGURE 17.5 Heart: (A) anterior view; (B) posterior view.

Be Active

Focused Activities are the guiding philosophy of this lab manual. Students learn best when they are actively engaged in the laboratory. In this manual, students are asked to be active by describing, labeling, writing, coloring, and drawing. 21 new activities have been added to this edition, including a starch solubility exercise, identifying structures of the shoulder joint, muscle fiber contraction, new special senses activities, and many more.

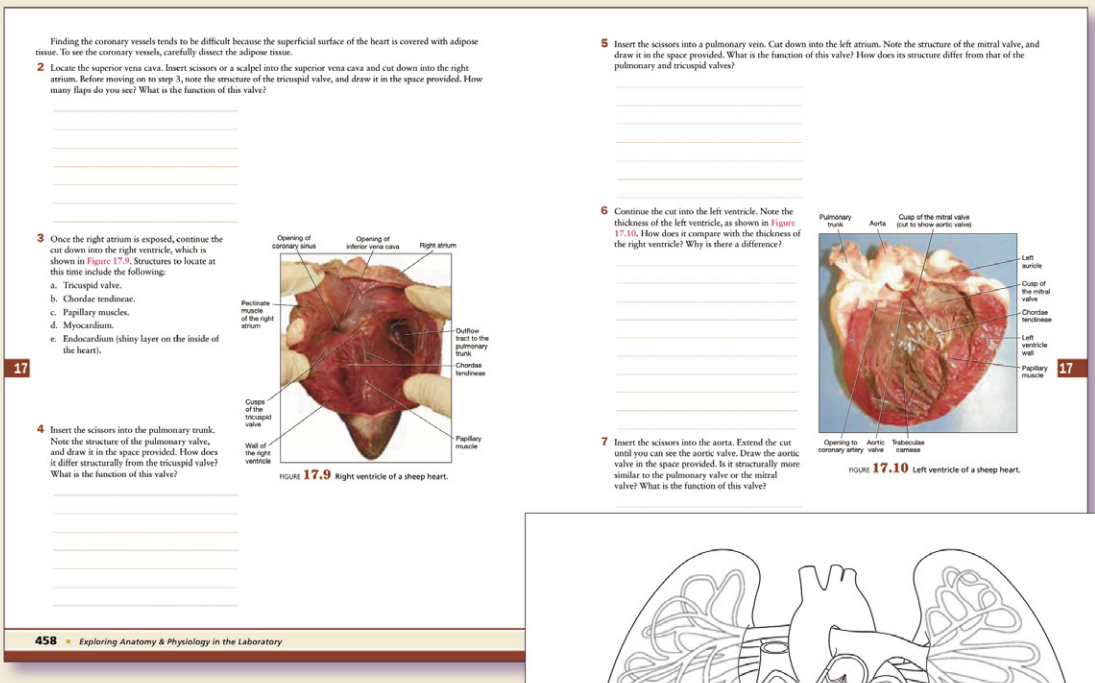

Finding the coronary vessels tends to be difficult because the superficial surface of the heart is covered with adipose tissue. To see the coronary vessels, carefully dissect the adipose tissue.

2 Locate the superior vena cava. Insert scissors or a scalpel into the superior vena cava and cut down into the right atrium. Before moving on to step 3, note the structure of the tricuspid valve, and draw it in the space provided. How many flaps do you see? What is the function of this valve?

3 Once the right atrium is exposed, continue the cut down into the right ventricle, which is shown in Figure 17.9. Structures to locate at this time include the following:

a. Tricuspid valve.
b. Chordae tendineae.
c. Papillary muscles.
d. Myocardium.
e. Endocardium (shiny layer on the inside of the heart).

17

Opening of coronary sinus
Opening of inferior vena cava
Right atrium
Pectinate muscle of the right atrium
Outflow tract to the pulmonary trunk
Chordae tendineae
Cusps of the tricuspid valve
Wall of the right ventricle
Papillary muscle

FIGURE 17.9 Right ventricle of a sheep heart.

4 Insert the scissors into the pulmonary trunk. Note the structure of the pulmonary valve, and draw it in the space provided. How does it differ structurally from the tricuspid valve? What is the function of this valve?

5 Insert the scissors into a pulmonary vein. Cut down into the left atrium. Note the structure of the mitral valve, and draw it in the space provided. What is the function of this valve? How does its structure differ from that of the pulmonary and tricuspid valves?

6 Continue the cut into the left ventricle. Note the thickness of the left ventricle, as shown in Figure 17.10. How does it compare with the thickness of the right ventricle? Why is there a difference?

Pulmonary trunk
Aorta
Cusp of the mitral valve (cut to show aortic valve)
Left auricle
Cusp of the mitral valve
Chordae tendineae
Left ventricle wall
Papillary muscle
Opening to coronary artery
Aortic valve
Trabeculae carneae

FIGURE 17.10 Left ventricle of a sheep heart.

7 Insert the scissors into the aorta. Extend the cut until you can see the aortic valve. Draw the aortic valve in the space provided. Is it structurally more similar to the pulmonary valve or the mitral valve? What is the function of this valve?

17

458 ■ *Exploring Anatomy & Physiology in the Laboratory*

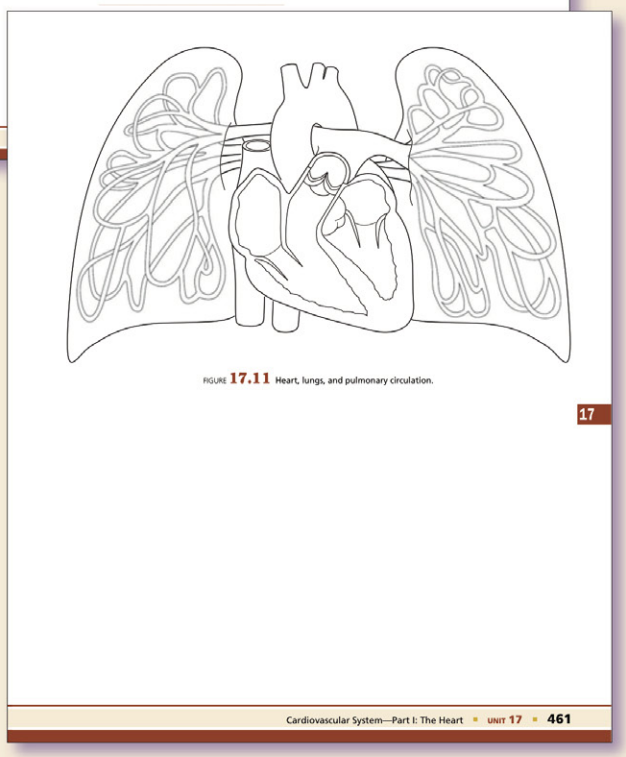

FIGURE 17.11 Heart, lungs, and pulmonary circulation.

17

Cardiovascular System—Part I: The Heart ■ UNIT 17 ■ 461

Tracing Exercises ask students to write step-by-step, turn-by-turn directions to follow substances (blood cells, food molecules, waste by-products, electrical events) through the human body, then trace the substances' path on a "map" of the body. These exercises allow students to see the big picture of how the body systems interact and to understand the relationship between structure and function.

Hints & Tips sidebars appear throughout the book to help students navigate some of the more difficult topics in A&P.

Be Sure

Check Your Progress sections completing each unit ensure that students understand key concepts and achieve the learning objectives, signaling that they are ready to move on. This new edition features new assessment questions throughout.

Check Your Recall "quizzes" consist of labeling, fill-in-the-blank, multiple choice, and sequencing questions that test the students' ability to retain the material they completed in the lab. These sheets can be used as graded lab quizzes and/or to check attendance in the lab.

Check Your Understanding "tests" ask students to use the information they have learned to answer critical thinking questions, frequently related to clinical scenarios. The ability to synthesize and apply knowledge is the desired outcome of any A&P course. These questions check students' deeper understanding by challenging them to provide answers they cannot find verbatim in either the lab manual or the textbook. New Check Your Understanding questions have been added to nearly every unit in this edition.

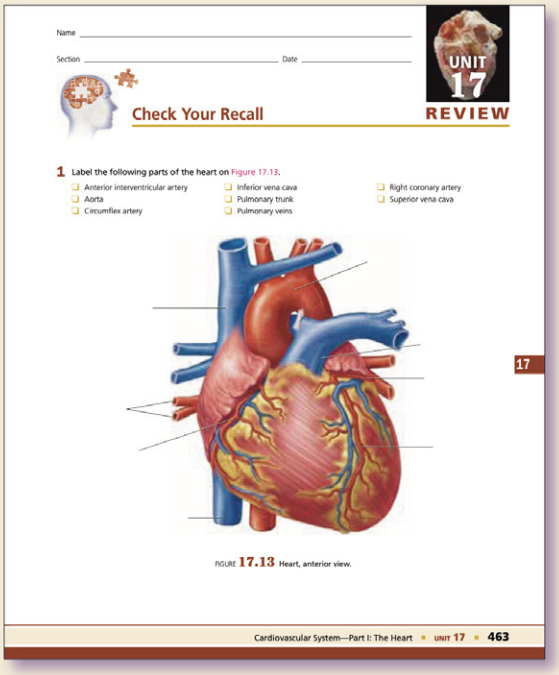

Name _____

Section _____ Date _____

UNIT 17 REVIEW

Check Your Recall

1 Label the following parts of the heart on Figure 17.13.

- ❑ Anterior interventricular artery
- ❑ Aorta
- ❑ Circumflex artery
- ❑ Inferior vena cava
- ❑ Pulmonary trunk
- ❑ Pulmonary veins
- ❑ Right coronary artery
- ❑ Superior vena cava

FIGURE **17.13** Heart, anterior view.

17

Cardiovascular System—Part I: The Heart ▪ UNIT 17 ▪ 463

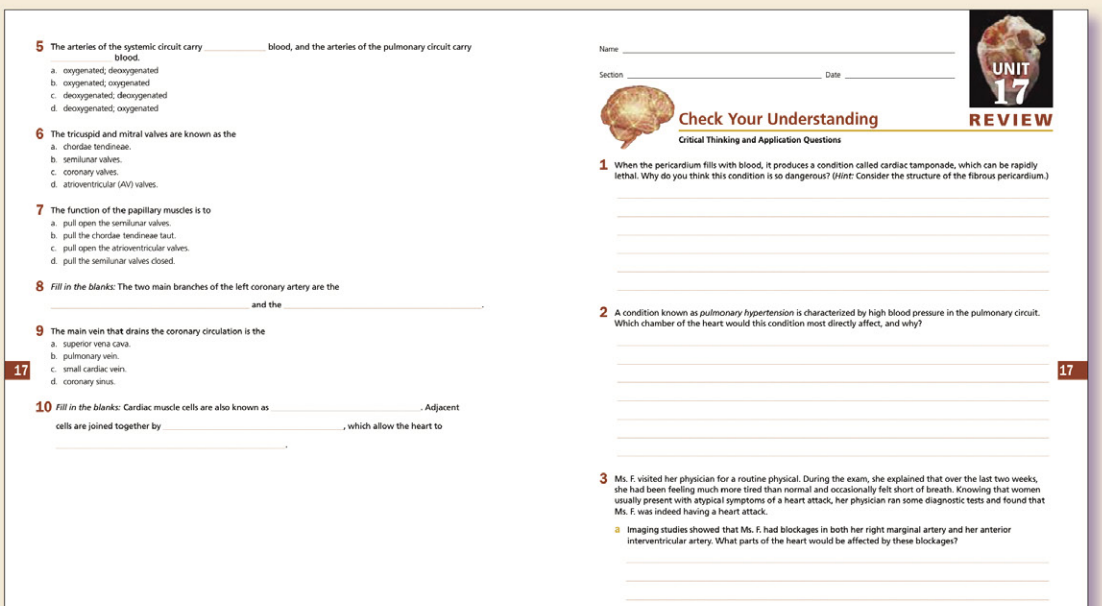

5 The arteries of the systemic circuit carry _____ blood, and the arteries of the pulmonary circuit carry _____ blood.

a. oxygenated; deoxygenated
b. oxygenated; oxygenated
c. deoxygenated; deoxygenated
d. deoxygenated; oxygenated

6 The tricuspid and mitral valves are known as the

a. chordae tendineae.
b. semilunar valves.
c. coronary valves.
d. atrioventricular (AV) valves.

7 The function of the papillary muscles is to

a. pull open the semilunar valves.
b. pull the chordae tendineae taut.
c. pull open the atrioventricular valves.
d. pull the semilunar valves closed.

8 *Fill in the blanks:* The two main branches of the left coronary artery are the _____ and the _____.

9 The main vein that drains the coronary circulation is the

a. superior vena cava.
b. pulmonary vein.
c. small cardiac vein.
d. coronary sinus.

17

10 *Fill in the blanks:* Cardiac muscle cells are also known as _____. Adjacent cells are joined together by _____, which allow the heart to _____.

Name _____

Section _____ Date _____

UNIT 17 REVIEW

Check Your Understanding

Critical Thinking and Application Questions

1 When the pericardium fills with blood, it produces a condition called cardiac tamponade, which can be rapidly lethal. Why do you think this condition is so dangerous? (*Hint:* Consider the structure of the fibrous pericardium.)

2 A condition known as *pulmonary hypertension* is characterized by high blood pressure in the pulmonary circuit. Which chamber of the heart would this condition most directly affect, and why?

17

3 Ms. F. visited her physician for a routine physical. During the exam, she explained that over the last two weeks, she had been feeling much more tired than normal and occasionally felt short of breath. Knowing that women usually present with atypical symptoms of a heart attack, her physician ran some diagnostic tests and found that Ms. F. was indeed having a heart attack.

a Imaging studies showed that Ms. F. had blockages in both her right marginal artery and her anterior interventricular artery. What parts of the heart would be affected by these blockages?

466 ▪ *Exploring Anatomy & Physiology in the Laboratory*

Cardiovascular System—Part I: The Heart ▪ UNIT 17 ▪ 467

Be Aware

Textbooks are expensive, and the last thing students need is to spend too much for a lab manual. Morton Publishing is committed to providing high-quality products at reasonable prices.

It is our sincere hope that *Exploring Anatomy & Physiology in the Laboratory*, 3e, will provide you the tools necessary for a productive and interesting laboratory experience. We welcome all comments and suggestions for future editions of this book. Please feel free to contact us at eapl@morton-pub.com or visit us at www.morton-pub.com.

Be Choosy

MortyPak Options

Bundle *Exploring Anatomy & Physiology in the Laboratory*, 3e, with one or more of the following supplemental titles:

- *A Visual Analogy Guide to Human Anatomy*
- *A Visual Analogy Guide to Human Physiology*
- *A Visual Analogy Guide to Human Anatomy and Physiology*
- *A Visual Analogy Guide to Chemistry*
- *A Photographic Atlas of Histology*
- *A Photographic Atlas for the A&P Laboratory*
- *A Dissection Guide and Atlas to the Rat*
- *A Dissection Guide and Atlas to the Fetal Pig*
- *A Dissection Guide and Atlas to the Mink*
- *Mammalian Anatomy: The Cat*
- *An Illustrated Atlas of the Skeletal Muscles*

Morton CustomLab

In an effort to lower the prices of books, and to provide instructors and students books tailored to their needs, we offer the enhanced Morton CustomLab program. With CustomLab, instructors can remove or combine material from our existing lab manuals or photographic atlases, or may use photographs and illustrations from our extensive online library, to create their own, personalized lab manual. Enrollment minimums apply.

E-books

As higher education continues to evolve and incorporate technology, we are pleased to offer our titles as e-books for students who prefer an e-format.

Pronunciation Guide

Note: Accented syllables are capitalized; for example "a-NAT-oh-mee and fiz-ee-AHL-oh-jee."

abdominal (ab-DAH-mih-nuhl)
abdominopelvic (ab-dom-ih-noh-PEL-vik)
abducens (ab-DOO-senz)
acetabulum (aeh-seh-TAB-yoo-lum)
acetylcholine (ah-SEE-til-koh'-leen)
acetylcholinesterase (ah-see-til-kohl-in-ESS-ter-ayz)
acinar (AY-sin-ahr)
acromial (ah-KROH-mee-uhl)
acromioclavicular (ah-KROH-mee-oh-klah-VIK-yoo-lur)
acromion (ah-KROH-mee-ahn)
acrosomal (ak-roh-ZOH-muhl)
adenohypophysis (ad-in-oh-hy-PAWF-ih-sis)
adipocytes (AD-ih-poh-syt'z)
adrenal (uh-DREE-nuhl)
adrenocorticotropic (ah-dree-noh-kohr-tih-koh-TROH-pik)
adventitia (ad-ven-TISH-uh)
agglutination (uh-gloo-tin-AY-shun)
agranulocytes (AY-gran-yoo-loh-syt'z)
alae (AY-lee)
albuginea (al-byoo-JIN-ee-uh)
aldosterone (al-DAHS-tur-ohn)
alleles (uh-LEELZ)
alveolar (al-vee-OH-lahr)
alveoli (al-vee-OH-lye)
amnion (AM-nee-ahn)
amphiarthroses (am-fee-ar-THROH-seez)
amphipathic (am-fih-PATH-ik)
amylase (AM-uh-layz)
antebrachial (an-tee-BRAY-kee-uhl)
antecubital (an-tee-KYOO-bih-tuhl)
anterior (an-TEER-ee-ur)
antidiuretic (an-tee-dy-yoo-RET-ik)
aorta (ay-OHR-tah)
aponeurosis (ap-oh-noo-ROH-sis)
arachnoid mater (ah-RAK-noyd MAH-tur)
arbor vitae (AR-bohr VEE-tay)
arcuate (ARK-yoo-it)
areola (aehr-ee-OH-lah)
arrector pili (ah-REK-tohr PIL-aye)
arteriosus (ahr-TEER-ee-oh-suss)
arytenoid (uh-RIT-uh-noyd)
atrioventricular (ay-tree-oh-ven-TRIK-yoo-lur)
atrium (AY-tree-um)
auricle (OHR-ih-kuhl)
auscultation (aws-kuhl-TAY-shun)
axillary (AX-il-ehr-ee)
axolemma (aks-oh-LEM-ah)
axon (AX-ahn)
azygos (ay-ZY-gus)
baroreceptor (BEHR-oh-reh-sep-ter)
basal lamina (BAY-zul LAM-in-uh)
basale (bay-SAY-lee)
basophils (BAY-zoh-filz)
biceps brachii (BY-seps BRAY-kee-aye)
blastocyst (BLAST-oh-sist)
brachial (BRAY-kee-uhl)
brachialis (bray-kee-AL-iss)
brachiocephalic (bray-kee-oh-seh-FAL-ik)
brachioradialis (bray-kee-oh-ray-dee-AL-iss)
bradycardia (bray-dih-KAR-dee-uh)
bronchi (BRONG-kye)
bronchial (BRONG-kee-uhl)
bronchioles (BRONG-kee-ohlz)
bronchomediastinal (brongk-oh-mee-dee-ah-STYN-uhl)
bruits (broo-eez)
buccal (BYOO-kuhl)
buccinator (BUK-sin-ay-tur)
bulbourethral (bul-boh-yoo-REETH-ruhl)
bursae (BURR-see)
calcaneal (kal-KAY-nee-uhl)
calcaneus (kal-KAYN-ee-us)
calcitonin (kal-sih-TOH-nin)
calvaria (kal-VEHR-ee-uh)
calyces (KAY-lih-seez)
canaliculi (kan-ah-LIK-yoo-lee)
canines (KAY-nynz)
capitulum (kah-PIT-yoo-lum)
carbonic anhydrase (kar-BAW-nik an-HY-dray'z)
carina (kuh-RY-nuh)
carneae (kar-NEE-ee)
carotid (kuh-RAWT-id)
carpal (KAR-puhl)
carpi radialis (KARP-aye ray-dee-AL-iss)
carpi ulnaris (KARP-aye uhl-NEHR-iss)
cauda equina (KOW-dah eh-KWY-nah)
cecum (SEE-kum)
celiac (SEE-lee-ak)
centrioles (SEN-tree-ohlz)
centromere (SIN-troh-meer)
centrosome (SEN-troh-sohm)
cephalic (sef-AL-ik)
cerebellum (sehr-eh-BELL-um)

cerebrospinal (seh-ree-broh-SPY-nuhl)
cerebrum (seh-REE-brum)
cervical (SIR-vih-kuhl)
cervicis (SIR-vih-sis)
chiasma (ky-AZ-mah)
chiasmata (ky-az-MAH-tah)
chylomicrons (ky-loh-MY-kronz)
chonchae (KAHN-kee)
chondrocytes (KAHN-droh-syt'z)
chordae tendineae (KOHRD-ee tin-din-EE-ee)
chorion (KOHR-ee-ahn)
chorionic villi (KOHR-ee-ahn-ik VILL-aye)
choroid (KOHR-oyd)
chromatin (KROH-mah-tin)
chromosomes (KROH-moh-sohmz)
chylomicrons (ky-loh-MY-kronz)
chyme (KAYE'M)
cilia (SILL-ee-uh)
ciliary body (SILL-ee-ehr-ee)
circumflex (SIR-kum-flex)
cisterna chyli (sis-TER-nah KY-lee)
cisternae (sis-TER-nee)
clitoris (KLIT-uhr-iss)
coccyx (KAHX-iks)
cochlea (KOHK-lee-ah)
colliculi (koll-IK-yoo-lye)
colloid (KAWL-oyd)
conceptus (kun-SEPT-uhs)
conchae (KAHN-kee)
conjunctiva (kon-junk-TY-vah)
conus medullaris (KOHN-us med-yoo-LEHR-us)
coracoid (KOHR-ah-koyd)
coracohumeral (kohr'-uh-koh-HYOO-muhr-uhl)
cornea (KOHR-nee-ah)
corniculate (kor-NIK-yoo-layt)
coronal (koh-ROH-nuhl)
coronary (KOHR-oh-nehr-ee)
corpora cavernosa (kohr-POHR-uh kah-ver-NOH-suh)
corpus callosum (KOHR-pus kal-OH-sum)
corpus luteum (KOHR-pus LOO-tee-um)
corpus spongiosum (KOHR-pus spun-jee-OH-sum)
cranial (KRAY-nee-uhl)
cremaster (kreh-MASS-ter)
cricoid (KRY-koyd)
cricothyroid (kry-koh-THY-royd)
cricothyroidotomy (kry-koh-thy-royd-AW-toh-mee)
crista galli (KRIS-tah GAL-ee)
cruciate (KROO-shee-iht)
crural (KROO-ruhl)
cubital (KYOO-bit-uhl)
cuneiform (kyoo-NEE-ih-form)
cystic (SIS-tik)
cytokines (SY-toh-kyn'z)
cytokinesis (sy-toh-kin-EE-sis)
cytoplasm (SY-toh-plaz-m)
cytosol (SY-toh-sahl)
deciduous (dih-SIJ-oo-uhs)
dendrites (DEN-dryt'z)
denticulate ligaments (den-TIK-yoo-lit)
deoxyribonucleic acid (dee-awks-ee-ry-boh-noo-KLAY-ik)
detrusor (dee-TROO-sur)
diaphragm (DY-uh-fram)
diaphysis (dy-AEH-fih-sis)
diarthroses (dy-ar-THROH-seez)
diastole (dy-AEH-stoh-lee)
diastolic (dy-uh-STAHL-ik)
diencephalon (dy-en-SEF-ah-lahn)
digital (DIJ-it-uhl)
diploid (DIH-ployd)
dorsalis pedis (dohr-SAL-iss PEE-diss)
ductus deferens (DUK-tuss DEF-er-ahnz)
duodenum (doo-AW-den-um)
dura mater (DOO-rah MAH-tur)
embryogenesis (em-bree-oh-JEN-ih-sis)
endolymph (EN-doh-limf)
endometrium (en-doh-MEE-tree-um)
endomysium (en-doh-MY-see-um)
endoneurium (en-doh-NOOR-ee-um)
endoplasmic reticulum (en-doh-PLAZ-mik reh-TIK-yoo-lum)
endosteum (en-DAH-stee-um)
eosinophils (ee-oh-SIN-oh-filz)
ependymal (eh-PEN-dih-muhl)
epicardium (ep-ih-KAR-dee-um)
epicondyles (ep-ih-KAHN-dyl'z)
epicranius (ep-ih-KRAY-ih-nee-uhs)
epididymis (ep-ih-DID-ih-miss)
epidural (ep-ih-DOO-ruhl)
epiglottis (ep-ih-GLAW-tiss)
epimysium (ep-ih-MY-see-um)
epineurium (ep-ih-NOOR-ee-um)
epiphyseal (eh-PIF-ih-seel)
epiphysis (eh-PIF-ih-seez)
epiploic (ep-ih-PLOH-ik)
epithalamus (ep-ih-THAL-ih-mus)
epithelial (ep-ih-THEE-lee-uhl)
eponychium (ep-oh-NIK-ee-um)
erector spinae (eh-REK-tohr SPY-nee)
erythrocytes (eh-RITH-roh-syt'z)
erythropoietin (eh-rith-roh-POY-ee-tin)
esophagus (eh-SOF-ah-gus)
falciform (FALL-sih-form)
falx cerebelli (FALS sehr-eh-BELL-ee)
falx cerebri (FALS seh-REE-bree)
fascia (FASH-uh)
fascicles (FASS-ih-kullz)
faciculata (fah-SIK-yoo-lah-tah)
femoral (FEM-oh-ruhl)
fibroblasts (FY-broh-blastz)
fibula (FIB-yoo-lah)
fibularis (fib-yoo-LEHR-iss)
filum terminale (FY-lum ter-mee-NAL-ay)
fimbriae (FIM-bree-ay)
flagella (flah-JEL-uh)
fossa ovalis (FAWS-ah oh-VAL-is)
fovea capitis (FOH-vee-uh CAP-ih-tiss)
fovea centralis (FOH-vee-uh sin-TRAL-iss)
frontal (FRUHN-tuhl)
frontalis (frun-TAL-iss)
funiculi (fun-IK-yoo-lye)
gametes (GAM-eetz)
gametogenesis (gah-meet-oh-JEN-us-sis)

gastrocnemius (gas-trawk-NEE-mee-uhs)
genotype (JEE-noh-type)
gingivae (JIN-jih-vay)
glenohumeral (glen'-oh-HYOO-mur-uhl)
glomerulosa (glom-ehr-yoo-LOH-sah)
glomerulus (gloh-MEHR-yoo-lus)
glossopharyngeal (glah-soh-fehr-IN-jee-uhl)
glucagon (GLOO-kah-gawn)
glucocorticoids (gloo-koh-KORT-ih-koydz)
gluteal (GLOO-tee-uhl)
glycoproteins (GLY-koh-proh-teenz)
gonadocorticoids (goh-nad-oh-KORT-ih-koydz)
Golgi (GOHL-jee)
gomphosis (gahm-FOH-sis)
gracilis (gruh-SILL-iss)
granulocytes (GRAN-yoo-loh-syt'z)
granulosum (gran-yoo-LOH-sum)
gyri (JY-ree)
haploid (HAP-loyd)
haustra (HAW-struh)
hematocrit (heh-MAEH-toh-krit)
hemoglobin (HEE-moh-glohb-in)
hemolysis (heem-AW-lih-sis)
hepatopancreatic ampulla (heh-PAEH-toh-payn-kree-at-ik am-POOL-ah)
heterozygous (het-er-oh-ZY-gus)
hilum (HY-lum)
homozygous (hoh-moh-ZY-gus)
humerus (HYOO-mur-us)
hyaline (HY-ah-lin)
hydrophilic (hy-droh-FIL-ik)
hydrophobic (hy-droh-FOH-bik)
hypothalamus (hy-poh-THAL-uh-muss)
hypophyseal (hy-PAW-fih-see-uhl)
ileocecal (ill-ee-oh-SEE-kuhl)
ileum (ILL-ee-um)
iliac (ILL-ee-ak)
iliacus (ILL-ee-AK-uhs)
iliocostalis (ill-ee-oh-kawst-AL-iss)
iliohypogastric (ill-ee-oh-hy-poh-GAS-trik)
ilioinguinal (ill-ee-oh-IN-gwin-uhl)
iliopsoas (ill-ee-oh-SOH-uhs)
ilium (ILL-ee-um)
incus (ING-kus)
infraspinatus (in-frah-spin-AY-tuhs)
infundibulum (in-fun-DIB-yoo-lum)
inguinal (IN-gwin-uhl)
integument (in-TEG-yoo-ment)
integumentary (in-TEG-yoo-MEN-tuh-ree)
interatrial (in-ter-AY-tree-uhl)
intercalated (in-TUR-kuh-layt-ed)
intertrochanteric (in-ter-troh-kan-TEHR-ik)
intertubercular sulcus (in-ter-too-BUR-kyoo-lur SUL-kuss)
intraperitoneal (in-trah-pehr-ih-toh-NEE-uhl)
ischium (ISS-kee-um)
islets (AYE-lets)
jejunum (jeh-JOO-num)
jugular (JUG-yoo-lur)
juxtaglomerular (jux-tah-gloh-MEHR-yoo-lur)
keratin (KEHR-ah-tin)
keratinocyte (kehr-ah-TIN-oh-sy't)
Korotkoff (koh-ROT-koff)
labia (LAY-bee-ah)
labrum (LAY-brum)
lacerum (LAS-er-um)
lacrimal (LAK-rih-muhl)
lacrimal caruncle (LAK-rih-muhl kar-UN-kuhl)
lacteal (lak-TEEL)
lacunae (lah-KOO-nee)
lambdoid (LAM-doyd)
lamellae (lah-MELL-ee)
laryngopharynx (lah-ring-oh-FEHR-inks)
larynx (LEHR-inks)
latissimus dorsi (lah-TISS-ih-muss DOHR-sye)
leukocytes (LOO-koh-syt'z)
linea aspera (LIN-ee-ah ASS-per-ah)
lingual (LING-yoo-uhl)
lipase (LY-payz)
longissimus (lawn-JISS-ih-muss)
lucidum (LOO-sid-um)
lumbar (LUHM-bahr)
lunula (LOON-yoo-luh)
luteinizing (LOO-tee-in-aye-zing)
lymph (LIMF)
lymphatic (limf-AEH-tik)
lymphocytes (LIMF-oh-syt'z)
lysosomes (LY-soh-zohmz)
macrophages (MAK-roh-feyk-uhz)
macula densa (MAK-yoo-lah-DEN-sah)
macula lutea (MAK-yoo-lah LOO-tee-ah)
malleolus (mal-ee-OH-lus)
malleus (MAL-ee-us)
mammary (MAM-uh-ree)
manual (MAN-yoo-uhl)
manubrium (mah-NOO-bree-um)
masseter (MASS-uh-tur)
maxillae (mak-SILL-ee)
mediastinum (mee-dee-uh-STY-num)
medius (MEE-dee-uhs)
medulla oblongata (meh-DOOL-uh ahb-lahn-GAH-tuh)
meiosis (MY-oh-sis)
melanin (MEL-uh-nin)
melanocytes (mel-AN-oh-syt'z)
melatonin (mel-uh-TOH-nin)
meninges (meh-NIN-jeez)
menisci (men-ISS-kee)
mental (MEN-tuhl)
mesenchyme (MEZ-en-ky'm)
mesenteric (mez-en-TEHR-ik)
mesentery (MEZ-en-tehr-ee)
metopic (met-AHP-ik)
micelles (my-SELLZ)
microglial (my-kroh-GLEE-uhl)
microvilli (my-kroh-VIL-aye)
micturition (mik-choo-RISH-un)
mineralocorticoids (min-er-al-oh-KORT-ih-koydz)

mitochondria (my-toh-KAHN-dree-ah)
mitosis (my-TOH-sis)
mitral (MY-tral)
monocytes (MAHN-oh-syt'z)
monosaccharide (mahn-oh-SAK-uh-ry'd)
mons pubis (MAHNS PYOO-biss)
morula (MOHR-yoo-luh)
musculocutaneous (musk-yoo-loh-kyoo-TAY-nee-us)
myelin (MY-lin)
myocardium (MY-oh-kar-dee-um)
myocytes (MY-oh-syt'z)
myofibrils (my-oh-FY-brillz)
myometrium (my-oh-MEE-tree-um)
myosin (MY-oh-sin)
nasal (NAY-zuhl)
nasopharynx (nayz-oh-FEHR-inks)
nephrons (NEF-rahnz)
neurilemma (noor-ih-LEM-uh)
neuroglial (noor-oh-GLEE-uhl)
neurohypophysis (noor-oh-hy-PAWF-ih-sis)
neurons (NOOR-ahnz)
neutrophils (NOO-troh-filz)
nuchal (NOO-kuhl)
nucleolus (noo-klee-OH-lus)
nucleus (NOO-klee-us)
obturator (AHB-too-ray-tur)
occipital (awk-SIP-ih-tuhl)
occipitalis (awk-SIP-ih-TAL-iss)
ocular (AWK-yoo-lur)
oculomotor (awk-yoo-loh-MOH-tohr)
olecranon (oh-LEK-rah-nahn)
oligodendrocytes (oh-lig-oh-DEN-droh-syt'z)
omentum (oh-MEN-tum)
oocytes (OH-oh-syt'z)
oogenesis (oh-oh-JEN-eh-sis)
oogonia (oh-oh-GOH-nee-uh)
oral (OH-ruhl)
orbicularis oculi (ohr-bik-yoo-LEHR-iss AWK-yoo-lye)
orbital (OHR-bit-uhl)
organelles (ohr-gan-ELLZ)
oropharynx (ohr-oh-FEHR-inks)
osmosis (oz-MOH-sis)
osseous (AHS-see-us)
ossicles (AW-sih-kullz)
osteoblasts (AH-stee-oh-blasts)
osteoclasts (AH-stee-oh-klasts)
osteocytes (AHS-tee-oh-syt'z)
osteogenic (ah-stee-oh-JEN-ik)
osteons (AH-stee-ahnz)
otic (OH-tik)
ovale (oh-VAL-ay)
oxytocin (awks-ee-TOH-sin)
palate (PAL-it)
palatine (PAL-uh-ty'n)
palmar (PAHL-mur)
palpebrae (pal-PEE-bree)
pancreas (PAYN-kree-us)
papillae (pah-PILL-ee)
parietal (puh-RY-ih-tuhl)
parotid (puh-RAWT-id)
patella (puh-TEL-uh)
pectinate (PEK-tin-et)
pectineus (pek-TIN-ee-uhs)
pedal (PEE-duhl)
pelvic (PEL-vik)
pericardial (pehr-ee-KAR-dee-uhl)
pericardium (pehr-ee-KAR-dee-um)
perilymph (PEHR-ee-limf)
perimetrium (pehr-ee-MEE-tree-um)
perimysium (pehr-ih-MY-see-um)
perineurium (pehr-ih-NOOR-ee-um)
periodontal ligament (pehr-ee-oh-DAHN-tuhl)
periosteum (pehr-ee-AH-stee-um)
peristalsis (pehr-ih-STAHL-sis)
peritoneal (pehr-ih-toh-NEE-uhl)
peroxisomes (per-AWKS-ih-zohms)
phalanges (fuh-LAN-jeez)
pharyngotympanic (fah-ring-oh-tim-PAN-ik)
pheochromocytoma (fee-uh-kroh-muh-sy-TOH-muh)
pharynx (FEHR-inks)
phenotype (FEE-noh-type)
phospholipid (FAHS-foh-lip-id)
phrenic (FREN-ik)
pia mater (PEE-ah MAH-tur)
pineal (pin-EE-uhl)
pituitary (pih-TOO-ih-tehr-ee)
placenta (plah-SIN-tuh)
plantar (PLAN-tahr)
platelets (PLAYT-letz)
platysma (plah-TIZ-muh)
pleural (PLOO-ruhl)
pneumothorax (noo-moh-THOR-ax)
podocytes (POH-doh-syt'z)
polysaccharide (pawl-ee-SAK-uh-ry'd)
popliteal (pahp-lih-TEE-uhl)
porta hepatis (POR-tuh heh-PAEH-tis)
prostate (PRAW-stayt)
proximal (PRAWKS-ih-muhl)
pseudostratified (SOO-doh-strat-ih-fy'd)
pterygoid (TEHR-ih-goyd)
pubic (PYOO-bik)
pubis (PYOO-bis)
pudendal nerve (poo-DEN-duhl)
Purkinje (pur-KIN-jee)
pylorus (py-LOHR-us)
pyrogens (PY-roh-jenz)
radius (RAY-dee-us)
rami (RAY-mee)
Ranvier (rahn-vee-ay)
renal (REE-nuhl)
rete testis (REE-tee TES-tis)
retina (RET-in-ah)
retroperitoneal (reh-troh-per-ih-toh-NEE-uhl)
ribosomes (RY-boh-zohmz)
Rinne (rinn-ay)
risorius (ry-ZOHR-ee-uhs)
rugae (ROO-ghee)
saccule (SAK-yool)
sacroiliac (say-kroh-ILL-ee-ak)
sacrum (SAY-krum)

sagittal (SAJ-ih-tuhl)
saphenous (SAF-en-us)
sarcolemma (sar-koh-LEM-uh)
sarcomere (SAR-koh-meer)
sarcoplasm (SAHR-koh-plazm)
sarcoplasmic reticulum (sar-koh-PLAZ-mik reh-TIK-yoo-lum)
sartorius (sar-TOHR-ee-uhs)
scapula (SKAP-yoo-lah)
scapular (SKAP-yoo-lur)
sciatic (sy-AEH-tik)
sclera (SKLEHR-ah)
sebaceous (seh-BAY-shuhs)
sebum (SEE-bum)
sella turcica (SELL-uh TUR-sih-kuh)
semimembranosus (sem-aye-mem-brah-NOH-suhs)
seminiferous (sem-ih-NIF-er-us)
semitendinosus (sem-aye-ten-din-OH-suhs)
seromucous (seer-oh-MYOO-kuss)
serous (SEER-us)
serratus (ser-AY-tuhs)
sinoatrial (sy-noh-AY-tree-uhl)
soleus (SOHL-ee-uhs)
spermatogenesis (sper-mat-oh-JEN-ih-sis)
spermatogonia (sper-mat-oh-GOH-nee-ah)
sphenoid (SFEE-noyd)
sphygmomanometer (sfig-moh-muh-NAH-muh-ter)
spinalis (spy-NAL-iss)
spinosum (spin-OH-sum)
spirometer (spih-RAH-meh-ter)
splenic (SPLEN-ik)
splenius capitis (SPLEN-ee-uhs CAP-it-uhs)
squamous (SKWAY-muss)
stapes (STAY-peez)
stenosis (sten-OH-sis)
sternal (STUR-nuhl)
sternocleidomastoid (stern-oh-kly-doh-MASS-toy'd)
stethoscope (STETH-oh-skohp)
stratum corneum (STRAT-um KOHR-nee-um)
striated (STRY-ayt-ed)
subclavian (sub-KLAY-vee-in)
sublingual (sub-LING-gwuhl)
subscabularis (sub-skap-yoo-LEHR-uhs)
sulci (SUL-kee)
supracondylar (soo-prah-KAHN-dah-lar)
supraspinatus (soo-prah-spin-AY-tuhs)
sural (SOO-ruhl)
sutural (SOO-tchur-uhl)
sutures (SOO-tchurz)
symphyses (SIM-fih-seez)
synapse (SIN-apz)
synarthroses (sin-ar-THROH-seez)
synchondroses (sin-khan-DROH-seez)
syndesmoses (sin-dez-MOH-seez)
synovial (sih-NOH-vee-uhl)
systole (SIS-toh-lee)
systolic (sis-TAHL-ik)
tachycardia (tak-ih-KAR-dee-uh)
taeniae coli (TEE-nee-ee KOHL-aye)
talus (TAY-luss)
tarsal (TAR-suhl)
telodendria (tee-loh-DEN-dree-uh)
telophase (TEL-oh-phayz)
temporalis (tem-pur-AL-iss)
teres (THER-eez)
thalamus (THAL-uh-muss)
thoracic (thoh-RAS-ik)
thymopoietin (thy-moh-poh-EE-tin)
tibia (TIB-ee-ah)
tibialis (tib-ee-AL-is)
trabeculae (trah-BEK-yoo-lee)
trachea (TRAY-kee-uh)
transversus (tranz-VUR-suss)
trapezius (trah-PEE-zee-uhs)
triglycerides (try-GLISS-er-ay'dz)
trigone (TRY-gohn)
triiodothyronine (try-aye-oh-doh-THY-roh-neen)
trochanter (TROH-kan-tur)
trochlea (TROH-klee-uh)
trophoblast (TROHF-oh-blast)
tropomyosin (trohp-oh-MY-oh-sin)
troponin (TROH-poh-nin)
tympanic (tim-PAN-ik)
umbilical (um-BIL-ih-kuhl)
ureteral (yoo-REE-ter-uhl)
ureters (YOOR-eh-terz)
urethra (yoo-REETH-ruh)
uterosacral (yoo-ter-oh-SAY-kruhl)
uterus (YOO-ter-us)
utricle (YOO-trih-kuhl)
uvea (YOO-vee-uh)
uvula (YOO-vyoo-luh)
vagus (VAY-gus)
vena cava (VEE-nah KAY-vah)
venosus (veh-NOH-suss)
vermis (VER-miss)
vertebral (vur-TEE-bruhl)
vestibulocochlear (ves-tib-yoo-loh-KOHK-lee-ur)
villi (VILL-aye)
visceral (VISS-er-uhl)
vitreous (VIT-ree-us)
vomer (VOH-muhr)
xiphoid (ZY-foyd)
zygote (ZY-goh't)

Contents

1 Introduction to Anatomical Terms 1

PRE-LAB EXERCISE 1-1 Key Terms 3
PRE-LAB EXERCISE 1-2 Body Cavities 4
EXERCISE 1-1 Anatomical Position 5
EXERCISE 1-2 Directional Terms 6
EXERCISE 1-3 Regional Terms 9
EXERCISE 1-4 Body Cavities and Membranes 13
EXERCISE 1-5 Planes of Section 21
EXERCISE 1-6 Organs and Organ Systems 24
Check Your Recall 29
Check Your Understanding 33

2 Chemistry 37

PRE-LAB EXERCISE 2-1 Key Terms 38
PRE-LAB EXERCISE 2-2 The pH Scale and –logarithms 39
PRE-LAB EXERCISE 2-3 Chemical Bonding 40
EXERCISE 2-1 pH, Acids, and Bases 43
EXERCISE 2-2 Buffers 46
EXERCISE 2-3 Enzymes and Chemical Reactions 47
EXERCISE 2-4 Chemical Solubilities 49
EXERCISE 2-5 DNA Extraction 53
Check Your Recall 55
Check Your Understanding 57

3 Introduction to the Microscope 59

EXERCISE 3-1 Introduction to the Microscope 60

4 Cytology 69

PRE-LAB EXERCISE 4-1 Key Terms 70
PRE-LAB EXERCISE 4-2 The Plasma Membrane 72
PRE-LAB EXERCISE 4-3 The Parts of the Cell 73
PRE-LAB EXERCISE 4-4 The Cell Cycle 74
EXERCISE 4-1 Organelles and Cell Structures 75
EXERCISE 4-2 Diffusion 81
EXERCISE 4-3 Osmosis and Tonicity 84
EXERCISE 4-4 Mitosis and the Cell Cycle 88
Check Your Recall 93
Check Your Understanding 95

5 Histology 97

PRE-LAB EXERCISE 5-1 Key Terms 99
EXERCISE 5-1 Epithelial Tissue 103
EXERCISE 5-2 Connective Tissue 111
EXERCISE 5-3 Muscle Tissue 121
EXERCISE 5-4 Nervous Tissue 125
EXERCISE 5-5 Organology 126
Check Your Recall 127
Check Your Understanding 131

6 Integumentary System 133

PRE-LAB EXERCISE 6-1 Key Terms 134
PRE-LAB EXERCISE 6-2 Skin Anatomy 135
PRE-LAB EXERCISE 6-3 Hair and Nail Anatomy 136
EXERCISE 6-1 Skin Anatomy and Accessory Structures 137
EXERCISE 6-2 Histology of Integument 142
EXERCISE 6-3 Touch Receptor Distribution 145
EXERCISE 6-4 Fingerprinting 146
Check Your Recall 149
Check Your Understanding 151

7 Introduction to the Skeletal System 153

PRE-LAB EXERCISE 7-1 Key Terms 155
PRE-LAB EXERCISE 7-2 Microscopic Anatomy of Compact Bone 157
PRE-LAB EXERCISE 7-3 Structure of a Long Bone 158
EXERCISE 7-1 Histology of Osseous Tissue 159
EXERCISE 7-2 Chemical Components of Bone Tissue 163
EXERCISE 7-3 Bone Markings and Bone Shapes 164
EXERCISE 7-4 Anatomy of Long Bones 166
Check Your Recall 169
Check Your Understanding 171

8 Skeletal System 173

PRE-LAB EXERCISE 8-1 Key Terms 174
PRE-LAB EXERCISE 8-2 Bones of the Skull 175
PRE-LAB EXERCISE 8-3 Whole Skeleton 177
EXERCISE 8-1 The Skull 180
EXERCISE 8-2 Remainder of the Axial Skeleton 191
EXERCISE 8-3 The Appendicular Skeleton 196
EXERCISE 8-4 More Practice 207
Check Your Recall 213
Check Your Understanding 223

9 Articulations 225

PRE-LAB EXERCISE 9-1 Key Terms 226
PRE-LAB EXERCISE 9-2 Anatomy of Synovial Joints 228
PRE-LAB EXERCISE 9-3 The Knee Joint 229
PRE-LAB EXERCISE 9-4 The Shoulder Joint 230
EXERCISE 9-1 Classification of Joints 231
EXERCISE 9-2 Synovial Joints 235
EXERCISE 9-3 Knee Joint 238
EXERCISE 9-4 Shoulder Joint 241
EXERCISE 9-5 Motions of Synovial and Cartilaginous Joints 243
Check Your Recall 247
Check Your Understanding 251

10 Muscular System: The Gross Anatomy of Muscles 253

PRE-LAB EXERCISE 10-1 Key Terms 254
PRE-LAB EXERCISE 10-2 Skeletal Muscle Anatomy 255
PRE-LAB EXERCISE 10-3 Muscle Origins, Insertions, and Actions 259
EXERCISE 10-1 Skeletal Muscles 261
EXERCISE 10-2 Muscle Origins, Insertions, and Actions 276
Check Your Recall 281
Check Your Understanding 287

11 Muscle Tissue 289

PRE-LAB EXERCISE 11-1 Key Terms 290
PRE-LAB EXERCISE 11-2 Basic Skeletal Muscle Anatomy 292
PRE-LAB EXERCISE 11-3 Muscle Fiber Microanatomy 293
PRE-LAB EXERCISE 11-4 Types of Muscle Tissue 294
EXERCISE 11-1 Microscopic Anatomy of Skeletal Muscle Tissue 295
EXERCISE 11-2 Muscle Physiology 301
EXERCISE 11-3 Smooth and Cardiac Muscle Tissues 305
Check Your Recall 307
Check Your Understanding 311

12 Introduction to the Nervous System 313

PRE-LAB EXERCISE 12-1 Key Terms 315
PRE-LAB EXERCISE 12-2 Nervous Tissue Microanatomy 316
EXERCISE 12-1 Neurons and Neuroglia 317
EXERCISE 12-2 Nervous Tissue Physiology 324
Check Your Recall 327
Check Your Understanding 331

13 Central Nervous System 333

PRE-LAB EXERCISE 13-1 Key Terms 334
PRE-LAB EXERCISE 13-2 Brain Anatomy 336
PRE-LAB EXERCISE 13-3 Spinal Cord Anatomy 338
EXERCISE 13-1 Anatomy of the Brain 339
EXERCISE 13-2 The Spinal Cord 349
Check Your Recall 353
Check Your Understanding 357

14 Peripheral and Autonomic Nervous System 359

PRE-LAB EXERCISE 14-1 Key Terms 361
PRE-LAB EXERCISE 14-2 Peripheral Nerve Anatomy 362
PRE-LAB EXERCISE 14-3 Cranial Nerve Functions 363
PRE-LAB EXERCISE 14-4 Spinal Nerve Plexuses and the Anterior Rami of the Spinal Nerves 364
PRE-LAB EXERCISE 14-5 Anterior Rami of the Spinal Nerves: Locations and Functions 365
PRE-LAB EXERCISE 14-6 Branches of the Autonomic Nervous System 366
EXERCISE 14-1 Peripheral Nerve Anatomy 367
EXERCISE 14-2 The Cranial Nerves 369
EXERCISE 14-3 Spinal Nerves and Reflexes 375
EXERCISE 14-4 The Autonomic Nervous System 381
Check Your Recall 383
Check Your Understanding 387

15 General and Special Senses 389

PRE-LAB EXERCISE 15-1 Key Terms 390
PRE-LAB EXERCISE 15-2 Anatomy of the Eye 392
PRE-LAB EXERCISE 15-3 Extrinsic Eye Muscles 393
PRE-LAB EXERCISE 15-4 Anatomy of the Ear 394
EXERCISE 15-1 Anatomy of the Eye and Vision 395
EXERCISE 15-2 Anatomy of the Ear, Hearing, and Equilibrium 403
EXERCISE 15-3 Olfactory and Taste Senses 408
EXERCISE 15-4 The General Senses: Cutaneous Sensation 410
Check Your Recall 413
Check Your Understanding 417

16 Endocrine System 419

PRE-LAB EXERCISE 16-1 Key Terms 420
PRE-LAB EXERCISE 16-2 Endocrine System Anatomy 422
PRE-LAB EXERCISE 16-3 Hormones: Target Tissues and Effects 423
EXERCISE 16-1 Endocrine System Anatomy 425
EXERCISE 16-2 Endocrine Organ Histology 430
EXERCISE 16-3 Time to Trace! Negative Feedback Loops 433
EXERCISE 16-4 Endocrine "Mystery Cases" 435
Check Your Recall 439
Check Your Understanding 443

17 Cardiovascular System—Part I: The Heart 445

PRE-LAB EXERCISE 17-1 Key Terms 446
PRE-LAB EXERCISE 17-2 Anatomy of the Thoracic Cavity 447
PRE-LAB EXERCISE 17-3 Anatomy of the Heart 448
PRE-LAB EXERCISE 17-4 Pathway of Blood Flow through the Heart 450
EXERCISE 17-1 Anatomy of the Heart 451
EXERCISE 17-2 Cardiac Muscle Histology 462
Check Your Recall 463
Check Your Understanding 467

18 Cardiovascular System—Part II: Blood Vessel Anatomy 469

PRE-LAB EXERCISE 18-1 Arterial Anatomy 471
PRE-LAB EXERCISE 18-2 Venous Anatomy 472
EXERCISE 18-1 Major Arteries of the Body 473
EXERCISE 18-2 Major Veins of the Body 478
EXERCISE 18-3 Time to Trace! 486
EXERCISE 18-4 Histology of the Blood Vessel Wall 491
EXERCISE 18-5 Clinical Applications 494
Check Your Recall 497
Check Your Understanding 503

19 Cardiovascular System—Part III: Cardiovascular Physiology 505

PRE-LAB EXERCISE 19-1 Key Terms 506
PRE-LAB EXERCISE 19-2 Autonomic Nervous System and the Cardiovascular System 508
EXERCISE 19-1 Heart Auscultation 509
EXERCISE 19-2 Vascular Examination 511
EXERCISE 19-3 Blood Pressure 513
EXERCISE 19-4 The Ankle-Brachial Index 516
EXERCISE 19-5 The Electrocardiogram 518
Check Your Recall 523
Check Your Understanding 527

20 Blood 529

PRE-LAB EXERCISE 20-1 Key Terms 530
PRE-LAB EXERCISE 20-2 Formed Elements 532
EXERCISE 20-1 Formed Elements (Cells) of Blood 533
EXERCISE 20-2 ABO and Rh Blood Groups 537
EXERCISE 20-3 Murder Mystery Game 540
EXERCISE 20-4 Blood Donation 543
EXERCISE 20-5 Typing and Examining Your Own Blood 546
Check Your Recall 549
Check Your Understanding 551

21 Lymphatics and Immunity 553

PRE-LAB EXERCISE 21-1 Key Terms 554
PRE-LAB EXERCISE 21-2 Anatomy of the Lymphatic System 556
EXERCISE 21-1 Lymphatic System Anatomy 557
EXERCISE 21-2 Lymphatic Organ Histology 563
EXERCISE 21-3 The Immune Response 567
EXERCISE 21-4 ELISA Test for Antigens 570
Check Your Recall 573
Check Your Understanding 577

22 Respiratory System 579

PRE-LAB EXERCISE 22-1 Key Terms 580
PRE-LAB EXERCISE 22-2 Respiratory System Anatomy 582
EXERCISE 22-1 Respiratory System Anatomy 585
EXERCISE 22-2 Histology of the Respiratory Tract 593
EXERCISE 22-3 Lung Inflation 597
Check Your Recall 599
Check Your Understanding 603

23 Respiratory System Physiology 605

PRE-LAB EXERCISE 23-1 Key Terms 606
PRE-LAB EXERCISE 23-2 Defining Pulmonary Volumes and Capacities 607
PRE-LAB EXERCISE 23-3 Labeling Pulmonary Volumes and Capacities 608
EXERCISE 23-1 Pressure-Volume Relationships in the Lungs 609
EXERCISE 23-2 Measuring Pulmonary Volumes and Capacities 611
EXERCISE 23-3 pH and Ventilation 615
Check Your Recall 617
Check Your Understanding 619

24 Digestive System 621
PRE-LAB EXERCISE 24-1 Key Terms 622
PRE-LAB EXERCISE 24-2 Anatomy of the Digestive System 624
PRE-LAB EXERCISE 24-3 Digestive Enzymes 628
EXERCISE 24-1 Digestive System Anatomy 629
EXERCISE 24-2 Digestive System Histology 641
EXERCISE 24-3 Digestion 649
EXERCISE 24-4 Time to Trace! 655
Check Your Recall 657
Check Your Understanding 661

25 Urinary System Anatomy 663
PRE-LAB EXERCISE 25-1 Key Terms 664
PRE-LAB EXERCISE 25-2 Structures of the Urinary System 666
PRE-LAB EXERCISE 25-3 Microanatomy of the Kidney 668
EXERCISE 25-1 Urinary System Anatomy 669
EXERCISE 25-2 Urinary Organ Histology 680
Check Your Recall 683
Check Your Understanding 687

26 Urinary System Physiology 689
PRE-LAB EXERCISE 26-1 Key Terms 690
PRE-LAB EXERCISE 26-2 Nephron Structure and Function 691
PRE-LAB EXERCISE 26-3 Glomerular Filtration and Tubular Reabsorption 692
EXERCISE 26-1 The Model Kidney 695
EXERCISE 26-2 Urinalysis 697
EXERCISE 26-3 Time to Trace! 700
Check Your Recall 703
Check Your Understanding 705

27 Reproductive System 707
PRE-LAB EXERCISE 27-1 Key Terms 708
PRE-LAB EXERCISE 27-2 Male Reproductive Anatomy 710
PRE-LAB EXERCISE 27-3 Female Reproductive Anatomy 711
PRE-LAB EXERCISE 27-4 Stages of Mitosis 712
EXERCISE 27-1 Male Reproductive Anatomy 713
EXERCISE 27-2 Female Reproductive Anatomy 717
EXERCISE 27-3 Meiosis 720
EXERCISE 27-4 Histology of the Reproductive System 723
Check Your Recall 731
Check Your Understanding 735

28 Human Development and Heredity 737
PRE-LAB EXERCISE 28-1 Key Terms 738
PRE-LAB EXERCISE 28-2 Fetal Membranes 739
PRE-LAB EXERCISE 28-3 Fetal Cardiovascular Anatomy 740
EXERCISE 28-1 Fertilization and Implantation 741
EXERCISE 28-2 Embryogenesis, Fetal Development, and Fetal Cardiovascular Anatomy 743
EXERCISE 28-3 Heredity 746
Check Your Recall 753
Check Your Understanding 757

29 The Big Picture of Human Anatomy and Physiology 759
EXERCISE 29-1 Physiological Connections 760
EXERCISE 29-2 Tracing—The Big Picture 763

Photo Credits 767

Index 769

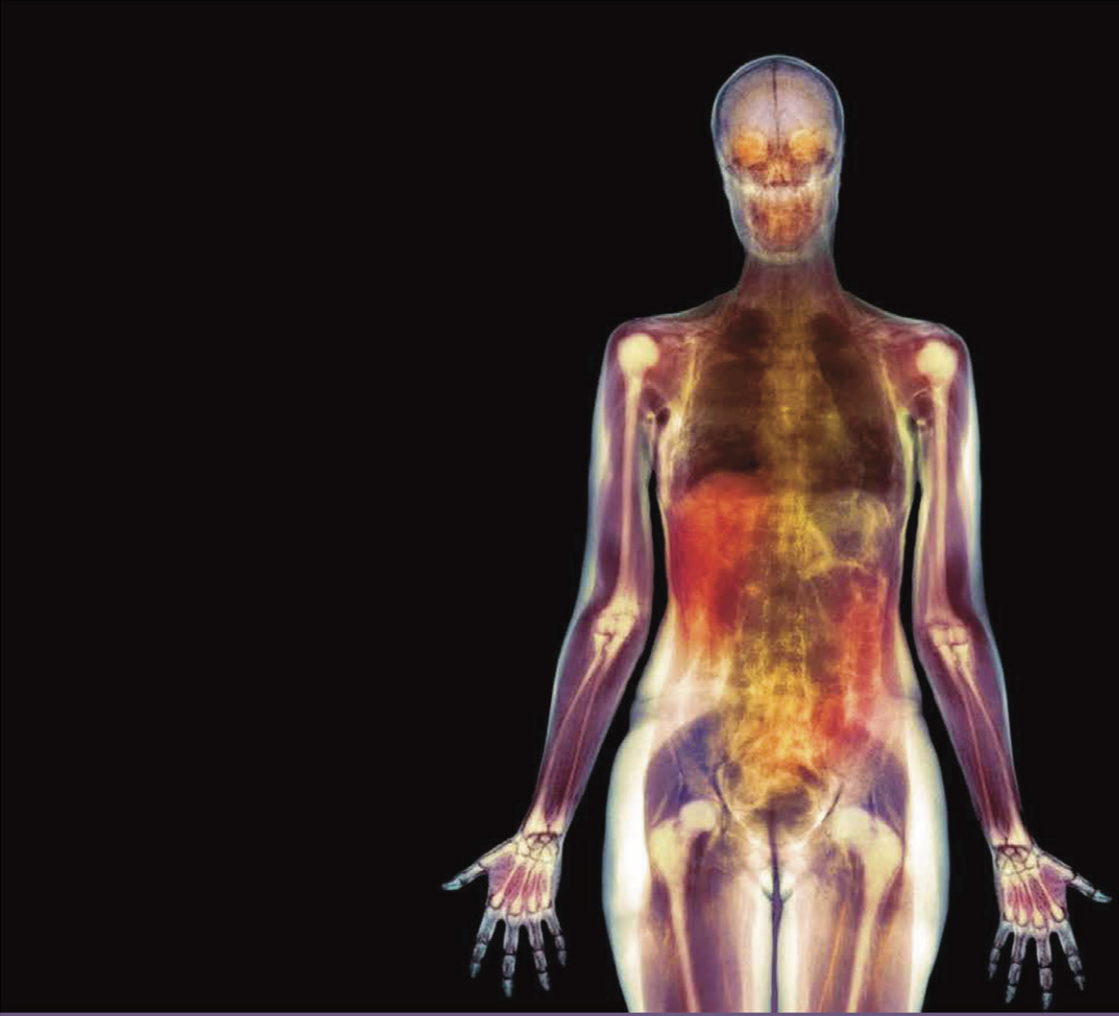

UNIT
1

Introduction to Anatomical Terms

Once you have completed this unit, you should be able to:

1. Demonstrate and describe anatomical position.
2. Apply directional terms to descriptions of body parts.
3. Use regional terms to describe locations on the body.
4. Locate and describe the divisions of the major body cavities and the membranes forming serous cavities.
5. Demonstrate and describe anatomical planes of section.
6. Identify the organ systems, their functions, and the major organs in each system.

Name _____ Section _____ Date _____

PRE-LAB EXERCISES

Complete the following exercises prior to coming to lab, using this lab manual and your textbook for reference.

Pre-Lab Exercise 1-1



Key Terms

You should be familiar with the following terms before coming to lab.

Term	Definition

Directional Terms

Anterior _____

Posterior _____

Superior _____

Inferior _____

Proximal _____

Distal _____

Superficial _____

Deep _____

Body Cavities and Membranes

Posterior body cavity _____

Anterior body cavity _____

Serous membrane (parietal and visceral layers) _____

Planes of Section

Sagittal plane _____

Frontal (coronal) plane _____

Transverse plane _____

Pre-Lab Exercise 1-2

Body Cavities

Label and color the body cavities in Figure 1.1 with the terms from Exercise 1-4 (p. 13). Use your text and Exercise 1-4 in this unit for reference.

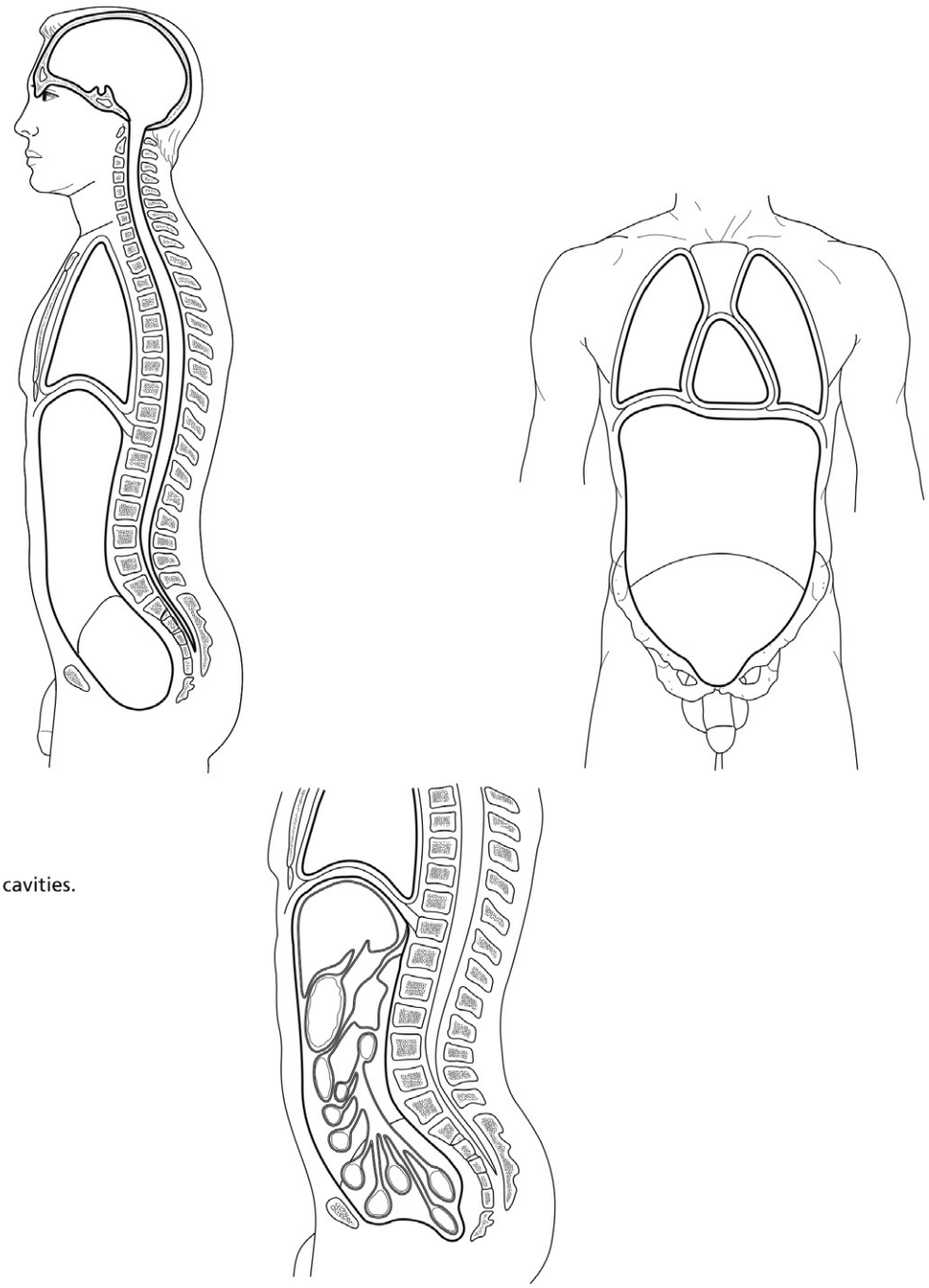

FIGURE **1.1** Body cavities.

Whole body scans using colored magnetic resonance imaging (MRI) of a man, woman, and boy (left to right) in frontal section.

EXERCISES

The bullet entered the right posterior scapular region, 3 centimeters lateral to the vertebral region, 4 centimeters inferior to the cervical region, and penetrated deep to the muscle and bone, but superficial to the lung and parietal pleura . . .

Would you believe that by the end of this unit, you will be able to translate the above sentence and also locate the hypothetical wound? Unit 1 introduces you to the world of **anatomy** and **physiology**, or A&P, which is the study and science of the structure and function of the human body. We start this unit with the language of A&P. Like learning any new language, this may seem overwhelming at first. The key to success is repetition and application: The more you use the terms, the easier it will be for them to become part of your normal vocabulary.

From terminology we move on to the organization of the internal body into spaces called **body cavities**, and how we can examine the body's cavities and organs with specific cuts known as **anatomical sections**. Finally, we look at how the body's organs are combined into functional groups called **organ systems**. When you have completed this unit, return to the opening statement, and challenge yourself to use your new knowledge of anatomical terms, body cavities, and organs to locate the precise position of the bullet wound on an anatomical model.

Exercise 1-1

Anatomical Position

In the study of the human body, most specimens are presented in a standard position called **anatomical position**. In anatomical position, shown in Figure 1.2, the body is presented facing forward, with the toes pointing forward, the feet shoulder-width apart, and the palms facing forward. This presentation of the human body creates a standard point of reference that facilitates communication among scientists and healthcare professionals.

FIGURE 1.2 Anatomical position.

Procedure 1 Demonstrating Anatomical Position

Have your lab partner stand in a normal, relaxed way, and then adjust their position so it matches anatomical position. When you have completed this exercise, answer Check Your Understanding question 1 (p. 33).

1

Exercise 1-2

Directional Terms

Another method that makes communication easier and less prone to errors is to use **directional terms** to define the location of body parts and body markings. For example, when describing a wound on the chest, we could say either of the following:

- The wound is near the middle and top of the chest
- The wound is on the right *anterior* thoracic region, 4 centimeters *lateral* to the sternum, and 3 centimeters *inferior* to the acromial region.

The second option is precise and allows the reader to exactly locate the wound. Remember that these descriptions are referring to a body in anatomical position.

Most directional terms are arranged into pairs of opposite directions. Some of the common pairs you will use in this course are illustrated in Figure 1.3 and include the following:

- **Anterior/Posterior.** The term **anterior** (an-TEER-ee-ur), also known as **ventral,** refers to the front of the body or of a body part. For example, we could say that the nose is on the anterior side of the body, or we may describe the surface of a bone that faces the front of the body as its *anterior surface*. However, we may also use the term anterior to describe a structure whose anatomical course takes it toward the front of the body, such as branches of spinal nerves called *anterior rami* (RAY-mee) that are named this way because they travel toward the anterior side of the body. The opposite term of anterior/ventral is **posterior/dorsal**. Just as with the term anterior, the term posterior

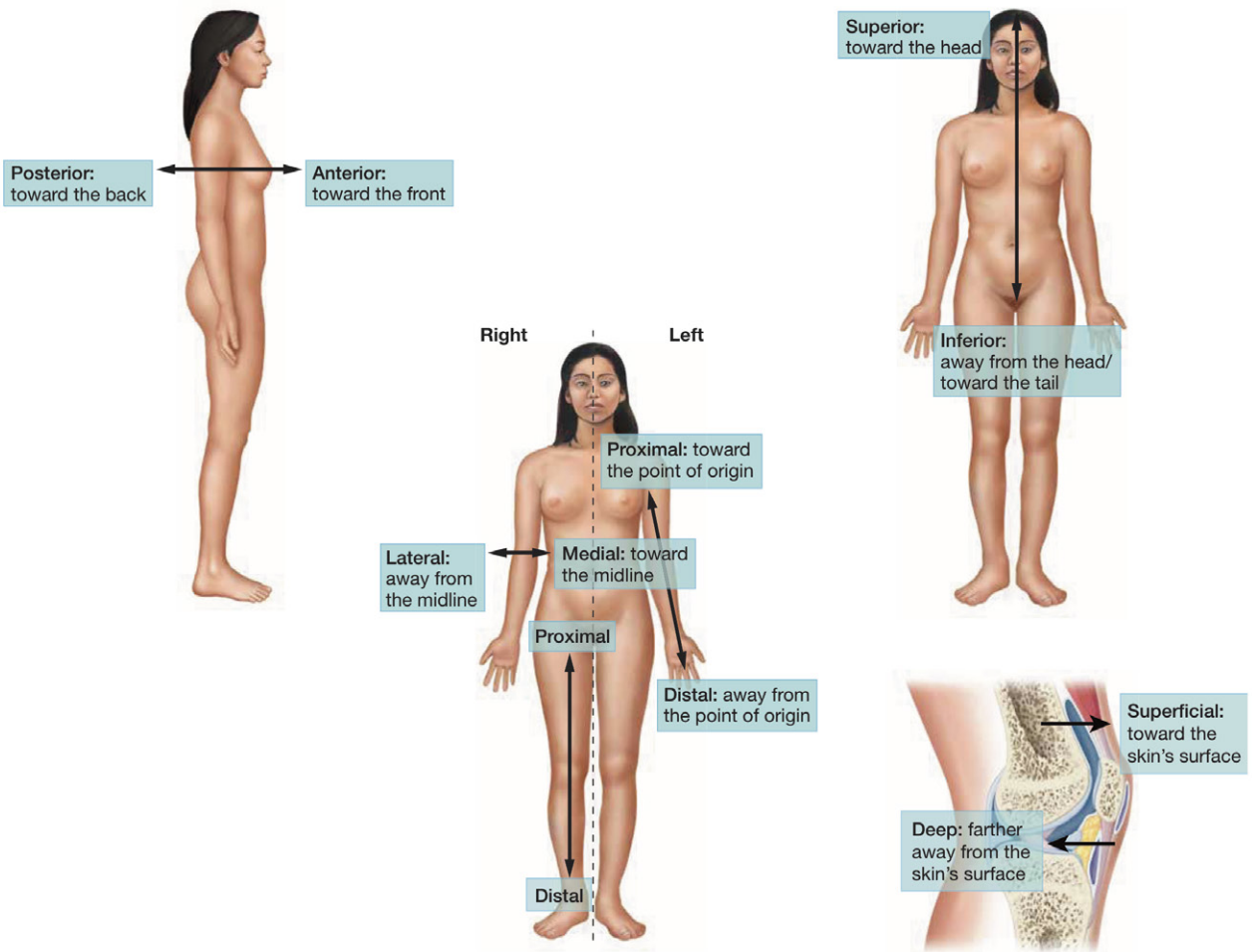

FIGURE **1.3** Directional terms.

can refer to the back side of the body or of a body part, or a structure that travels toward the back side of the body (such as the *posterior rami*).

- **Superior/Inferior.** The directional term **superior** is used to describe structures that are toward or closer to the head. The opposite term of superior is **inferior**, which means away from the head or toward the tail. Both superior and inferior may be used to describe a structure's absolute position in the body or the position of a structure relative to another structure. For example:
  - The two largest veins in the body are the *superior vena cava* and the *inferior vena cava*. The superior vena cava is the vessel located nearer the head, and the inferior vena cava is the one located farther away from the head (or closer to the tail).
  - We can describe the head as being *superior* to the neck, and we can say that the abdomen is *inferior* to the chest.
  - A very important rule to remember with superior and inferior is that these terms are used to describe structures only on the head, neck, and trunk, which are located in the part of the body known as the *axial region*. With very few exceptions, we do not use superior and inferior on the upper and lower limbs.
- **Proximal/Distal.** The upper and lower limbs are the part of the body known as the *appendicular region*. We use the terms proximal and distal on the appendicular region instead of using superior and inferior. The directional term **proximal** (PRAWKS-ih-muhl) refers to the closeness—or *proximity*—of a structure to its point of origin, which is the shoulder for the upper limb and the hip for the lower limb. You know this from the everyday term *approximate*, which refers to closeness. The opposite term, **distal**, refers to the farness—or *distance*—of a structure from the shoulder or hip. As with superior and inferior, the terms can describe a structure's absolute position, or the position of a structure relative to another structure. Here are a couple of examples:
  - The part of the femur (thigh bone) that is closest to the hip is called the *proximal* end of the bone. The end of the femur that is farthest away from the hip is its *distal* end.
  - We can describe the knee as being *proximal* to the ankle, because it is closer to the hip than is the ankle. Similarly, the fingers are *distal* to the wrist because they are farther away from the shoulder than is the wrist.

HINTS & TIPS

Sorting Out Superior and Inferior versus Proximal and Distal

One of the most common problems students have with respect to directional terms is how to use the terms superior/inferior and proximal/distal. Superior and inferior are easy enough on the head, neck, and trunk, but many students forget the rules and want to use them on the upper and lower limbs. So to start, here's a mnemonic to help: "Use your **superior mind** to remember when to use **superior** and **inferior**." This will help remind you to use these terms only on the head, neck, and trunk, as these are the locations in the body that house structures associated with your "mind" (the brain and spinal cord).

Now let's think about proximal and distal for a minute. To start, why even have different terms on the upper and lower limbs? Well, stand with your hands by your side. If we were to use superior and inferior, we would say that your hand is inferior to your shoulder. But lift your arm in the air above your head—where is your hand now? It's superior to your shoulder, right? This is the problem with limbs: they can change position. Ideally, every specimen we describe is in anatomical position, but we can't guarantee that every patient we treat or body we find will be in anatomical position. So for the upper and lower limbs, we need a different set of terms.

Once you understand the "why" of proximal and distal, all that's left is to understand how to apply them. That part is easy, because both are words that you already know, even if you don't immediately recognize them. The word root for "proximal" is *proxim-*, which means "near." You use words with this word root all of the time, such as "proximity" and "approximate." The word root for "distal" is *dist-*, which means "far." This is another very common word root—you use it in words like "distant," "distinct," "distance," and "distend."

Knowing the meanings of the word roots for the terms proximal and distal makes it very simple to come up with mnemonics for their use. Here are a couple of easy ones:

- The more **proximal** structure is the one in the closest **proximity** to the hip (or shoulder).
- The more **distal** structure is the one that is the most **distant** from the hip (or shoulder).

However, don't forget that these terms are only used on the upper and lower limbs, with very few exceptions. Just as you can't use superior and inferior on the upper and lower limbs, you also can't use proximal and distal on the head, neck, and trunk.

- **Medial/Lateral.** The terms medial and lateral reference an imaginary line running down the middle of the body called the *midline*. A structure is described as **medial** when its position is closer to this midline, and its position becomes more **lateral** as it moves farther away from the midline. Again, we can use these terms to describe a structure's absolute location or its location relative to another structure. For example:
  - The ulna, or the inner forearm bone, is the *medial* bone of the forearm because it is closest to the midline of the body. The radius, or the outer forearm bone, is the *lateral* bone of the forearm because it is farthest away from the midline of the body.
  - We can describe the ears as being *lateral* to the eyes because the ears are farther away from the midline than are the eyes. Conversely, we could say that the eyes are *medial* to the ears for the same reason.
- **Superficial/Deep.** The final pair of directional terms we use is one with which you are probably already familiar just from your everyday language: superficial and deep. As you might expect, the term **superficial** refers to a position that is closer to the surface of the body or closer to the skin. Structures that are **deep** are farther away from the skin's surface.

Review the definitions of the directional terms that you just read and that are illustrated in Figure 1.3. When you think you understand how to use them, fill in the correct directional terms in the following practice procedure.

Procedure 1 Directional Terms

Fill in the correct directional term for each of the following items. Note that in some cases, more than one directional term may apply.

The elbow is _____ to the wrist.

The chin is _____ to the nose.

The shoulder is _____ to the clavicle (collarbone).

The forehead is _____ to the mouth.

The skin is _____ to the muscle.

The esophagus is _____ to the sternum (breastbone).

The nose is _____ to the cheek.

The spine is on the _____ side of the body.

The arm is _____ to the torso.

The knee is _____ to the hip.

Exercise 1-3

Regional Terms

MATERIALS

- ❑ Laminated outline of the human body
- ❑ Water-soluble marking pens

You may have noticed in the example of Exercise 1-2 that we said *thoracic region* and *acromial region* instead of using generic words such as "chest" and "shoulder." These more specific words are known as **regional terms,** and their use is another standard practice to make descriptions as specific as possible and to reduce the potential for errors in communication. Think about it—the "shoulder" could consist of quite a large area, whereas the "acromial region" refers to one specific location.

The following regional terms, illustrated in Figure 1.4 and defined in Table 1.1, are among the more common terms you will encounter in your study of anatomy and physiology. Note that most of these terms are adjectives rather than nouns. This means that the term is not complete unless it is paired with the term "region." For example, we cannot say, "The wound is in the antebrachial." We instead must say, "The wound is in the antebrachial *region*."

The following list may look daunting, but you are probably familiar with several of the terms already. For example, you likely know the locations of the "oral," "nasal," and "abdominal" regions. Watch for other terms that you may know.

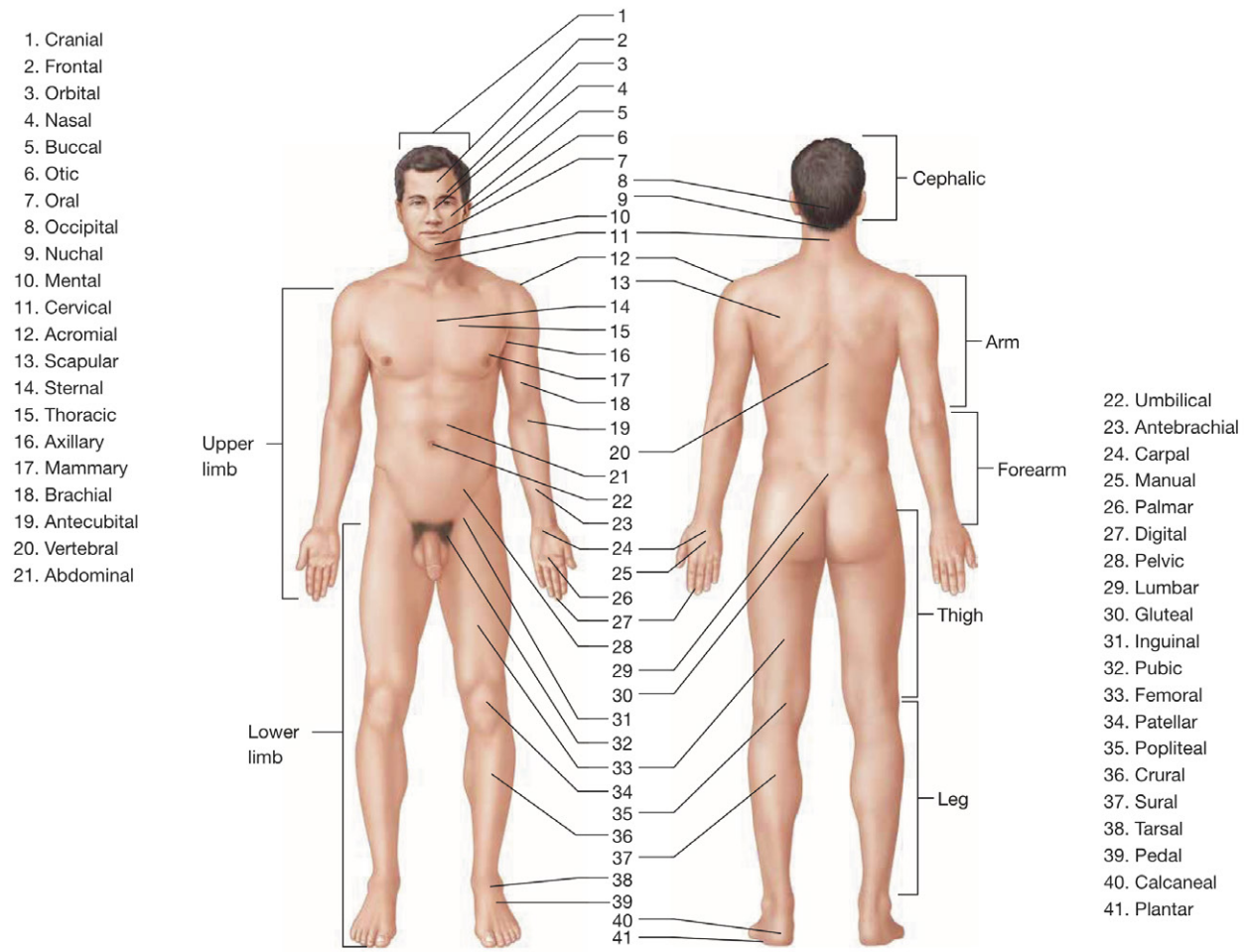

FIGURE **1.4** Regional terms.

TABLE 1.1 Regional Terms

Term	Definition
Adjectives	
Abdominal region	The area over the abdomen that is inferior to the diaphragm and superior to the bony pelvis
Acromial region	The area over the lateral part of the shoulder that contains the acromion of the scapula
Antebrachial region	The forearm
Antecubital region	The anterior upper limb between the forearm and arm, over the elbow joint
Axillary region	The area in and around the axilla (armpit)
Brachial region	The anterior and posterior arm (between the elbow and the shoulder)
Buccal region	The lateral portions of the face corresponding to the cheeks
Calcaneal region	The heel of the foot
Carpal region	The wrist
Cephalic region	The entire head from the chin to the top of the head
Cervical region	The neck
Cranial region	The top of the head, or the portion of the skull that encases the brain
Crural region	The anterior leg, or the shin
Digital region	The fingers or the toes
Femoral region	The thigh
Frontal region	The forehead
Gluteal region	The buttock
Inguinal region	The area along the inguinal ligament that divides the pelvis from the thigh
Lumbar region	The lower back
Mammary region	The area around the breast
Manual region	The general area of the hand
Mental region	The chin
Nasal region	The nose
Nuchal region	The ridge that runs along the back of the skull within the occipital region
Occipital region	The general area of the back of the skull
Oral region	The mouth
Orbital region	The area around the eye
Otic region	The area around the ear
Palmar region	The anterior hand (the palm of the hand)
Patellar region	The anterior part of the knee over the patella (kneecap)

(continues)

TABLE **1.1** Regional Terms *(cont.)*

Term	Definition
Adjectives	
Pedal region	The foot
Pelvic region	The anterior pelvis
Plantar region	The bottom of the foot
Popliteal region	The posterior side of the knee joint
Pubic region	The area over the pubic bone
Scapular region	The area over the scapula in the superior back
Sternal region	The area in the middle of the chest over the sternum
Sural region	The posterior part of the leg (the calf)
Tarsal region	The ankle region
Thoracic region	The general chest area
Umbilical region	The area around the umbilicus (belly button)
Vertebral region	The area over the vertebral column (spine)
Nouns	
Arm	The portion of the upper limb from the elbow to the shoulder
Forearm	The portion of the upper limb from the elbow to the wrist
Leg	The portion of the lower limb from the knee to the ankle
Lower limb	The entire portion of the body from the hip to the digits of the foot
Thigh	The portion of the lower limb from the hip to the knee
Upper limb	The entire portion of the body from the shoulder to the digits of the hand

1

Procedure 1 Labeling Body Regions

Use water-soluble markers to locate and label each of the following regions on laminated outlines of the human body. If outlines are unavailable, label the regions on Figure 1.5.

Adjectives

- ❑ Abdominal (ab-DAH-mih-nuhl)
- ❑ Acromial (ah-KROH-mee-uhl)
- ❑ Antebrachial (an-tee-BRAY-kee-uhl)
- ❑ Antecubital (an-tee-KYOO-bih-tuhl)
- ❑ Axillary (AX-il-ehr-ee)
- ❑ Brachial (BRAY-kee-uhl)
- ❑ Buccal (BYOO-kuhl)
- ❑ Calcaneal (kal-KAY-nee-uhl)
- ❑ Carpal (KAR-puhl)
- ❑ Cephalic (sef-AL-ik)
- ❑ Cervical (SIR-vih-kuhl)
- ❑ Cranial (KRAY-nee-uhl)
- ❑ Crural (KROO-ruhl)
- ❑ Digital (DIJ-it-uhl)
- ❑ Femoral (FEM-oh-ruhl)
- ❑ Frontal (FRUHN-tul)
- ❑ Gluteal (GLOO-tee-uhl)
- ❑ Inguinal (IN-gwin-uhl)
- ❑ Lumbar (LUHM-bahr)
- ❑ Mammary (MAM-uh-ree)
- ❑ Manual (MAN-yoo-uhl)
- ❑ Mental (MEN-tuhl)
- ❑ Nasal (NAY-zuhl)
- ❑ Nuchal (NOO-kuhl)
- ❑ Occipital (awk-SIP-ih-tuhl)
- ❑ Oral (OH-ruhl)
- ❑ Orbital (OHR-bit-uhl)
- ❑ Otic (OH-tik)
- ❑ Palmar (PAHL-mur)
- ❑ Patellar (puh-TEL-ur)
- ❑ Pedal (PEE-duhl)
- ❑ Pelvic (PEL-vik)
- ❑ Plantar (PLAN-tahr)
- ❑ Popliteal (pahp-lih-TEE-uhl)
- ❑ Pubic (PYOO-bik)
- ❑ Scapular (SKAP-yoo-lur)
- ❑ Sternal (STUR-nuhl)
- ❑ Sural (SOO-ruhl)
- ❑ Tarsal (TAR-suhl)
- ❑ Thoracic (thoh-RAH-sik)
- ❑ Umbilical (um-BIL-ih-kuhl)
- ❑ Vertebral (vur-TEE-bruhl)

Nouns

- ❑ Arm
- ❑ Forearm
- ❑ Leg
- ❑ Lower limb
- ❑ Thigh
- ❑ Upper limb

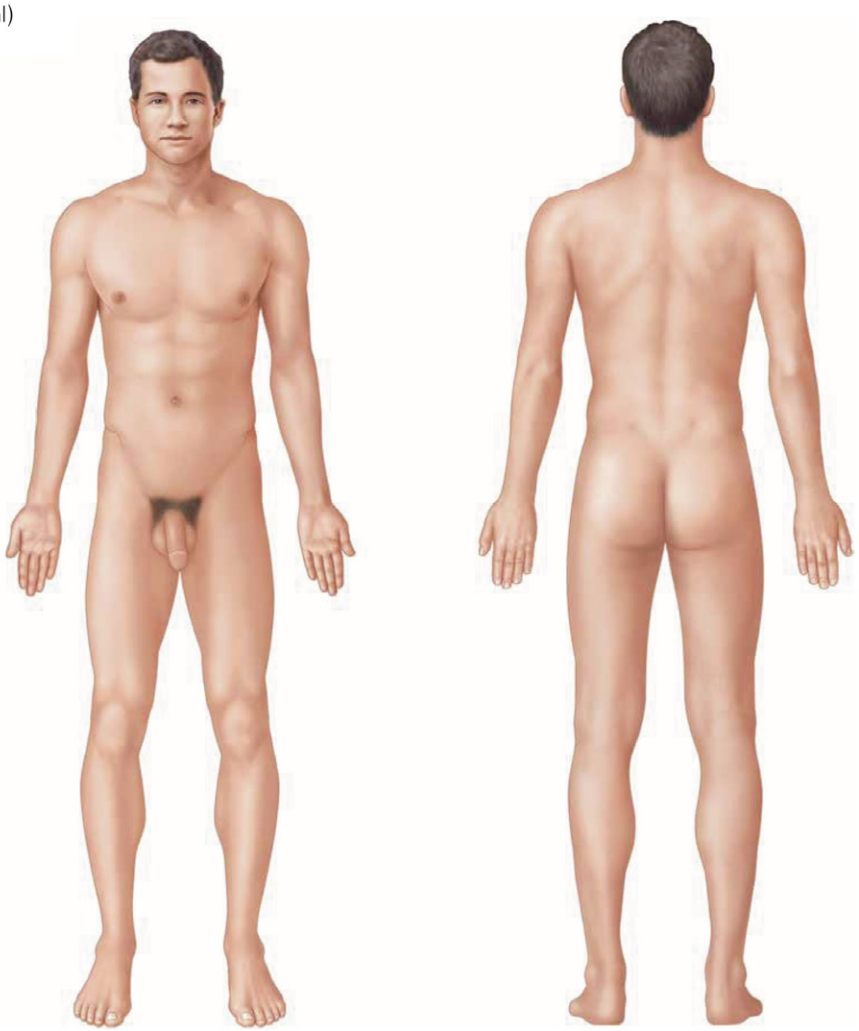

FIGURE **1.5** Anterior and posterior views of the human body in anatomical position.

Exercise 1-4

Body Cavities and Membranes

MATERIALS

- ❑ Human torso models
- ❑ Fetal pigs (or other preserved small mammals)
- ❑ Dissection kits/dissection trays

The body is divided into several cavities, many of which are fluid-filled and each of which contains specific organs. In this exercise you will identify the body cavities and the organs contained within each cavity.

Several of the fluid-filled body cavities are formed by thin sheets of tissue called **serous membranes** (SEER-us). Cells of these membranes produce a thin, watery fluid called **serous fluid** that lubricates organs so they move within the cavity with little friction. Serous membranes are composed of two layers: an outer **parietal layer** (puh-RY-ih-tuhl) that is attached to the body wall and surrounding structures, and an inner **visceral layer** (VISS-er-uhl) that is attached to specific organs. Between the parietal and visceral layers is a thin potential space that contains serous fluid. This potential space is referred to as a cavity.

As you can see in Figure 1.6, there are two major body cavities, each of which is subdivided into smaller cavities, as follows:

1. **Posterior (dorsal) body cavity.** As implied by its name, the **posterior body cavity** is largely on the posterior side of the body (Fig. 1.6A). It is divided into two smaller cavities:
   a. **Cranial cavity.** The **cranial cavity** is the area encased by the skull. It contains the brain and a fluid called *cerebrospinal fluid*.
   b. **Vertebral** (or **spinal**) **cavity.** The **vertebral cavity** is the area encased by the vertebrae. It contains the spinal cord and is also filled with cerebrospinal fluid.

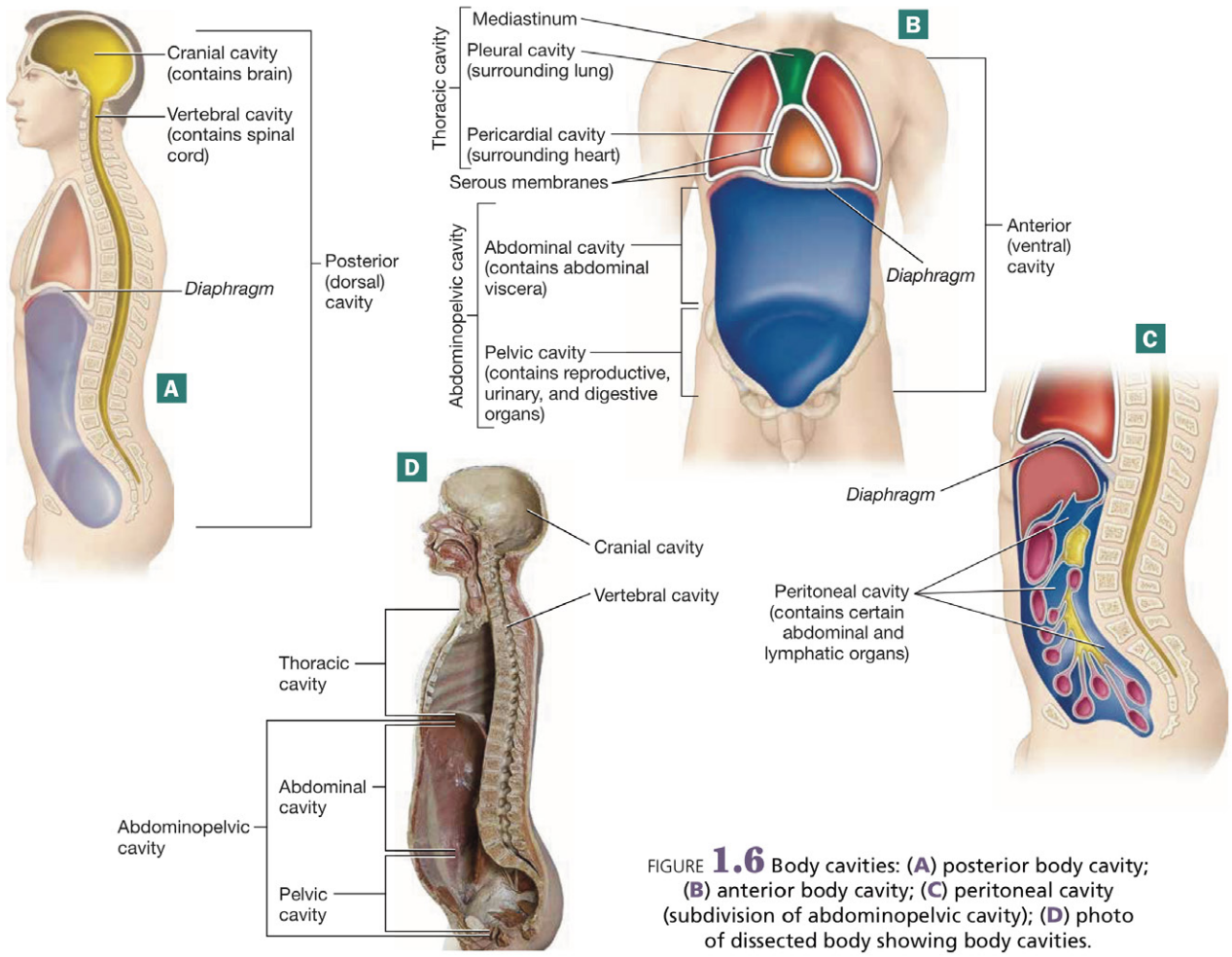

FIGURE **1.6** Body cavities: (**A**) posterior body cavity; (**B**) anterior body cavity; (**C**) peritoneal cavity (subdivision of abdominopelvic cavity); (**D**) photo of dissected body showing body cavities.

2. **Anterior (ventral) body cavity.** The **anterior body cavity** is largely on the anterior side of the body (Fig. 1.6B). It has two main divisions: the *thoracic* and *abdominopelvic cavities*, each of which is divided into smaller subcavities.
   a. **Thoracic cavity.** The **thoracic cavity** (thoh-RAS-ik) is located superior to a muscle called the diaphragm and encompasses the area encased by the ribs. We find the following smaller cavities within the thoracic cavity:
      (1) **Pleural cavities.** Each **pleural cavity** (PLOO-ruhl) surrounds one of the lungs. The pleural cavities are located between two layers of a serous membrane called the **pleural membrane.** The **parietal pleurae** are attached to the body wall and the surface of the diaphragm, and the **visceral pleurae** are attached to the surface of the lungs. Between the two layers we find a thin layer of serous fluid.
      (2) **Mediastinum.** The cavity between the pleural cavities, called the **mediastinum** (mee-dee-uh-STY-num), contains the great vessels, the esophagus, the trachea and bronchi, and other structures. It houses another cavity formed by a serous membrane called the **pericardial membrane** (pehr-ee-KAR-dee-uhl). The **parietal pericardium** is attached to surrounding structures, and the inner **visceral pericardium** is attached to the heart muscle. Between the two layers we find the **pericardial cavity**, which is filled with a thin layer of serous fluid.
   b. **Abdominopelvic cavity.** The **abdominopelvic cavity** (ab-dom-ih-noh-PEL-vik) is located inferior to the diaphragm and extends into the bony pelvis. There are three subcavities within the abdominopelvic cavity:
      (1) **Abdominal cavity.** The area superior to the bony pelvis, called the **abdominal cavity**, houses many organs including the liver, gallbladder, small intestine, stomach, pancreas, kidneys, adrenal glands, spleen, and much of the colon (large intestine).
      (2) **Pelvic cavity.** The cavity housed within the bony pelvis, the **pelvic cavity**, contains certain sex organs, the urinary bladder, the rectum, and part of the colon.
      (3) **Peritoneal cavity.** The third subcavity of the abdominopelvic cavity, shown in Figure 1.6C, is formed by a serous membrane called the **peritoneal membrane** (pehr-ih-toh-NEE-uhl). The outer **parietal peritoneum** is attached to the body wall and surrounding structures, and the inner **visceral peritoneum** is attached to the surface of many of the abdominal and pelvic organs. Between these two layers of peritoneal membrane we find the **peritoneal cavity**, which is filled with serous fluid. Organs that are within the peritoneal cavity are **intraperitoneal** (in-trah-pehr-ih-toh-NEE-uhl), and include the liver, most of the small intestine, much of the colon, the stomach, the spleen, and part of the pancreas. Those organs that are posterior to the peritoneal cavity are said to be **retroperitoneal** (reh-troh-pehr-ih-toh-NEE-uhl), and include the kidneys, adrenal glands, the sex organs, the urinary bladder, part of the colon, and part of the pancreas.

We often divide the abdominopelvic cavity into four surface quadrants: the right upper, right lower, left upper, and left lower quadrants, as shown in Figure 1.7. Take note in the figure of which organs are located in each quadrant, as you will be identifying them in an upcoming procedure. Be aware, though, that certain structures are deep to the labeled organs and so aren't visible in the figure. These deeper organs are listed to the side of each quadrant.

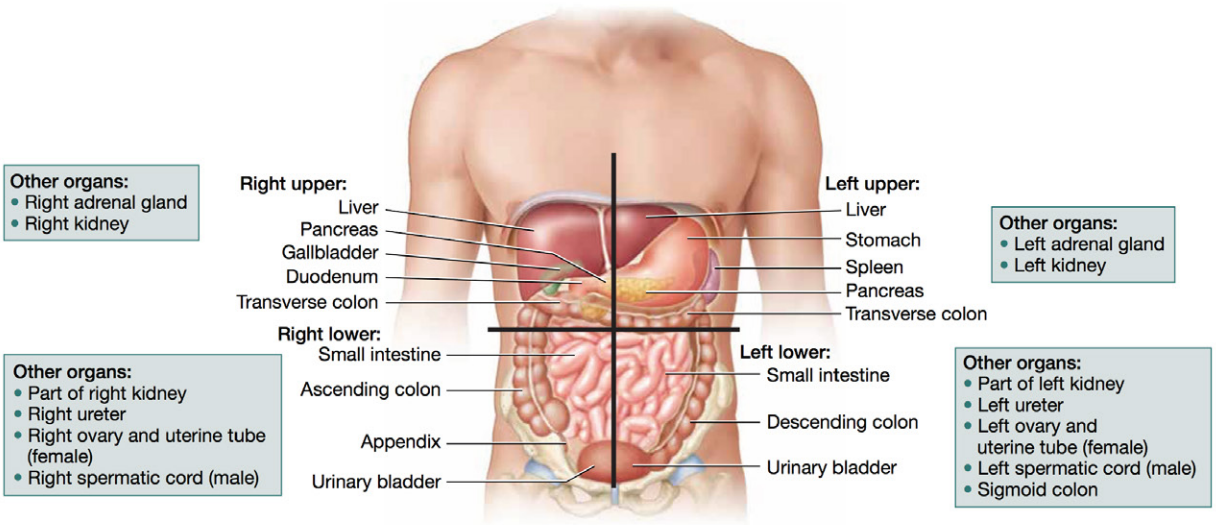

FIGURE **1.7** Quadrants of the abdominopelvic cavity.

Procedure 1 Body Cavities

In this procedure you will use a human torso model or a preserved small mammal such as a fetal pig to examine the body cavities. If you are using a preserved small mammal, you may use the following procedure to open the animal. *Note that you will not open the animal fully in this procedure to preserve structures for future dissections.*

Safety Note

Safety glasses and gloves are required!

1. Place the animal in the dissecting tray with its ventral (abdominal) side facing you. Use a scalpel to make shallow incisions, following the guide in Figure 1.8.
2. Using a blunt dissection probe, peel back the skin of the abdomen carefully to expose the abdominopelvic cavity, and examine its contents.
3. Gently peel back the skin of the chest and neck incisions. Use scissors or a scalpel to carefully cut through the sternum, expose the thoracic cavity, and examine its contents.

When you have opened the anterior body cavity of your preserved small mammal or human torso model, locate and identify each cavity, and do the following:

4. Identify the organs of the thoracic, abdominal, and pelvic cavities, and list these organs in Table 1.2. See Figures 1.9 (p. 17) and 1.10 (p. 18) for reference.
5. Mark each quadrant of the abdominopelvic cavity with a pin or marking tape (if working with a torso model). Note which organs are located in each quadrant.

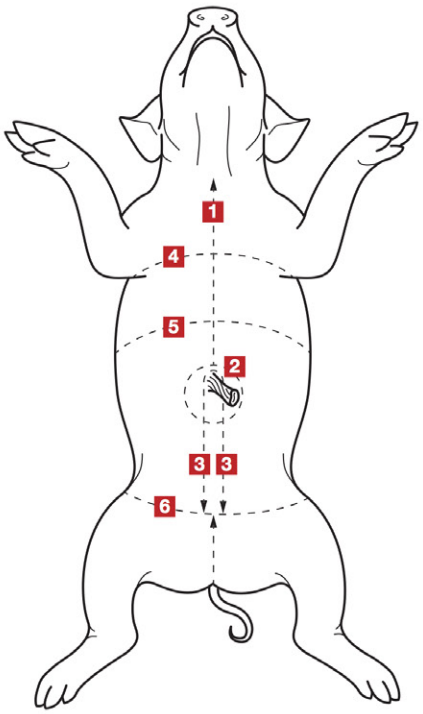

FIGURE **1.8** Incisions for a fetal pig dissection.

1

TABLE **1.2** Divisions of the Anterior Body Cavity and Quadrants of the Abdominopelvic Cavity

Cavity	Organ(s)
1. Thoracic cavity	
a. Pleural cavities	
b. Mediastinum	
(1) Pericardial cavity	
2. Abdominopelvic cavity	
a. Subdivisions	
(1) Abdominal cavity	
(2) Pelvic cavity	
(3) Peritoneal cavity	
b. Regions	
(1) Right upper quadrant	
(2) Right lower quadrant	
(3) Left upper quadrant	
(4) Left lower quadrant	

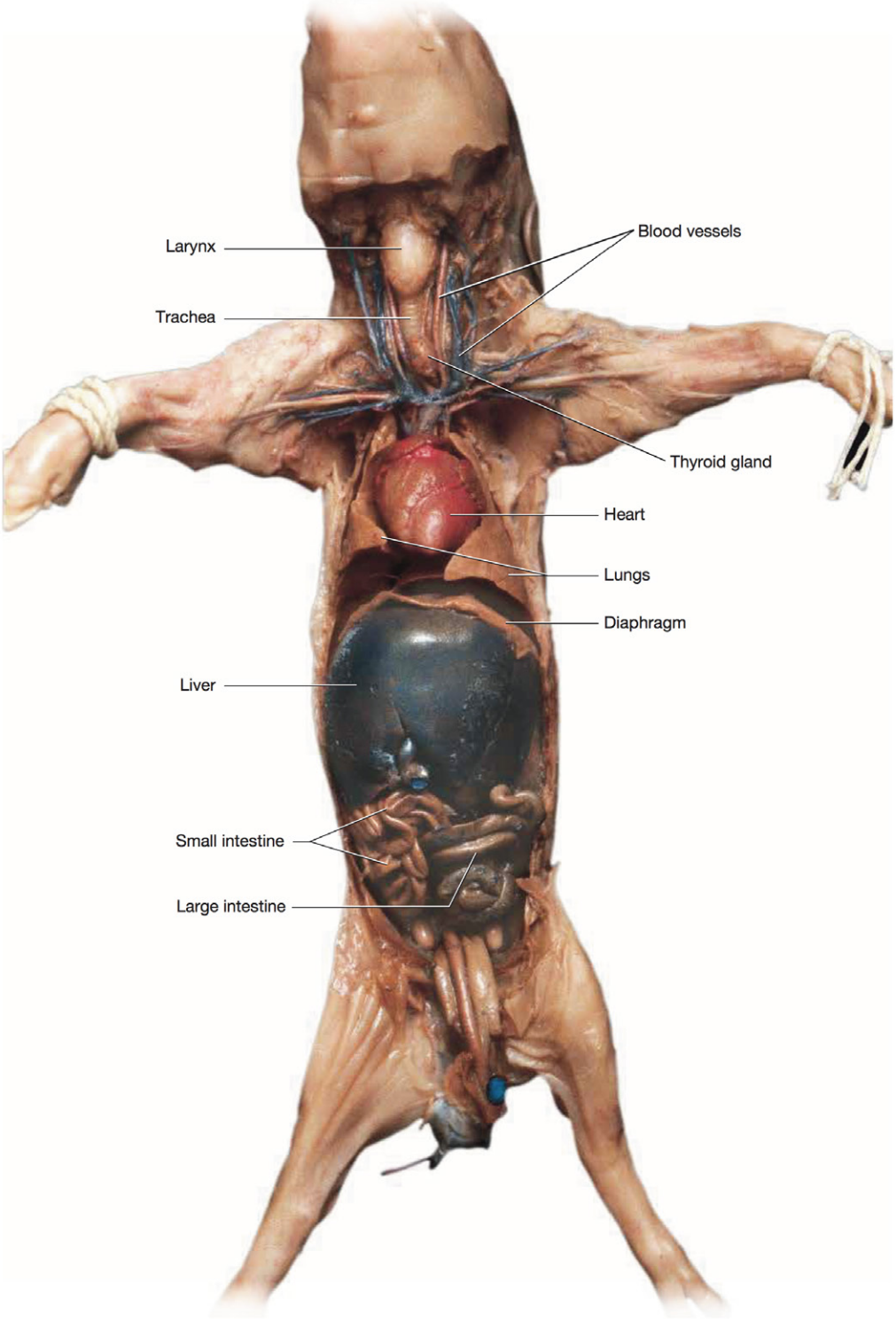

FIGURE **1.9** Ventral view of the fetal pig.

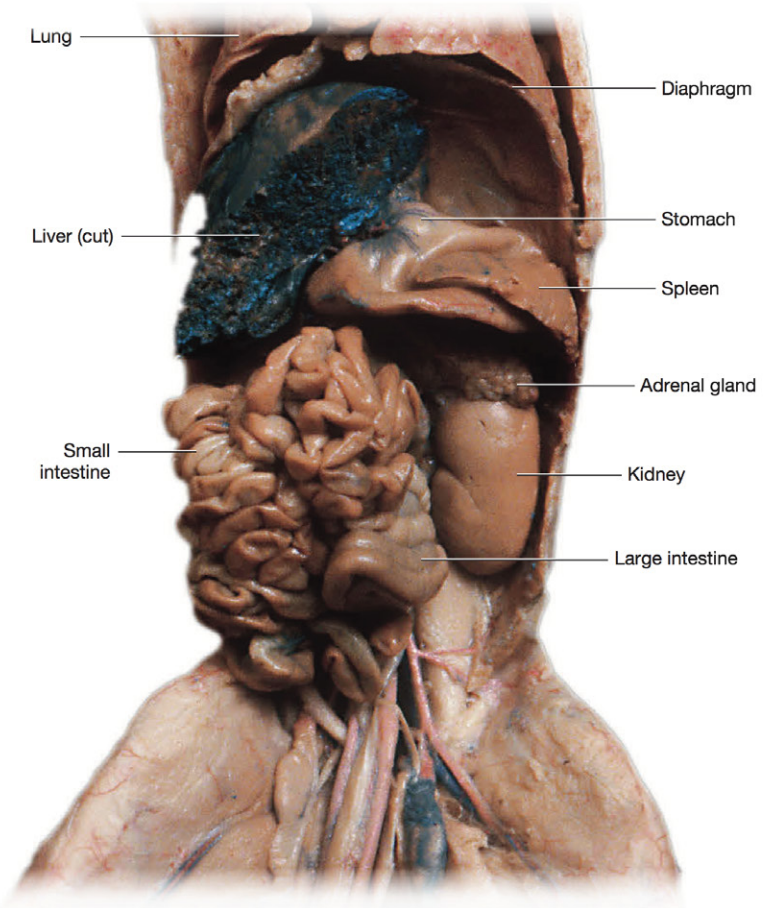

FIGURE **1.10** Abdominopelvic cavity of the fetal pig.

Procedure 2 Serous Membranes

Part A

Serous membranes are best examined on a preserved specimen such as a fetal pig, because their structure is difficult to appreciate on a model. As you dissect the preserved mammal, look for the serous membranes listed in Table 1.3. Take care not to tear the fragile membranes, which consist of just a few layers of cells. As you identify each membrane, name the structure to which the membrane is attached (the lungs, heart, abdominal wall, etc.).

TABLE **1.3** Serous Membranes

Membrane	Cavity	Structure
Parietal pleura		
Visceral pleura		
Parietal pericardium		
Visceral pericardium		
Parietal peritoneum		
Visceral peritoneum		

Part B

Draw in the body cavities on your laminated outlines of the human body or Figure 1.11. Label each body cavity and the serous membranes surrounding the cavity where applicable.

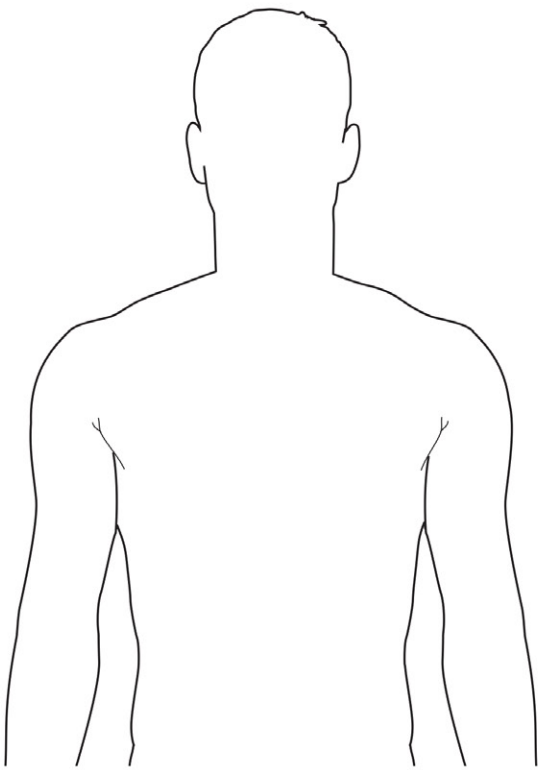

FIGURE **1.11** Anterior view of the human torso.

Procedure 3 Applications of Terms: Cavities and Membranes

Remember this from the unit opener?

> *The bullet entered the right posterior scapular region, 3 centimeters lateral to the vertebral region, 4 centimeters inferior to the cervical region, and penetrated deep to the muscle and bone, but superficial to the parietal pleura.*

Now it's your turn to combine the different anatomical terms you have learned to describe a "bullet wound." Assume that you are acting as coroner, and you have a victim with three gunshot wounds. In this scenario your victim will be your fetal pig or a human torso model that your instructor has "shot." For each "bullet wound," describe the location of the wound using at least three directional terms and as many regional terms as possible, following this example. As coroner, you have to be as specific as possible, and don't forget to keep your patient in anatomical position. When you have completed the activity, answer Check Your Understanding questions 2 through 5 (pp. 33–35).

Shot 1	
Shot 2	
Shot 3	

Exercise 1-5

Planes of Section

MATERIALS

- ❑ Modeling clay
- ❑ Knife or scalpel
- ❑ Various anatomical models demonstrating planes of section

Often in anatomy and physiology, we need to obtain different views of the internal structure of an organ or a body cavity. These views are obtained by making an **anatomical section** along a specific plane. The commonly used planes of section, shown in Figures 1.12 and 1.13, are as follows:

1. **Sagittal plane.** A section along the **sagittal plane** (SAJ-ih-tuhl) divides the specimen into right and left parts. The sagittal section has two variations:
   a. **Midsagittal sections** divide the specimen into equal right and left halves.
   b. **Parasagittal sections** divide the specimen into unequal right and left parts.
2. **Frontal plane.** The **frontal plane,** also known as the **coronal plane** (koh-ROH-nuhl), divides the specimen into an anterior (front) part and a posterior (back) part.
3. **Transverse plane.** The **transverse plane,** also known as a **cross section** or the **horizontal plane,** divides the specimen into a superior (or proximal) part and an inferior (or distal) part.

Note that although there is only a single midsagittal plane, there are a near infinite number of possible parasagittal, frontal, and transverse planes. In your study of anatomy and physiology, you will see many different examples of these planes of section.

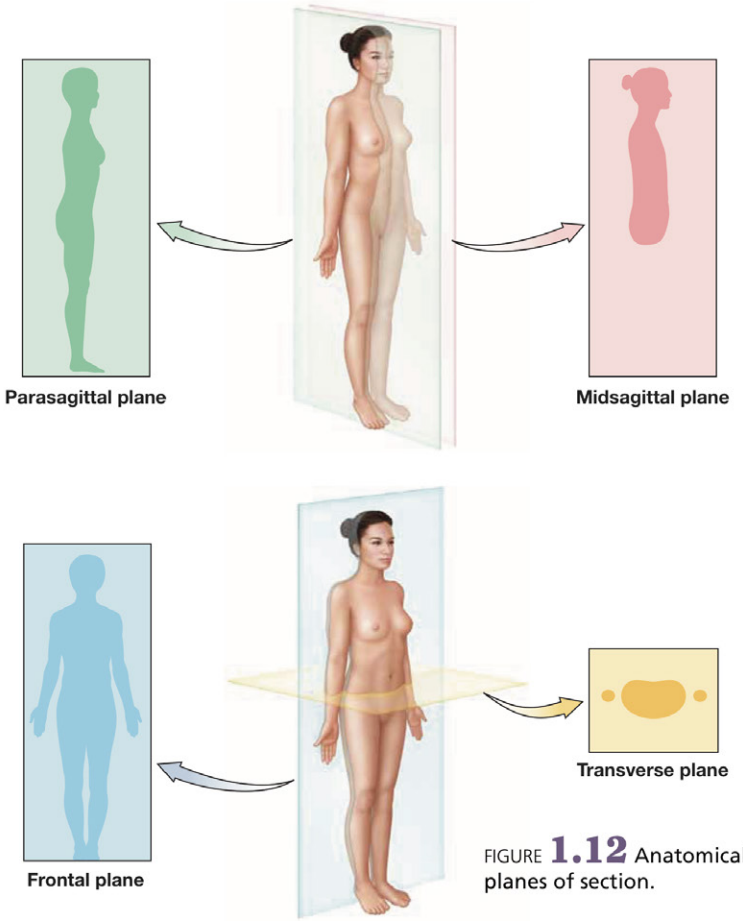

FIGURE **1.12** Anatomical planes of section.

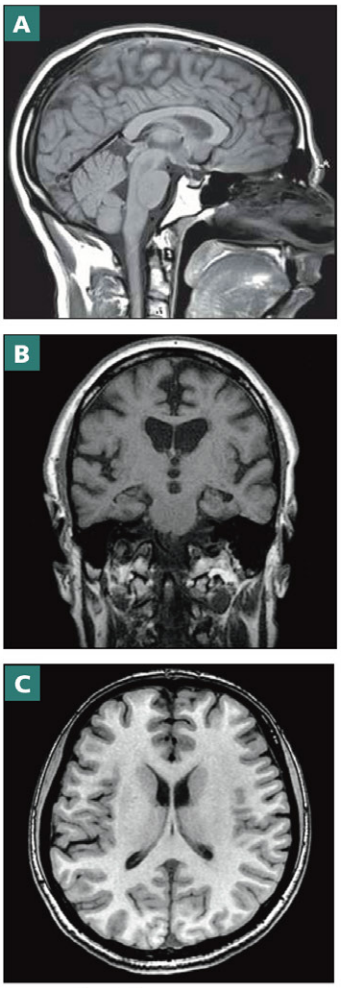

FIGURE **1.13** Planes of anatomical section visible on computed tomography scans of the brain: (**A**) midsagittal section; (**B**) frontal section; (**C**) transverse section.

Procedure 1 Sectioning Along Anatomical Planes

Use a scalpel to cut a ball of modeling clay in each of following anatomical planes. Before you make your cuts, mold your clay into the shape of a head and draw eyes on the head to denote anterior and posterior sides. When you have finished making your model, draw a model in the space provided and draw each of the planes of section. Use Figures 1.12 and 1.13 for reference.

1. Sagittal
   a. Midsagittal
   b. Parasagittal
2. Frontal
3. Transverse

Procedure 2 Identifying Examples of Anatomical Planes of Section

Identify at least two examples of each plane of section listed in Table 1.4 on anatomical models that your instructor provides. In addition, list the organs that are visible in the section. When you have completed this exercise, answer Check Your Understanding questions 6 and 7 (p. 36).

TABLE **1.4** Anatomical Models and Planes of Section

Model Name or Description	Organ(s) Visible
Examples of Midsagittal and/or Parasagittal Sections	
1.	
2.	
Examples of Frontal Sections	
1.	
2.	
Examples of Transverse Sections	
1.	
2.	

1

Exercise 1-6

Organs and Organ Systems

MATERIALS

- ❑ Human torso models
- ❑ Fetal pigs (or other preserved small mammals)

The organs that you have identified in this lab are organized into functional groups called **organ systems**. The human body has 11 organ systems, each with specific organs and functions (Fig. 1.14). In this exercise you will examine the organ systems and identify their major organs.

Procedure 1 Identifying Organs

Identify the following organs on your preserved mammal specimen or human torso models. Check off each organ as you identify it, and record the organ system to which it belongs in Table 1.5, using Figure 1.14 for reference. Remember that some organs may function in more than one system.

- ❑ Adrenal glands
- ❑ Blood vessels
- ❑ Bones
- ❑ Brain
- ❑ Esophagus
- ❑ Gallbladder
- ❑ Heart
- ❑ Joints
- ❑ Kidneys
- ❑ Large intestine
- ❑ Larynx
- ❑ Liver
- ❑ Lungs
- ❑ Lymph nodes
- ❑ Pancreas
- ❑ Skeletal muscles
- ❑ Skin
- ❑ Small intestine
- ❑ Spinal cord
- ❑ Spleen
- ❑ Stomach
- ❑ Testes (male) or ovaries (female)
- ❑ Thymus
- ❑ Thyroid gland
- ❑ Trachea
- ❑ Urinary bladder
- ❑ Uterus

TABLE 1.5 Organs and Organ Systems

Organ System	Major Organ(s)
Integumentary system	
Skeletal system	
Muscular system	
Nervous system	
Endocrine system	
Cardiovascular system	
Lymphatic system	
Respiratory system	
Digestive system	
Urinary system	
Reproductive system	

1

Procedure 2 Researching Organ Systems

The body's organ systems are illustrated in Figure 1.14. Fill in the blanks next to each organ system to identify the major organs shown. Then, use your textbook or other resources to research the principal functions of each system.

Integumentary System

Main Organs:

Main Functions:

Skeletal System

Main Organs:

Main Functions:

Muscular System

Main Organs:

Main Functions:

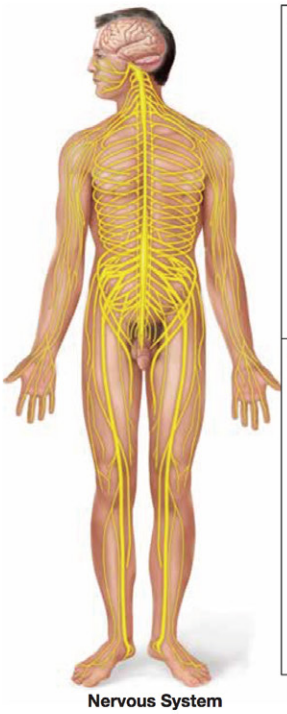

Nervous System

Main Organs:

Main Functions:

FIGURE **1.14** Organ systems of the body *(continues)*

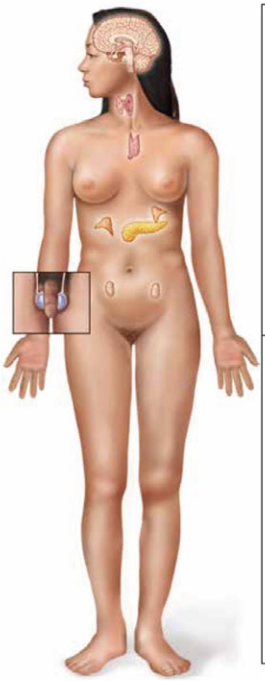

Endocrine System

Main Organs:

Main Functions:

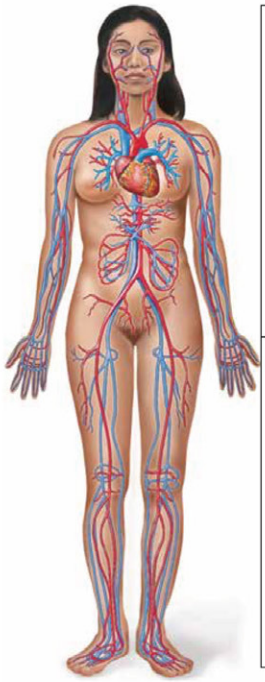

Cardiovascular System

Main Organs:

Main Functions:

Lymphatic System

Main Organs:

Main Functions:

Respiratory System

Main Organs:

Main Functions:

FIGURE **1.14** *(cont.)* **Organ systems of the body** *(continues)*

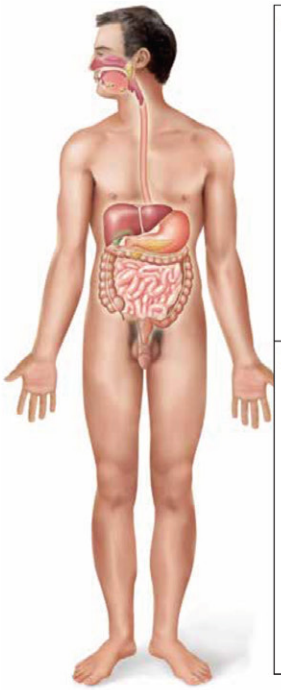

Digestive System

Main Organs:

Main Functions:

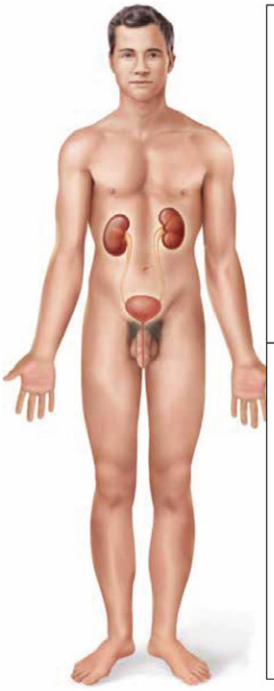

Urinary System

Main Organs:

Main Functions:

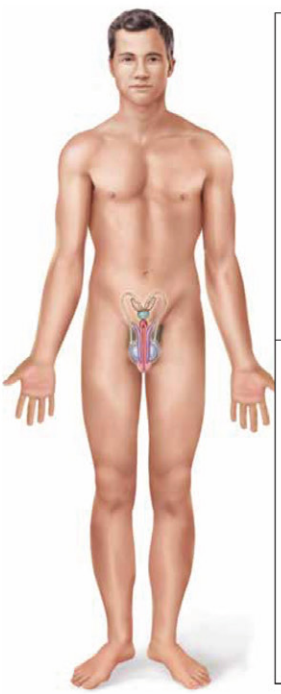

Male Reproductive System

Main Organs:

Main Functions:

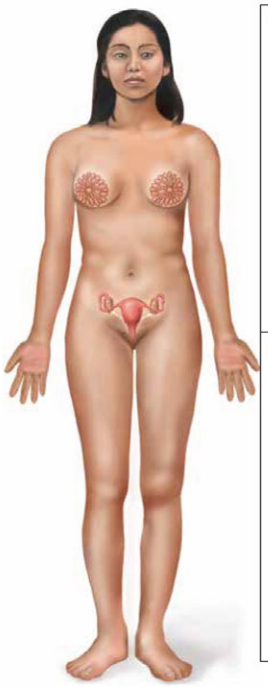

Female Reproductive System

Main Organs:

Main Functions:

FIGURE **1.14** *(cont.)* Organ systems of the body.

Name _____

Section _____ Date _____

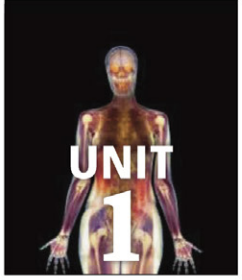

Check Your Recall

REVIEW

1 Define anatomical position.

2 *Matching:* Match the directional term with its correct definition.

_____ Distal	A. Away from the surface/toward the body's interior
_____ Lateral	B. Toward the back of the body
_____ Anterior	C. Closer to the point of origin (e.g., of a limb)
_____ Proximal	D. Away from the body's midline
_____ Inferior	E. Toward the head
_____ Deep	F. Farther from the point of origin (e.g., of a limb)
_____ Superficial	G. Toward the body's midline
_____ Posterior	H. Away from the head/toward the tail
_____ Medial	I. Toward the front of the body
_____ Superior	J. Toward the surface/skin

3 Which of the following is a correct use of a directional term?

a. The ankle is inferior to the knee.
b. The sternum is distal to the abdomen.
c. The bone is superficial to the muscle.
d. The ear is lateral to the mouth.

1

4 Label the following anatomical regions on Figure 1.15.

- ❑ Arm
- ❑ Axillary region
- ❑ Brachial region
- ❑ Carpal region
- ❑ Cervical region
- ❑ Femoral region
- ❑ Forearm
- ❑ Leg
- ❑ Otic region
- ❑ Tarsal region
- ❑ Thigh
- ❑ Vertebral region

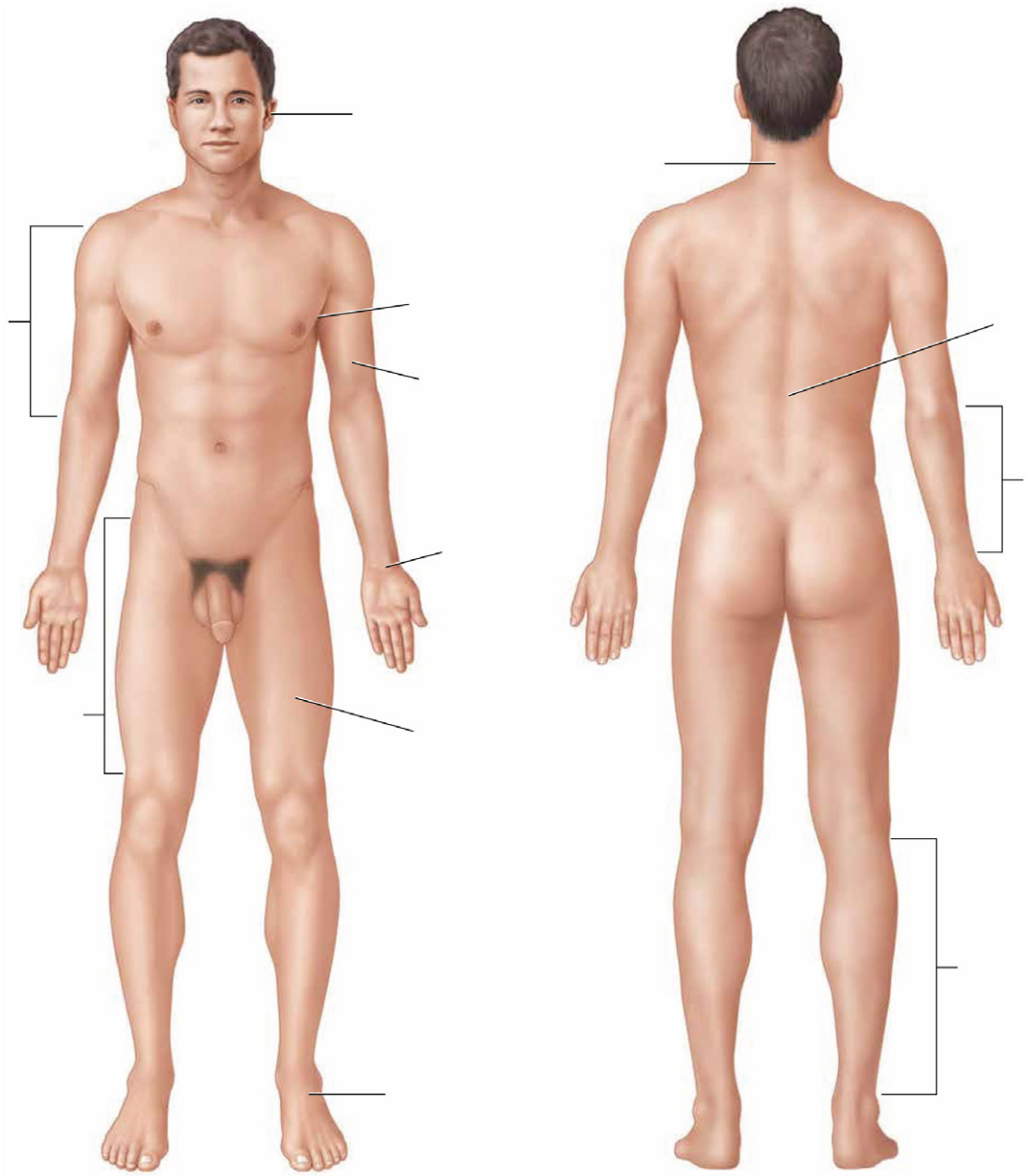

FIGURE **1.15** Anterior and posterior views of the body.

Name _____

Section _____ Date _____

5 Label the following body cavities on Figure 1.16, and indicate with an asterisk (*) which cavities are surrounded by serous membranes.

- ❑ Abdominal cavity
- ❑ Cranial cavity
- ❑ Mediastinum
- ❑ Pelvic cavity
- ❑ Pericardial cavity
- ❑ Peritoneal cavity
- ❑ Pleural cavity
- ❑ Vertebral cavity

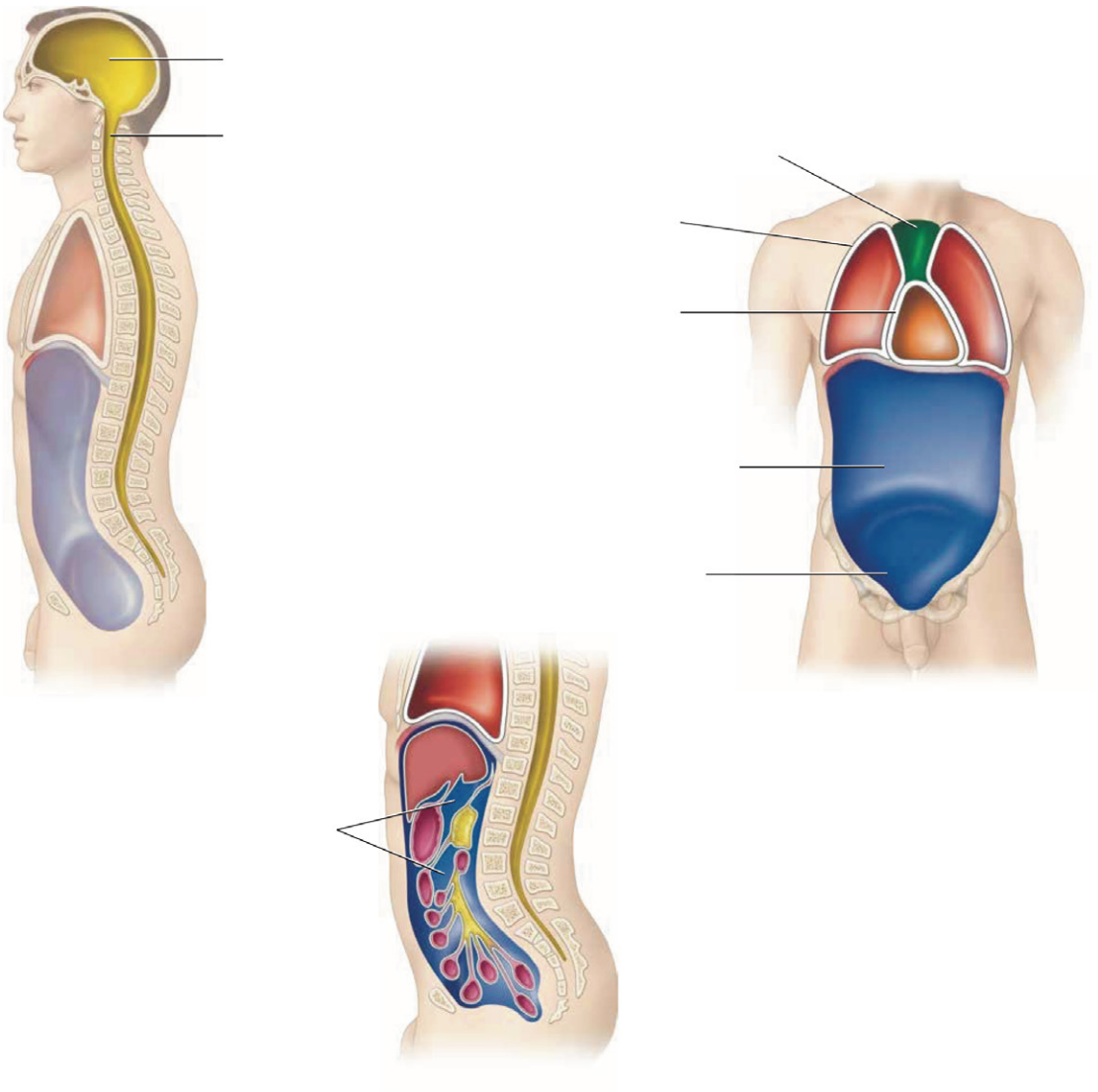

FIGURE **1.16** Body cavities.

6 *Fill in the blanks:* The outer layer of a serous membrane is called the _____ layer, and the inner layer of the serous membrane is called the _____ layer.

7 The midsagittal plane divides the body or body part into

a. anterior and posterior parts.
b. equal right and left halves.
c. unequal right and left parts.
d. superior and inferior (or proximal and distal) parts.

8 The frontal plane divides the body or body part into

a. anterior and posterior parts.
b. equal right and left halves.
c. unequal right and left parts.
d. superior and inferior (or proximal and distal) parts.

9 The following organs belong to the _____ system: spleen, lymph nodes, and thymus.

a. integumentary
b. reproductive
c. lymphatic
d. digestive

10 The following organs belong to the _____ system: gallbladder, liver, and esophagus.

a. digestive
b. urinary
c. endocrine
d. respiratory

Name _____

Section _____ Date _____

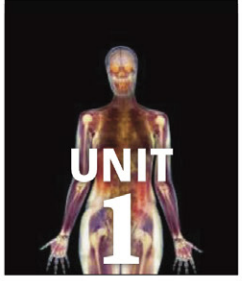

Check Your Understanding

REVIEW

Critical Thinking and Application Questions

1 Figure 1.17 is not in anatomical position. List all of the deviations from anatomical position.

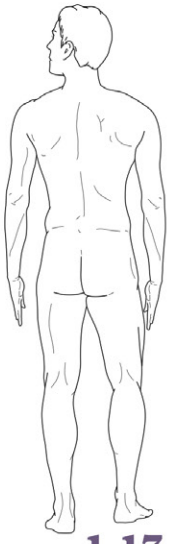

FIGURE **1.17** Figure not in anatomical position.

2 Locate the following wounds, and mark them on the body in Figure 1.18.

a The wound is located in the right superior, posterior acromial region. It is 8 centimeters lateral to the vertebral region and 3 centimeters superior to the scapular region.

b The wound is located on the left anterior, medial femoral region, 10 centimeters distal to the inguinal region.

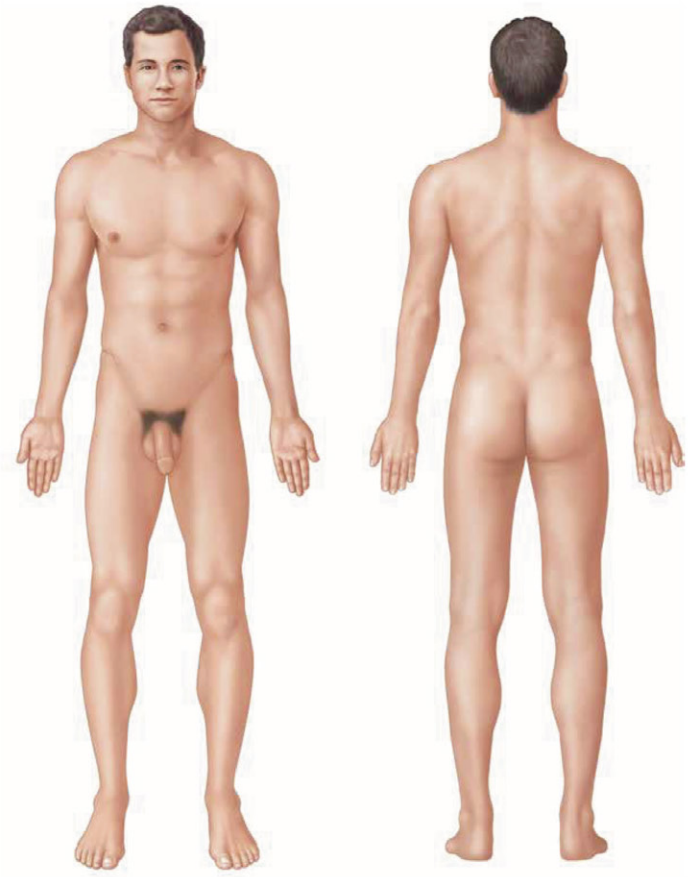

FIGURE **1.18** Anterior and posterior views of the body.

1

3 You are reading a surgeon's operative report. During the course of the surgery, she made several incisions. Your job is to read her operative report and determine where the incisions were made. Draw and label the incisions on Figure 1.19.

a The first incision was made in the right anterior sternal region, 3 centimeters inferior to the cervical region. The cut extended vertically in an inferior direction, ending 2 centimeters superior to the umbilical region.

b The second incision began in the left lateral inguinal region and extended horizontally in a medial direction for 4 centimeters to the pubic region. At the pubic region, the cut turned and extended vertically in a distal direction for 4 centimeters and ended in the proximal femoral region.

c The third incision was made in the left posterior, lateral femoral region, 2 centimeters proximal to the popliteal region. The cut extended in a distal direction to 2 centimeters proximal to the tarsal region.

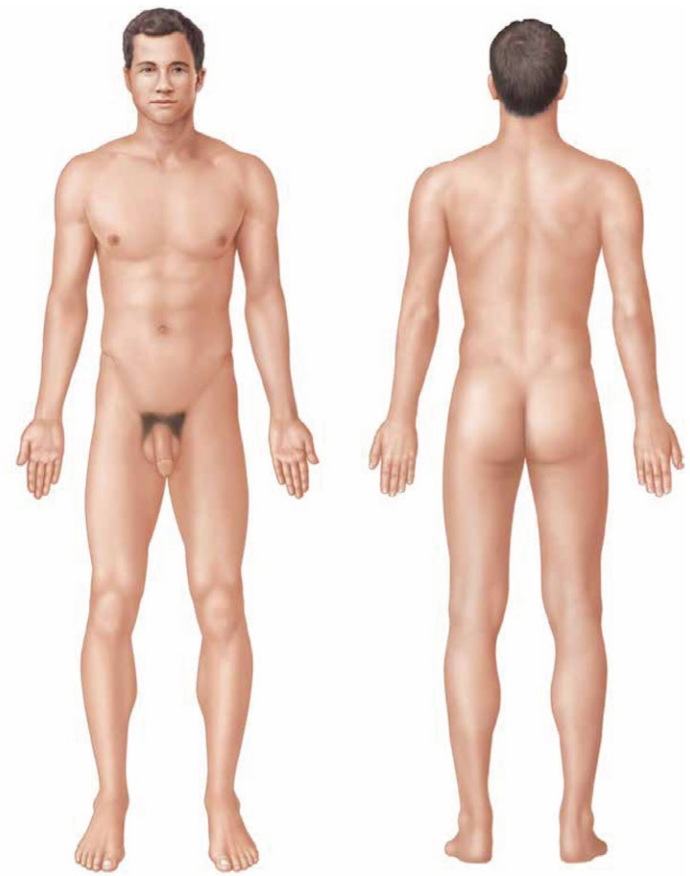

FIGURE **1.19** Anterior and posterior views of the body.

Name _____

Section _____ Date _____

4 You are riding with an ambulance crew who is called to the scene of a motor vehicle accident caused by texting while driving. As the paramedics are loading one of the victims into the ambulance, you are asked to describe his most serious wounds to the emergency department so they can be prepared for his arrival. Describe the location of his wounds, indicated on Figure 1.20 by three X marks, using at least three correct regional and directional terms.

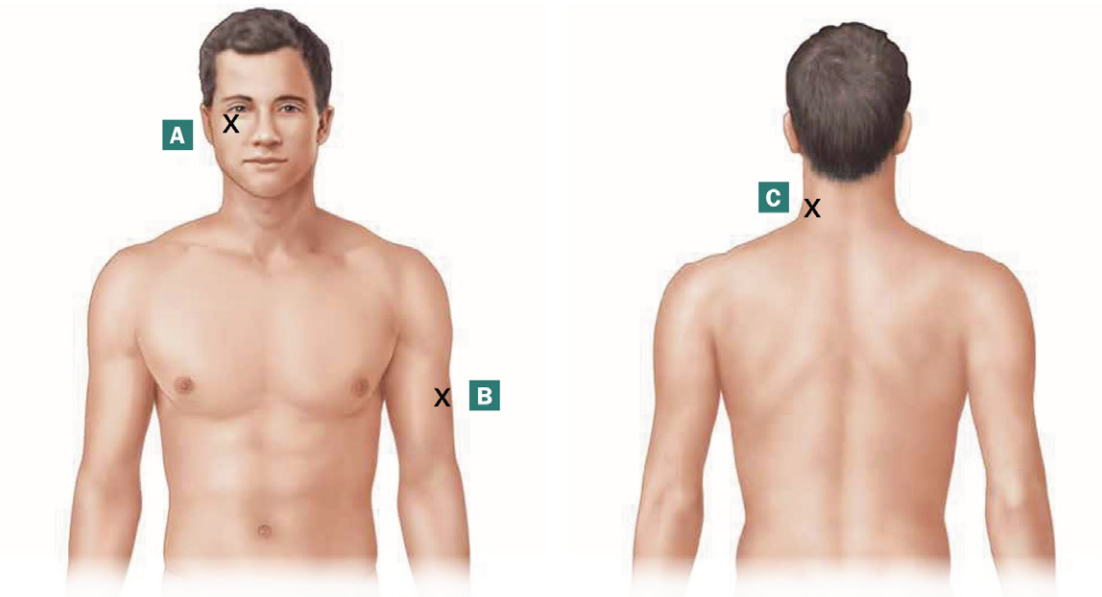

FIGURE **1.20** Anterior and posterior views of the body.

a _____

b _____

c _____

5 A female patient presents to the emergency department complaining of pain in the right lower quadrant of her abdomen. List the organs and structures that could possibly be involved in causing her pain.

_____

_____

_____

6 Identify the planes of section of each of the following medical imaging scans in Figure 1.21.

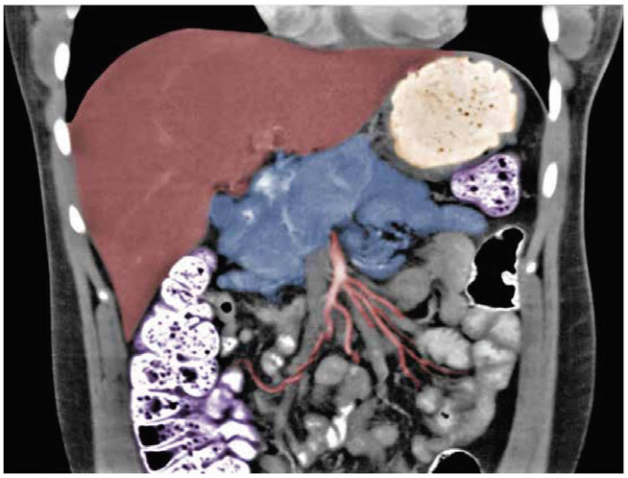

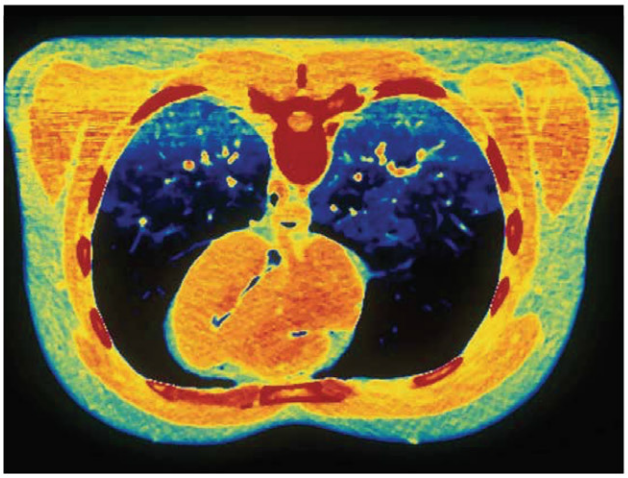

a _____ b _____

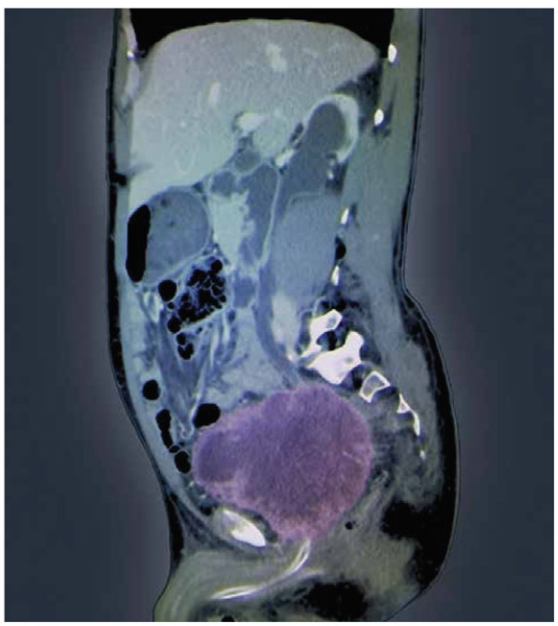

c _____

FIGURE **1.21** Computed tomography scans in different anatomical sections.

7 Identify some of the major organs you can see in each of the sections from question 6.

a _____

b _____

c _____

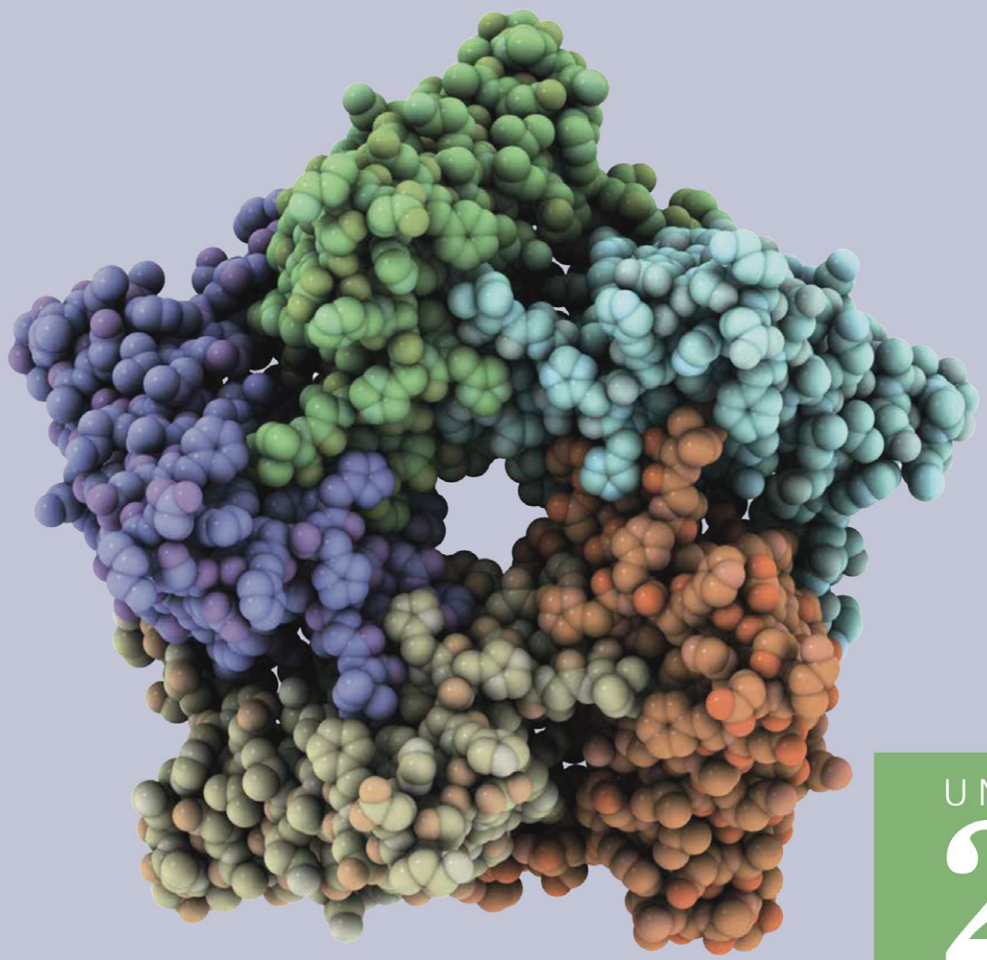

UNIT
2

Chemistry

Once you have completed this unit, you should be able to:

1. Demonstrate the proper interpretation of pH paper.
2. Describe and apply the pH scale.
3. Describe the purpose and effects of a buffer.
4. Explain and demonstrate the purpose of an enzyme.
5. Determine the degree of solubility of a solute in water based on its chemical properties and its size.
6. Describe the differences in solubility of ionic, polar, and nonpolar molecules in different solvents.
7. Apply laboratory techniques to perform DNA extraction.

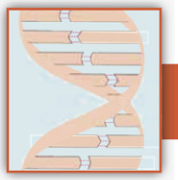

Name _____ Section _____ Date _____

2

PRE-LAB EXERCISES

Complete the following exercises prior to coming to lab, using this lab manual and your textbook for reference.

Pre-Lab Exercise 2-1



Key Terms

You should be familiar with the following terms before coming to lab.

Term	Definition
pH	
Acid	
Base	
Neutral	
Buffer	
Chemical reaction	
Enzyme	
Denatured	
Polar covalent bond	
Nonpolar covalent bond	
Ionic bond	
Solute	

Name _____ Section _____ Date _____

Solvent _____

Solubility _____

Hydrophilic _____

Hydrophobic _____

Deoxyribonucleic acid (DNA) _____

Pre-Lab Exercise 2-2

The pH Scale and –logarithms

The **pH scale** is a numerical scale from 0 through 14 that represents the hydrogen ion concentration of a solution. Solutions with a pH of 0 have the highest hydrogen ion concentration, and solutions with a pH of 14 have the lowest hydrogen ion concentration. This is because the pH isn't the actual hydrogen ion concentration; instead, it is a negative logarithm of a solution's hydrogen ion concentration. This actually isn't as difficult as it sounds. Grab your calculator and enter the following:

–log(0.01) = _____

–log(0.001) = _____

–log(0.0001) = _____

–log(0.00001) = _____

Notice the general trend here: *As the number gets smaller, its negative log gets bigger.*

Here's a quick example using hydrogen ions: Solution X has a hydrogen ion concentration of 0.05 M. Solution Y has a hydrogen ion concentration of 0.0002 M.

- Which solution has more hydrogen ions? (***Hint:*** It's just the solution with the bigger number.) _____
- What is the –log of solution X? _____
- What is the –log of solution Y? _____

As you can see, the solution with the *higher* hydrogen ion concentration has the *lower* –log. This means that:

- Solution X is the more _____ (acidic/basic) solution and has a _____ (lower/higher) pH.
- Solution Y is the more _____ (acidic/basic) solution and has a _____ (lower/higher) pH.

2

Pre-Lab Exercise 2-3



Chemical Bonding

One of the more challenging concepts to grasp in chemistry is **chemical bonding**, a topic that pops up again and again in A&P. We revisit it in cytology, the nervous system, blood, respiration, and digestion—to name just a few.

First let's do some basics. Use your textbook and this unit to answer the following questions.

1. Do metals donate or accept electrons? What do they become after they donate/accept electrons?

2. Do nonmetals donate or accept electrons? What do they become after they donate/accept electrons?

3. Electron shells:

   How many electrons can go in the first shell? _____

   How many electrons can go in the second shell? _____

   How many electrons can go in the third shell? _____

4. How many electrons does each element require in its valence shell to become stable? _____

Okay, now let's apply all of this to an example.

Example 1: Ionic Bond

Let's take a look at sodium (Na) and chlorine (Cl). Draw what I am describing, and you will see it better.

A sodium atom has how many protons? _____

A sodium atom has how many electrons? _____

How many electrons will go in the first shell? _____

How many in the second shell? _____

How many in the third? _____

Now draw this out on the diagram in Figure 2.1, and take a look at it, in particular the third (valence) shell.

We know that Na requires eight electrons in its valence shell to become stable. But how many does it have? _____

So, to fill this shell, will it be easier for sodium to steal seven more electrons from another atom, or will it be easier for sodium to give up that one electron and get rid of that third shell? Sodium is simply going to *give away* that last electron. This means that it will lose an electron (negative charge) but will keep the same number of protons (positive charges). What will the sodium ion's overall charge be now? _____

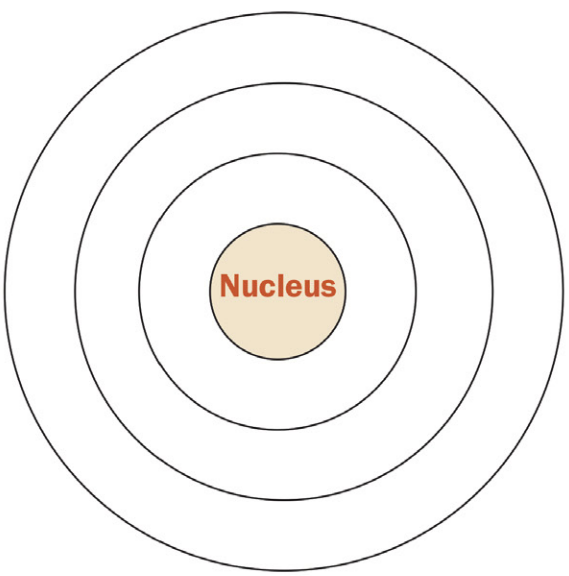

FIGURE **2.1** Orbital model of an atom.

Now let's look at chlorine:

A chlorine atom has how many protons? _____

Therefore, we know that a chlorine atom has how many electrons? _____

How many electrons will go in the first shell? _____

How many in the second shell? _____

How many in the third? _____

Draw this in Figure 2.2.

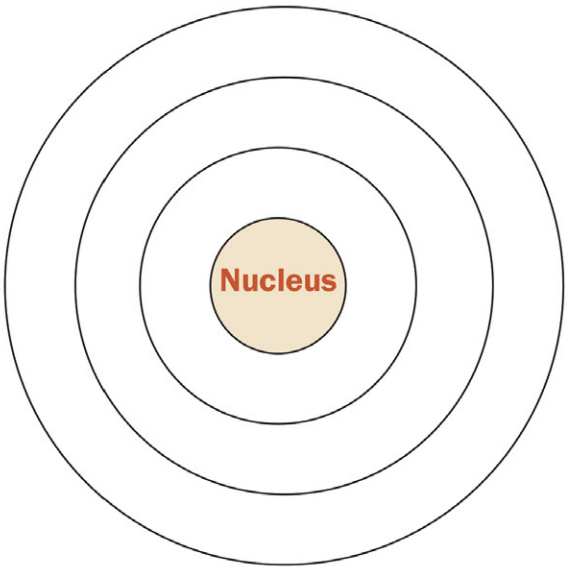

FIGURE **2.2** Orbital model of an atom.

We know that a chlorine atom requires eight electrons in its valence shell to become stable. Will it be easier for chlorine to steal one electron from another atom, or will it be easier for chlorine to give away seven electrons? It will be *much* easier for chlorine to take an electron from another atom than to try to pawn off seven electrons. This means that chlorine will gain an electron (negative charge) but will keep the same number of protons (positive charges). What charge will chlorine (now called a *chloride ion*) have now? _____

Let's tie this in with what we learned about metals and nonmetals earlier.

We said that metals _____ electrons to become _____.

Is sodium a metal or a nonmetal? _____

Looking at our example above, did sodium donate or accept an electron? _____

We also said that nonmetals _____ electrons to become _____.

Is chlorine a metal or a nonmetal? _____

Looking at our example above, did chlorine donate or accept an electron? _____

Why do we care? Well, when sodium donates an electron to become a positively charged **cation**, and chlorine accepts an electron to become a negatively charged **anion**, this creates an attraction. (Think of it like "opposites attract.") This attraction leads the two ions to *bond* to one another, forming an **ionic bond.** See how simple that is?

Example 2: Polar Covalent Bond

2

Now let's tackle another bonding concept, the **polar covalent bond**. The classic example of a polar covalent bond is represented by the two bonds in a water molecule (Fig. 2.3A):

A hydrogen (H) atom has how many protons? _____

A hydrogen atom has how many electrons? _____

How many electrons will go in the first shell? _____

How many electrons would hydrogen require to fill up that first shell? _____

An oxygen (O) atom has how many protons? _____

Therefore, we know that oxygen has how many electrons? _____

How many electrons will go in the first shell? _____

How many electrons will go in the second shell? _____

How many electrons would oxygen require to fill up that second shell? _____

In this case, both hydrogen and oxygen are nonmetals, and neither element will give up electrons in this situation. So, instead of one element taking the electrons, they share them. Because oxygen requires two electrons to fill that valence shell, and hydrogen has only one electron to share, oxygen has to form a partnership with two hydrogen atoms, forming H_2O. But oxygen has a higher **electronegativity**, which means that it attracts electrons more strongly than hydrogen does. This means that the electrons will spend more time around the oxygen and less around the hydrogen. Thus, a polar covalent bond is born. This means that:

Oxygen will have a partial _____ charge, and the two hydrogens will have a partial _____ charge, which you can see in Figure 2.3A.

A **nonpolar covalent bond** involves the same principles, except that the atoms share the electrons equally. As a result, there are no partial positive or negative charges because the electrons don't spend any more time around one or more of the atoms. You can see this in Figure 2.3B with the example of a molecule of hydrogen (H_2)—both hydrogen atoms have the same electronegativity, and so they have the same pull on the electrons. As a result, the electrons spend an equal amount of time around each atom.

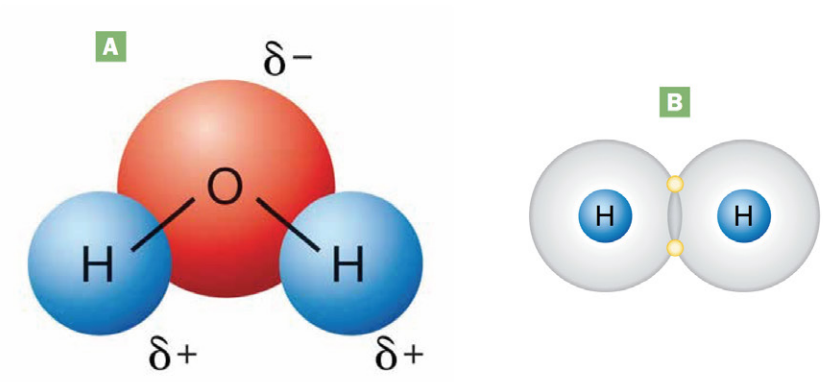

FIGURE **2.3** Covalent bonds: (**A**) polar covalent, a molecule of water; (**B**) nonpolar covalent, a molecule of hydrogen.

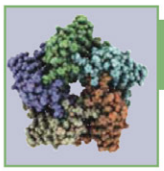

Molecular model of lumazine synthase, an enzyme involved in riboflavin (vitamin B_2) biosynthesis.

EXERCISES

Including a chemistry unit with an anatomy and physiology course may seem odd, but consider for a moment the simplest level of organization—the chemical level. Our cells, tissues, and organs, as well as our extracellular environments, are all composed of chemicals that undergo countless chemical reactions every second. So, to be able to understand our anatomy and physiology, we first must understand the most basic structures in our bodies—chemicals.

In the following exercises you will learn chemistry principles as you measure the pH of various solutions, demonstrate the effects of buffers on the pH of solutions, examine the effects of enzymes on chemical reactions, and determine different chemicals' solubilities. Then you will witness chemistry in action by extracting DNA. It's not every day that you get to say that you extracted DNA!

Safety Note

Many of the chemicals you will use in this lab are poisons and can burn your skin, eyes, and mucous membranes. Take care in handling all chemicals. Do not handle any chemicals without safety glasses, gloves, and a lab coat.

Exercise 2-1

pH, Acids, and Bases

MATERIALS

- ❑ 3 glass test tubes
- ❑ Test tube rack
- ❑ Graduated cylinder
- ❑ Dropping pipette
- ❑ pH paper
- ❑ Samples of various acids and bases
- ❑ 0.1 M hydrochloric acid
- ❑ Samples of Tums, Rolaids, and Alka-Seltzer antacid tablets
- ❑ Glass stirring rods
- ❑ Sharpie

The **pH** represents a measure of the concentration of hydrogen ions present in a solution. As the hydrogen ion concentration increases, the solution becomes more **acidic**. As the hydrogen ion concentration decreases, the solution becomes more **alkaline**, or **basic**. Notice that the **pH scale**, shown in Figure 2.4, ranges from 0 (the most acidic) to 14 (the most basic). As you learned in the Pre-Lab Exercises, the reason for this is that the pH is actually a negative logarithm, so the lower the pH, the higher the hydrogen ion concentration. A pH of 7 is considered **neutral**, which is neither acidic nor basic, because the number of hydrogen ions equals the number of base ions in the solution.

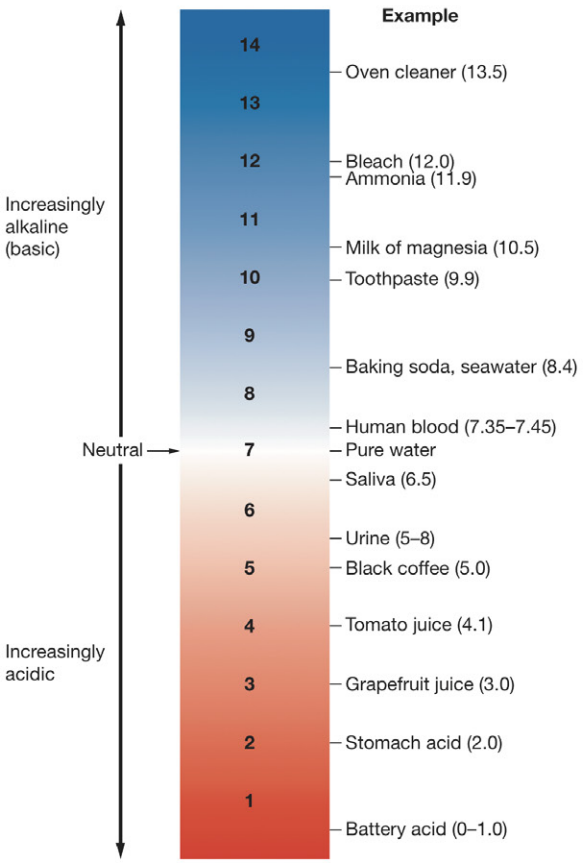

FIGURE **2.4** pH scale and examples of solutions with different pH values.

Acids and bases are some of the most important chemicals in the human body: They are found in the stomach, in the blood and other extracellular body fluids, in the cytosol, and in the urine and are released by cells of the immune system. The normal pH for the blood is about 7.35 to 7.45. The body regulates this pH tightly, as swings of even 0.2 in either direction can cause serious disruptions in many of our physiological processes.

Procedure 1 Reading the pH

A simple way to measure pH is to use pH paper (Fig. 2.5). To test the pH with pH paper, drop one or two drops of the sample solution on the paper, and compare the color change with the colors on the side of the pH paper container. The pH is read as the number that corresponds to the color the paper turned.

Safety Note

Safety glasses and gloves are required!

1. Obtain two samples each of known acids and bases, and record their molecular formulae in Table 2.1 (the molecular formula should be on the side of each bottle).
2. Measure the pH of each acid and base using pH paper, and record their pH values in Table 2.1.
3. Obtain two randomly selected unknown samples, and measure their pH using pH paper.
4. Record the pH values in Table 2.1, and determine if this substance is an acid, a base, or neutral based upon its pH.

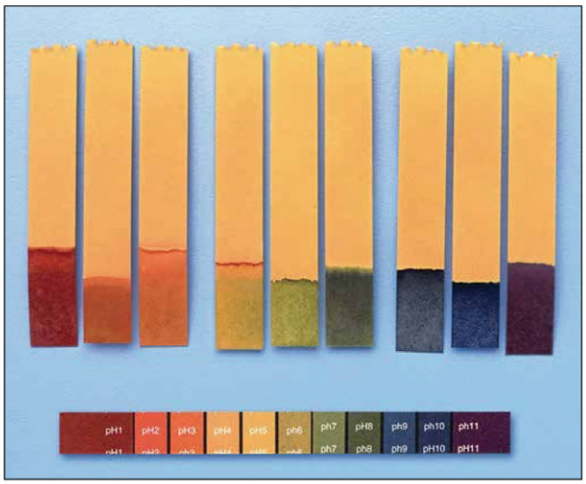

FIGURE 2.5 pH paper and indicator strip.

TABLE 2.1 Samples of Acids and Bases

Samples	Molecular Formula	pH
Acid #1		
Acid #2		
Base #1		
Base #2		
Unknown Samples	**pH**	**Acid, Base, or Neutral?**
Unknown #1		
Unknown #2		

Procedure 2 pH Applications

Now let's apply the pH scale to physiological systems. The stomach contains concentrated hydrochloric acid, and the pH of the stomach contents ranges between 1 and 3. **Antacids** are a group of medications that raise the pH of the stomach contents to treat a variety of conditions, including *gastroesophageal reflux*, commonly known as *heartburn*. Antacids generally consist of a metal bonded ionically to a base. In this activity you will compare the effectiveness of three widely available antacids in raising the pH of concentrated hydrochloric acid. When you have completed the activity, answer Check Your Understanding questions 1 and 2 (p. 57).

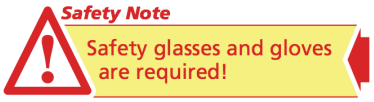

1. Obtain three glass test tubes, and label them 1, 2, and 3 with a Sharpie.
2. Obtain a bottle of 0.1 M hydrochloric acid (HCl), and record its pH in the blank below.

   pH of 0.1 M HCl: _____
3. In each tube, place 2 mL of the 0.1 M HCl.
4. Add about one-fourth of one crushed Tums tablet to tube 1 and stir the contents with a glass stirring rod.
5. Add about one-fourth of one crushed Rolaids tablet to tube 2 and stir the contents with a glass stirring rod.
6. Add about one-fourth of one crushed Alka-Seltzer tablet to tube 3 and stir the contents with a glass stirring rod.
7. Allow the tubes to sit undisturbed for 3 minutes.
8. Measure the pH of the contents of each tube, and record the values in Table 2.2.
9. What effect did the antacids have on the acid? _____

TABLE 2.2 Effectiveness of Three Antacids

Antacid	Active Ingredient	pH
Tums		
Rolaids		
Alka-Seltzer		

10. Based upon your observations, which antacid is the most effective at neutralizing the acid?

_____

2

Exercise 2-2

Buffers

MATERIALS

- ❑ Well plates
- ❑ Stirring rods
- ❑ Dropping pipettes
- ❑ 0.1 M hydrochloric acid
- ❑ Buffered solution
- ❑ Distilled water
- ❑ 0.1 M NaOH
- ❑ pH paper
- ❑ Sharpie

A **buffer** is a chemical that resists large or dramatic changes in pH; a solution to which a buffer has been added is called a **buffered solution**. When acid is added to a buffered solution, the buffer binds the added hydrogen ions and removes them from the solution. Similarly, when a base is added to a buffered solution, the buffer releases hydrogen ions into the solution. Both effects minimize the pH changes that otherwise would occur in the solution if the buffer were not present.

Procedure 1 Testing Buffered Solutions

In this experiment you will examine the effects of adding an acid or a base to buffered solutions and nonbuffered solutions. You will use distilled water as your nonbuffered solution, and your instructor will choose an appropriate buffered solution for you to use. When you have completed the activity, answer Check Your Understanding questions 3 and 4 (p. 57).

1 Obtain a well plate, and number four wells 1, 2, 3, and 4 with a Sharpie.

2 Fill wells 1 and 2 about half-full of distilled water. Measure the pH of the distilled water, and record that value in Table 2.3.

3 Fill wells 3 and 4 about half-full of buffered solution. Measure the pH of the buffered solution and record that value in Table 2.3.

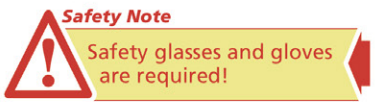

4 Add two drops of 0.1 M HCl to wells 1 and 3. Stir the solutions with a stirring rod (or a toothpick), and measure the pH of each well. Record the pH in Table 2.3.

5 Add two drops of 0.1 M NaOH (a base) to wells 2 and 4. Stir the solutions, and measure the pH of each well. Record the pH in Table 2.3.

TABLE **2.3** pH of Buffered and Nonbuffered Solutions

	Initial Solution		Solution After Adding Acid or Base	
Well	Contents	pH	Contents	pH
1	Water		Water + 0.1 M HCl	
2	Water		Water + 0.1 M NaOH	
3	Buffered solution		Buffered solution + 0.1 M HCl	
4	Buffered solution		Buffered solution + 0.1 M NaOH	

6 Interpret your results. What effect did the buffer have on the pH changes you saw? _____

Exercise 2-3

Enzymes and Chemical Reactions

MATERIALS

- ❑ 6 glass test tubes
- ❑ Test tube rack
- ❑ Lipase
- ❑ Boiled lipase
- ❑ Bile salts
- ❑ Vegetable oil
- ❑ 0.1 M NaOH
- ❑ Ice water bath
- ❑ Warm-water bath (set to 37°C)
- ❑ Phenol red
- ❑ Sharpie

Often when atoms or molecules interact, chemical bonds are formed, broken, or rearranged, or electrons are transferred between molecules. These interactions are called **chemical reactions**. Most chemical reactions can proceed spontaneously, but they often take an extremely long time.

One factor that can alter the rate at which a reaction takes place is *temperature*. Generally, when the temperature increases (up to a point), molecules move faster, and they collide and react at a faster rate. The opposite happens when the temperature decreases.

Another factor that can affect reaction rate is a substance called a **catalyst** that is added to a reaction to increase its rate. Catalysts are not consumed in the reaction and may be reused after the reaction has completed.

In the body, biological catalysts called **enzymes** speed up essentially all of our chemical reactions. Nearly all enzymes in the body are **proteins** that work by binding specifically to the reacting components and reducing the amount of energy required for a reaction to proceed (called the *activation energy*). Note that like all proteins, an enzyme must have a specific shape that allows it to bind to the reactants for it to work. This means that if the enzyme is damaged and loses its shape, it will not be able to function. Enzymes can be damaged by the same processes that can damage any protein, including extreme heat and extreme pH swings. An enzyme that has lost its shape as a result of such damage is said to be **denatured** and is not able to catalyze reactions.

Procedure 1 Test Enzymatic Activity

In the following procedure, you will be comparing the ability of two solutions—lipase and boiled lipase—to digest vegetable oil at three different temperatures. **Lipase** (LYE-payz) is an enzyme found in the human digestive tract that catalyzes the digestion of fats called **triglycerides** (try-GLISS-er-aye'dz). Triglycerides consist of three long hydrocarbon chains called *fatty acids* bound to a sugar alcohol called *glycerol* (Fig. 2.6). Lipase catalyzes the reactions that break a triglyceride into two free fatty acids and a *monoglyceride*.

You will check for the presence of digestion using an indicator called **phenol red**. Phenol red appears pink at an alkaline (basic) pH, changes to an orange-red color at a neutral pH, and changes to a yellow color when the pH becomes acidic. If triglycerides have been digested, fatty acids will be released that will decrease the pH of the contents of your tube and turn them orange-red or yellow. You may interpret your results in the following way (Fig. 2.7):

- Yellow color = the pH is acidic, and significant triglyceride digestion occurred.
- Red-orange color = the pH is neutral, and some triglyceride digestion occurred.
- Pink color = the pH is basic, and no (or limited) triglyceride digestion occurred.

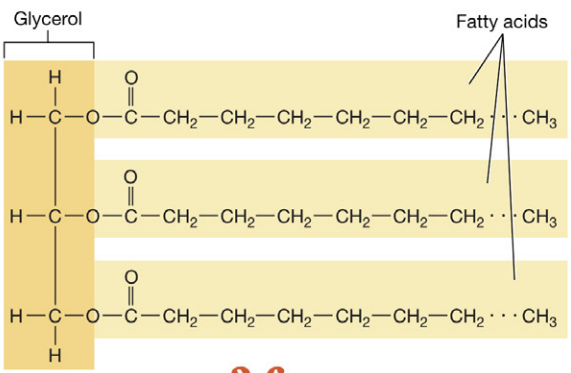

FIGURE **2.6** Triglyceride.

FIGURE **2.7** Possible results from the lipid digestion experiment.

Note that you also must add another component, called **bile**, to your mixture for digestion to occur. Bile is not an enzyme itself, but it does increase the ability of lipase to catalyze triglyceride digestion. When you have completed this experiment, answer Check your Understanding question 5 (p. 58).

Safety Note

Safety glasses and gloves are required!

2

1. Obtain six glass test tubes and label them 1 through 6 with a Sharpie.
2. Add 3 mL of vegetable oil to each test tube.
3. Add 8–10 drops of the pH indicator phenol red to each test tube. The oil now should appear pink. If it does not, add drops of 0.1 M NaOH (a base) to each tube until the indicator turns pink.
4. Add the following ingredients to each test tube:
   - Tubes 1, 3, and 5: 1 mL lipase, 1 mL bile.
   - Tubes 2, 4, and 6: 1 mL boiled lipase, 1 mL bile.
5. Place tubes 1 and 2 in an ice bath, and incubate them for 30 minutes.
6. Leave tubes 3 and 4 in your test tube rack to incubate at room temperature for 30 minutes.
7. Place tubes 5 and 6 in a warm-water bath set to 37°C, and incubate them for 30 minutes.
8. After 30 minutes have passed, remove the tubes from the ice bath and warm-water bath, and place them in your test tube rack.
9. Record the color of each tube in Table 2.4, and interpret your results.

TABLE **2.4** Enzymatic Activity of Lipase

Tube Number	Color	pH (Acidic, Neutral, or Alkaline)	Amount of Digestion that Occurred
1			
2			
3			
4			
5			
6			

10. Answer the following questions about your results:
    a. What effect does temperature have on enzyme activity?

    b. Were your results with the boiled lipase different from the results with nonboiled lipase? Why?

Exercise 2-4

Chemical Solubilities

MATERIALS

- ❑ 13 glass test tubes
- ❑ 13 rubber stoppers
- ❑ Graduated cylinders
- ❑ Test tube rack
- ❑ Distilled water
- ❑ Paint thinner (such as acetone)
- ❑ Table salt
- ❑ Sucrose
- ❑ Iodine crystals
- ❑ Unknown solids
- ❑ Starch
- ❑ Pink glucose
- ❑ Oil dyed with Sudan red
- ❑ Lab scoops or spatulas
- ❑ Lugol's iodine
- ❑ Sharpie

In the Pre-Lab Exercises you learned that three main types of bonds are present between atoms:

1. **Ionic bonds.** An **ionic bond** forms when one or more electrons is transferred from a metal to a nonmetal. In this transfer, the metal becomes a positive cation, and the nonmetal becomes a negative anion. These positive and negative charges attract and result in the ionic bond.
2. **Covalent bonds. Covalent bonds** form when two or more atoms share electrons. This results in more stable atoms with eight electrons in their valence shells (or two electrons for atoms with five or fewer protons). The two types of covalent bonds are:
   a. **Polar covalent bonds.** A **polar covalent bond** results from the unequal sharing of electrons between atoms with unequal electronegativities. Essentially, one atom is "greedier" (more electronegative) than the other, and the electrons spend more time around the "greedier" atom. This creates what is known as a **dipole**—a molecule with a partially positive pole and a partially negative pole ("dipole" literally means "two poles").
   b. **Nonpolar covalent bonds.** The electrons are shared equally between the atoms involved in a **nonpolar covalent bond** because the two atoms have nearly the same electronegativities. As a result, they have no partial positive or negative charges.

Chemicals are not limited to having only ionic, polar covalent, or nonpolar covalent bonds. Certain chemicals are **amphipathic** (am-fih-PATH-ik), meaning that they have both polar and nonpolar parts. Many important biological compounds, including phospholipids and bile salts, are amphipathic.

Determining the types of bonds present in a molecule is important, because molecules will generally only mix well with other molecules that have similar bonds. In general, the following rule can be used to determine whether one substance will mix with another:

Like interacts with like.

This means that chemicals with charged ends (polar and ionic compounds) prefer to interact with chemicals that also have charged ends (other polar and ionic compounds). Chemicals without charged ends (nonpolar molecules) prefer to interact with chemicals that also have no charged ends (other nonpolar molecules). This is something you have seen in action if you have ever tried to combine oil (nonpolar compound) and water (polar compound). In their natural conditions, oil and water don't mix because of their types of chemical bonds.

The degree to which a solid substance, called a **solute**, will mix with another substance (usually a liquid), called a **solvent**, is known as its **solubility**. A solute that dissolves completely in a solvent is said to be highly *soluble* in that solvent. Conversely, a solute that does not dissolve in a solvent is said to be *insoluble* in that solvent. The rules for which solutes are soluble in which solvents are simple:

- Polar and ionic solutes are soluble in most polar solvents.
- Nonpolar solutes are soluble in most nonpolar solvents.

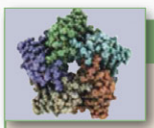

HINTS & TIPS

How to Determine the Types of Bonds in a Molecule

Following are some simple rules for determining whether a molecule is polar, nonpolar, or ionic.

- Any metal bound to a nonmetal is an ionic compound.
- All compounds that contain only C and H are nonpolar.
- Any molecule containing multiple atoms of the same element (e.g., H_2) is a nonpolar molecule.
- A compound containing C and/or H bound to a significant amount (about one-fourth or more of the total atoms) of O, N, P, Cl, or F is a polar compound.
- Any compound containing mostly C and H is overall a nonpolar compound. Note that many nonpolar compounds do contain atoms of O or N, but these atoms are in the minority.

2

The solvent in the human body is water, which is a polar compound. This means that polar and ionic solutes are soluble, or can *dissolve*, in liquid water and be carried around the body relatively easily and safely. Such solutes are said to be **hydrophilic** (hy-droh-FIL-ik), or "water loving." On the other hand, nonpolar substances are insoluble in water and are said to be **hydrophobic** (hy-droh-FOH-bik), or "water fearing." When hydrophobic substances are placed in water, they are attracted to one another instead of to the water molecules. This causes them to clump together and form increasingly large globs separate from the water.

Procedure 1 Test for Hydrophobic and Hydrophilic Solutes

You will now see what happens, with a simple demonstration, when we add a hydrophilic solute and a hydrophobic solute to water. When you have completed the activity, answer Check Your Understanding question 6 (p. 58).

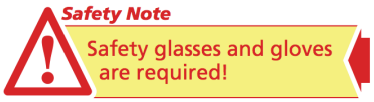

1. Obtain two test tubes with rubber stoppers. Label one "sugar" and the other one "oil."
2. Place about 3 mL of distilled water in each test test tube.
3. Add a pinch of pink glucose to the "sugar" test tube, place the rubber stopper on it, and shake the tube vigorously until the pink color is evenly distributed. Set the tube in a test tube rack and leave it undisturbed for 10 minutes.
4. Add about 1 mL of oil stained with Sudan red to the "oil" test tube, place the rubber stopper on it, and shake the tube vigorously until the red color is evenly distributed. Set the tube in a test tube rack and leave it undisturbed for 10 minutes.
5. After 10 minutes:
   a. What is the color of the water in the "sugar" tube? _____
   b. What is the color of the water in the "oil" tube? _____
6. Interpret your results:
   a. What types of bonds are in glucose ($C_6H_{12}O_6$)? How does this help explain the color of the water in this tube?

   b. What types of bonds are in oil? How does this help explain the color of the water in this tube?

   c. Which substance was hydrophilic? Which substance was hydrophobic? How do you know?

Procedure 2 Test the Solubility of Starch

The types of chemical bonds present in a molecule aren't the only factors that determine solubility. Other important factors to consider are the size and structure of the molecule. We can demonstrate this with the carbohydrate starch. You have already seen that glucose is soluble in water. Glucose is a simple sugar or **monosaccharide** (mahn-oh-SAK-uh-ry'd), which is shown in Figure 2.8A. Conversely, starch, shown in Figure 2.8B, is a complex carbohydrate or **polysaccharide** (pawl-ee-SAK-uh-ry'd). Notice the difference between the two structures—glucose consists of a single subunit, whereas starch consists of multiple glucose subunits bound together in a branching pattern. Both compounds are polar, but do they have the same solubility in water?

Safety Note

Safety glasses and gloves are required!

1. Obtain a test tube with a rubber stopper. Label it "starch" with a Sharpie.
2. Fill the tube with 3 mL of distilled water. Add a small scoopful of starch to the water, place the rubber stopper on the tube, and shake the tube vigorously for about one minute.
3. Place the tube in the test tube rack and let it sit for 10 minutes.
4. After 10 minutes, add two drops of Lugol's iodine to the mixture. Lugol's iodine turns dark blue-purple in the presence of starch.

   Color of mixture: _____

5. Interpret your results:

   a. How soluble is starch in water?

   b. Why is there a difference between the solubilities of starch and glucose, even though they are both polar compounds?

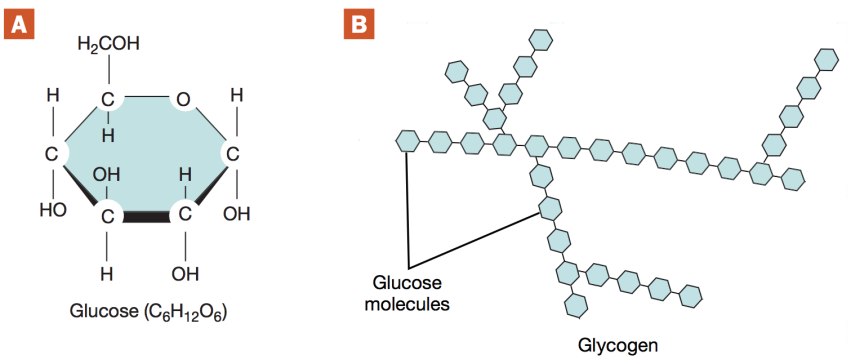

FIGURE 2.8 Carbohydrates: (A) glucose; (B) starch.

2

Procedure 3 Test Chemical Solubilities

You now will determine whether solutes are nonpolar or polar ionic, based upon the type of solvent in which they dissolve. In this exercise, you will have two solvents—one that is polar and one that is nonpolar. You will attempt to dissolve three known samples of solute and two unknown samples of solute in these solvents, after which you will use these solubilities to determine the types of bonds that may be present in your unknown samples.

After you test them, your instructor may wish to give you the molecular formulae of your unknown samples so you may determine the types of molecules more precisely.

Safety Note
Safety glasses and gloves are required!

1 Obtain 10 glass test tubes, a test tube rack, and 10 rubber stoppers. Number the test tubes 1 through 10 with a Sharpie.

2 Add 2 mL of distilled water to tubes 1 through 5. Add 2 mL of paint thinner to tubes 6 through 10.

- **a** Which solvent is the polar solvent? _____
- **b** Which solvent is the nonpolar solvent? _____

3 Add a pinch of table salt to tubes 1 and 6. What is the molecular formula for salt?

_____

4 Add a pinch of sucrose to tubes 2 and 7. What is the molecular formula for sucrose?

_____

5 Add a pinch of iodine crystals to tubes 3 and 8. What is the molecular formula for iodine?

_____

6 Add a pinch of unknown substance A to tubes 4 and 9.

7 Add a pinch of unknown substance B to tubes 5 and 10.

8 Place a stopper firmly in each of the tubes. Shake each tube for several seconds until you are certain that no further change will take place in the solute.

TABLE **2.5** Solubilities

Tube	Tube Contents	Dissolved in Polar Solvent?
1	(salt + water)	
2	(sucrose + water)	
3	(iodine + water)	
4	(unknown A + water)	
5	(unknown B + water)	
Tube	**Tube Contents**	**Dissolved in Nonpolar Solvent?**
6	(salt + paint thinner)	
7	(sucrose + paint thinner)	
8	(iodine + paint thinner)	
9	(unknown A + paint thinner)	
10	(unknown B + paint thinner)	

9 Examine each tube, and determine if the solute dissolved or remained separate. Record your results in Table 2.5.

10 Now use your results to determine if the solute is an ionic, polar, or nonpolar molecule. For your unknowns, you will only be able to determine if the solute is ionic/polar or nonpolar.

- **a** What type of compound is salt? _____
- **b** What type of compound is sucrose? _____
- **c** What type of molecule is iodine? _____
- **d** What type of molecule is unknown A (polar ionic or nonpolar)? _____
- **e** What type of molecule is unknown B (polar ionic or nonpolar)? _____

Exercise 2-5

DNA Extraction

MATERIALS

- ❑ 50 mL beaker
- ❑ Test tube
- ❑ Glass stirring rod
- ❑ Graduated cylinder
- ❑ Pea mixture
- ❑ Isopropyl alcohol
- ❑ Meat tenderizer
- ❑ Liquid detergent
- ❑ Wooden applicator stick

The chemical **deoxyribonucleic acid** (dee-awks-ee-ry-boh-noo-KLAY-ik), or **DNA**, which contains the instructions for building nearly every protein in an organism, is located in the nucleus of nearly all cells (mature red blood cells are an exception). DNA is composed of two strands held together in a double helix by hydrogen bonds (Fig. 2.9). It consists of subunits called **nucleotides**, which are composed of three parts: (1) a nitrogenous base, (2) the five-carbon sugar *deoxyribose*, and (3) a phosphate group. There are four nitrogenous bases: **adenine** (**A**), **guanine** (**G**), **cytosine** (**C**), and **thymine** (**T**). The DNA of every organism on this planet, from humans to bacteria, contains these four nitrogenous bases. It is the small differences in DNA from one organism to another that account for the vast diversity we see among species.

DNA extraction and analysis have become commonplace in the search for diagnoses of genetic diseases, our evolutionary history, and many other topics in science and medicine. DNA analysis requires specialized equipment, but DNA extraction is surprisingly simple and can be performed using things you have around the house.

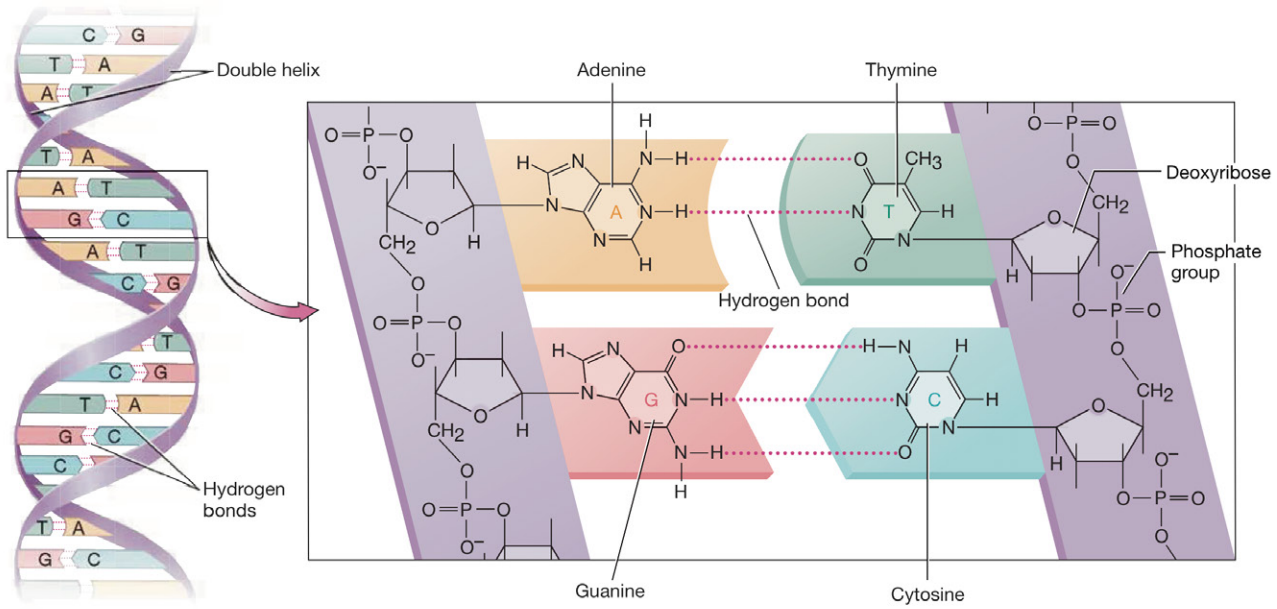

FIGURE **2.9** Deoxyribonucleic acid (DNA).

2

Procedure 1 DNA Extraction

In this exercise, we will be extracting DNA from dried green peas. Although this obviously is not animal DNA, keep in mind that it is composed of precisely the same nucleic acid bases as animal DNA, and that the plant cell membrane is composed of phospholipids, like that of animal cells. The first part of the extraction involves removing the DNA from the cell and the nucleus using a mild detergent. Then you will use enzymes to degrade the proteins around the DNA and free up the nucleic acids. Finally, you will take advantage of DNA's weak polarity to extract it from strongly polar water into weakly polar isopropyl alcohol. When you have completed the activity, answer Check Your Understanding question 7 (p. 58).

Safety Note

Safety glasses and gloves are required!

1. Obtain about 10 mL of the blended pea mixture (which contains only dried peas and water), and scoop it into a 50 mL beaker.
2. Add 1.6 mL of liquid detergent to the pea soup. Stir gently with a glass stirring rod, and let the mixture sit undisturbed for 5 to 10 minutes.
3. After 5 to 10 minutes, fill about one-third of a test tube with the pea-soap mixture.
4. Add a pinch of meat tenderizer (which contains enzymes) to the test tube, and stir with a glass stirring rod *very gently* (rough stirring will break up the DNA, making it harder to see).
5. Tilt the test tube, and slowly add isopropyl alcohol with a dropping pipette (or directly from a plastic squeeze bottle) so the alcohol forms a layer on the top of the pea mixture. The amount of alcohol you add should be approximately equal to the volume of the pea mixture.
6. Watch as the DNA (it looks like long, stringy stuff) rises to the alcohol layer (Fig. 2.10).
7. Use an applicator stick to fish out the DNA, and set it on a paper towel. Voila! You have just extracted DNA!

FIGURE **2.10** Extracted DNA in alcohol.

Name _____

Section _____ Date _____

Check Your Recall

REVIEW

1 *Fill in the blanks:* An acidic solution has a pH value of _____, a neutral solution has a pH value of _____, and a basic (alkaline) solution has a pH value of _____.

2 Adding hydrogen ions to a solution will make the solution more _____, and its pH will _____.

a. acidic; increase
b. basic; increase
c. acidic; decrease
d. basic; decrease

3 What does a buffer do when hydrogen ions are added to a solution?

a. The buffer keeps the pH of a solution neutral.
b. The buffer releases base ions.
c. The buffer releases additional hydrogen ions.
d. The buffer binds the hydrogen ions to remove them from the solution.

4 Which of the following statements about chemical reactions is false?

a. The rate of a chemical reaction increases when temperature decreases.
b. A chemical reaction occurs when chemical bonds are formed, broken, or rearranged.
c. A chemical reaction occurs when electrons are transferred between molecules.
d. All of the above are true.

5 How does an enzyme affect the rate of a chemical reaction?

_____

_____

6 An enzyme that has lost its shape

a. is denatured and no longer functional.
b. is denatured but still functional.
c. is not different from a regular enzyme as shape is not important.
d. can be restored by extreme temperatures or pH swings.

7 *Fill in the blanks:* Electrons are _____ in an ionic bond, whereas they are _____ _____ in a polar covalent bond, and _____ _____ in a nonpolar covalent bond.

8 Predict whether each of the following has ionic, polar covalent, or nonpolar covalent bonds.

LiCl _____

Cl_2 _____

$CHCl_3$ _____

$C_5H_{10}O_5$ _____

KBr _____

C_2H_8 _____

9 *Fill in the blanks:* A substance that dissolves in water is called _____, and a substance that will not dissolve in water is called _____.

10 Which of the following molecules would you expect to not dissolve in water?

a. Polar molecules.
b. Ionic molecules.
c. Nonpolar molecules.
d. Both a and b are correct.
e. Both a and c are correct.

Name _____

Section _____ Date _____

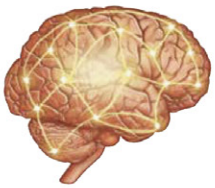

Check Your Understanding

REVIEW

Critical Thinking and Application Questions

1 The normal pH of the blood is 7.35–7.45. Is this pH acidic, neutral, or basic? Explain.

2 Ms. Young presents to the emergency department in respiratory distress. The respiratory therapist measures the pH of her blood and determines that it is 7.15. Is the pH of her blood more acidic or more basic than normal? Has the number of hydrogen ions in her blood increased or decreased? Explain.

3 Your lab partner argues with you that if you add a buffer to a solution, it will make the solution neutral. Is he correct? What do you tell him?

4 You may have read about "alkaline diets" that claim that you need to eat only alkaline foods in order to remain healthy. According to this philosophy, eating acidic foods "acidifies the blood," leading to disease. But our blood has several buffer systems in place. Explain what happens when buffers encounter additional hydrogen ions from foods. Will the pH of the blood decrease?

5 You take the boiled lipase from Exercise 2-3 (p. 47) and compare its structure to normal, unboiled lipase. You note that the two structures differ. Why are they different? How does this help to explain your results?

6 An *embolus* is a piece of a clot that lodges in a blood vessel, blocking the flow of blood through that vessel. Most emboli are composed of hydrophilic substances that can be dissolved into the water of blood relatively easily. However, two types of emboli—air emboli and fat emboli—are particularly dangerous and difficult to treat because both are composed of hydrophobic substances. Why do you think hydrophobic emboli are more difficult to break apart in the water-based environment of blood?

7 You could use the same procedure that you used here to extract DNA from any source—your own cells, your dog, a strawberry, or a bacterial culture. Why would this procedure work with the DNA from any other living organism?

UNIT
3

Introduction to the Microscope

Once you have completed this unit, you should be able to:

1. Identify the major parts of the microscope.
2. Define the magnification of high, medium, and low power.
3. Demonstrate proper use of the microscope.
4. Practice focusing on low, medium, and high power.
5. Define depth of field.

Blood sample being examined by a light microscope.

3

EXERCISES

Working with the microscope and slides seems to be one of the least favorite tasks of anatomy and physiology students. But with a bit of help, a fair amount of patience, and a lot of practice, the use of microscopes becomes progressively easier with each unit.

Exercise 3-1

Introduction to the Microscope

MATERIALS

- ❑ Light microscopes with three objective lenses
- ❑ Introductory slides (letter "e" and three colored threads)
- ❑ Fetal pigs or other preserved small mammals
- ❑ Sterile cotton swabs
- ❑ Methylene blue dye
- ❑ Glass slide (blank)
- ❑ Distilled water
- ❑ Coverslip

The microscopes that you will use in this lab are called **light microscopes** (Fig. 3.1). This type of microscope shines light through the specimens to illuminate them, and the light is refracted through objective lenses to magnify the image. Light microscopes have the following components:

- **Ocular lens.** The **ocular lens** (AWK-yoo-lur) is the lens through which you look to examine the slide. It generally has a 10× power of magnification, meaning it magnifies the image you are examining 10 times. The microscope may have one ocular lens (a **monocular** microscope) or two ocular lenses (a **binocular** microscope). Many ocular lenses have pointers that can be moved by rotating the black **eyepiece**. The area of the slide visible when you look into the ocular is known as the **field of view**.
- **Objective lenses.** The **objective lenses** are lenses with various powers of magnification. Most microscopes have low (4×), medium (10×), and high (40×) power objective lenses. Note that sometimes the 4× objective is referred to as the scan objective. On such microscopes, the 10× objective is actually called the low-power objective. The objective lenses are attached to the **nosepiece**, which allows the user to switch between objectives. Certain microscopes have a higher power objective (100×), called the **oil immersion lens**, which requires that a drop of oil be placed between the slide and objective lens. Without this drop of oil, you will not be able to focus the image.
- **Stage.** The **stage** is the surface on which the slide sits. It typically has stage clips to hold the slide in place. The stage on many microscopes is moveable using the **mechanical stage adjustment knob**. Others require you to move the slide manually.
- **Arm.** The **arm** supports the body of the microscope and typically houses the adjustment knobs.
- **Coarse adjustment knob.** The large knob on the side of the arm is the **coarse adjustment knob**. Turning it moves the stage up and down to change the distance of the stage from the objective lenses. It allows gross focusing of the image.
- **Fine adjustment knob.** The smaller knob underneath the coarse adjustment knob is the **fine adjustment knob**. Turning it allows fine-tuning of the image's focus. Note that occasionally the fine adjustment knob is situated on top of the coarse adjustment knob.
- **Lamp.** The **lamp**, also called the *illuminator*, provides the light source. It rests on the base of the microscope. Light from the lamp is focused on the specimen by the **condenser**, a lens that sits under the stage.
- **Iris diaphragm.** On the underside of the stage is an adjustable wheel called the **iris diaphragm** that controls the amount of light allowed to pass through the slide. The iris diaphragm is important to check when you are focusing on an image, as too much light will wash the image out, and too little light will make it harder to see details. You may also be able to adjust the amount of light coming into the image with a **light adjustment dial** (or knob), which is found on the arm or base of the microscope. This dial allows you to control the brightness of the lamp.

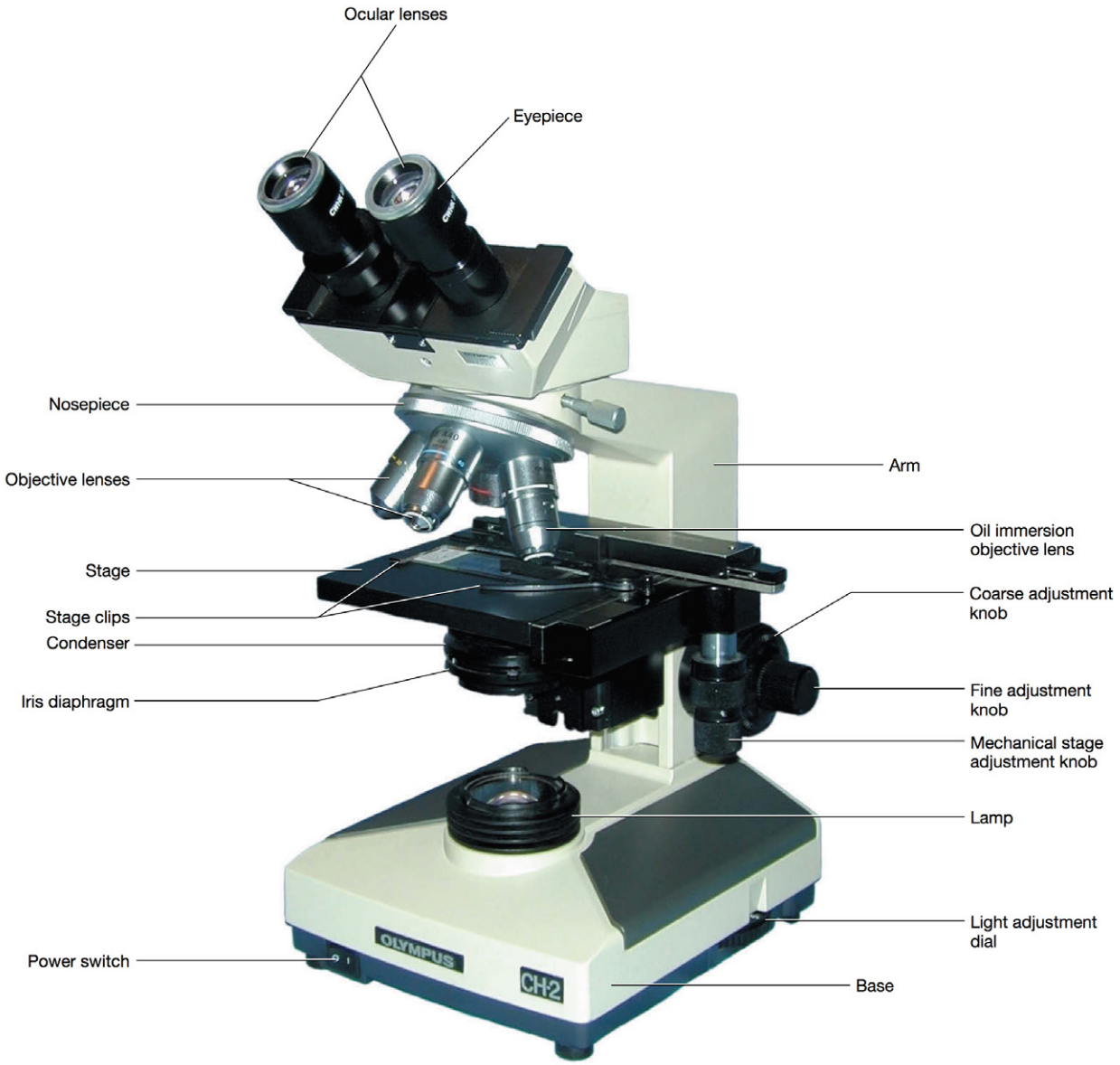

FIGURE **3.1** Compound light microscope.

3

Check Your Recall

1 *Matching:* Match the following terms with the correct definition from the column.

_____ Ocular lens	A. The surface on which the slide sits
_____ Iris diaphragm	B. The microscope's light source
_____ Condenser	C. Allows fine-tuning of the focus
_____ Objective lens	D. The lens through which you look to view the slide
_____ Coarse adjustment knob	E. Lens under the stage that focuses light from the lamp on the specimen
_____ Stage	F. Controls the amount of light that passes through the slide
_____ Fine adjustment knob	G. Moves the stage up and down; provides gross focusing
_____ Lamp	H. Lenses of various powers of magnification

2 *Fill in the blank:* Magnification of the ocular lens is usually _____.

3 The lens that provides 100× magnification is the

a. low-power lens.
b. medium-power lens.
c. high-power lens.
d. oil immersion lens.

Procedure 1 Magnification

Light is refracted through two lenses to obtain magnification—the ocular lens and the objective lens. Magnification of the ocular lens is usually 10×. This means that if you were to view a slide with only the ocular lens, the image would be magnified 10 times. Magnification of the objective lenses varies, but typically is 4× for low power, 10× for medium power, and 40× for high power. (To verify that this is the case for your microscope, look at the side of the objective lens, which usually is labeled with its magnification.) Remember that oil immersion provides even greater magnification at 100×. When calculating the total magnification, you must multiply the magnification of the ocular lens (10) by the power of the objective lens.

Fill in Table 3.1 to determine total magnification at each of the different objective lenses on your microscope. Remember that the magnification of the objective lens is usually printed on the side of the lens itself.

TABLE **3.1** Total Magnification at Each Power

Magnification of Ocular Lens	Power	Magnification of Objective Lens	Total Magnification
	Low		
	Medium		
	High		
	Oil Immersion		

As I'm certain your professor will tell you, microscopes are expensive! Care must be taken to ensure that the microscopes stay in good working condition. Taking proper care of microscopes makes the histology sections of your labs run more smoothly, and also ensures that you stay on your lab instructor's good side. Keeping that in mind, following are some general guidelines for handling the microscopes:

- Use two hands to support the microscope when carrying it—one hand to hold the arm and the other hand to support the base.
- Gather up the cord so it does not dangle off the lab table after you have plugged in the microscope. This will help to prevent people from tripping over loose cords.
- Clean the lenses with lens paper only. Do not use paper towels or cloth to clean a lens, because this will scratch its surface.
- Make sure the *lowest* power objective is in place before you begin. This will prevent you from cracking the slide and possibly the lens.
- Get the image in focus on low power, then switch to higher power and adjust with the **fine** adjustment knob. Be careful not to use the coarse adjustment knob with the high-power objective in place, because you could break the slide and damage the lens.
- When you are finished with the microscope, turn the nosepiece to the lowest power objective, and remove the slide. Be sure to clean off the objective if you used oil, because oil left on the objective tends to harden. Turn off the power to the microscope, and unplug it. This will decrease the chances of a blown bulb or fuse next time the microscope is used. Before putting the microscope away, wrap the electrical cord around the base or secure with a Velcro strap, and cover it with a dust cover.

If you follow these general guidelines, you can rest assured that the microscopes (and your grade) will not suffer any harm.

3

Check Your Recall

4 Before you begin, you should make sure that

a. the objective lens is switched to the highest-power magnification.
b. the lamp is turned to its full brightness.
c. the ocular lens is switched to the highest-power magnification.
d. the objective lens is switched to the lowest-power magnification.

5 Which knob should you use to get the image in focus when using the higher-power objective lenses?

a. The coarse adjustment knob.
b. The fine adjustment knob.
c. The iris diaphragm.
d. The light adjustment dial.

6 What should you use to clean the lenses?

HINTS & TIPS

How to Determine the Types of Bonds in a Molecule

Before you try to focus the microscope, read the following hints and tips to make it easier.

- **Always start on low power.** You are supposed to start on low power anyway, to avoid damaging the objective lenses. Sometimes, though, students forget, and jump straight to medium or high power. This risks damaging the lenses and also makes it harder on you. Bear in mind that most slides will have more than one histological or cellular structure on each slide. Starting on low power allows you to scroll through a large area of the slide, and then focus in on the desired part of the section.
- **Make sure the specimen is over the condenser.** This tip may sound simplistic, but I can't count the number of times that my students have declared in frustration that the slide is blank because they either forgot to move the stage around or the specimen is small and they couldn't find it. The easy solution to this problem is to examine the slide with the naked eye first, and then place it on the stage so that the specimen is right over the condenser (the light). This way, you are guaranteed to see something when you look through the ocular.
- **Beware of too much light.** It is easy to wash out the specimen with too much light. If you are having difficulty making out details, first adjust the focus with the fine adjustment knob. If this doesn't help, use the iris diaphragm to reduce the amount of light illuminating the specimen. This will increase the contrast and allow you to observe more details. It also helps to reduce headaches and eyestrain.
- **Keep both eyes open.** It is tempting to close one eye when looking through a monocular microscope. Admittedly, keeping both eyes open isn't easy at first, but it helps to reduce eyestrain and headaches.
- **Compare your specimen to the photos in your lab manual.** Although the slides you are examining will not necessarily be identical to the photos in this book, they should be similar in appearance. Generally speaking, if you are looking at something that is vastly different from what is in this book, you probably should move the slide around a bit or change to a different power objective to find the correct tissue or cell type on the slide. Other good sources for micrographs include atlases, your textbook, and images on the Internet.
- **Remember that the slides aren't perfect.** Not all slides will clearly demonstrate what you need to see. Some aren't stained adequately or properly. Some are sectioned at a funny angle. Some don't contain all of the tissue or cell types you need to see. What should you do about this? See the next hint for the answer.
- **Look at more than one slide of each specimen.** This will help you in the face of subpar slides and also will assist you overall in gaining a better understanding of the specimens you are examining.
- **Draw what you see.** Although you may tend to resist drawing, even the most basic picture is helpful for two reasons. First, it allows you to engage more parts of your brain in the learning process. The more areas of your brain engaged, the better are the chances you will retain the information. Also, drawing is helpful in that you actually have to look at the specimen long enough to draw it.
- **Have patience!** It really does get easier. Don't get frustrated, and don't give up. By the end of the semester, you may come to appreciate the microscope and the fascinating world it reveals.

3

Check Your Recall

7 What should you do if your slide looks dramatically different from the slide in your lab manual?

8 If you are having trouble making out details on your slide, what can you do?

a. Adjust the focus with the fine adjustment knob.
b. Reduce the amount of light with the iris diaphragm.
c. Both a and b.
d. Neither a nor b.

Procedure 2 Focusing the Microscope

Now that we know how to handle the microscope properly, let's practice using it. We will start with a simple slide: an image of a newsprint letter "e."

1 Obtain a slide of the letter "e."

2 Examine the letter "e" slide macroscopically (with the naked eye) before placing it on the stage. How is the "e" oriented on the slide? Is it right side up, upside down, backward, etc.?

3 Switch the nosepiece to the low-power objective, place the slide on the stage, and secure it with the stage clips. Move the slide using the stage adjustment knob until the "e" is over the condenser.

4 Use the coarse adjustment knob to bring the slide into focus slowly. Once it is grossly in focus, use the fine adjustment knob to sharpen the focus. Note that you might need to adjust the iris diaphragm to allow more light to pass through the specimen, as the newsprint is relatively thick. How is the "e" oriented in the field of view? Is it different from the way it was when you examined it in item 2?

5 Move the nosepiece to medium power. You should only have to adjust the focus with the fine adjustment knob; no adjustment of the coarse focus should be necessary.

6 Once you have examined the slide on medium power, move the nosepiece to high power. Again, focus only with the fine adjustment knob.

Wasn't that easy?

Check Your Recall

9 What are the steps you should use to focus the image on the slide?

Procedure 3 Depth of Field

At times you will look at a slide and see something brown or black and kind of neat-looking with interesting swirls and specks. What is this fascinating discovery you've made? It's dirt on top of the slide. This happens because students tend to focus the objective on the first thing they can make out, which usually is the top of the coverslip on the slide, and this has a tendency to be dirty.

These "dirt discoveries" can be avoided by appreciating what is known as **depth of field**. Also called the *depth of focus*, the depth of field is the thickness of a specimen that is in sharp focus. Thicker specimens will require you to focus up and down to look at all levels of the specimen. This takes practice and skill. Let's get some practice doing this. Here we will use a slide that has three differently colored threads stacked on top of one another.

1 Obtain a slide with three colored threads. The threads are located on the slide at varying depths, and you will have to focus on each thread individually.

2 Examine the slide macroscopically prior to putting it on the stage.

3 Switch the nosepiece to the low-power objective, place the slide on the stage, and secure it with the stage clips. Move the slide using the stage adjustment knob until the threads are in your field of view.

4 Use the coarse adjustment knob to get the slide into focus on low power.

5 Switch to medium power, and use the fine adjustment knob to sharpen the focus. Which thread(s) is (are) in focus?

6 Move the objective up and down slowly with the coarse adjustment knob, focusing on each individual thread. Figure out which color thread is on the bottom, in the middle, and on the top, and write the color order here:

Bottom _____

Middle _____

Top _____

Check Your Recall

10 What is the depth of field?

Procedure 4 Preparing a Cell Sample

Now let's do some actual laboratory microscopy. In this procedure, you will prepare what is known as a cell smear (Fig. 3.2). To prepare a cell smear, obtain a sample of cells (in this case from the mouth) with a cotton applicator swab and "smear" these cells on a blank slide. However, cells and cell structures aren't visible unless they are first stained, so the next step in preparing a smear is to apply a stain, in this case methylene blue, to the sample.

Safety Note

Safety glasses and gloves are required! ***Methylene blue stains hands and clothes readily.***

1 Obtain a blank slide and a coverslip.

2 Clean the slide with lens paper.

3 Swab the inside of your cheek with a sterile cotton swab. As an alternative, swab the inside cheek of a fetal pig or other preserved small mammal. Do not get large chunks of tissue on the swab, or individual cells will not be visible.

4 Wipe the swab with the cheek cells on the blank slide. If you are using your own cheek cells, dispose of the swab in a biohazard bag.

5 Place one drop of methylene blue dye onto the slide. Wait 1 minute.

6 Rinse the dye off the slide with distilled water and pat dry. The blue dye should be barely visible on the slide. If you see large areas of blue, rinse the slide again, or get a new sample of cheek cells.

7 Place a coverslip over the stained area, and place the slide on the stage of a microscope. Focus the image grossly on low power, then switch to the high power objective lens to find individual cells (use oil immersion if available).

8 Identify and draw some of the cells in your smear in the space provided.

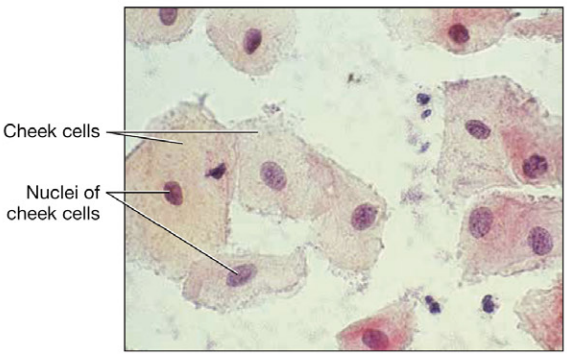

FIGURE **3.2** Cell smear.



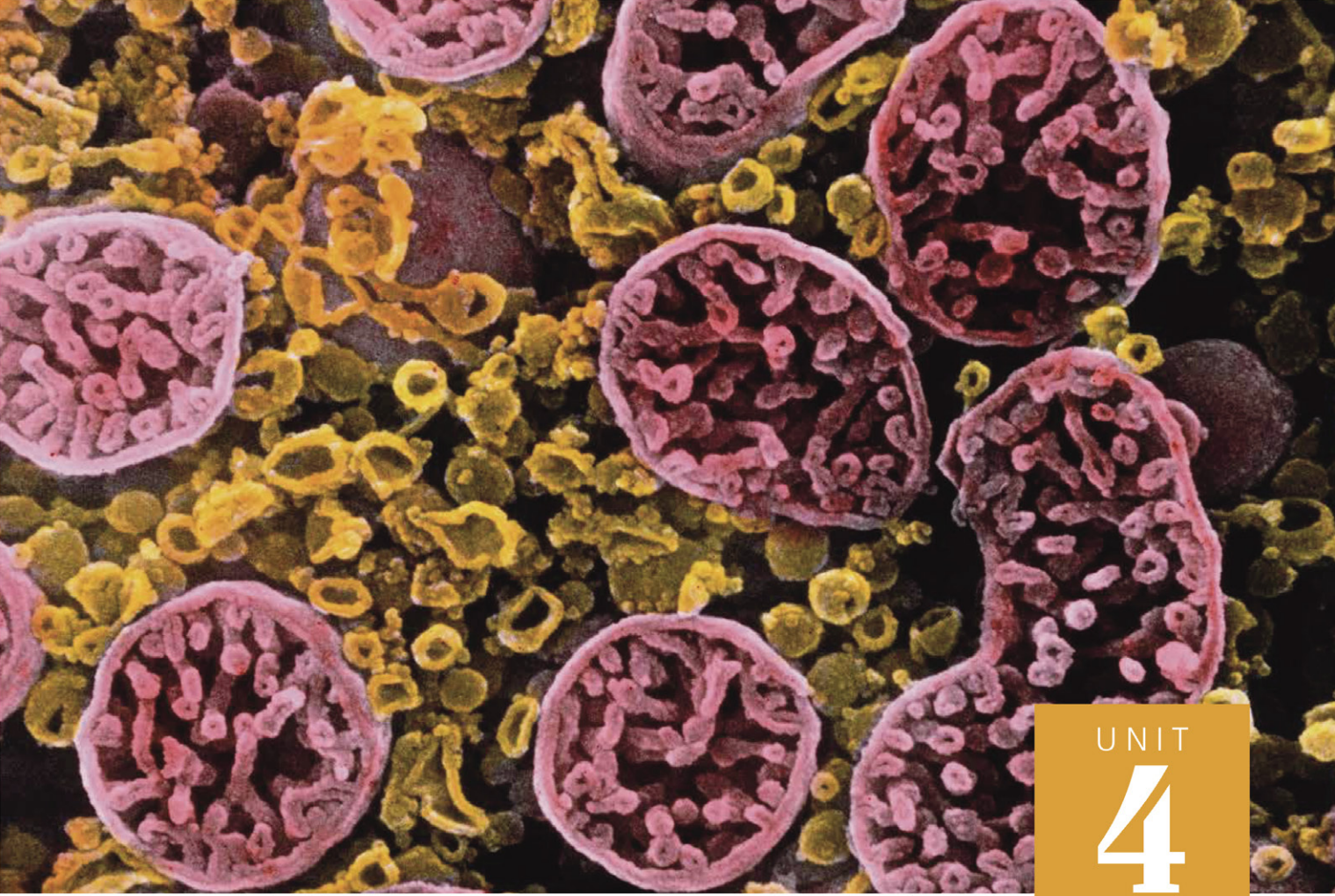

UNIT
4

Cytology

Once you have completed this unit, you should be able to:

1. Identify parts of the cell and organelles.
2. Describe the processes of diffusion and osmosis.
3. Describe the effects of hypotonic, isotonic, and hypertonic environments on cells.
4. Identify the stages of the cell cycle and mitosis.

Name _____ Section _____ Date _____

PRE-LAB EXERCISES

Complete the following exercises prior to coming to lab, using this lab manual and your textbook for reference.

4

Pre-Lab Exercise 4-1



Key Terms

You should be familiar with the following terms before coming to lab.

Term	Definition

Cell Structures and Organelles

Plasma membrane _____

Cytoplasm _____

Nucleus _____

Nucleolus _____

Mitochondrion _____

Ribosome _____

Peroxisome _____

Smooth endoplasmic reticulum _____

Rough endoplasmic reticulum _____

Golgi apparatus (or complex) _____

Lysosome _____

Name _____ Section _____ Date _____

Centriole _____

Cilia _____

Flagella _____

Vesicle _____

Membrane Transport

Diffusion _____

Osmosis _____

Tonicity _____

Cell Cycle and Mitosis

Cell cycle _____

Interphase _____

Mitosis _____

Pre-Lab Exercise 4-2

The Plasma Membrane

Label and color the parts of the plasma membrane in Figure 4.1 with the terms from Exercise 4-1 (p. 75). Use your text and Exercise 4-1 in this unit for reference.

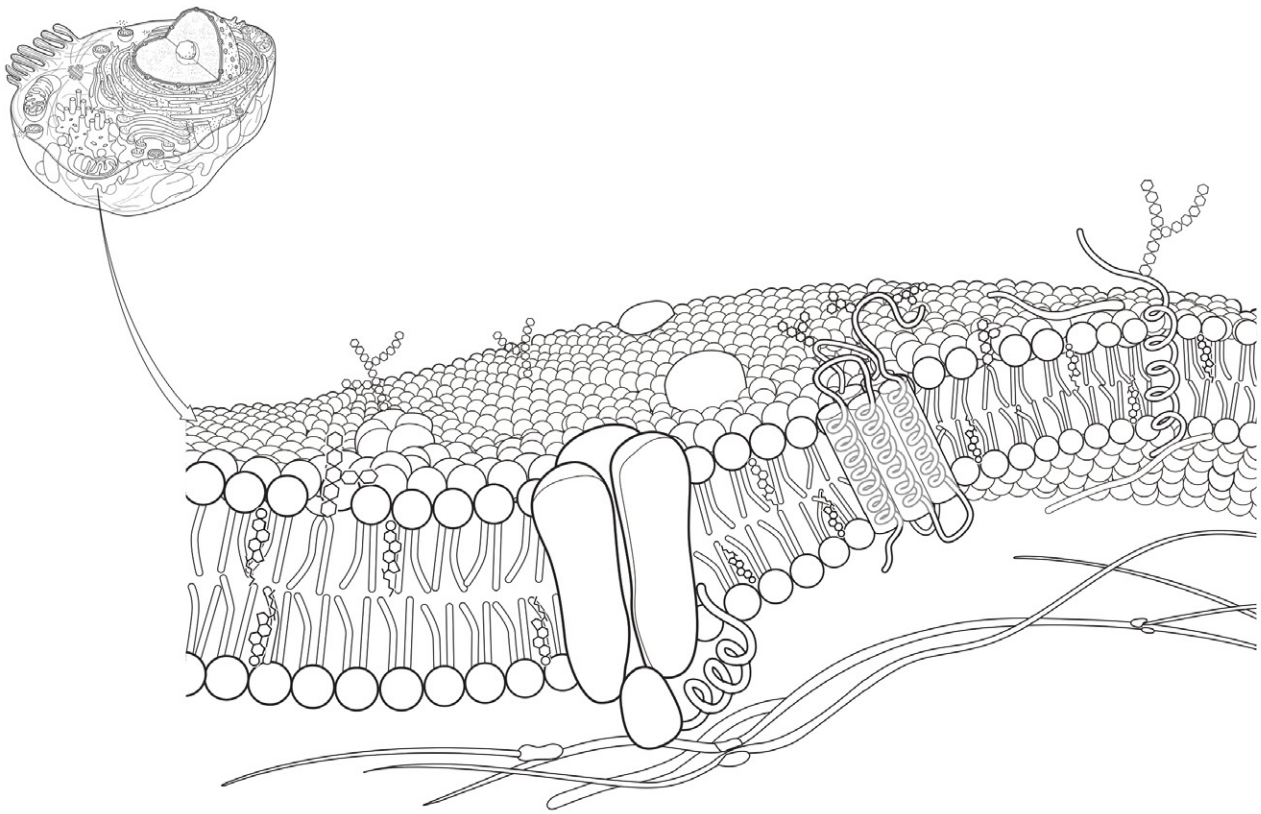

FIGURE 4.1 Plasma membrane.

Name _____ Section _____ Date _____

Pre-Lab Exercise 4-3

The Parts of the Cell

Label and color the parts of the cell in Figure 4.2 with the terms from Exercise 4-1 (p. 75). Note that you may not see all structures in this diagram. Use your text and Exercise 4-1 in this unit for reference.

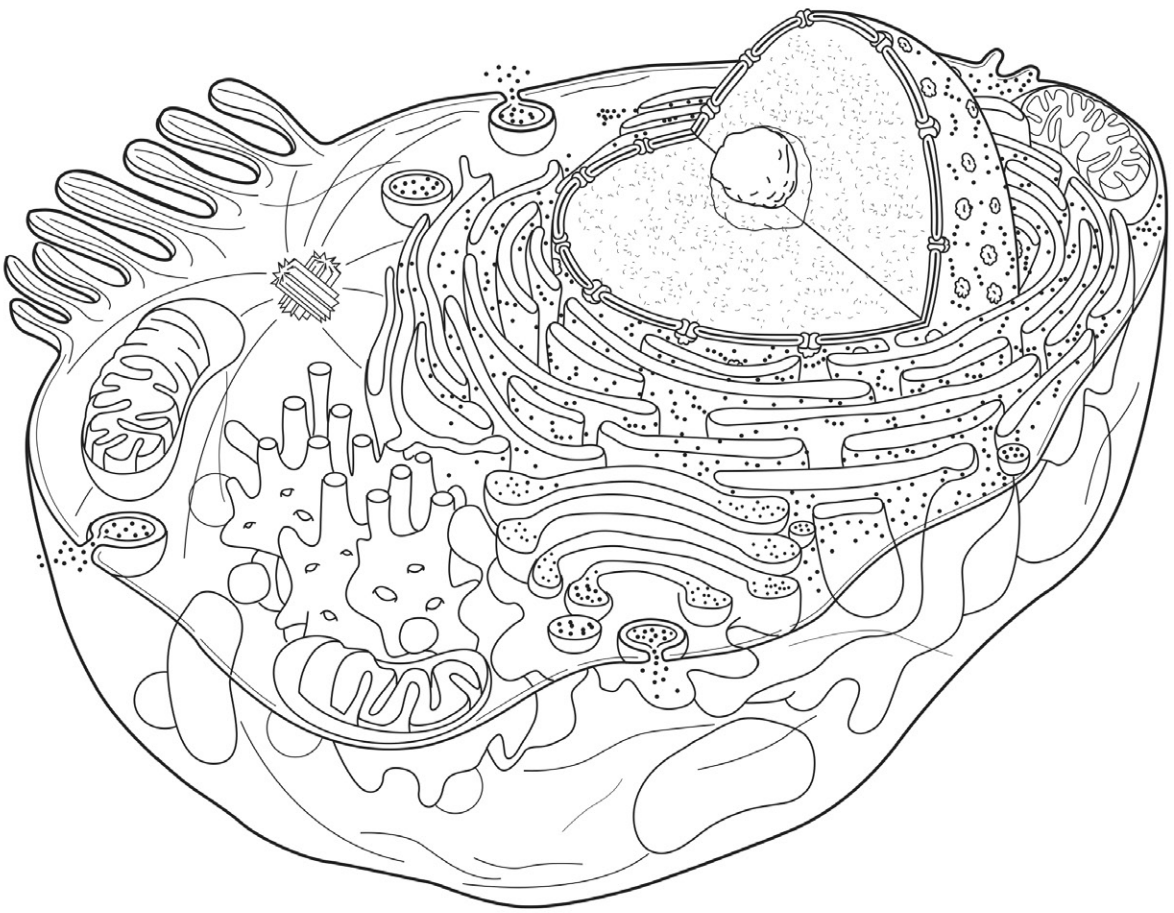

FIGURE 4.2 Generalized cell.

Pre-Lab Exercise 4-4



The Cell Cycle

Use your text and lab manual to answer the following questions about the cell cycle and mitosis.

1. Describe the following stages of the cell cycle:

a. G_1: _____

b. S: _____

c. G_2: _____

d. M: _____

2. Describe the events occurring in the cell in each of the phases of mitosis in Table 4.1.

TABLE **4.1** Stages of Mitosis

Stage of Mitosis	Events Taking Place in the Cell	Cell Appearance
Prophase		
Metaphase		
Anaphase		
Telophase		

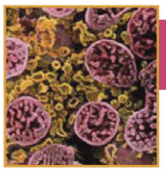

SEM of mitochondria and smooth endoplasmic reticulum in an ovarian granulosa-lutein cell.

EXERCISES

We now move on to the next level of organization: the **cell**, the smallest unit of life. This unit introduces you to the cell, its structures, and how the cell reproduces itself via the process of cell division. We also examine two important physiological processes that occur at the chemical and cellular level: *diffusion* and *osmosis*.

Note that this is the first unit in which you will use a *Model Inventory*—something you will use throughout this lab manual. In this inventory you will list the anatomical models or diagrams that you use in lab—if the model is not named, make up a descriptive name for it. You will then record in a table the structures you are able to locate on each model. This is particularly helpful for study purposes, as it allows you to return to the proper models to locate specific structures.

In this unit you will also do your first "Time to Draw" exercise, in which you sketch and label one of your anatomical models. Now, I know that a lot of you might not see the point of drawing. But give it a try. Studies have shown that drawing anatomical structures helps you form a mental map of what you've learned and helps you to better remember it. If you're still hesitant to draw, know that your drawings don't have to be works of art—a simple sketch is all that's needed.

Exercise 4-1

Organelles and Cell Structures

MATERIALS

- ❑ Cell models and diagrams
- ❑ Light microscope
- ❑ Cell slides (with red blood cells, skeletal muscle, and sperm cells)
- ❑ Colored pencils

Most cells in the body are composed of three basic parts—the plasma membrane, the cytoplasm, and the nucleus.

1. **Plasma membrane.** The **plasma membrane** is the outer boundary of the cell (Fig. 4.3). As you can see in Figure 4.3, it is composed of a **phospholipid bilayer** (FAHS-foh-lip-id). Notice that the two rows of phospholipids are aligned so that their nonpolar fatty acid tails face one another and their polar phosphate heads face the water-containing fluids inside and outside of the cell. There are multiple components interspersed throughout the phospholipid bilayer, including **integral proteins**, which span the width of the membrane; **peripheral proteins**, which are located on only one face of the membrane; **cholesterol**, a steroid that stabilizes the membrane's structure in the face of changing temperatures; and **glycoproteins** (GLY-koh-proh-teenz) and **glycolipids**, which function in cell recognition. The plasma membrane is a dynamic, fluid structure that acts as a selectively permeable barrier, meaning that it only allows certain solutes to pass into or out of the cell. In parts of the body where rapid absorption is necessary, the plasma membrane is folded into projections called **microvilli** (my-kroh-VIL-aye), which increase its surface area.

2. **Cytoplasm.** The **cytoplasm** (SY-toh-plaz-m) is the material inside the cell. It consists of three parts: **cytosol** (SY-toh-sahl), the **cytoskeleton**, and **organelles** (ohr-gan-ELLZ; Fig. 4.4).

   a. **Cytosol** is the fluid portion of the cytoplasm and contains water, solutes, RNA enzymes, and other proteins.

   b. The **cytoskeleton** is a collection of protein filaments including actin filaments, intermediate filaments, and microtubules. **Actin filaments** are small filaments, many of which are located along the plasma membrane and in the core of microvilli, that help maintain the shape of the cell and function in cell movement. The larger **intermediate filaments** are ropelike structures that help maintain the shape of the organelles and the nucleus and give the cell mechanical strength. **Microtubules**, the largest filaments, are hollow tubes that maintain the shape of the cell; hold organelles in place, move substances within the cell, and function in cell division. In addition, microtubules form the core of motile extensions from the cell called cilia (SIL-ee-uh) and flagella (flah-JEL-uh). **Cilia** are small, hairlike extensions that beat rhythmically together to propel substances past the cell. **Flagella** are single extensions that propel the cell itself (sperm cells are the only flagellated cells in the human body).

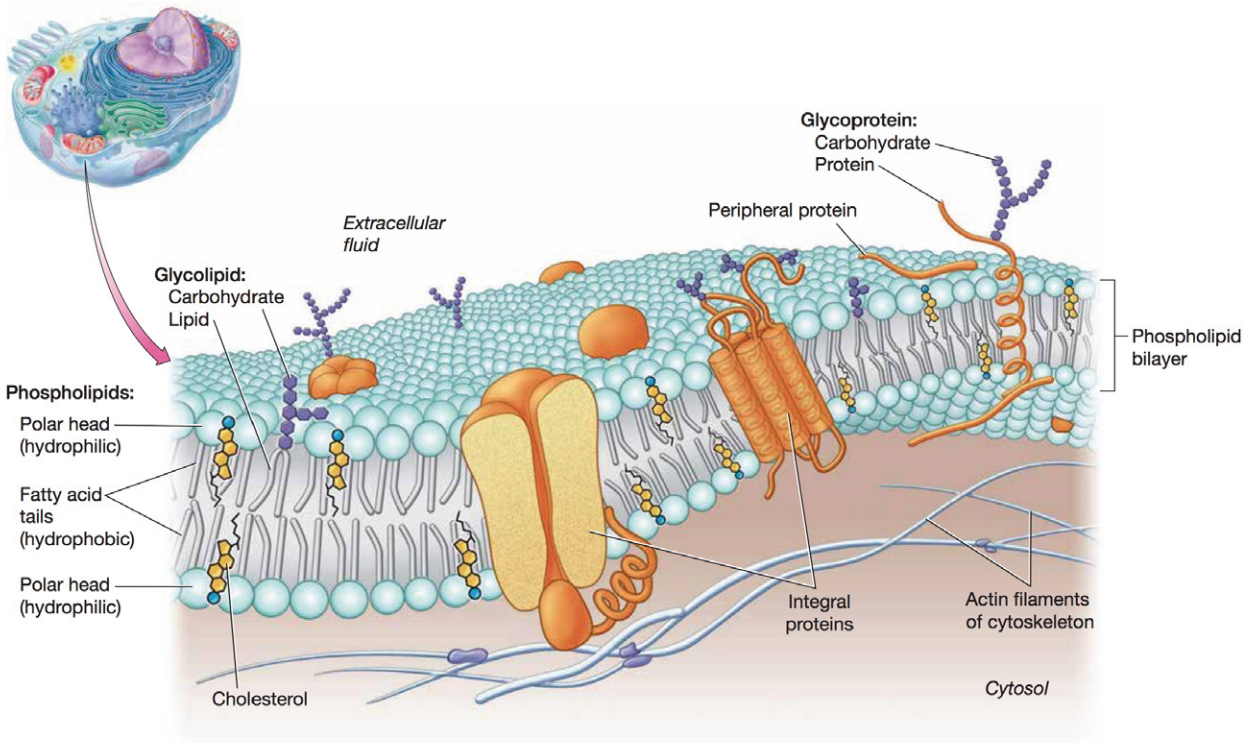

FIGURE **4.3** Plasma membrane.

c. **Organelles** are specialized cellular compartments that carry out a variety of functions. The organelles we cover in this unit include the following:

- **Ribosomes.** The small, granular **ribosomes** (RY-boh-zohmz) are composed of two subunits. Some ribosomes float freely in the cytosol, whereas others are bound to the membrane of another organelle or the nucleus. They are one of the few organelles that are not enclosed by a membrane. Ribosomes are the sites of protein synthesis in the cell.
- **Peroxisomes.** The small, vesicular organelles known as **peroxisomes** (per-AWKS-ih-zohmz) are small, round membrane-enclosed sacs. They contain enzymes that catalyze reactions to detoxify chemicals produced by cellular reactions, metabolize fatty acids, and synthesize certain phospholipids.
- **Mitochondria.** The bean-shaped **mitochondria** (my-toh-KAHN-dree-ah) produce the bulk of the cell's ATP (energy). Notice in Figure 4.5 that they are surrounded by a double plasma membrane that encloses a central space called the **matrix.** Within the matrix we find numerous enzymes, circular mitochondrial DNA, and ribosomes.
- **Endoplasmic reticulum.** The series of membrane-enclosed sacs known as the **endoplasmic reticulum** (en-doh-PLAZ-mik reh-TIK-yoo-lum) may be of two types: **rough endoplasmic reticulum,** or **RER,** which has ribosomes on its surface, and **smooth endoplasmic reticulum,** or **SER,** which lacks ribosomes. The RER modifies proteins that the ribosomes have made. The SER has multiple functions, including lipid synthesis and detoxification reactions.
- **Golgi apparatus.** The **Golgi apparatus** (GOHL-jee) is a stack of flattened sacs near the RER. Its membrane-enclosed sacs receive vesicles from the RER and other places in the cell and process, modify, and sort the products within the vesicles.
- **Lysosomes. Lysosomes** (LY-soh-zohmz) are membrane-enclosed vesicular organelles filled with digestive enzymes that catalyze reactions that digest particles brought into the cell, old and worn-out organelles, and even the cell itself.

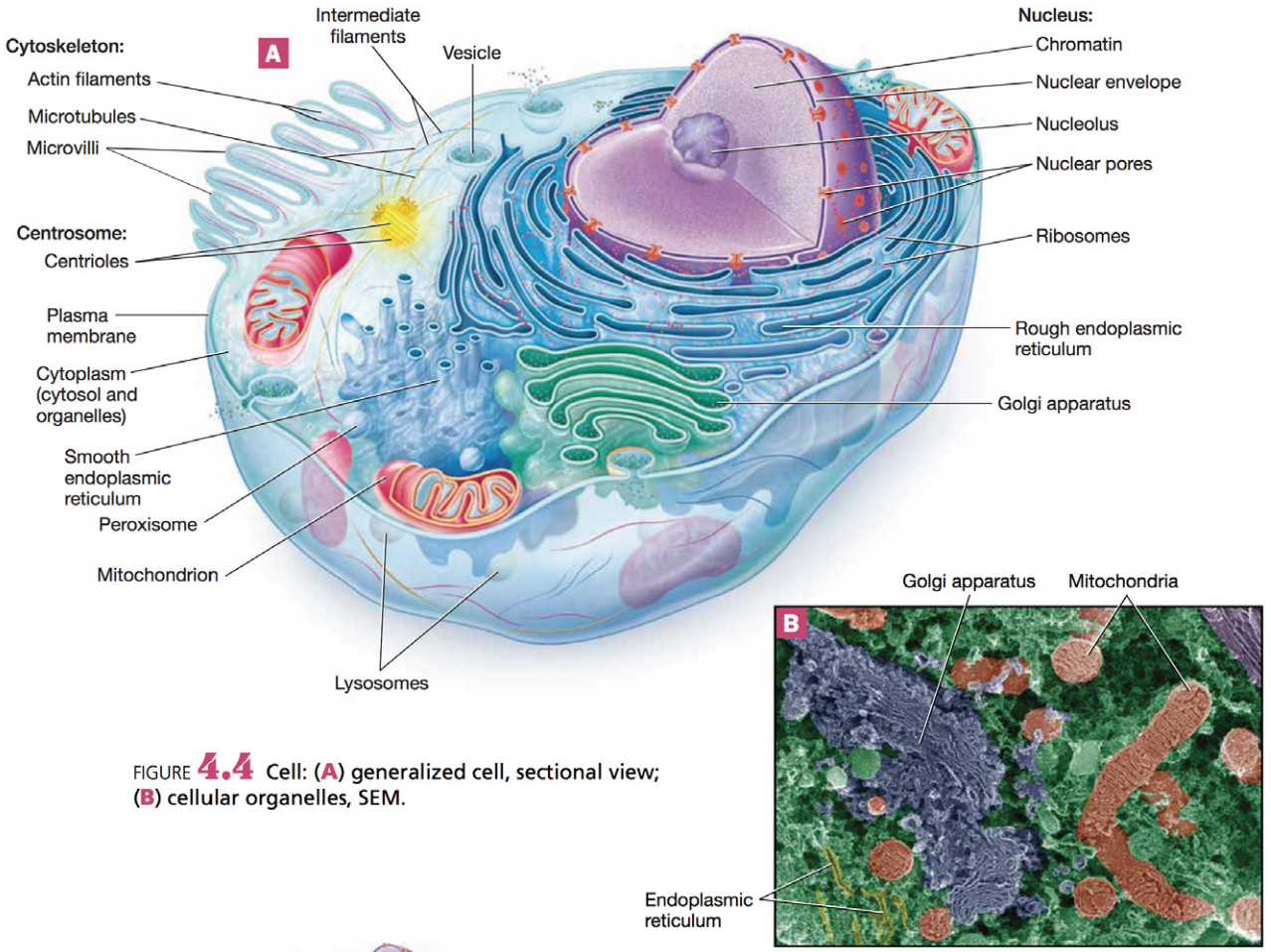

FIGURE **4.4** Cell: (A) generalized cell, sectional view; (B) cellular organelles, SEM.

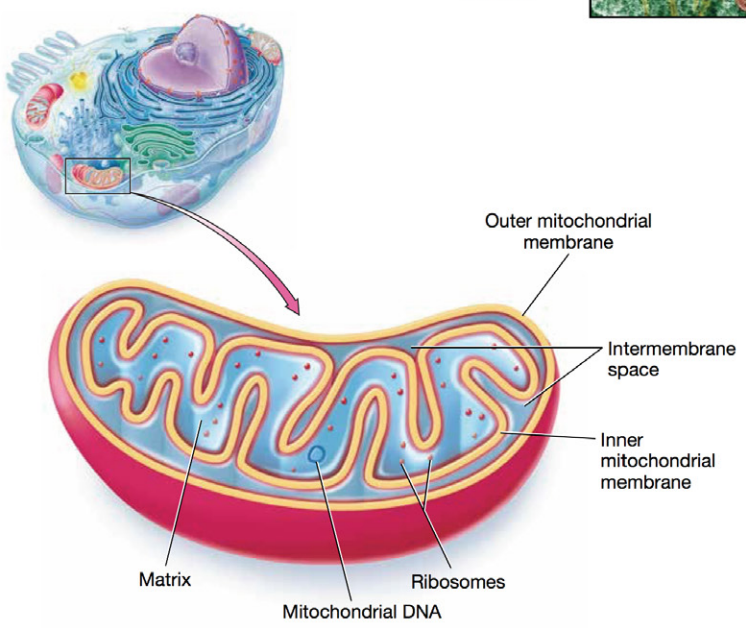

FIGURE **4.5** Mitochondrion.

- **Centrioles. Centrioles** (SEN-tree-ohlz) are paired organelles composed primarily of microtubules that are located in the central area of the cell called the **centrosome** (SEN-troh-sohm). They appear to be microtubule organizing centers and are important in facilitating the assembly and disassembly of microtubules.

3. **Nucleus.** The third component in nearly all cells is a specialized structure called the **nucleus** (NOO-klee-us). The nucleus is the cell's biosynthetic center that directs the synthesis of nearly all of the body's proteins, as well as certain nucleic acids. The nucleus is surrounded by a double membrane called the **nuclear envelope**, which contains holes called **nuclear pores**. Within the nucleus we find **chromatin** (KROH-mah-tin), a ball-like mass of tightly coiled DNA and proteins; RNA; and a dark-staining region called the **nucleolus** (noo-klee-OH-lus). The nucleolus contains a type of RNA called **ribosomal RNA** and is the "birthplace" of ribosomes.

Note that the cell shown in Figure 4.4 is a **generalized cell** that contains each organelle in average numbers. Most cells in the body don't look like this and instead are specialized so their structure follows their functions. For example, the cells of the liver contain a large amount of smooth endoplasmic reticulum, and immune cells called phagocytes house many lysosomes.

Procedure 1 Model Inventory for the Cell

Identify the following structures of the cell on models and diagrams, using this unit and your textbook for reference. As you examine the anatomical models and diagrams, record the name of the model and the structures that you were able to identify on the model inventory in Table 4.2. When you have completed this activity, answer Check Your Understanding questions 1 through 3 (p. 95).

1. Plasma membrane
   a. Phospholipid bilayer
   b. Integral proteins
   c. Peripheral proteins
   d. Carbohydrates
   e. Microvilli
2. Cytoskeleton
   a. Actin filaments
   b. Intermediate filaments
   c. Microtubules
   d. Cilia
   e. Flagella
3. Cytoplasmic organelles
   a. Ribosomes
   b. Peroxisomes
   c. Mitochondria
   d. Rough endoplasmic reticulum
   e. Smooth endoplasmic reticulum
   f. Golgi apparatus
   g. Lysosomes
   h. Centrioles
4. Nucleus
   a. Nuclear membrane
   b. Nuclear pores
   c. Chromatin
   d. Nucleolus

TABLE 4.2 Cellular Structures Model Inventory

Model/Diagram	Structures Identified

Procedure 2 Time to Draw

In the space below, draw, color, and label one of the cell models that you examined. In addition, write the function of each organelle that you label.

Procedure 3 Examining Cellular Diversity with Microscopy

The structure of different cell types can vary drastically. Cells differ not only in size and shape but also in the types and prevalence of organelles in the cell. In this activity you will examine prepared microscope slides of red blood cells, sperm cells, and skeletal muscle cells. Use the techniques you learned in Unit 3: Begin your observation on low power, and advance to high power for each slide. Note that sperm cells can be difficult to find, so an oil immersion lens is helpful to find the tiny cells. Draw, color, and label the cellular structures and organelles that you see on each slide. You may wish to look at Figures 5.9 (p. 116) for red blood cells, 5.10A (p. 122) for skeletal muscle, and 27.15 (p. 724) for sperm cells.

1 Red blood cells



2 Sperm cells



3 Skeletal muscle cells



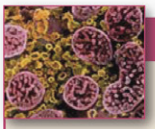

HINTS & TIPS

How to Draw Useful Micrograph Diagrams

You don't need to be a great artist to draw useful micrograph diagrams. Following are some tips for producing effective drawings that can help you learn the material and study for practical exams.

- First look at a diagram of the cell or tissue in this book or your textbook to get oriented and get an idea of what you should look for in the field of view.
- Make note of the image's magnification. As always, start on low power, then advance to higher-powered objectives as needed. You should aim for a magnification about the same as the magnification in the diagram.
- Reproduce as closely as possible what you see in the field of view using a pencil. This doesn't have to be a work of art, but you should take care to draw the shape of the cells, the way the cells are organized, and the components of the extracellular matrix. You may draw in the circles in this manual or on a piece of white paper for larger diagrams.
- Add color to your drawing with colored pencils using the slide as a guide. Color is a critical component, particularly for study purposes. Some slides will have uniquely colored stains or staining patterns, and studying the colored images can prove quite helpful. In addition, the slides that your lab uses might have different stains than the images in your book. In these cases, it is useful to have a drawing with those specific stain colors.
- The final step is to label your drawing. Use your lab manual, textbook, and other resources as a guide to ensure that your labels are accurate.

Exercise 4-2

Diffusion

MATERIALS

- ❑ 2 100 mL beakers
- ❑ Food coloring
- ❑ Hot water
- ❑ Ice water
- ❑ 4 empty Petri dishes
- ❑ Corn syrup
- ❑ 0.1 M potassium permanganate
- ❑ 0.1 M methylene blue
- ❑ 1.0 M methylene blue
- ❑ 0.1 M Congo red
- ❑ Ruler

Diffusion is defined as the movement of solute molecules from a high concentration to a low concentration until a state of equilibrium is reached (Fig. 4.6). When equilibrium is reached, net diffusion stops, although molecules continue moving. Diffusion is a **passive process**—one that requires no net input of energy by a cell—because the energy for diffusion comes from a **concentration gradient**. A concentration gradient is defined as a situation in which two connected areas have different concentrations of a solute. Figure 4.6 illustrates a concentration gradient in the panels "Time 1" and "Time 2." Equilibrium is illustrated in "Time 3."

The rate at which diffusion takes place depends upon several factors, including the steepness of the concentration gradient, the temperature, and the size of the particles. Generally, smaller particle size, steeper concentration gradients, and higher temperatures will increase the rate of diffusion.

Diffusion occurs all around us and is very easy to see in action (Fig. 4.7). You'll observe it in this exercise while examining the effects of temperature, concentration, and particle size on the rate of diffusion. When you have completed both procedures, answer Check Your Understanding question 4 (p. 95).

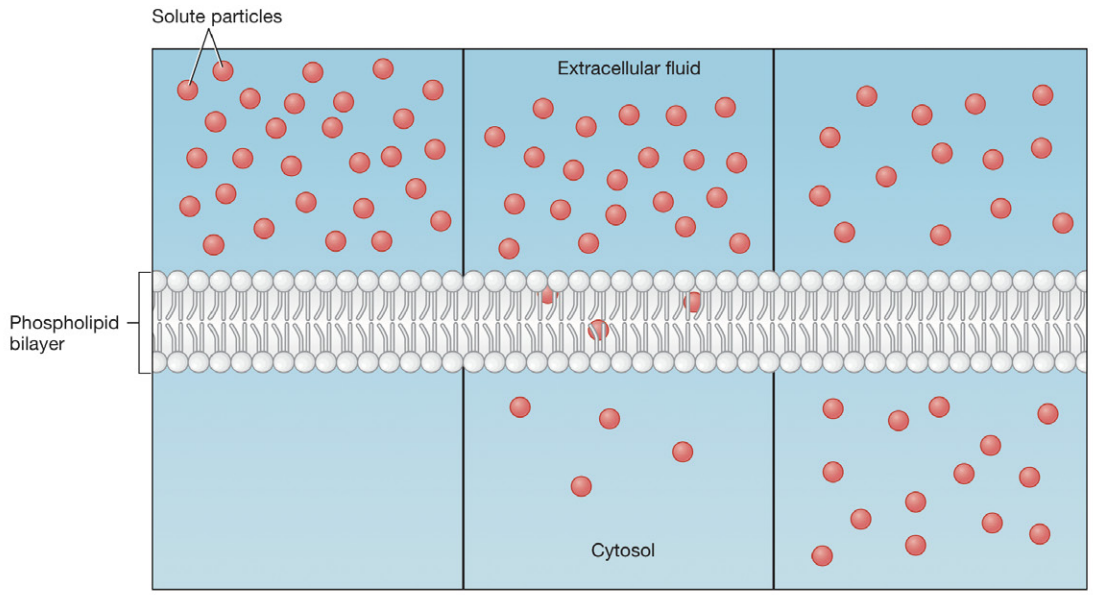

FIGURE **4.6** Diffusion across a plasma membrane.

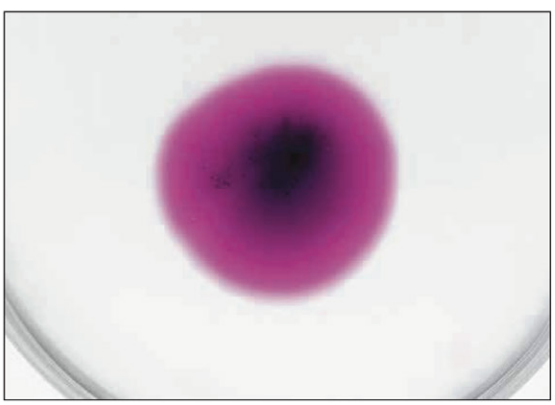

FIGURE **4.7** Example of diffusion seen with potassium permanganate dye in agar. Dye diffuses outward over time from a high concentration to a low concentration.

Procedure 1 Measuring the Effect of Temperature on Diffusion Rate

The first variable you will test is the effect of temperature on the rate at which diffusion takes place. The setup here is very simple, and requires only food coloring and water at two different temperatures.

1. Obtain two 100 mL glass beakers. Label one beaker "cold" and the other "hot." Fill the "cold" beaker with ice water (take care not to get ice in the beaker, though), and fill the "hot" beaker with water that has been heated.
2. Add two drops of food coloring to each beaker.
3. Observe the beakers from the side and measure with a ruler the distance that the dye spreads every minute for 5 minutes. Record your results in Table 4.3.

TABLE 4.3 Diffusion Results for Food Coloring in Water

Time	Distance of Dye Diffusion: Cold Water	Distance of Dye Diffusion: Hot Water
1 minute		
2 minutes		
3 minutes		
4 minutes		
5 minutes		

4. Interpret your results. What effect does temperature have on the rate of diffusion?

Procedure 2 Measuring the Effect of Concentration and Particle Size on the Rate of Diffusion

Now you'll explore the effects of the concentration and particle size on diffusion rate. You will compare the effects of particle size by comparing three dyes of different molecular weights: potassium permanganate, which has the lowest molecular weight; methylene blue, which has a middle molecular weight; and Congo red, which has the highest molecular weight. To compare the effect of concentration, you will be using two different concentrations of methylene blue.

1. Obtain four empty Petri dishes. Label the plates 1, 2, 3, and 4. Mark a spot in the center of each dish.
2. Fill each Petri dish about half-full with corn syrup.

Safety Note

Safety glasses, gloves, and lab coats are required. ***Use caution with the dyes, as they will stain clothes and irritate and stain skin.***

3 Place a drop of 0.1 M potassium permanganate (molecular weight = 158 g/mol) in the center of dish 1. Measure with a ruler the distance that it diffuses every 30 seconds for 2 minutes. Record these data in Table 4.4.

4 Place a drop of 0.1 M methylene blue (molecular weight = 374 g/mol) in the center of dish 2. Measure with a ruler the distance that it diffuses every 30 seconds for 2 minutes. Record these data in Table 4.4.

5 Place a drop of 1.0 M methylene blue (molecular weight = 374 g/mol) in the center of dish 3. Measure with a ruler the distance that it diffuses every 30 seconds for 2 minutes. Record these data in Table 4.4.

6 Place a drop of 0.1 M Congo red (molecular weight = 697 g/mol) in the center of dish 4. Measure with a ruler the distance that it diffuses every 30 seconds for 2 minutes. Record these data in Table 4.4.

TABLE 4.4 Diffusion Results for Dyes in Corn Syrup

Time	Distance of Diffusion			
	Plate 1 0.1 Potassium Permanganate	Plate 2 0.1 M Methylene Blue	Plate 3 1.0 M Methylene Blue	Plate 4 0.1 M Congo Red
30 seconds				
60 seconds				
90 seconds				
120 seconds				

7 Interpret your results:

a Which dye diffused the fastest?

b Which dye diffused the slowest?

c What effect does particle size have on the rate of diffusion?

d What effect does concentration have on the rate of diffusion?

Exercise 4-3

Osmosis and Tonicity

4

MATERIALS

- ❑ Animal or human blood cells
- ❑ 3 glass slides (blank)
- ❑ Coverslips
- ❑ Dropper
- ❑ Wooden applicator stick
- ❑ 5% dextrose in water solution
- ❑ Deionized water
- ❑ 25% NaCl in water solution
- ❑ Lens paper/paper towel
- ❑ Light microscope with 40× objective

For alternate procedure:

- ❑ Pieces of potato cut into equal sizes
- ❑ 3 400 mL beakers
- ❑ Calipers
- ❑ Wax marker
- ❑ Sharpie

Whereas diffusion refers to the movement of solute, the passive process called **osmosis** (oz-MOH-sis) refers to the movement of *solvent*. Specifically, osmosis is the movement of solvent (usually water in biological systems) from a solution with a lower solute concentration to a solution with a higher solute concentration (Fig. 4.8). A key feature of osmosis is that it only occurs through a *selectively permeable membrane*; in this case, the membrane allows water to cross it but not the solute particles. For this reason, the solvent crosses the membrane and moves to the more concentrated solution, diluting it until both solutions have approximately the same concentration.

We can compare the solute concentration of two solutions—for example, the cytosol and the extracellular fluid (ECF)—with the concept of **tonicity**. The ECF surrounding a cell can have three variations in tonicity:

- **Isotonic.** An **isotonic** ECF has the same solute concentration as the cytosol. As both solutions have the same solute concentration, there is no net movement of water into or out of a cell in an isotonic solution (Fig. 4.9A).
- **Hypotonic.** A **hypotonic** ECF has a lower solute concentration than the cytosol. This means that the cytosol has more solute particles, and so will pull water into the cell by osmosis. This may cause the cell to swell and burst (Fig. 4.9B).
- **Hypertonic.** A **hypertonic** ECF has a higher solute concentration than the cytosol. This causes the ECF to pull water molecules out of the cytosol by osmosis. The cell may shrivel or crenate as it loses water to the ECF (Fig. 4.9C).

The following experiment will allow you to watch osmosis in action by placing cells—in this case, red blood cells or *erythrocytes*—into solutions of different tonicity. If your lab doesn't have access to blood products, skip down to the alternate procedure. When you have completed the activities, answer Check Your Understanding questions 5 and 6 (p. 96).

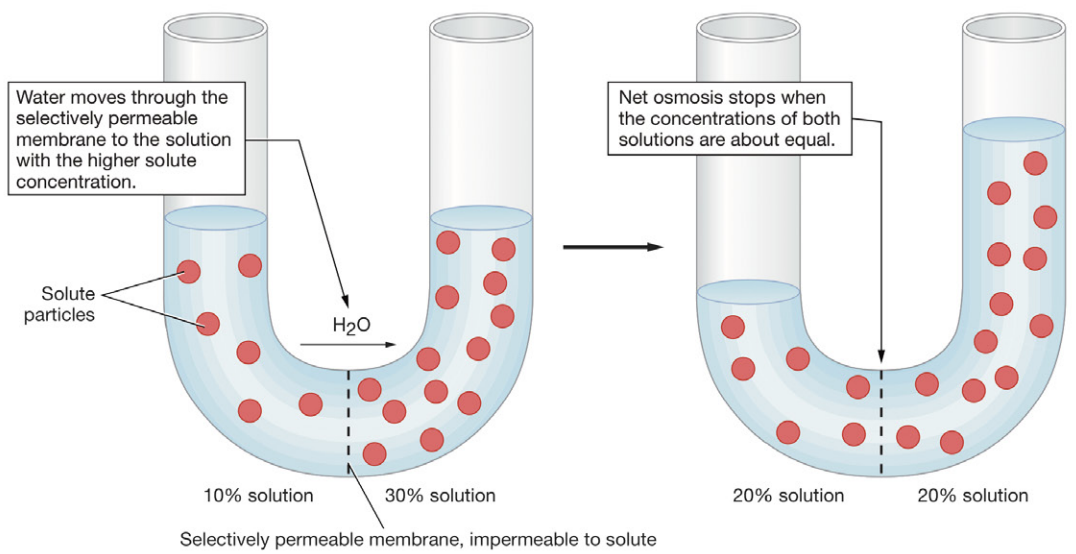

FIGURE **4.8** Osmosis.

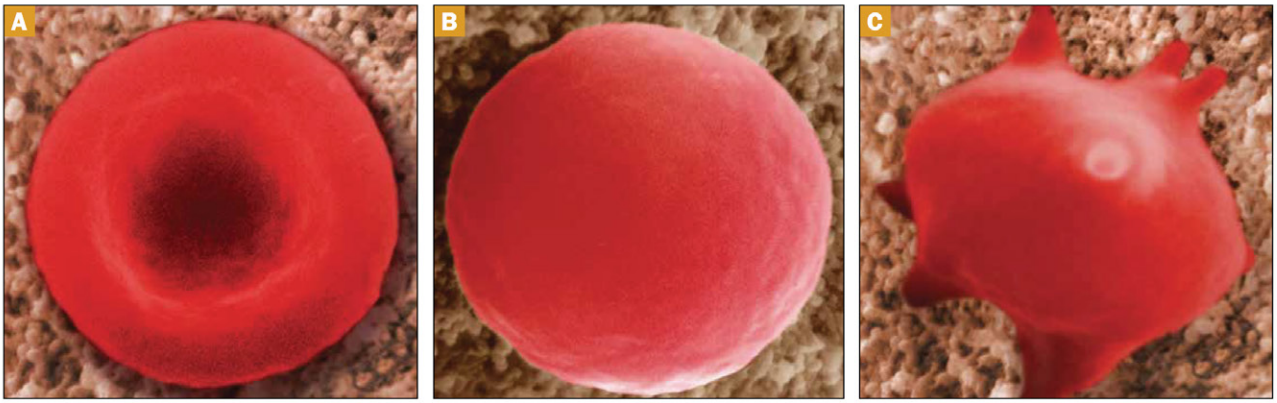

FIGURE **4.9** Effects of solutions of different tonicities on cells: (**A**) isotonic solution; (**B**) hypotonic solution; (**C**) hypertonic solution.

Procedure 1 Watching Osmosis in Action, Blood Version

1 Obtain three blank slides, and number them 1, 2, and 3 with a Sharpie.

Safety Note
Safety glasses and gloves are required!

2 Place one small drop of animal blood on each slide with a dropper. Take care to keep your droplet fairly small; otherwise you won't be able to see individual cells.

3 Gently spread the droplet around the center of the slide with a wooden applicator stick, and place a coverslip on it.

4 On slide 1, place a drop of 5% dextrose solution on one side of the coverslip. On the other side of the coverslip, hold a piece of lens paper or a paper towel. The lens paper will draw the fluid under the coverslip.

5 Observe the cells under the microscope on high power.

6 Repeat the procedure by placing the 25% NaCl solution on slide 2 and distilled water on slide 3.

7 Draw and describe what you see with each slide. Then, move on to Procedure 3 to interpret your results.

Slide 1

Description:



Slide 2

Description:



Slide 3

Description:



Procedure 2 Alternate: Watching Osmosis in Action, Potato Version

1. Obtain three pieces of potato of equal size. Mark them as 1, 2, and 3 with a Sharpie.
2. Measure the length and width of each piece of potato with calipers. Record these data in Table 4.5.
3. Obtain three 400-mL beakers and label them as 1, 2, and 3 with a wax marker.
4. Fill beaker 1 about half-full with distilled water; fill beaker 2 about half-full with 5% dextrose; and fill beaker 3 about half-full with 25% NaCl.
5. Place each piece of potato in its corresponding numbered beaker, and leave it in the solution undisturbed for one hour.
6. After an hour has passed, remove the potato pieces and measure their length and width with calipers. Record these data in Table 4.5. After you have recorded your data, move on to Procedure 3.

TABLE 4.5 Results for Potato Osmosis Experiment

Sample	Sample Contents	Length Before	Width Before	Length After	Width After
1	Distilled water				
2	5% dextrose				
3	25% NaCl				

Procedure 3 Interpret Your Results

Now that you've performed one of the osmosis experiments, you can interpret your data.

1 Which solution was hypotonic? Explain your reasoning.

2 Which solution was isotonic? Explain your reasoning.

3 Which solution was hypertonic? Explain your reasoning.

Exercise 4-4

Mitosis and the Cell Cycle

4

MATERIALS

- ❑ Cell models or diagrams
- ❑ Mitosis models
- ❑ Mitosis slides
- ❑ Light microscope
- ❑ Colored pencils

Many cells go through a continual cycle of growth and replication called the **cell cycle**. The cell cycle consists of four phases (Fig. 4.10):

1. **G_1** is the initial growth phase during which the cell grows, develops, and carries out activities that are specific to that cell type. Some cells are *amitotic*, meaning that they never divide, and remain in G_1 indefinitely. These cells are said to be in phase G_0 (pronounced "G not") of the cell cycle.
2. **S phase** is the period during which the cell's DNA is replicated. In this case, the "S" stands for "synthesis" because another copy of the DNA is synthesized.
3. **G_2** is the second growth phase during which the cell makes its final preparations for division.
4. **M phase** is the phase during which the cell, sometimes called the *mother cell*, undergoes the process of **mitosis** (my-TOH-sis) and divides its replicated DNA among two identical **daughter cells**. Also occurring during M phase is the process of **cytokinesis** (sy-toh-kin-EE-sis), during which the mother cell's cytoplasm is distributed between the two daughter cells. Each daughter cell has the same exact genetic and structural characteristics as the original mother cell.

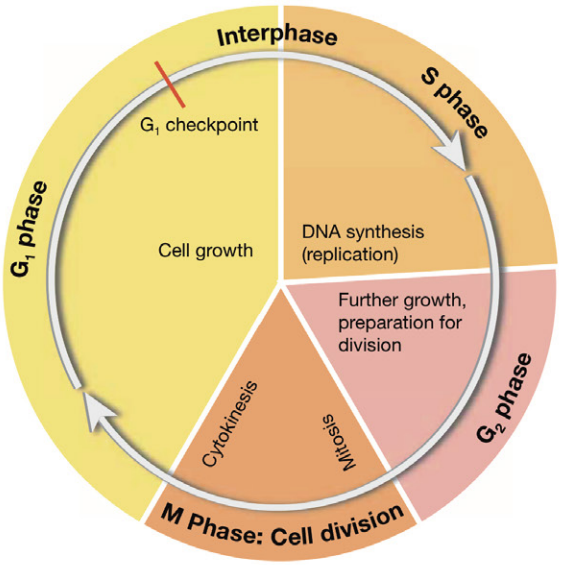

FIGURE **4.10** Cell cycle.

The portions of the cycle from G_1–G_2, when the cell is not dividing, are collectively called **interphase**, which is shown in Figure 4.11A. In G_1, the cell has only a single copy of its DNA. As the cell enters S phase, DNA replication occurs. Human cells have 23 pairs of **homologous chromosomes** (KROH-moh-sohmz): one set from the mother, and one set from the father. After the DNA is replicated, each homologous chromosome exists in a set of "identical twins" called **sister chromatids**. Note that in Figure 4.11A we only show two pairs of homologous chromosomes for simplicity. Note also that the DNA through all of interphase is still in the form of chromatin and you can't see individual chromosomes or sister chromatids—we have shown them here in the illustration for teaching purposes only.

When S phase has completed, the cell enters G_2, and when G_2 is finished, mitosis begins. Mitosis proceeds in the four general stages shown in Figure 4.11B.

1. **Prophase.** During **prophase**, the nuclear membrane starts to degenerate, and the chromatin condenses into individual **chromosomes**. Also during this stage, we see a structure called the **mitotic spindle** organizing around the centrioles, which begin migrating to the opposite poles of the cell. By the end of late prophase, the centrioles have reached the opposite poles of the cell. Microtubules called spindle fibers emanate from each side of the mitotic spindle and attach to a structure known as the **centromere** (SIN-troh-meer) that joins the two sister chromatids—one spindle fiber attaches to each side of the centromere.
2. **Metaphase.** In **metaphase** we see the sister chromatids, attached to the spindle fibers, line up along the equator of the cell.
3. **Anaphase.** During **anaphase** we see the spindle fibers shorten, which pulls the centromeres apart, and the sister chromatids migrate toward the opposite poles of the cell. In addition, **cytokinesis** begins, and the cell elongates.
4. **Telophase.** In the final phase of mitosis, **telophase** (TEL-oh-phayz), a divot forms between the two cells called a **cleavage furrow** (Fig 4.12). As the cleavage furrow progressively narrows, the cell is pinched into two identical daughter cells and cytokinesis is completed. In addition, during this stage the nuclear membranes begin to reassemble, the mitotic spindle becomes less visible, and the DNA returns to its chromatin form.

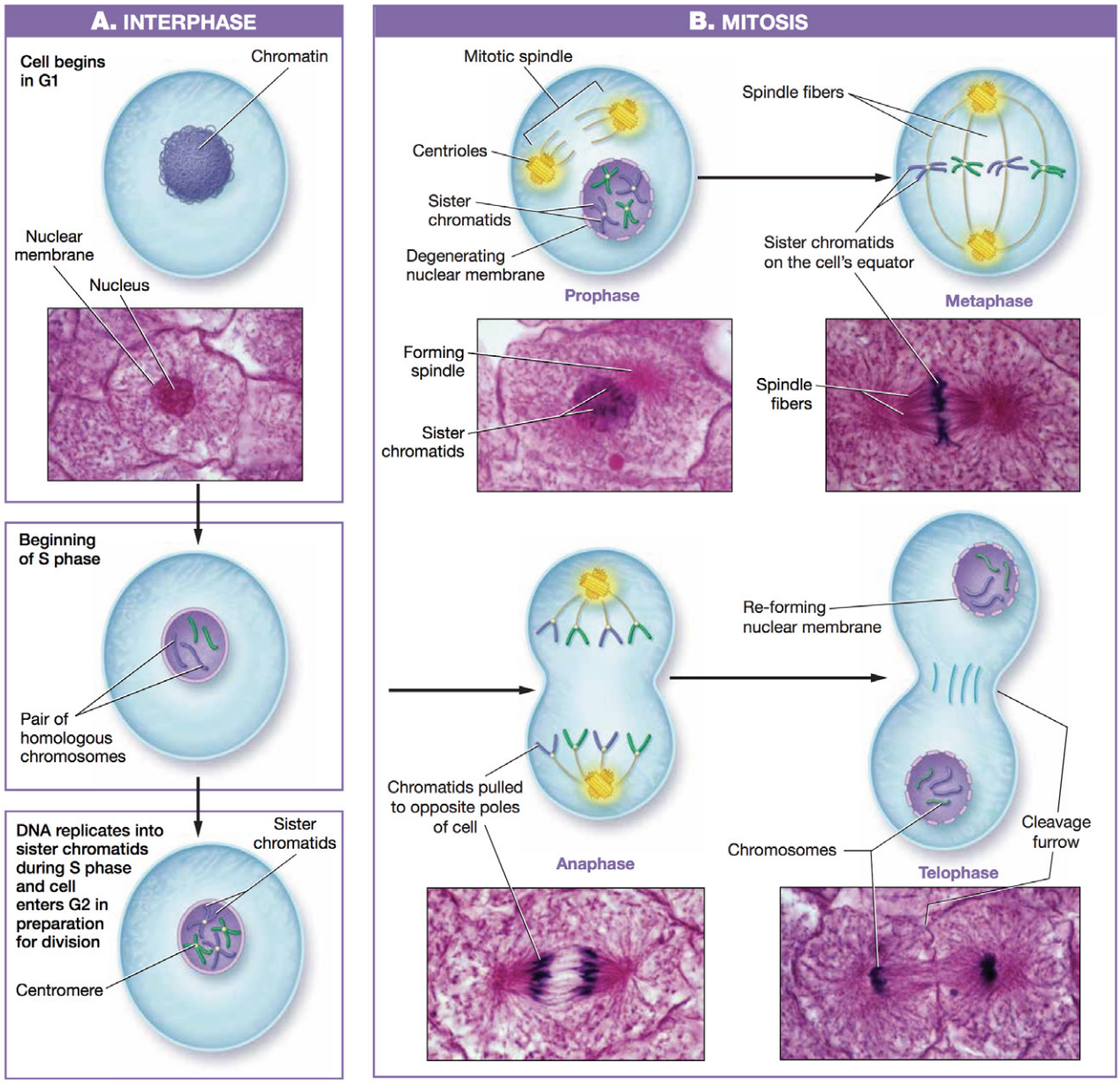

FIGURE **4.11** Cell during the stages of the cell cycle: (**A**) interphase; (**B**) stages of mitosis.

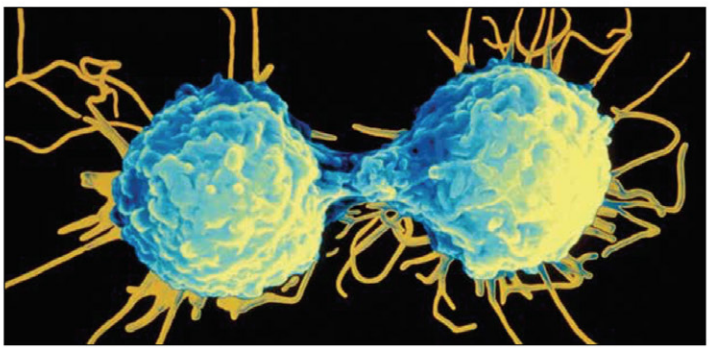

FIGURE **4.12** White blood cell in telophase of mitosis.

Procedure 1 Identify Structures of Cell Division

Identify the following structures associated with mitosis on cell models and diagrams.

1. Mitotic spindle
   a. Centrioles
   b. Microtubules (spindle fibers)
2. Nucleus
   a. Nucleolus
   b. Nuclear membrane
3. Chromosomes
   a. Sister chromatids
   b. Centromere

Procedure 2 Model Mitosis

Arrange models of the cell cycle and mitosis in the proper order.

1. Interphase
2. Mitosis
   a. Prophase
   b. Metaphase
   c. Anaphase
   d. Telophase

Procedure 3 Microscopy of the Cell Cycle

Examine the five phases of the cell cycle on prepared whitefish mitosis slides using the highest-power objective. Note that every stage of the cell cycle may not be visible on one single slide, so you may have to use more than one slide. Note also that most of the cells you see will be in interphase.

Draw and describe what the cell looks like during each phase of the cell cycle, and label your drawing with as many of the structures of cell division (see p. 89) as you can see in each cell. Use your Pre-Lab Exercises and Figure 4.11 for reference. When you have completed the activities, answer Check Your Understanding question 7 (p. 96).

1 Interphase

Description:



2 Mitosis

a Prophase

Description:



b Metaphase

Description:



c Anaphase

Description:



4

d Telophase

Description:



Name _____

Section _____ Date _____

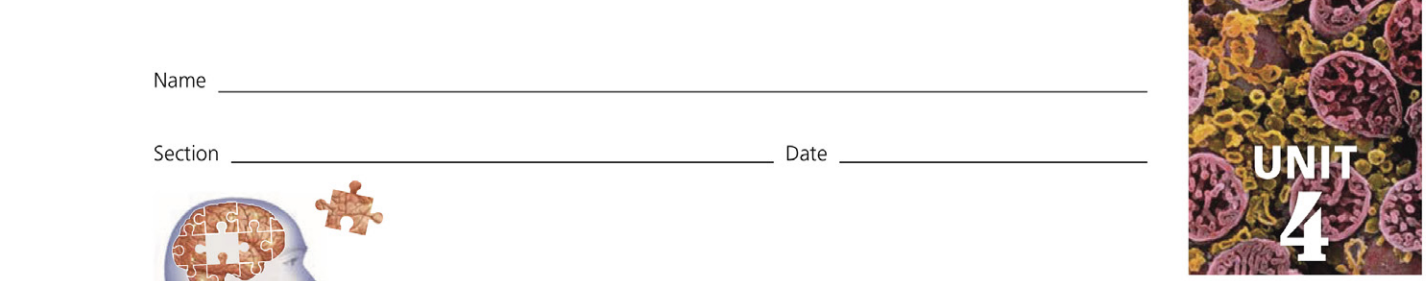

Check Your Recall

REVIEW 4

1 Label the following parts of the cell on Figure 4.13.

- ❑ Centrioles
- ❑ Chromatin
- ❑ Golgi apparatus
- ❑ Microvillus
- ❑ Mitochondrion
- ❑ Nuclear envelope
- ❑ Nuclear pore
- ❑ Nucleolus
- ❑ Plasma membrane
- ❑ Rough endoplasmic reticulum
- ❑ Smooth endoplasmic reticulum

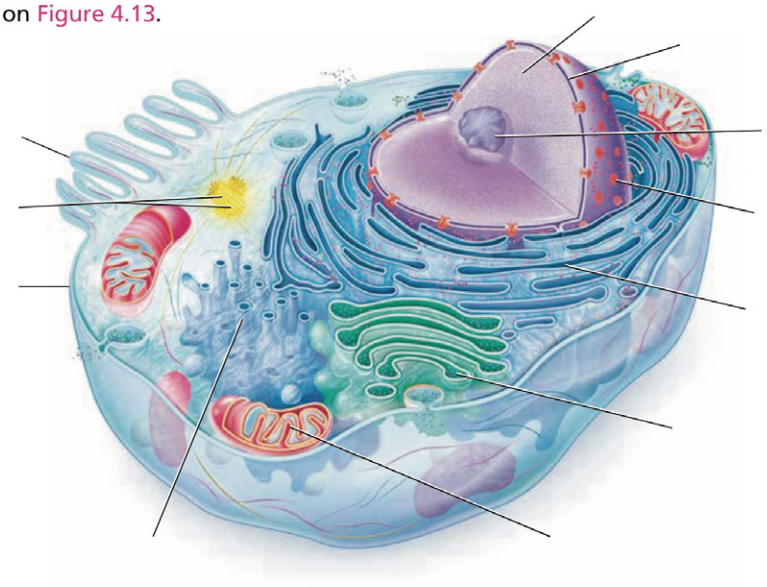

FIGURE **4.13** Generalized cell.

2 Which of the following is the primary component of the plasma membrane?

a. Cholesterol.
b. Glycolipids.
c. Phospholipids.
d. Integral proteins.

3 What are the three basic components of most cells?

_____

_____

4 *Fill in the blanks:* Diffusion is the movement of _____ from a _____ concentration to a _____ concentration. Osmosis is the movement of _____ from a _____ _____ concentration to a _____ _____ concentration.

5 Which of the following factors influences the rate at which diffusion takes place?

a. Size of the particles.
b. Temperature.
c. Steepness of the concentration gradient.
d. All of the above.

6 *Matching:* Match the following organelles and cell structures with the correct definitions.

_____ Peroxisome
_____ Smooth ER
_____ Mitochondria
_____ Ribosomes
_____ Rough ER
_____ Actin filaments
_____ Nucleolus
_____ Lysosome
_____ Microtubule
_____ Golgi apparatus

A. Part of the cytoskeleton located along the plasma membrane and in microvilli that helps maintain the cell's shape
B. Produce(s) the bulk of the cell's ATP
C. Contain(s) digestive enzymes
D. Stack of flattened sacs that modify and sort proteins
E. Vesicular organelle that detoxifies substances, metabolizes fatty acids, and synthesizes phospholipids
F. Series of membrane-enclosed sacs with ribosomes on the surface
G. Cytoskeletal filament found in cilia and flagella
H. Series of membrane-enclosed sacs that detoxify substances and synthesize lipids
I. The cell's "ribosome factory"
J. Granular organelles that are the sites of protein synthesis

7 How do isotonic, hypertonic, and hypotonic solutions differ?

8 What happens during S phase of the cell cycle?

a. The cell divides.
b. The cell undergoes its final preparation for division.
c. The cell undergoes its initial growth phase.
d. The cell replicates its DNA.

9 Label the stages of mitosis and the cell cycle on Figure 4.14.

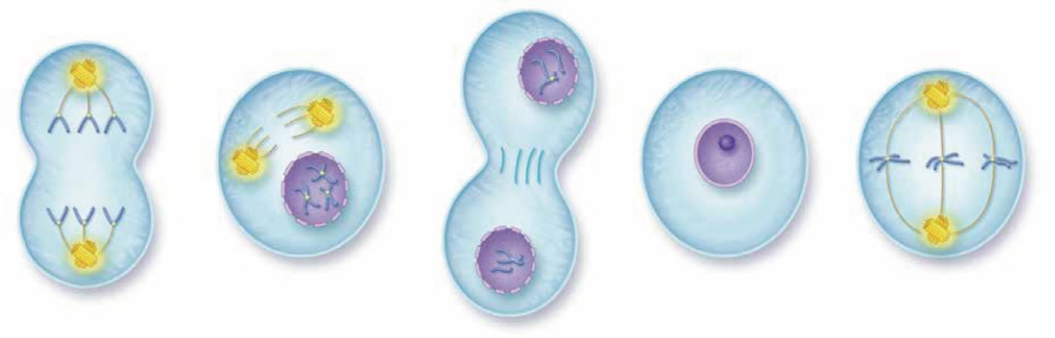

FIGURE **4.14** Cells in different stages of the cell cycle.

10 The mitotic spindle fibers are composed of

a. microtubules.
b. microvilli.
c. intermediate filaments.
d. actin filaments.

Name _____

Section _____ Date _____

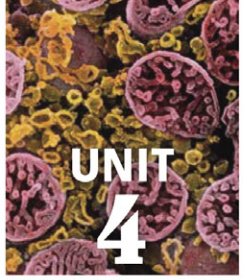

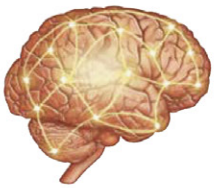

Check Your Understanding

REVIEW 4

Critical Thinking and Application Questions

1 A hypothetical poison prevents nucleoli from carrying out their functions. Which organelles would be affected by this poison? What would the cell be unable to do? Explain.

2 One of the liver's main functions is to detoxify potentially toxic substances. Given this information, which organelle(s) would you expect liver cells to have in abundance? Explain.

3 Autolysis is a process in which damaged or dying cells digest themselves via reactions catalyzed by their own digestive enzymes due to rupture of a specific organelle. Which organelle do you think is involved in autolysis? Explain.

4 Your patient has a severe infection, and you want to get an antibiotic into his system as quickly as possible. You have two choices for your antibiotic, both of which must be injected into muscle and so must diffuse into his blood: PeniKill'Em, which must be stored in the refrigerator and has a molecular weight of 450 g/mol, or AzithroLyse'Em, which is stored at room temperature and has a molecular weight of 200 g/mol. Which drug will you choose, and why?

5 Gatorade and other sports drinks are actually hypotonic solutions. How do these drinks rehydrate their users?

4

6 Your friend notes that Gatorade has electrolytes like sodium and potassium chloride. He figures that if a few electrolytes are good for you, then a lot must be even better. Following this logic, he adds nearly a tablespoonful of salt to his Gatorade. What kind of solution is his Gatorade now (hypotonic, isotonic, or hypertonic)? What will likely happen to his cells if he drinks this liquid?

7 The anticancer drug paclitaxel (Taxol), derived from the Pacific Yew, has many effects on mitosis. One of its most powerful effects is that it prevents disassembly of the mitotic spindle, which prevents spindle fibers from shortening. Which phase of mitosis would this directly affect? Why would this stop cell division overall and lead to cell death?

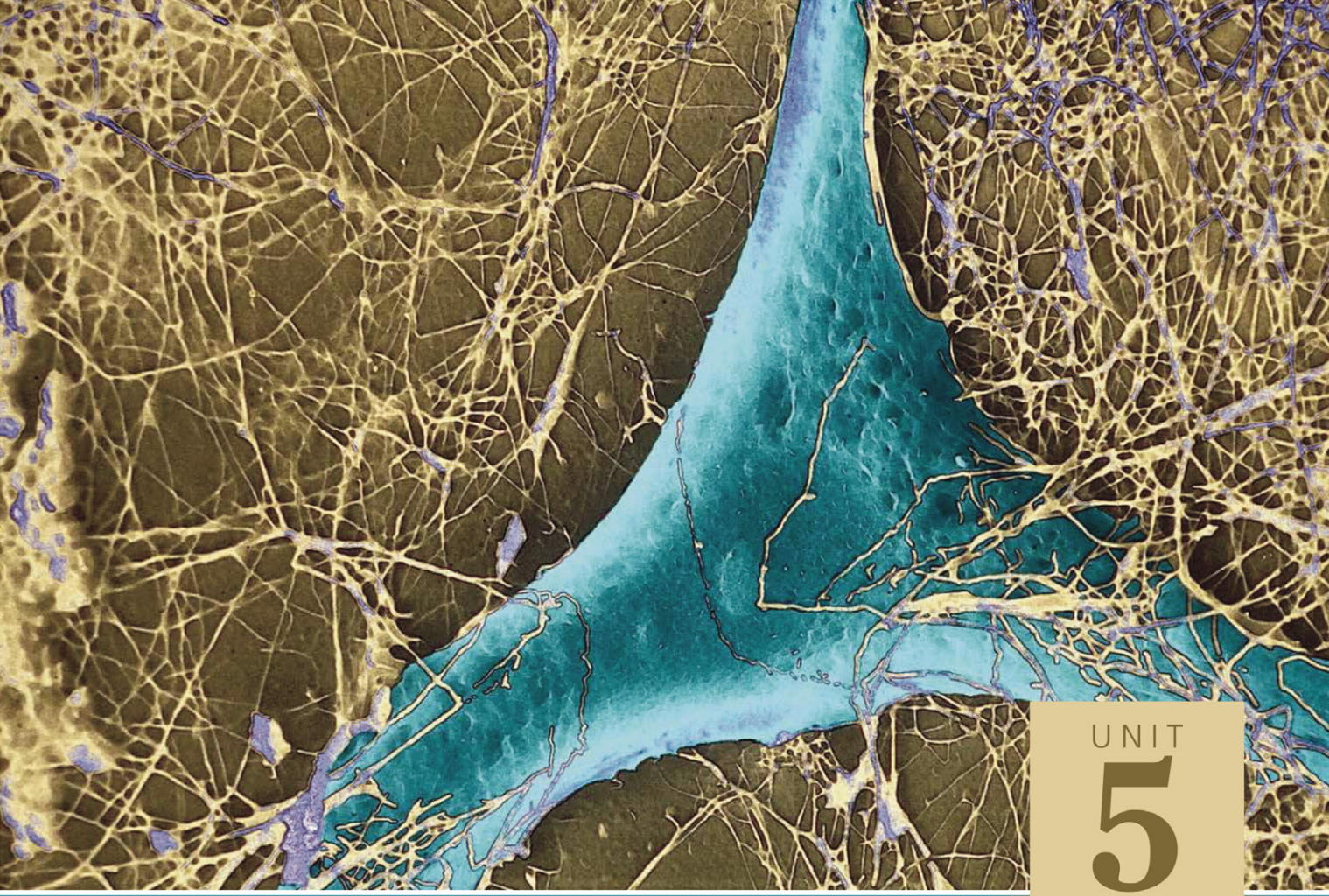

UNIT
5

Histology

Once you have completed this unit, you should be able to:

1. Describe the basic components of all tissues.
2. Identify epithelial tissues by number of layers and cell shape.
3. Identify and describe connective tissues.
4. Identify and describe muscle and nervous tissues.
5. Relate tissue structure to tissue function, and describe how organs are formed from two or more tissue types.

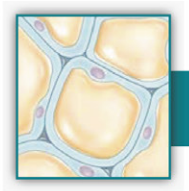

Name _____ Section _____ Date _____

PRE-LAB EXERCISES

Complete the following exercises prior to coming to lab, using this lab manual and your textbook for reference.

Pre-Lab Exercise 5-1

Key Terms

You should be familiar with the following terms before coming to lab.

Term	Definition

Extracellular Matrix

Ground substance _____

Collagen fiber _____

Elastic fiber _____

Reticular fiber _____

Epithelial Tissue

Simple epithelial tissue _____

Stratified epithelial tissue _____

Pseudostratified epithelial tissue _____

Squamous cell _____

Cuboidal cell _____

Columnar cell _____

Basement membrane _____

Connective Tissue

Loose connective tissue

Dense connective tissue

5

Cartilage

Bone

Blood

Muscle Tissue

Striated

Skeletal muscle tissue

Cardiac muscle tissue

Smooth muscle tissue

Nervous Tissue

Neuron

Neuroglial cell

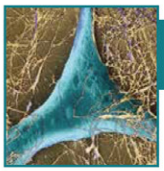

SEM of a fibroblast and collagen fibers.

EXERCISES

The histology labs can be some of the more intimidating and frustrating labs for beginning anatomy and physiology students. The subjects are somewhat abstract and unfamiliar and require use of a complicated tool—the microscope. The best way to approach this subject is to be systematic, and let your lab manual walk you through it step-by-step. If you get confused, don't despair. With the help of this book, your lab instructor, and a little patience, you can do it! Before you begin, you may wish to review the "Hints and Tips" box on p. 80.

The exercises in this unit introduce you to the four basic types of tissue: **epithelial tissue** (ep-ih-THEE-lee-uhl), **connective tissue, muscle tissue,** and **nervous tissue** (Fig. 5.1). All four of these tissue types have two main components: cells, which are specialized for each tissue type, and the **extracellular matrix** (ECM), which is the material around the tissue's cells that is largely produced by the cells themselves. As you can see in Figure 5.1, all tissues have ECM, although its prominence, composition, and location varies in the different tissue types.

ECM consists of two components: ground substance and protein fibers (Fig. 5.2). **Ground substance** is a gelatinous material that contains water, ions, nutrients, and large polysaccharides, as well as *proteoglycans,* which are polysaccharides bound to a protein core. Notice in Figure 5.2 that thousands of proteoglycans come together to form huge structures called *proteoglycan aggregates* that resemble bottle brushes. The polysaccharides, proteoglycans, and proteoglycan aggregates trap water in the ECM and make it firmer, which helps a tissue resist compression.

Protein fibers are found within ground substance. The three types of protein fiber include:

1. **Collagen fibers.** Cells make many different types of **collagen fibers** (known as type I, type II, type III, etc.), which are composed of multiple entwining

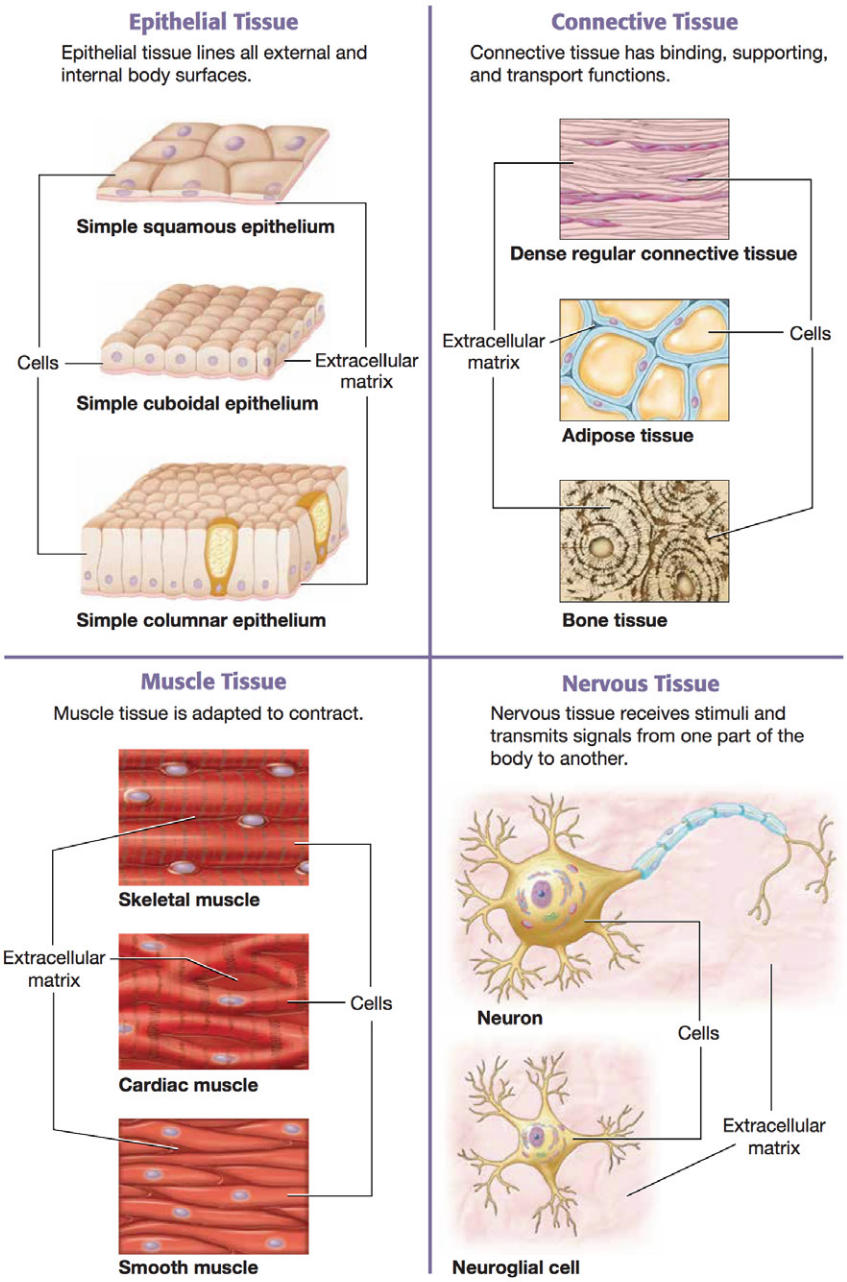

FIGURE **5.1** The four different types of tissue.

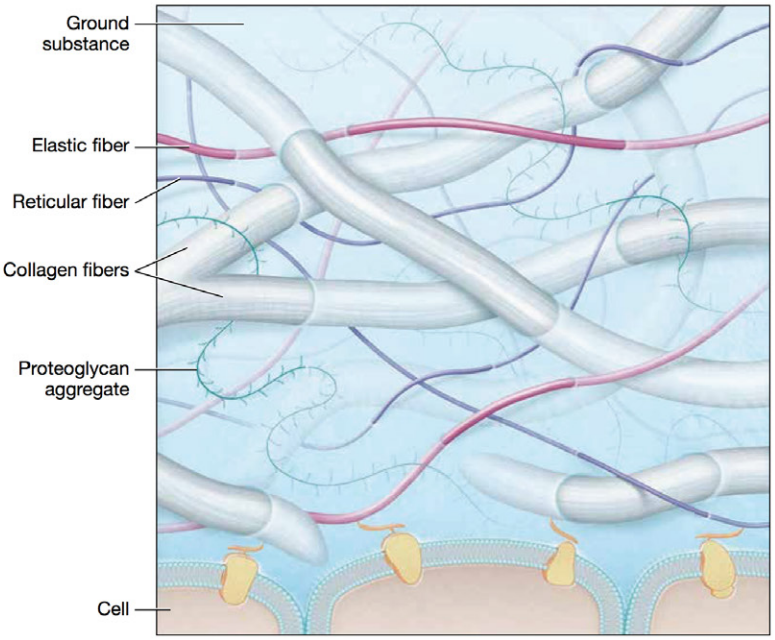

FIGURE **5.2** Composition of extracellular matrix.

strands of the thick protein **collagen.** Imagine collagen fibers as the steel cables of a tissue—just as steel cables give a structure the ability to withstand tension, collagen fibers give a tissue tensile strength (i.e., the ability to resist stretching forces).

2. **Elastic fibers.** Cells may produce another type of fiber called **elastic fibers,** which are composed of the protein **elastin.** These protein strands perform the opposite function of collagen fibers—whereas collagen fibers resist stretch, elastic fibers allow a tissue to be stretched, which is a property known as *distensibility*. Elastic fibers also give a tissue the property of *elasticity*, meaning that the tissue returns to its original shape and size when the stretching force is removed.
3. **Reticular fibers.** The final fiber type made by cells is thin **reticular fibers.** These fibers were long thought to be a unique fiber type, but are now understood to be a special type of collagen fiber composed of collagen proteins. The thin structure of reticular fibers allows them to interweave to form "nets" that support blood vessels, nerves, and other structures. Indeed, the word root "reticul-" means "netlike."

Let's now begin our exploration of this fascinating level of organization, starting with epithelial tissues.

Exercise 5-1

Epithelial Tissue

MATERIALS

- ❑ Epithelial tissue slides
- ❑ Light microscope
- ❑ Colored pencils

Epithelial tissues are our covering and lining tissues. They are found covering body surfaces, lining body passageways, lining body cavities, and forming glands. Epithelia contain mostly cells, called **epithelial cells**, with little visible ECM. In fact, the majority of their ECM is located underneath the cells in a thin layer called the **basal lamina** (BAY-zul LAM-in-uh). The basal lamina performs an important function: It adheres to another layer of ECM produced by the connective tissues deep to the epithelium (known as the *lamina reticularis*), which effectively "glues" the epithelium in place. Together, the basal lamina and lamina reticularis are called the **basement membrane**.

Epithelial tissues are all **avascular**, which means that they have no blood vessels to supply them directly. This means that epithelial cells must obtain oxygen and nutrients that have diffused up from blood vessels supplying deeper tissues. For this reason, epithelial tissues can be only a certain number of cell layers in thickness. If they are too thick, oxygen and nutrients will not reach the more superficial cells, and these cells will die.

The different types of epithelia are classified according to the number of layers of cells they have: **Simple epithelia** have only one layer of cells, and **stratified epithelia** have two or more cell layers. Epithelia are also classified by their predominant cell shape: **squamous** (SKWAY-muss) **cells** are flat; **cuboidal cells** are about as tall are they are wide; and **columnar cells** are taller than they are wide. These two criteria give us the following classes of epithelia (see Fig. 5.3):

1. **Simple epithelia:**
   a. **Simple squamous epithelium. Simple squamous epithelium,** shown in Figure 5.3A, consists of a single layer of flat cells with a centrally located, flattened nucleus. We often find simple squamous epithelium in places where substances have to cross the epithelium quickly, such as the air sacs of the lungs.
   b. **Simple cuboidal epithelium.** Note in Figure 5.3B that the cells of **simple cuboidal epithelium** are short and have a spherical, central nucleus. Simple cuboidal epithelium is found lining glands such as the thyroid gland, certain respiratory passages, and in the kidneys.
   c. **Simple columnar epithelium.** The cells of **simple columnar epithelium,** shown in Figure 5.3C, have spherical nuclei generally located near the base of the cell. These cells line certain respiratory passages and much of the digestive tract. The plasma membranes of simple columnar epithelial cells often contain cilia or are folded into microvilli.
   d. **Pseudostratified ciliated columnar epithelium. Pseudostratified** (SOO-doh-strat-ih-fy'd) **epithelium,** seen in Figure 5.3D, looks as if it has many cell layers but actually has only one layer of cells (*pseudo* = false). Notice in the figure that the nuclei of the cells are at different heights, which gives the epithelium the appearance of having many layers. However, the cells are all attached to the same basal lamina, and so exist

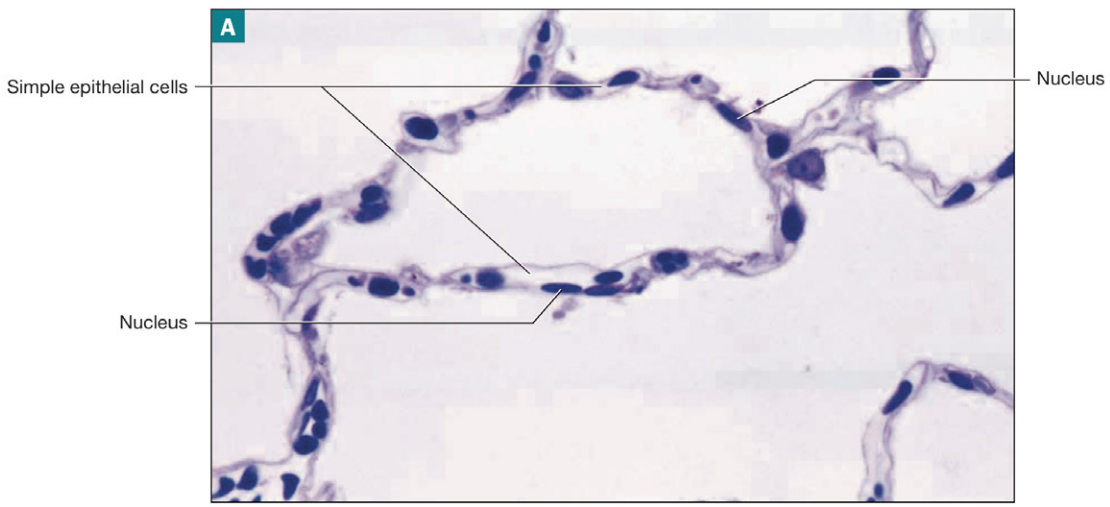

FIGURE **5.3** Simple epithelial tissues: (**A**) simple squamous epithelium from the lungs; *(continues)*

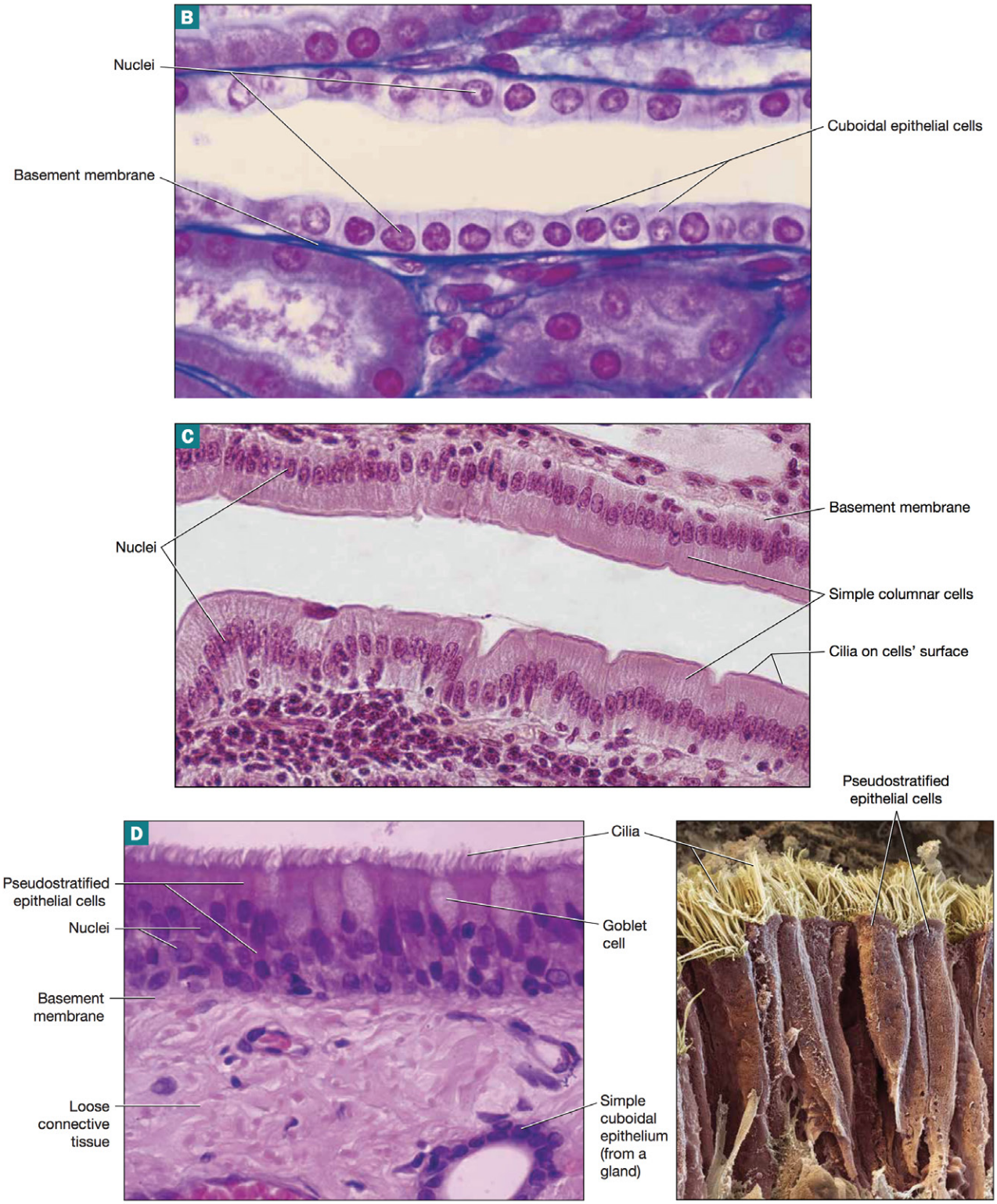

FIGURE **5.3** Simple epithelial tissues *(cont.)*: (**B**) simple cuboidal epithelium from the kidney; (**C**) simple ciliated columnar epithelium from the uterine tube; (**D**) pseudostratified ciliated columnar epithelium from the trachea, light micrograph and scanning electron micrograph.

in a single layer. This type of epithelium usually has cilia, and the cell shape is always columnar. It is found lining the nasal cavity and much of the respiratory tract, where it is often called *respiratory epithelium*.

2. **Stratified epithelia:**
   a. **Stratified squamous epithelium.** This type of epithelium consists of many layers of flattened cells and has two variants. The first, shown in Figure 5.4A, is **stratified squamous keratinized epithelium,** which consists of epithelial cells called **keratinocytes** (kehr-ah-TIN-oh-syt′z) that produce the protein **keratin** (KEHR-ah-tin). The more superficial flaky-looking cells are dead because they are too far away from the blood supply in the deeper tissues and, as a result, they harden and die. Stratified squamous keratinized epithelial cells resist mechanical stresses and so are found in the superficial layer of the skin where the body is subject to multiple environmental stresses. **Stratified squamous nonkeratinized epithelium** (Fig. 5.4B) contains no keratin and is located in places subject to lesser degrees of mechanical stress, such as the oral cavity, the pharynx (throat), the anus, and the vagina. This type of epithelium is not as thick and so the superficial cells are alive. As you can see, this gives them a much different appearance than the superficial cells of keratinized epithelium.
   b. **Stratified cuboidal epithelium** and **stratified columnar epithelium.** Both of these types of epithelium are rare in the human body (Figure 5.4C shows stratified cuboidal epithelium only) and are found lining the ducts of certain glands.
   c. **Transitional epithelium. Transitional epithelium,** shown in Figure 5.4D, is stratified but is not classified by its shape because its cells can change shape. Typically, the apical or surface cells are dome-shaped, but when the tissue is stretched, they flatten and are squamous in appearance. Transitional epithelium is found lining the urinary bladder and ureters, and for this reason is also sometimes known as *urinary epithelium*.

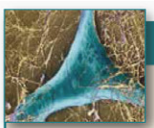

HINTS & TIPS

Histology: Don't Panic

There's one mantra you always need to repeat before you place a slide on the stage: *Don't panic.* Histology really isn't as hard as it seems. Remember that everything that you see on a slide, no matter how disorganized or confusing the slide may look, is either cells or ECM. These are easy to tell apart. If you're looking at something that has a dark purple nucleus, it's a cell. If it doesn't, it's ECM. So right there, you've got a starting point.

Now let's review the basics of microscopy that we talked about in Unit 3, as a good understanding of the basics makes histology much easier. So first recall how to approach any slide: Examine the slide with the naked eye, place the slide on the stage with the specimen directly over the condenser (light source), and then begin to scan the slide on low power. Once you have found the structures or general area that you need, advance progressively to higher power to see details, and use the fine adjustment knob to get the image in better focus. Use the figures in this manual as a guide—if your slide looks nothing like the tissue in the figure, scroll around the slide, and keep looking. But don't rely completely on the figures here, because the slides that your lab uses may be prepared with different stains or taken from different tissues.

As mentioned before, once you find the general area of the slide that you need, what you are seeing is nothing more than cells and ECM. So first identify the cells, which are the things with dark purple nuclei. Sometimes these will be nice and round, other times they will be kind of flat, and other times they will just look like purple dots. But no matter their shape, nothing else in the tissue looks like this, so when you find something with a nucleus, you've found a cell.

Everything around the cell, no matter how haphazard it may be arranged, be it purple straight lines, pink wavy lines, light purple gel, or all of the above, is just ECM. The "lines" are simply protein fibers, and the "gel" is merely ground substance.

If you keep all of this in mind, and above all, don't panic, you can use the appearance and distribution of the cells and the makeup of the ECM to determine what type of tissue you are seeing.

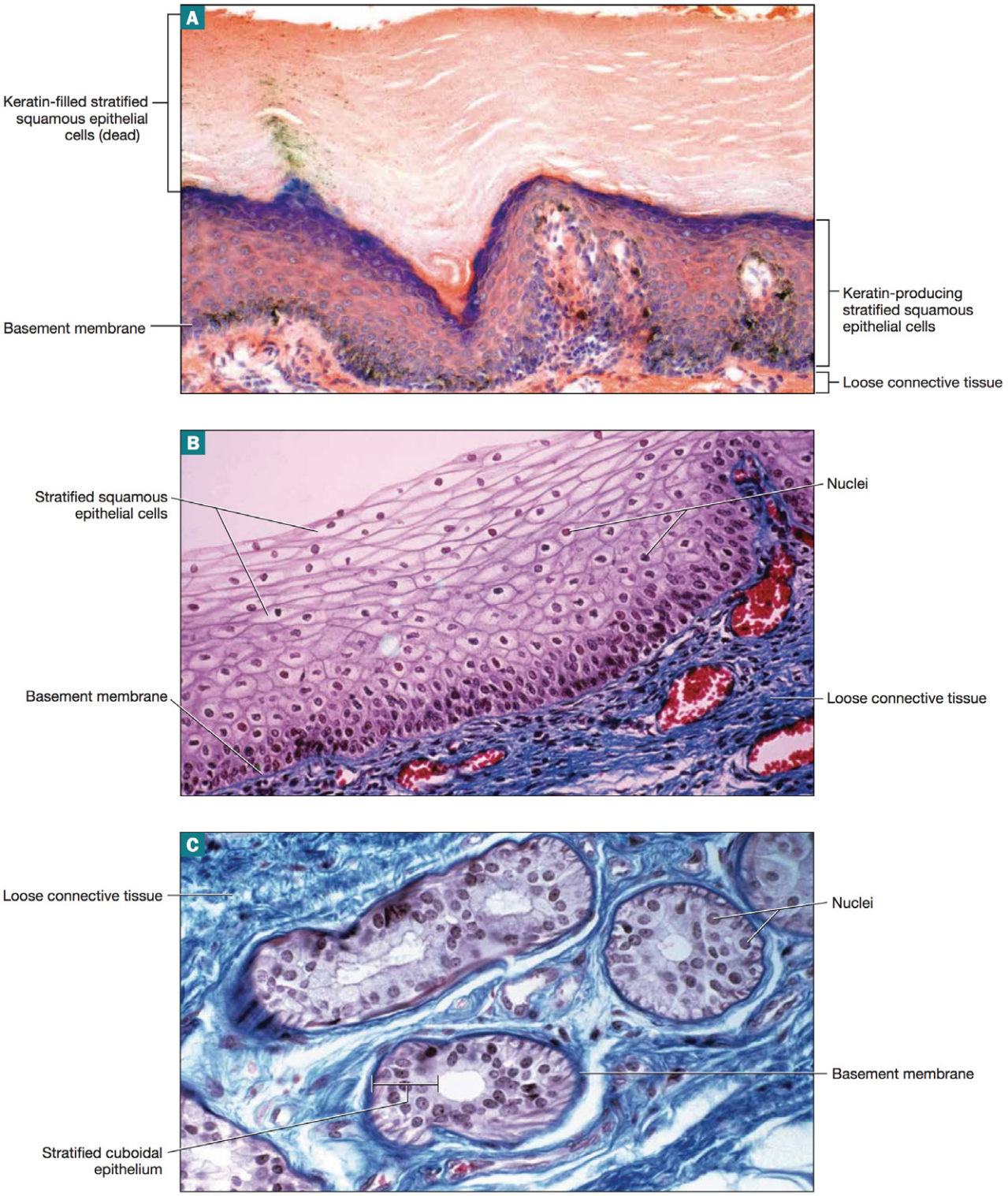

FIGURE **5.4** Stratified epithelial tissues: (**A**) stratified squamous keratinized epithelium from the skin; (**B**) stratified squamous nonkeratinized epithelium from the vagina; (**C**) stratified cuboidal epithelium from a sweat gland; *(continues)*

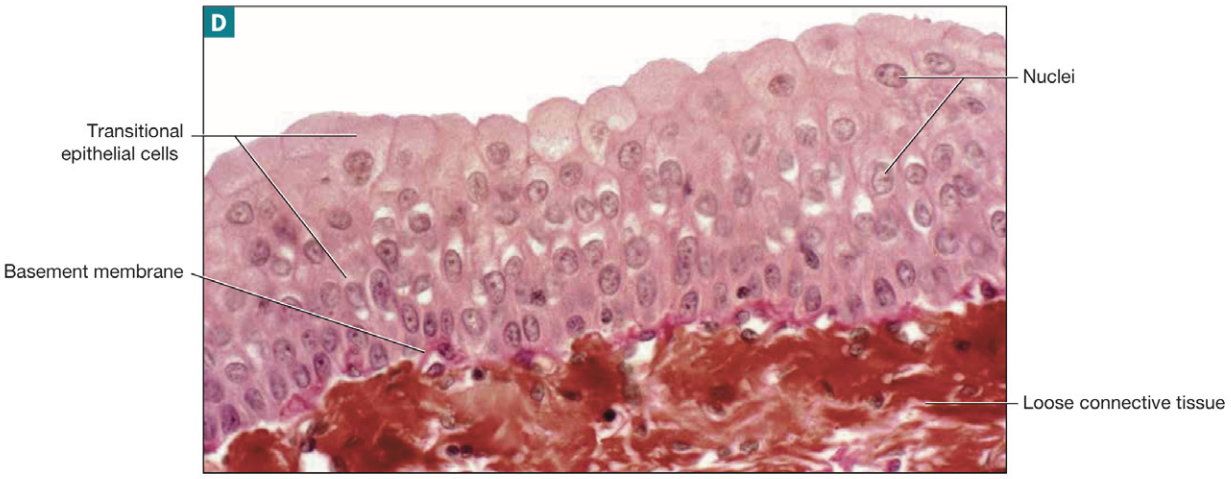

FIGURE **5.4** Stratified epithelial tissues *(cont.)*: (**D**) transitional epithelium from the urinary bladder.

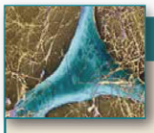

HINTS & TIPS

Identifying Epithelial Tissue

The first step in locating and identifying a tissue is to figure out if you are looking at epithelial, connective, muscle, or nervous tissue. Fortunately, it is relatively easy to determine if you are seeing epithelium. A few unique features can help you distinguish epithelial tissues from other tissues:

- Epithelial tissues are all avascular, so you won't see any blood vessels in epithelium.
- Epithelial tissues are typically on the outer edge of the slide or, at least, on the outer edge of the tissue. Keep in mind that most slides have several tissues in each section. To find the epithelial tissue, often you need to scroll to one end of the slide or the other.
- Epithelial tissues consist mostly of cells. As we have established, everything in a tissue is either cells or ECM. In the case of epithelium, the vast majority of the ECM is restricted to a thin layer deep to the cells. Therefore, you will be looking for cells—structures with dark purple nuclei—that are tightly packed together.

Procedure 1 Microscopy of Epithelial Tissues

Examine prepared slides of the following epithelial tissues. Use colored pencils to draw what you see under the microscope, and label your drawings with the terms from Figures 5.3 and 5.4. Then (a) describe what you see, and (b) give examples of locations in the body where this tissue is found. When you have completed the exercise, answer Check Your Understanding questions 1 and 2 (p. 131).

1 Simple squamous epithelium

a _____

b _____



2 Simple cuboidal epithelium

a _____

b _____



3 Simple columnar epithelium

a _____

b _____



4 Pseudostratified ciliated columnar epithelium

a

b



5 Stratified squamous keratinized epithelium

a

b



6 Stratified squamous nonkeratinized epithelium

a

b



7 Stratified cuboidal or columnar epithelium

a _____

_____

_____

_____

b _____

_____

_____

_____



8 Transitional epithelium

a _____

_____

_____

_____

b _____

_____

_____

_____



Exercise 5-2

Connective Tissue

MATERIALS

- ❑ Connective tissue slides
- ❑ Light microscope
- ❑ Colored pencils

Connective tissues are found throughout the body. They have a variety of functions, most of which serve to *connect*, as their name implies. All connective tissues stem from a common embryonic tissue called **mesenchyme** (MEZ-en-ky′m). Connective tissues are distinguished easily from epithelial tissues by the prominence of their extracellular matrices. Typically, connective tissues contain few cells and have an extensive ECM.

The four general types of connective tissue (CT) are as follows:

1. **Connective tissue proper. Connective tissue proper,** the most widely distributed class of connective tissue in the body, consists of scattered cells called **fibroblasts** (FY-broh-blastz) that secrete an extensive ECM filled with many types of protein fibers. This tissue is highly vascular with an extensive blood supply. The subclasses of CT proper include the following:

- **Loose (areolar) CT.** You can see in Figure 5.5A that the primary element in **loose CT** is ground substance, which gives it a "loose" appearance on a slide. All three types of protein fibers are scattered in loose CT ground substance, although the slide is stained for only collagen and elastic fibers. Loose CT is found as part of the basement membrane and in the walls of hollow organs, where it helps to "glue" together the tissue layers of these organs.
- **Reticular CT.** As you can guess by the name, **reticular CT** consists of many reticular fibers produced by cells called **reticular cells** (Fig. 5.5B). It is located in the spleen and lymph nodes, where the fine reticular fibers interweave to form "nets" that trap pathogens and foreign cells. Reticular CT also is located around blood vessels and nerves, where it forms supportive networks.
- **Adipose tissue.** Notice in Figure 5.5C that **adipose tissue** (fat tissue) has a much different appearance than the other types of CT proper. It consists mostly of huge cells called **adipocytes** (AD-ih-poh-syt′z) with collagen fibers in the ECM. Each adipocyte contains a large lipid droplet that occupies most of its cytoplasm. The nucleus and other organelles are barely visible, because they are pushed to the periphery of the cell against the plasma membrane. Adipose tissue is distributed widely throughout the body under the skin and around organs.
- **Dense regular collagenous CT.** The difference between loose and dense CT is obvious in Figure 5.6A. **Dense regular collagenous CT** consists primarily of collagen fibers arranged in parallel bundles with little ground substance and few cells. It is exceptionally strong and makes up structures that require tensile strength in a single plane, such as tendons and ligaments.

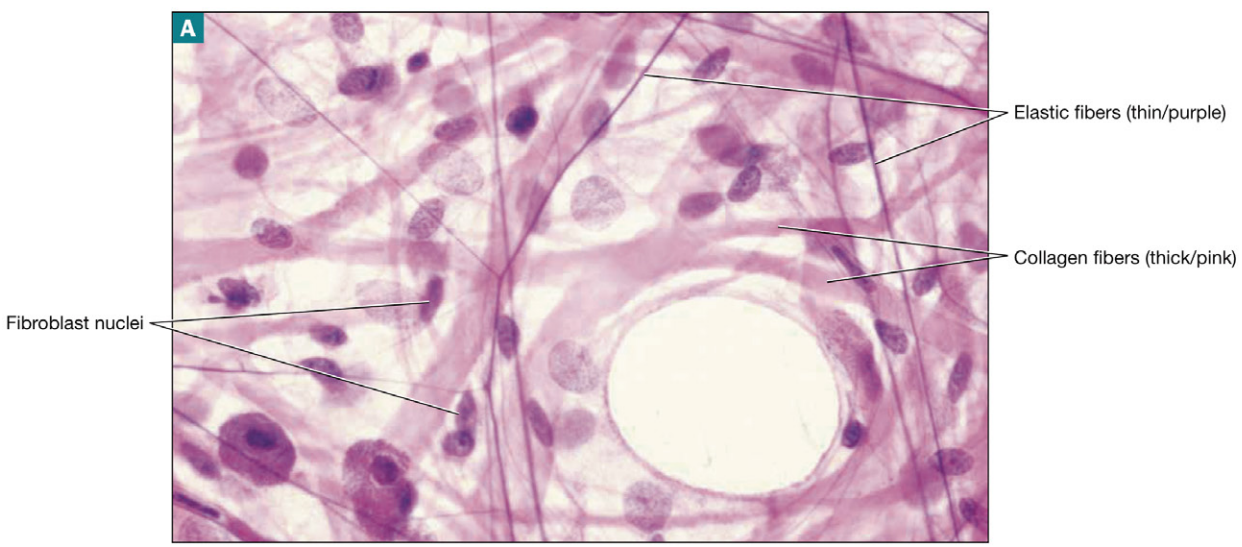

FIGURE **5.5** Loose connective tissues: (**A**) loose (areolar) CT; *(continues)*

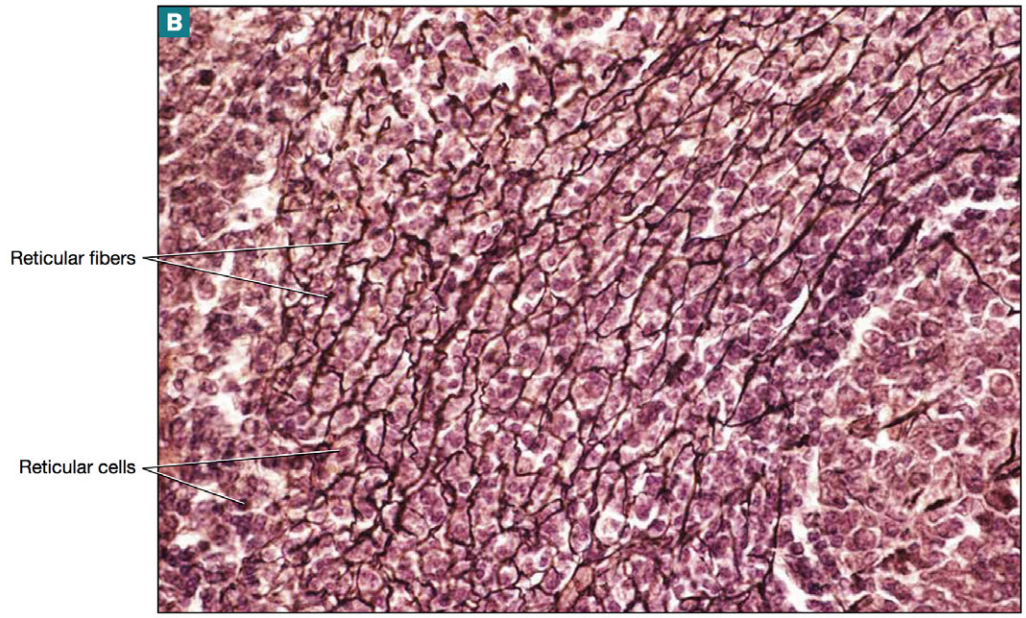

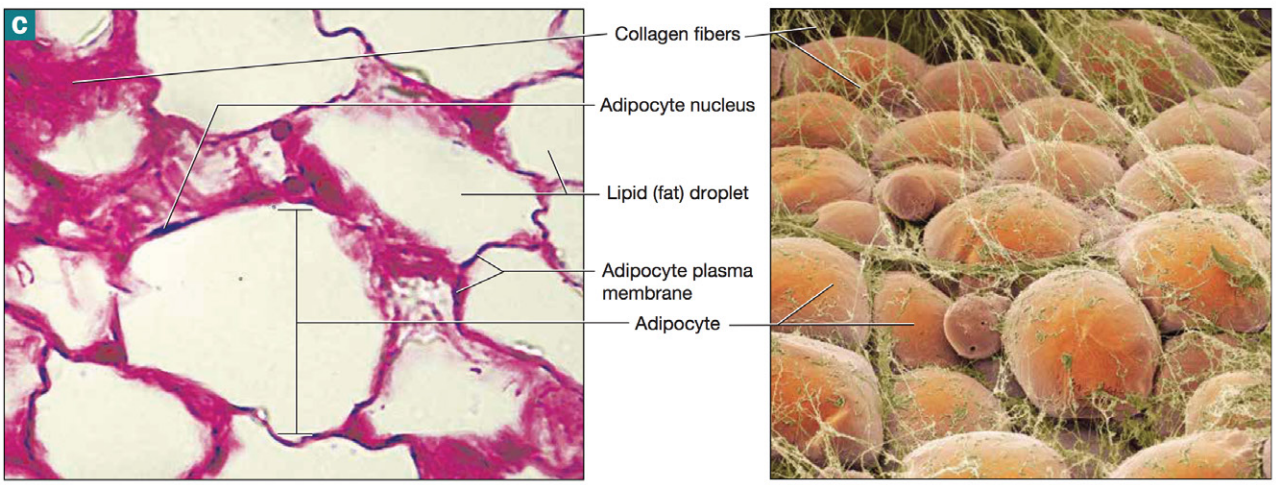

FIGURE **5.5** Loose connective tissues *(cont.)*: (**B**) reticular CT from the spleen; (**C**) adipose tissue, light micrograph and SEM.

- **Dense irregular collagenous CT.** Like dense regular collagenous CT, **dense *irregular* collagenous CT** consists of bundles of collagen fibers. Notice in Figure 5.6B, however, that these collagen bundles are arranged in an irregular, haphazard fashion without a consistent pattern. You can see the difference clearly in the scanning electron micrographs of the two tissues. Like dense regular collagenous CT, dense irregular collagenous CT also is quite strong. The arrangement of its collagen bundles makes it well-suited to support structures that require tensile strength in multiple planes, such as the dermis of the skin and joint and organ capsules.
- **Dense elastic CT. Dense elastic CT** contains elastic fibers arranged in parallel bundles (Fig. 5.6C). We find dense elastic CT in organs that need to be both distensible and elastic. A good example of such organs are large blood vessels, which are subject to pressure changes and so must be able to change size with each heartbeat. We also find this tissue type in certain ligaments, which allows them to be supportive without tearing when stretched.

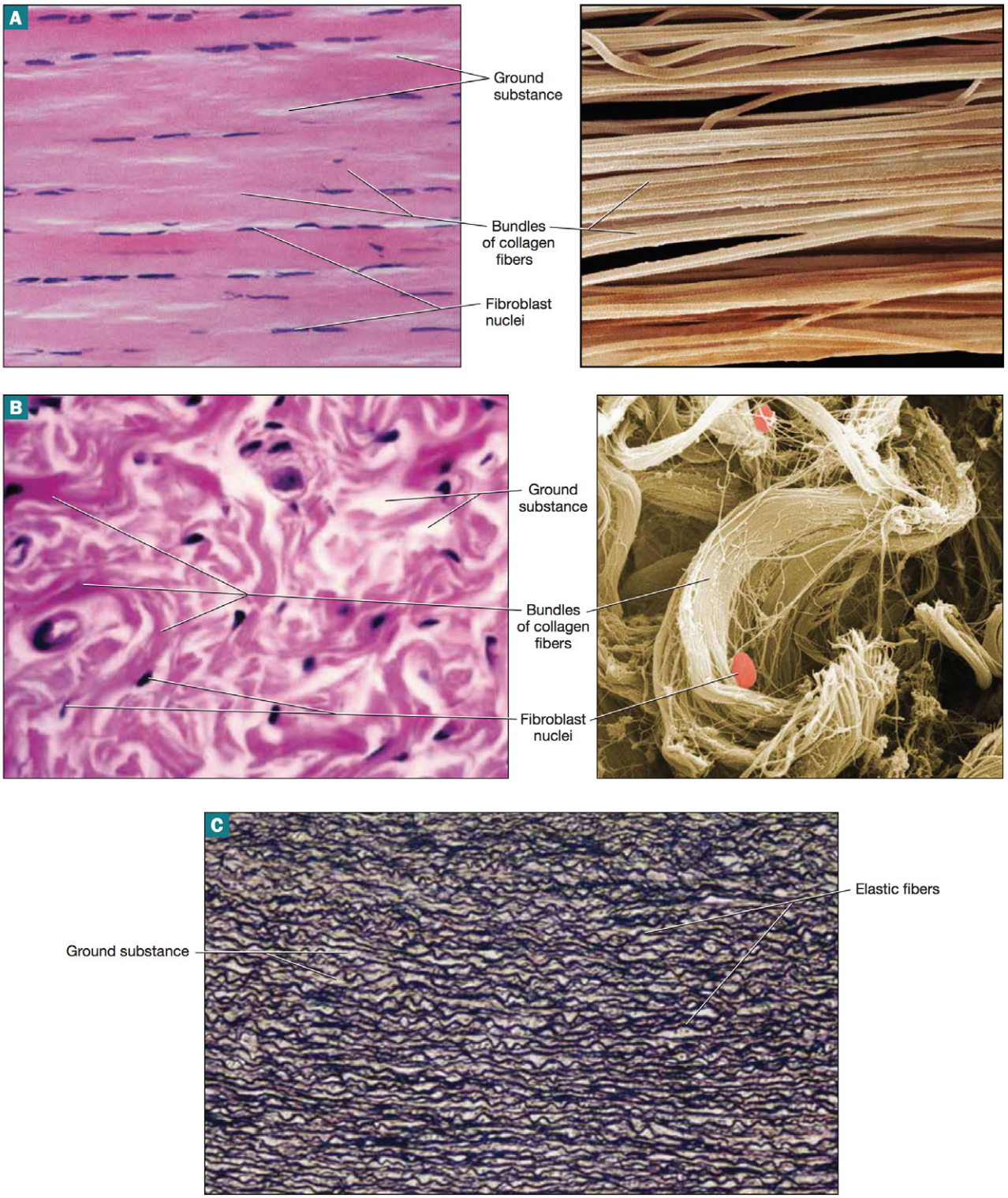

FIGURE **5.6** Dense connective tissues: (**A**) dense regular collagenous CT from a tendon, light micrograph and SEM; (**B**) dense irregular collagenous CT from the dermis, light micrograph and SEM; (**C**) dense elastic CT from the aorta.

2. **Cartilage. Cartilage** is a tough but flexible tissue that is resistant to tension, twisting, and compressive forces. It consists of cells called **chondrocytes** (KAHN-droh-syt'z) located in cavities called **lacunae** (lah-KOO-nee) embedded in the ECM. Cartilage is notable among the connective tissues for being avascular. Each of the three types of cartilage has a different ECM composition.

   - **Hyaline cartilage.** Notice in Figure 5.7A that **hyaline cartilage** (HY-ah-lin) contains mostly chondrocytes scattered in ground substance with few visible protein fibers. This gives hyaline cartilage a smooth, glassy appearance and makes it an ideal tissue to cover the ends of bones where they form joints with another bone. The smooth texture of hyaline cartilage provides a nearly frictionless surface on which bones can articulate. Hyaline cartilage also is found connecting the ribs to the sternum, in the nose, and forming the framework for certain respiratory passages.
   - **Fibrocartilage.** As you can see in Figure 5.7B, **fibrocartilage** is named appropriately because its ECM is full of protein fibers (mostly collagen). This makes fibrocartilage tough and extremely strong but not very smooth (think of the surface of fibrocartilage like a flannel sheet, with the cotton fibers representing the protein fibers). For this reason, fibrocartilage does not form articular cartilage, but it does reinforce ligaments and form *articular discs*, tough structures that improve the fit of two bones. In addition, fibrocartilage is found in intervertebral discs, structures between two vertebrae that help to support the weight of the vertebral column and absorb shock.
   - **Elastic cartilage.** The final type of cartilage, **elastic cartilage**, is shown in Figure 5.7C. Its ECM is filled with elastic fibers that allow it to stretch and recoil. Elastic cartilage is found in the ear and in the epiglottis.

HINTS & TIPS

Identifying Connective Tissue

Connective tissue really isn't as confusing as it seems. If you approach these slides systematically, use the figures in this manual as a guide, and, of course, don't panic, you will find they are surprisingly simple. Remember, everything in the field of view is only one of two things: cells or ECM.

The following points will help you to identify the various connective tissues and differentiate them from other tissue types:

- Usually in connective tissue, you will see a large amount of space between the cells because they aren't packed tightly together (adipose tissue is an exception). Remember to look for the nucleus to find the cells.
- You will often see a lot of straight or wavy lines running through a connective tissue section. These are just protein fibers. Many types of CT can be distinguished by the types of fibers they contain:
  - Reticular fibers are the thinnest fibers, and they require a special stain to be visible. As you saw in Figure 5.5B (p. 112), this stain makes reticular fibers brownish-black. In general, only reticular tissue is prepared with this stain, so if you see brownish-black reticular fibers, you know you are looking at reticular tissue.
  - Collagen fibers are thick fibers that usually stain pink or light purple. Look for collagen fibers in fibrocartilage, dense regular collagenous CT, dense irregular collagenous CT, and loose CT. The arrangement of the collagen fibers can tell you even more about the tissue. Are the fibers arranged haphazardly (basically, does your slide look like an undefined mess)? Then it's loose CT. Are they arranged in straight rows? Then it's dense regular collagenous CT. Are there small, wavy bundles of collagen? Then it's dense irregular collagenous CT.
  - Elastic fibers are thinner than collagen fibers and may have a wavy appearance. Their color ranges from purple-black to blue, depending on the stain used. Look for them in dense elastic CT, elastic cartilage, and loose CT. Dense elastic CT and elastic cartilage are easy to tell apart. Are there many visible cells among the elastic fibers? Then it's elastic cartilage. Is it almost exclusively fibers with few, if any cells? Then it's dense elastic CT.
- Cartilage is easy to differentiate from CT proper by looking at the shape of the cells. Fibroblasts are generally small and flat, and often appear as just purple dots. Chondrocytes are also fairly small, but they sit in lacunae, which creates a clear space around the cells. This makes the cells much easier to see and makes them appear to be bigger.
- Blood and bone are perhaps the two easiest tissues you will examine in this lab. They should look much like they do in Figures 5.8 and 5.9 (p. 116), and no other tissues resemble them.

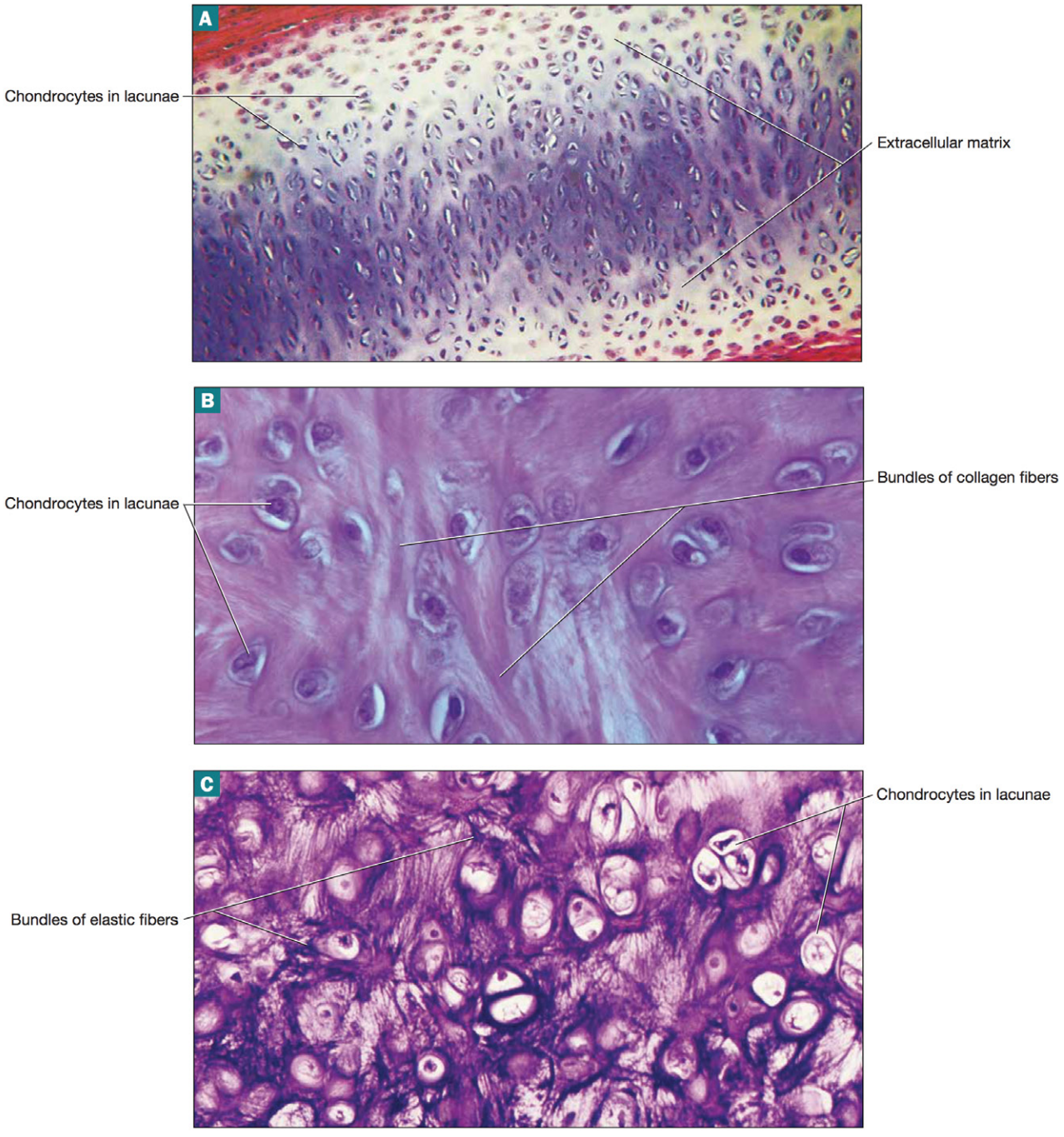

FIGURE **5.7** Cartilaginous connective tissues: (**A**) hyaline cartilage from a joint; (**B**) fibrocartilage from an articular disc; (**C**) elastic cartilage from the ear.

3. **Bone.** Bone tissue, also called **osseous tissue** (AHS-see-us), consists of bone cells called **osteocytes** (AHS-tee-oh-syt′z) encased in an ECM that contains collagen fibers and calcium hydroxyapatite crystals. Note in Figure 5.8 that the ECM is arranged in concentric layers called **lamellae** (lah-MELL-ee), with the osteocytes sandwiched between them. This structure makes bone one of the hardest tissues in the body and very resistant to mechanical stresses.

4. **Blood. Blood** (Fig. 5.9) consists of a liquid ECM called **plasma,** within which we find cells called **erythrocytes** (eh-RITH-roh-syt′z; red blood cells) and **leukocytes** (LOO-koh-syt′z; white blood cells), and cellular fragments called **platelets.** Its main role is to transport oxygen, nutrients, electrolytes, wastes, and many other substances through the body. Note that blood features the only cell type in the body that lacks a nucleus: the mature erythrocyte.

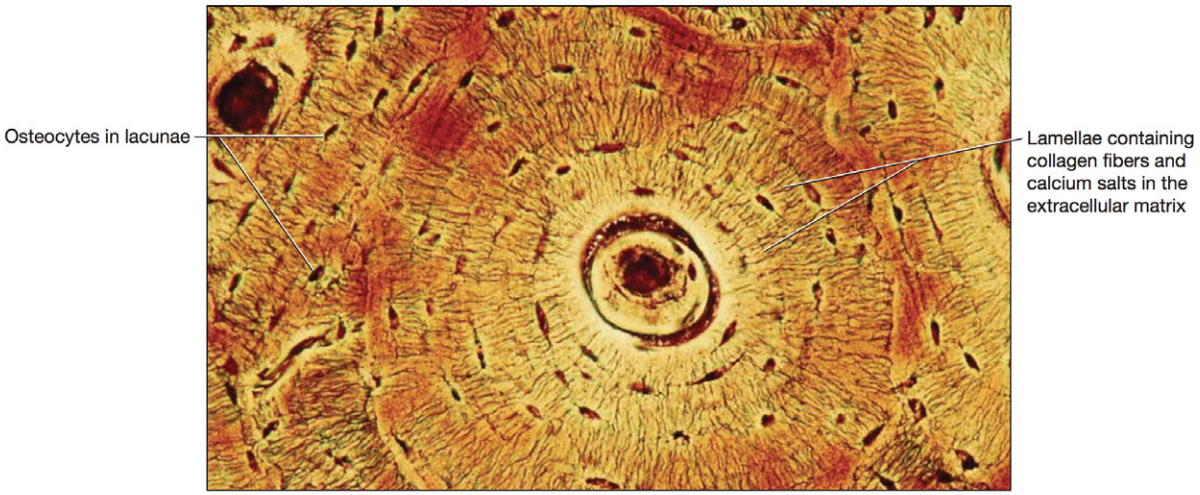

FIGURE **5.8** Bone tissue.

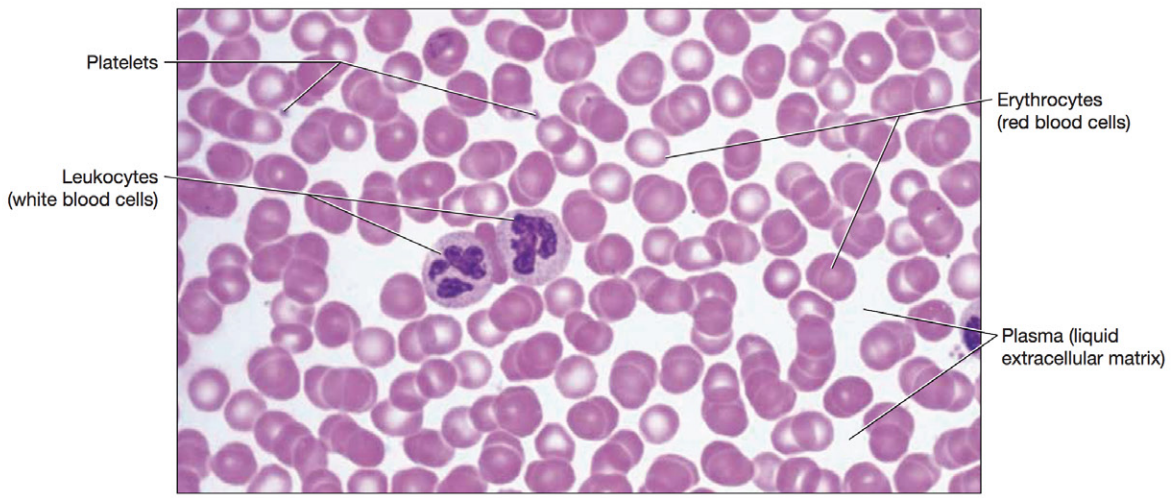

FIGURE **5.9** Blood.

Procedure 1 Microscopy of Connective Tissue Proper

View prepared slides of each type of connective tissue proper. Use colored pencils to draw pictures of what you see under the microscope, and label your drawings with the terms from Figures 5.5 and 5.6 (pp. 111–113), Then (a) describe what you see, and (b) give examples of locations in the body where this tissue is found. When you have completed the exercise, answer Check Your Understanding question 3 (p. 131).

1 Loose (areolar) CT



a _____

b _____

2 Reticular CT



a _____

b _____

3 Adipose tissue



a _____

b _____

4 Dense regular collagenous CT

a _____

b _____



5 Dense irregular collagenous CT

a _____

b _____



6 Dense elastic CT

a _____

b _____



Procedure 2 Microscopy of Cartilage

View prepared slides of the three types of cartilage. Use colored pencils to draw pictures of what you see under the microscope, and label your drawings with the terms from Figure 5.7 (p. 115). Then (a) describe what you see, and (b) give examples of locations in the body where this tissue is found. When you have completed this activity, answer Check Your Understanding question 4 (p. 131).

1 Hyaline cartilage

a _____

b _____



2 Fibrocartilage

a _____

b _____



3 Elastic cartilage

a _____

b _____



Procedure 3 Microscopy of Bone and Blood

View prepared slides of bone and blood. Use colored pencils to draw pictures of what you see under the microscope, and label your drawings with the terms in Figures 5.8 and 5.9 (p. 116). Then (a) describe what you see, and (b) give examples of locations in the body where this tissue is found.

1 Bone

a _____

_____

_____

b _____

_____

_____



2 Blood

a _____

_____

_____

b _____

_____

_____



Exercise 5-3

Muscle Tissue

MATERIALS

- ❑ Muscle tissue slides
- ❑ Light microscope
- ❑ Colored pencils

Muscle tissue is located in skeletal muscles, in the walls of hollow organs, in the heart, and in other locations such as the iris of the eye. It consists of muscle cells, sometimes called **myocytes** (MY-oh-syt′z) or **muscle fibers**, and a small amount of ECM called the **endomysium** (en-doh-MY-see-um). Note that the endomysium blends with connective tissue surrounding groups of muscle fibers and is often called connective tissue as a result. As you can see in Figures 5.10A–C, myocytes aren't shaped like the cells of epithelial or connective tissues. This makes muscle tissue easy to tell apart from most other tissue types.

There are three types of muscle tissue:

1. **Skeletal muscle tissue.** The muscle fibers of **skeletal muscle tissue** are long, tubular, and **striated** (STRY-ayt-ed; striped) in appearance (Fig. 5.10A). The striations result from the arrangement of proteins within the muscle fiber called **myofilaments**. Skeletal muscle fibers are formed from the fusion of cells called **myoblasts** and thus have multiple nuclei. This type of muscle tissue is *voluntary*, which means that its contraction is under conscious control. For this reason, it has a close relationship with the nervous system and nervous tissue, because skeletal muscle fibers must be stimulated by a nerve cell to contract.
2. **Cardiac muscle tissue.** The myocytes of **cardiac muscle tissue**, located in the heart, are short, wide, striated, and tend to be branching (Fig. 5.10B). Cardiac myocytes typically have only one nucleus, but some may have two or more. Adjacent cardiac myocytes are linked by specialized junctions called **intercalated discs** (in-TUR-kuh-layt-ed) that contain desmosomes and gap junctions. Intercalated discs link all cardiac myocytes physically and electrically so that the heart may contract as a unit. Cardiac muscle tissue is *involuntary* and *autorhythmic*, meaning that it requires no outside stimulus from the nervous system to contract. (Note, however, that the nervous system can influence the rate and force of cardiac muscle contraction.)
3. **Smooth muscle tissue.** The myocytes of **smooth muscle tissue** are flat with a single nucleus in the center of the cell (Fig. 5.10C). The arrangement of myofilaments within smooth muscle fibers differs from that of skeletal and cardiac muscle fibers, and as a result, these cells lack noticeable striations (hence the name *smooth* muscle). Smooth muscle lines all hollow organs and is found in the skin, the eyes, and surrounding many glands. Like cardiac muscle tissue, smooth muscle tissue is involuntary. However, although there are populations of smooth muscle cells that are autorhythmic, much of our smooth muscle requires stimulation from the nervous system to contract.

We revisit each type of muscle tissue in later units in this book.

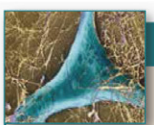

HINTS & TIPS

Identifying Muscle Tissue

The three types of muscle tissue aren't that difficult to tell apart from one another. The only two that might give you troubles are skeletal and cardiac muscle tissues, but if you remember that cardiac muscle tissue has intercalated discs, you shouldn't have any problems. However, sometimes students mistake skeletal or smooth muscle tissue for an entirely different tissue type: dense regular collagenous CT.

Take a look back to Figure 5.6A (p. 113). Notice how the collagen bundles are arranged in a way that almost looks like the tubular skeletal muscle fibers? And notice also how the nuclei of the fibroblasts have the same shape and arrangement as those of smooth muscle cells? Both of these situations can cause students to sometimes mix up these tissue types, so careful examination is needed to prevent these mistakes:

- Look closely at the "tubes" to see if they have striations running through them. If there are striations, as in Figure 5.10A, the section is skeletal muscle tissue.
- If there are no striations, look more closely at the nuclei.
  - Advance to a higher-power objective lens and look for plasma membranes or boundaries around each nucleus, which you can see in Figure 5.10D. If you can find plasma membranes around the nuclei, you are looking at smooth muscle tissue.
  - If you can't see any boundaries around the nuclei, and the space between the nuclei looks slightly fuzzy rather than well-defined, you're probably looking at dense regular collagenous CT.

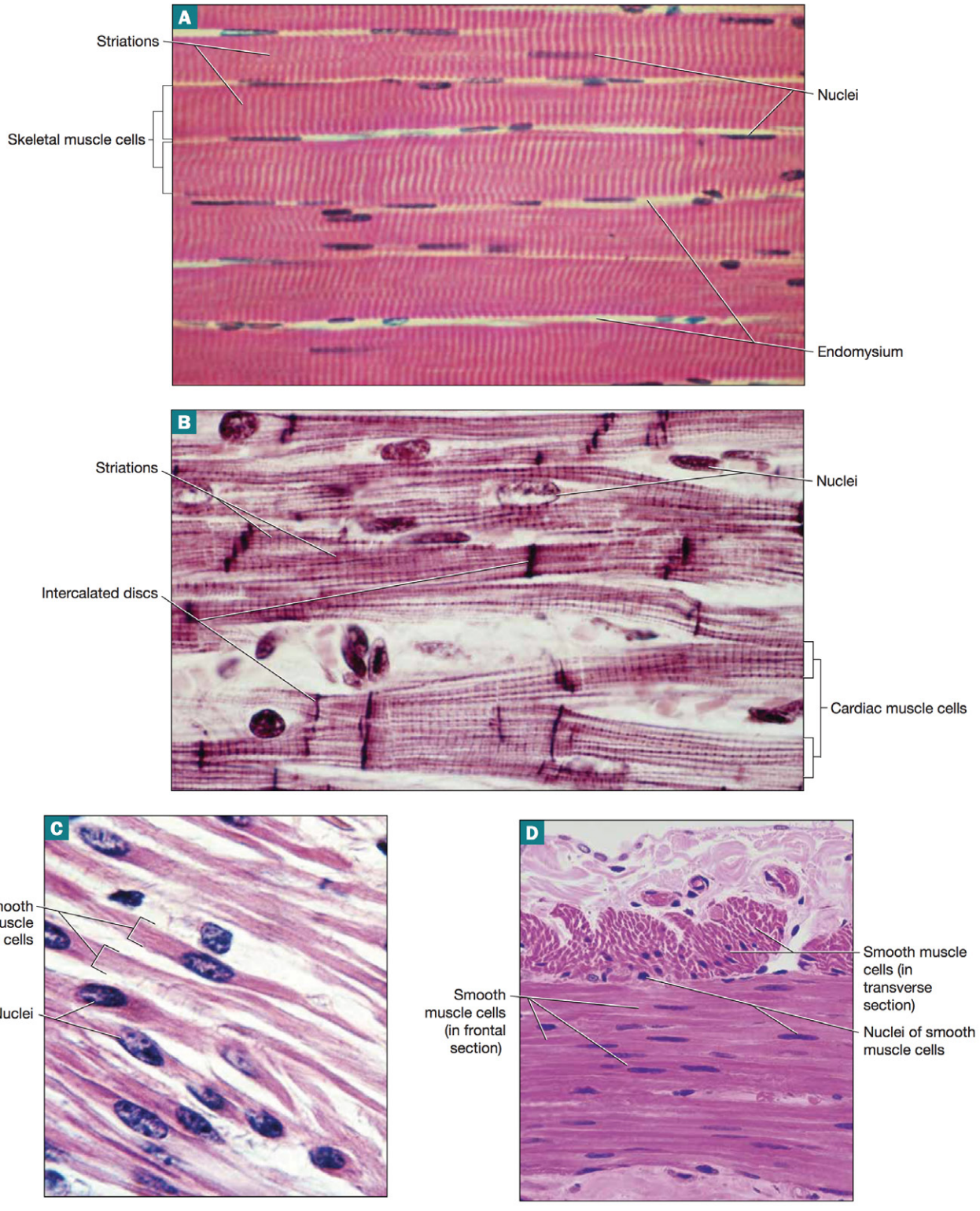

FIGURE **5.10** Muscle tissue: (**A**) skeletal muscle tissue; (**B**) cardiac muscle tissue; (**C**) teased smooth muscle cells; (**D**) smooth muscle cells in an organ.

Procedure 1 Microscopy of Muscle Tissue

View prepared slides of skeletal, smooth, and cardiac muscle tissue. Use colored pencils to draw what you see under the microscope, and label your drawing with the terms from Figure 5.10. Record your observations of each slide in Table 5.1. When you have completed the microscope slides, answer Check Your Understanding question 5 (p. 132).

1 Skeletal muscle

a _____

b _____



2 Cardiac muscle

a _____

b _____



3 Smooth muscle

a _____

b _____



TABLE **5.1** Characteristics of Muscle Tissues

Muscle Tissue Type	Striated or Nonstriated	One or Multiple Nuclei	Size and Shape of Cells	Special Features
Skeletal muscle				
Cardiac muscle				
Smooth muscle				

Exercise 5-4

Nervous Tissue

MATERIALS

- ❑ Nervous tissue slides
- ❑ Light microscope
- ❑ Colored pencils

Nervous tissue (Fig. 5.11) is the primary component of the brain, the spinal cord, and the peripheral nerves. It consists of a unique ECM and two main cell types:

1. **Neurons**. The **neurons** (NOOR-ahnz) are responsible for sending and receiving messages within the nervous system. On your slide they are the larger of the two cell types. The large, central portion of the neuron is called the **cell body**. Within the cell body we find the nucleus and many of the neuron's organelles, including clusters of rough endoplasmic reticulum called **Nissl bodies**. Most neurons contain two types of long armlike processes extending from the cell body—the **dendrites** (DEN-dryt'z), which receive messages from other neurons, and the **axon** (AX-ahn), which sends messages to other neurons, muscle cells, or gland cells.
2. **Neuroglial cells**. The smaller and more numerous cells around the neurons are the **neuroglial cells** (noor-oh-GLEE-uhl). The six different types of neuroglial cells vary significantly in shape and appearance. Neuroglial cells in general perform functions that support the neurons or the ECM in some way.

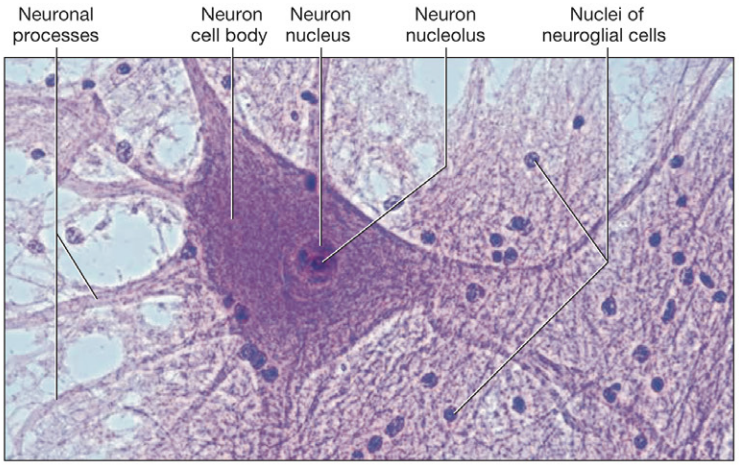

FIGURE **5.11** Nervous tissue.

Procedure 1 Microscopy of Nervous Tissue

View a prepared slide of nervous tissue (the slide might be called a "motor neuron smear"). Use colored pencils to draw a picture of what you see under the microscope, and label your drawing with the terms from Figure 5.11. Then (a) describe what you see, and (b) give examples of locations in the body where this tissue is found.

1 Nervous tissue

a _____

b _____



Exercise 5-5

Organology

All organs consist of two or more tissues that must work together to enable the organ to function properly. The study of the tissues that make up the body's organs is called **organology**. Most organs are made of layers of tissues stacked upon one another and "glued" together by proteins and other compounds in the ground substance. This exercise introduces you to organology, a topic we explore repeatedly in the remainder of this lab manual.

Procedure 1 Determine the Tissue Types of Organs

Following are illustrations of two organs: a joint and the esophagus (Fig. 5.12). Tissue sections from each organ have been taken, and your task is to identify each tissue. Be specific about which type of muscle, epithelial tissue, and connective tissue you identify in the organ. When you have completed the procedure, answer Check Your Understanding question 6 (p. 132).

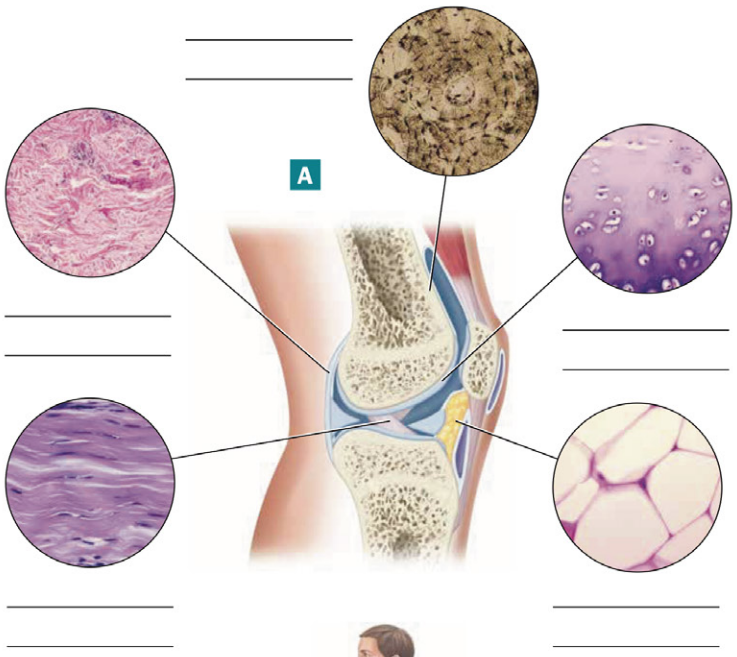

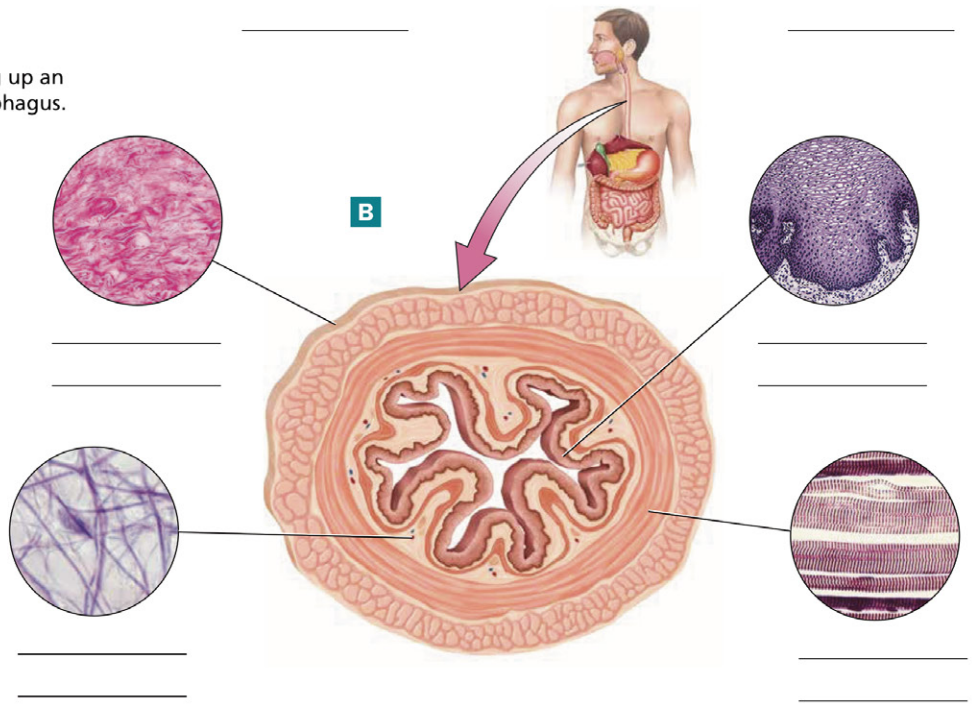

FIGURE **5.12** Tissues making up an organ: (**A**) a joint; (**B**) the esophagus.

Name _____

Section _____ Date _____

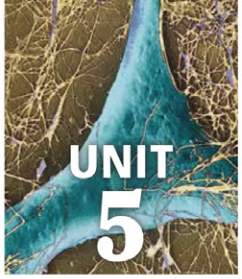

Check Your Recall

REVIEW

5

1 Identify each of the following tissues in Figure 5.13.

a _____ **e** _____

b _____ **f** _____

c _____ **g** _____

d _____ **h** _____

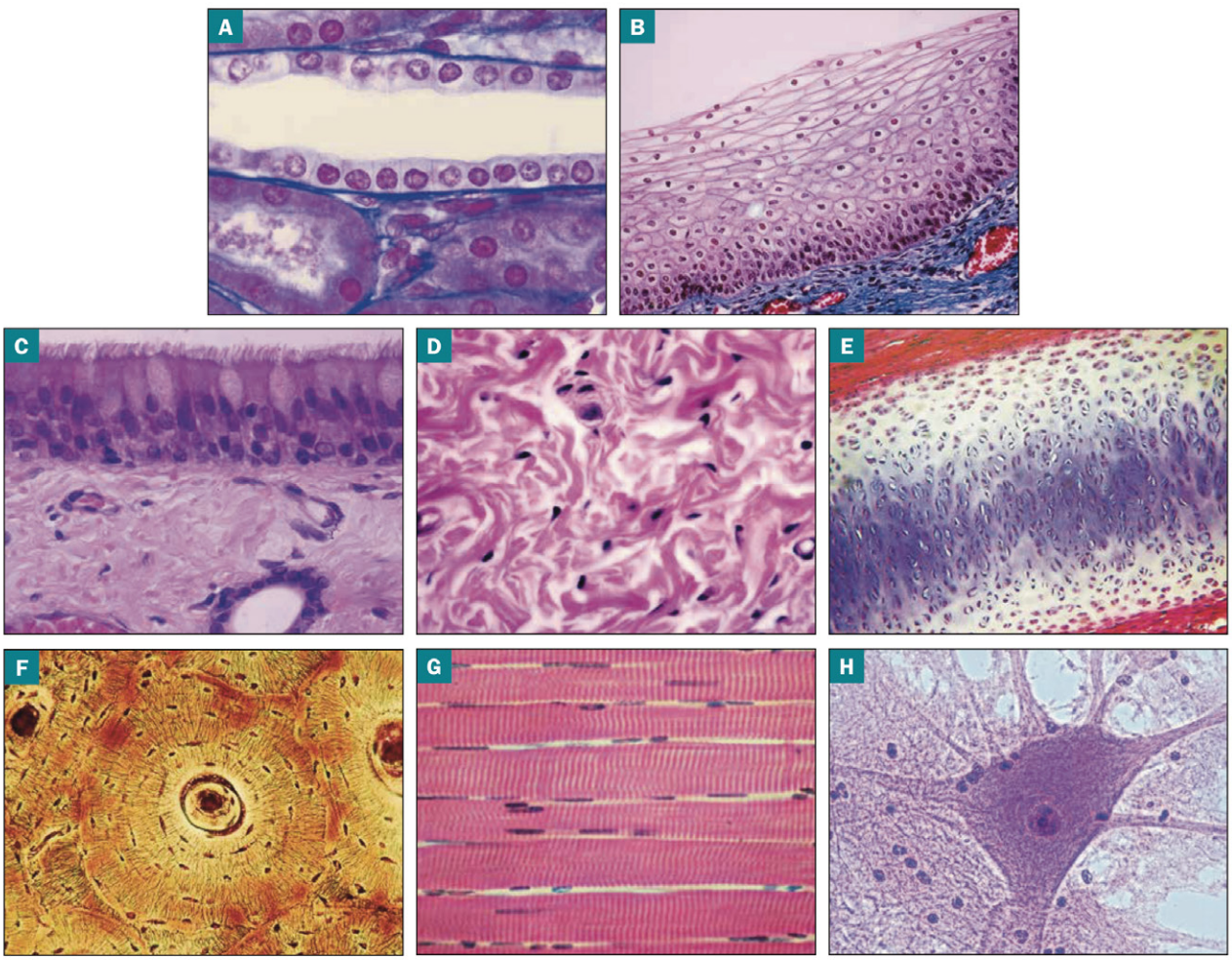

FIGURE **5.13** Unknown tissues for question 1.

2 *Fill in the blanks:* All tissues consist of two main components: _____ and _____, which consists of a gelatinous substance called _____ and numerous different _____.

3 An epithelial tissue that has one layer of rectangular cells would be classified as

a. stratified squamous epithelium.
b. simple cuboidal epithelium.
c. stratified columnar epithelium.
d. simple columnar epithelium.

4 How do pseudostratified ciliated columnar epithelium and transitional epithelium differ from other types of epithelia?

5 *True/False:* Mark the following statements concerning connective tissue proper and cartilage as true (T) or false (F). If the statement is false, correct it to make it a true statement.

_____ Adipocytes contain a large lipid droplet in their cytoplasm.

_____ The primary element in dense regular collagenous connective tissue is ground substance.

_____ Bundles of collagen fibers are arranged parallel to one another in dense irregular collagenous connective tissue.

_____ Loose connective tissue contains all three protein fiber types.

_____ Fibrocartilage has a smooth, glassy appearance due to a large amount of ground substance and few visible protein fibers.

6 Which of the following best characterizes the extracellular matrix (ECM) of bone tissue?

a. Bone tissue ECM consists of only calcium hydroxyapatite crystals.
b. Bone tissue ECM consists of calcium hydroxyapatite crystals and collagen fibers.
c. Bone tissue ECM consists of only collagen fibers.
d. Bone tissue ECM consists of collagen, elastic, and reticular fibers.

7 *Circle all that apply.* Which of the following characteristics apply to skeletal muscle tissue?

a. Striated.
b. Nonstriated.
c. Multinucleate.
d. Uninucleate.
e. Contains intercalated discs.
f. Voluntary.
g. Involuntary.
h. Autorhythmic.

Name _____

Section _____ Date _____

8 What is the function of intercalated discs?

_____

_____

9 *Fill in the blanks:* Nervous tissue is composed of _____ and two types of cells: _____ and _____.

10 *Matching:* Match the tissue type with its location in the body.

_____ Simple squamous epithelium

_____ Transitional epithelium

_____ Loose CT

_____ Cardiac muscle

_____ Nervous tissue

_____ Stratified squamous nonkeratinized epithelium

_____ Hyaline cartilage

_____ Smooth muscle

_____ Dense regular collagenous CT

_____ Reticular CT

A. Part of the basement membrane, walls of hollow organs
B. Spleen and lymph nodes
C. Air sacs of the lungs
D. Oral cavity, pharynx, vagina, anus
E. Lining hollow organs, in the skin, in the eye, and surrounding many glands
F. Brain, spinal cord, peripheral nerves
G. Urinary bladder
H. Tendons and ligaments
I. Joints, connecting the ribs to the sternum, nose
J. In the heart

Name _____

Section _____ Date _____

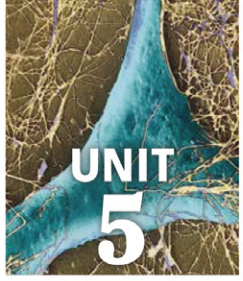

Check Your Understanding

REVIEW

5

Critical Thinking and Application Questions

1 The structure in the lungs known as the *respiratory membrane* is where gases are exchanged—oxygen leaves the lungs and enters the blood, and carbon dioxide leaves the blood and enters the lungs. The respiratory membrane is composed of two extremely thin layers of simple squamous epithelium. Explain how the structure of the respiratory membrane follows its function.

2 Predict what you think might happen if the respiratory membrane were instead composed of two layers of stratified squamous epithelium. Explain.

3 The condition *Marfan syndrome* results from the production of abnormal elastin, the main protein component of elastic fibers. Predict the potential consequences of defective elastic fibers. (***Hint:*** Consider the organs and tissues in which elastic fibers are found. How would defective elastic fibers impair the functions of these organs and tissues?)

4 *Collagenopathies*, conditions characterized by the production of one or more types of defective collagen proteins, are in a group of disorders called *connective tissue diseases*. Many collagenopathies feature arthritis or other joint problems as part of the symptoms of the disorder. Why would defective collagen proteins affect an individual's joints?

5 When muscle tissue dies, it usually is replaced with dense irregular collagenous connective tissue. How do these tissues differ in structure? Will the muscle be able to function normally? Why or why not?

6 A hypothetical organ has the following functional requirements: (1) the ability to resist surface abrasion and mechanical stresses; (2) the ability to contract involuntarily when stimulated by cells of the nervous system; and (3) the ability to resist tension in many different planes of force. The organ needs one tissue to carry out each of these requirements, and it also needs one tissue to "glue" all other tissues together, and one tissue to stimulate the contracting cells. What are the five tissues that will make up this hypothetical organ? Justify your choices.

UNIT
6

Integumentary System

Once you have completed this unit, you should be able to:

1. Identify structures of the integumentary system.
2. Describe the gross and microscopic structure of thick and thin skin.
3. Map the distribution of touch receptors on different areas of the body.

Name _____ Section _____ Date _____

PRE-LAB EXERCISES

Complete the following exercises prior to coming to lab, using this lab manual and your textbook for reference.

Pre-Lab Exercise 6-1



6

Key Terms

You should be familiar with the following terms before coming to lab.

Term	Definition

Epidermal Structures

Epidermis _____

Keratinocyte _____

Melanocyte _____

Stratum corneum _____

Stratum lucidum _____

Stratum granulosum _____

Stratum spinosum _____

Stratum basale _____

Structures of the Dermis

Dermis _____

Dermal papillae _____

Lamellated corpuscle _____

Tactile corpuscle _____

Name _____ Section _____ Date _____

Arrector pili muscle _____

Accessory Structure and Other Structures

Hypodermis _____

Sweat gland _____

Sebaceous gland _____

Hair follicle _____

Nails _____

Pre-Lab Exercise 6-2

Skin Anatomy

Label and color the structures of the skin in Figure 6.1 with the terms from Exercise 6-1 (p. 137). Use your text and Exercise 6-1 in this unit for reference.

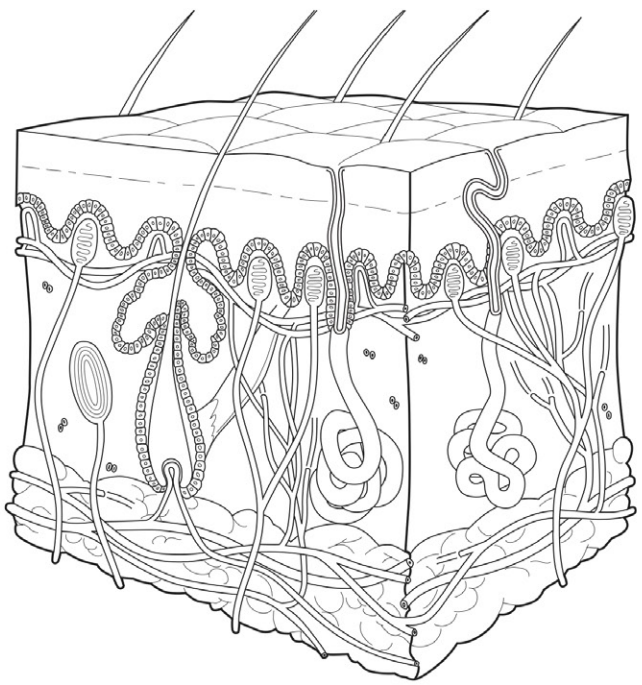

FIGURE **6.1** Skin section.

Pre-Lab Exercise 6-3

Hair and Nail Anatomy

Label and color the structures of the hair and nail in Figure 6.2 with the terms from Exercise 6-1 (p. 137). Use your text and Exercise 6-1 in this unit for reference.

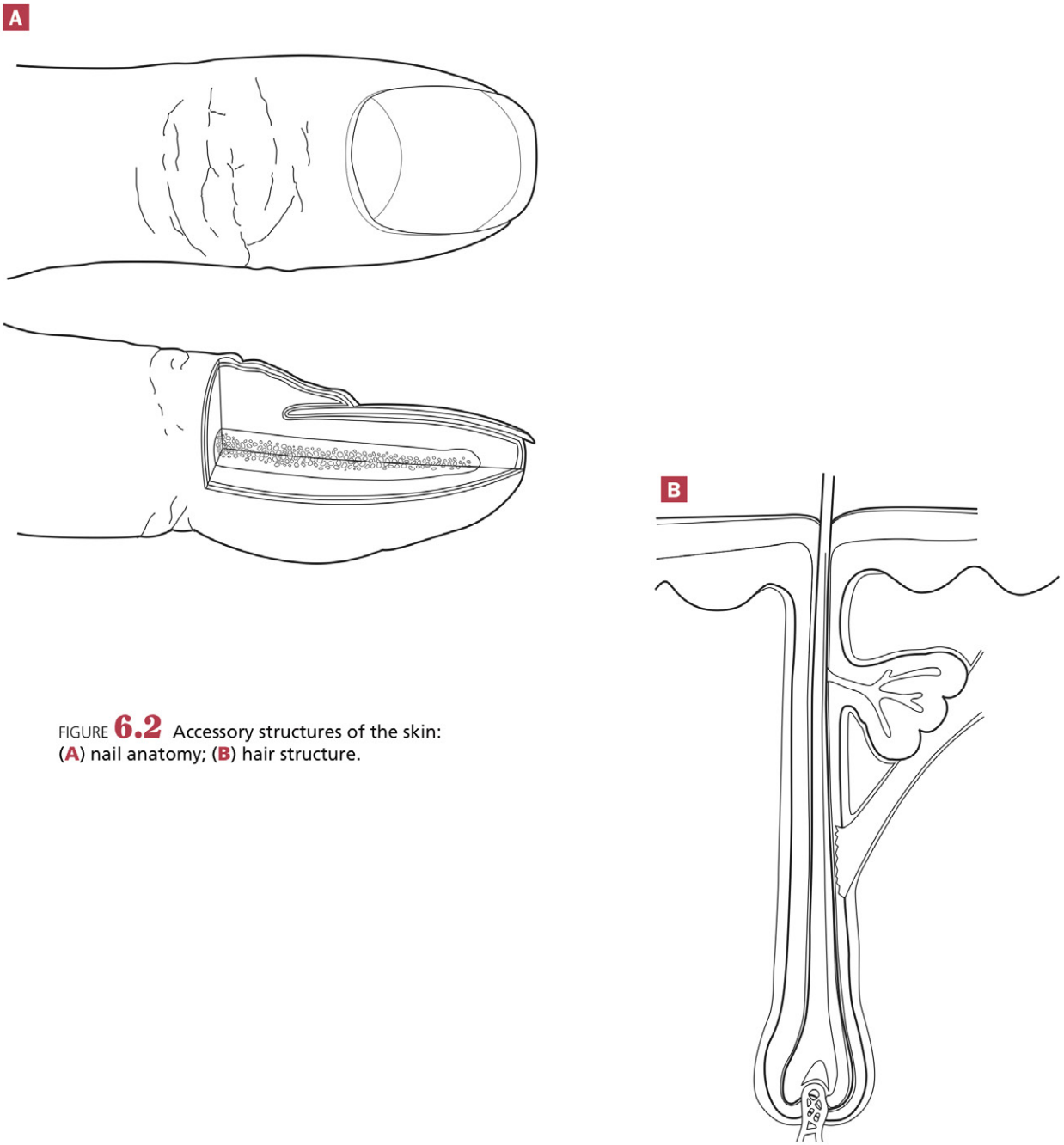

FIGURE **6.2** Accessory structures of the skin: (**A**) nail anatomy; (**B**) hair structure.

Colored SEM of a keratinocyte skin cell with a large central nucleus.

EXERCISES

Although the skin is the largest organ in the body, most people don't realize that it is actually an organ. Like all organs, the skin or **integument** (in-TEG-yoo-ment) is composed of several tissue types, including epithelial tissue, connective tissue, muscle tissue, and nervous tissue. In the following exercises you will examine the tissues of this organ, along with the other structures of the integumentary system, and apply your knowledge of skin anatomy to perform fingerprinting procedures.

Exercise 6-1

Skin Anatomy and Accessory Structures

MATERIALS

- ❑ Skin models and diagrams
- ❑ Colored pencils

The **integumentary system** is composed of the skin and its **accessory structures**: the *hair*, *glands*, and *nails*. The skin is composed of two general tissue layers: the *epidermis* and the *dermis*. The tissue beneath the dermis, called the **hypodermis** or the *subcutaneous tissue*, connects the skin to the underlying tissues and is not considered part of the integument. The hypodermis is richly supplied with blood vessels.

The **epidermis** contains layers (or *strata*) of stratified squamous keratinized epithelium. The predominant cell type found in the epidermis is the keratin-producing **keratinocyte** (kehr-ah-TIN-oh-sy't). Keratin is a hard protein that protects the skin from mechanical stresses. From superficial to deep, the layers of the epidermis are as follows (Fig. 6.3):

1. **Stratum corneum.** The superficial layer of cells, called the **stratum corneum** (STRAT-um KOHR-nee-um) is composed of dead keratinocytes. Under microscopic examination, the keratinocytes of the stratum corneum bear little resemblance to living cells and have a dry, flaky appearance. These cells typically appear dark purple or hot pink, which is due to the accumulation of keratin in their cytosol.
2. **Stratum lucidum.** The **stratum lucidum** (LOO-sid-um) is a single layer of translucent, dead keratinocytes found only in the skin of the palms and the soles of the feet.
3. **Stratum granulosum.** The third layer of keratinocytes is the **stratum granulosum** (gran-yoo-LOH-sum). Here the superficial keratinocytes are dead, but the deeper cells are alive. This layer is named for the cells' cytoplasmic granules, which contain keratin and a lipid-based substance. This lipid-based substance is found in **lamellar granules**, and helps to keep the skin water-resistant.
4. **Stratum spinosum.** The first actively metabolizing cells are encountered in the fourth cell layer, the **stratum spinosum** (spin-OH-sum). The pigment **melanin** (MEL-uh-nin) is found in this layer, which provides protection from UV light and also decreases production of vitamin D (to prevent the body from overproducing it).
5. **Stratum basale.** The **stratum basale** (bay-SAY-lee) is the deepest layer and consists of a single row of actively dividing keratinocytes. Here we also find **melanocytes** (mel-AN-oh-syt'z), which produce melanin, and sensory receptor cells called **Merkel cells** (also known as *tactile discs*), which function in light touch and texture discrimination.

Why does the epidermis have so many dead cells? Recall that the epidermis is composed of epithelial tissue, and epithelial tissue is avascular (has no blood supply). All epithelial tissues require oxygen and nutrients to diffuse to them from the deeper tissues. In the case of the epidermis, this deeper tissue is the dermis. Only the cells of the deeper parts of the stratum granulosum, the stratum spinosum, and the stratum basale are close enough to the blood supply in the dermis to get adequate oxygen and nutrients for survival. For this reason, as the cells migrate farther away from the blood supply, they begin to die.

Immediately deep to the stratum basale of the epidermis is the **basement membrane**, which consists of the basal lamina, composed of ECM produced by keratinocytes, and the reticular lamina, composed of ECM produced by the dermis. The basement membrane holds the epidermis in place with molecular "glue" that prevents it from separating from the dermis.

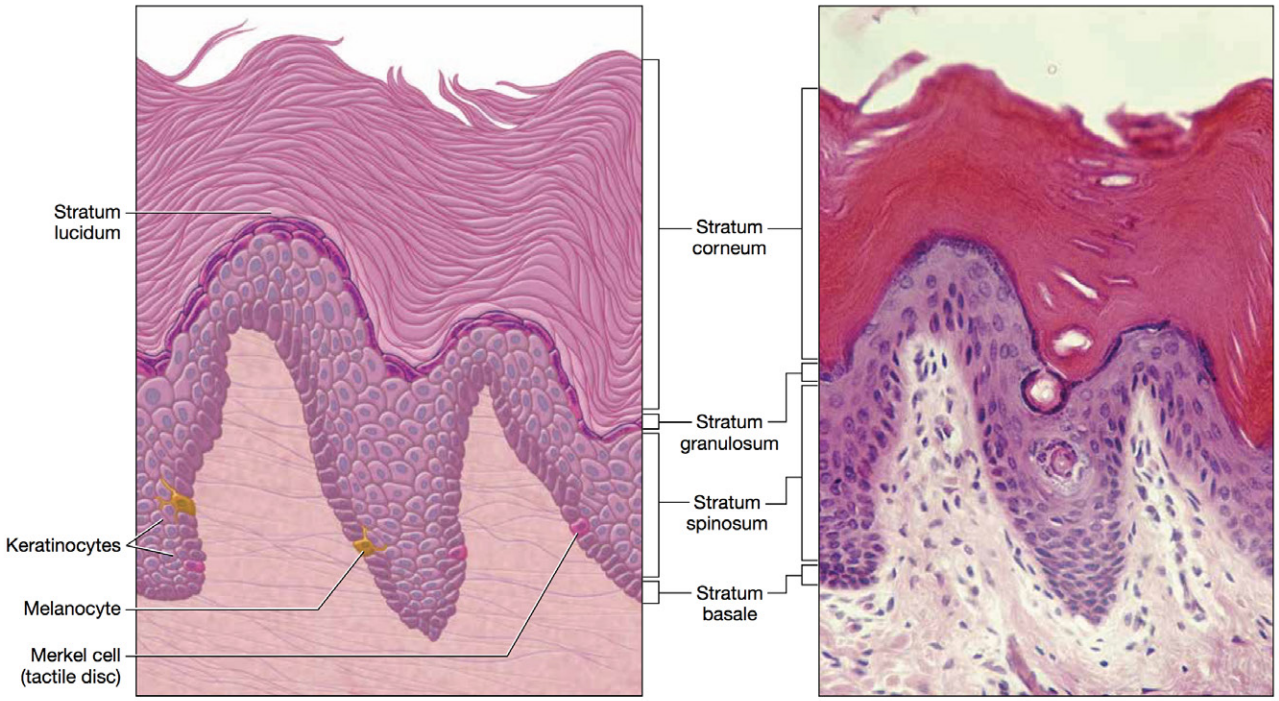

FIGURE **6.3** Layers of the epidermis.

Deep to the epidermis is the **dermis,** which is composed of highly vascular connective tissue. It consists of two layers (Fig. 6.4):

1. **Papillary layer.** The superficial **papillary layer** is composed of loose connective tissue. It contains fingerlike projections called the **dermal papillae** (pah-PILL-ee) that project into the epidermis, which you can see in Figure 6.4. The dermal papillae contain touch receptors called **tactile corpuscles** that detect fine touch and capillary loops that provide blood supply to the avascular epidermis.
2. **Reticular layer.** The thick **reticular layer** is composed of dense irregular collagenous connective tissue. It houses structures such as **sweat glands,** oil-producing **sebaceous glands** (seh-BAY-shuhs), blood vessels, and pressure receptors called **lamellated corpuscles.** Also within the reticular layer we find numerous *free nerve endings* that transmit pain sensations, which is why it hurts when you cut yourself down to the dermis.

Let's move on to accessory structures of the integumentary system. First are its sebaceous glands and sweat glands. **Sebaceous glands** are exocrine glands that secrete **sebum** (SEE-bum; oil). Notice in Figure 6.4 that sebaceous glands are associated with hairs and indeed they release sebum directly into a hair follicle. **Sweat glands** are also exocrine glands; however, notice that they secrete their product, *sweat*, through a **sweat duct.** There are two types of sweat glands. The type shown in Figure 6.4, the *eccrine sweat gland*, is found all over the body. This type of gland releases sweat onto the surface of the skin through a small **sweat pore.** The other type, the *apocrine sweat gland*, is found in the axillae and genital region. This type releases sweat into a hair follicle like a sebaceous gland.

Both hair and nails are also accessory structures of the integumentary system (Fig. 6.5). A **hair** consists of two basic parts: (a) the long, slender **shaft** composed of dead keratinocytes that projects from the skin's surface, and (b) the **hair root** embedded in the dermis (Fig. 6.5A). The base of the root is indented by a projection from the dermis called the **hair papilla;** the papilla and root together are known as the **hair bulb.** The hair is embedded in a sheath known as the **hair follicle.** The inner lining of the hair follicle is epithelium that is continuous with the epidermis, and the outer lining is dermal connective tissue. A band of smooth muscle called an **arrector pili muscle** (ah-REK-tohr PIL-aye) attaches to this dermal sheath, and can pull the hair into an upright or erect position when it contracts.

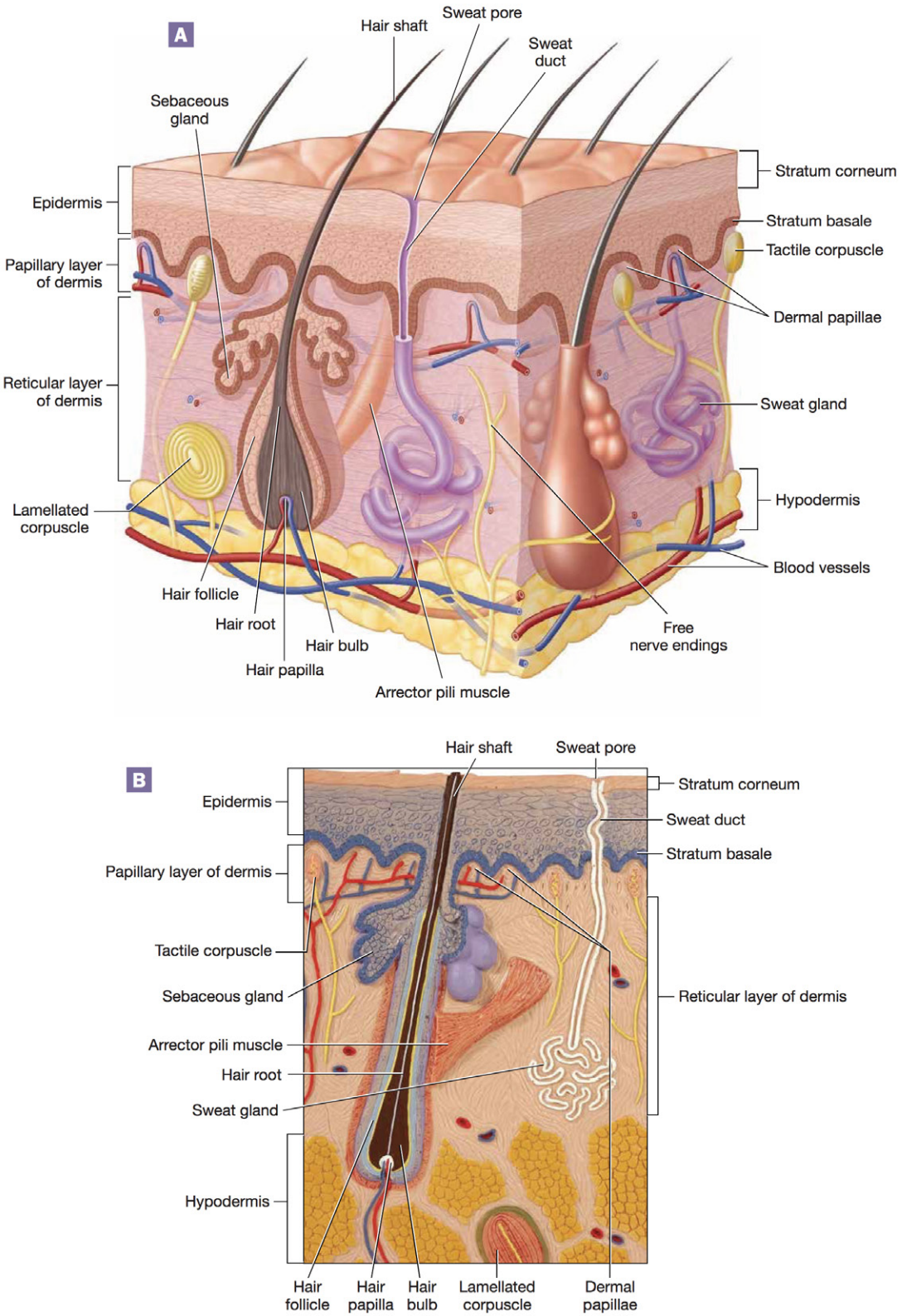

FIGURE **6.4** Skin section: (A) illustration; (B) anatomical model photo.

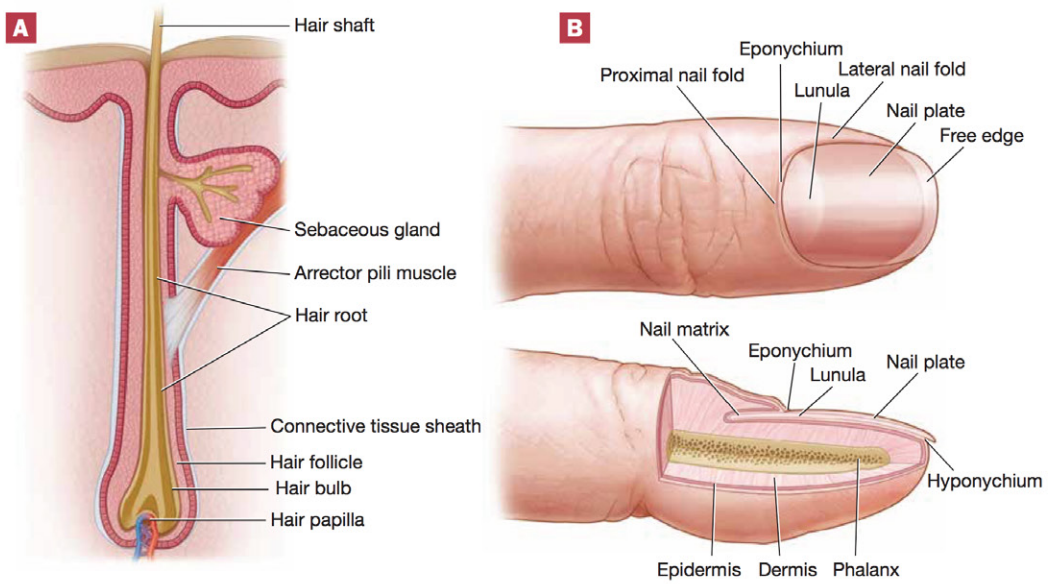

FIGURE **6.5** Accessory structures of the skin: (**A**) hair structure; (**B**) nail anatomy.

Like hairs, **nails** are composed primarily of dead keratinocytes (Fig. 6.5B). A nail consists of a flat **nail plate** surrounded by folds of skin on all three sides, known as **nail folds.** Those on the sides of the nails are **lateral nail folds,** and that at the base is the **proximal nail fold.** The stratum corneum of the proximal nail fold grows over the nail plate to form a thin structure called the **eponychium** (ep-oh-NIK-ee-um) or *cuticle*. Often near the eponychium, we find a thickened area of the nail plate, the **lunula** (LOON-yoo-luh), which generally has a half-moon shape (note that many nails lack a lunula). Deep to the proximal nail fold is a group of dividing cells from which the nail plate grows known as the **nail matrix.**

Procedure 1 Model Inventory for the Integumentary System

Identify the following structures of the integumentary system on models and diagrams, using your textbook and this unit for reference. As you examine the anatomical models and diagrams, record the name of the model and the structures you were able to identify on the model inventory in Table 6.1. When you have completed this activity, answer Check Your Understanding questions 1 through 4 (pp. 151–152).

Structures of the Skin

1. Epidermal layers
   a. Stratum corneum
   b. Stratum lucidum
   c. Stratum granulosum
   d. Stratum spinosum
   e. Stratum basale
2. Dermis
   a. Papillary layer
      (1) Dermal papillae
      (2) Tactile corpuscle
   b. Reticular layer
      (1) Lamellated corpuscle
3. Blood vessels

Accessory and Other Structures

1. Sebaceous gland
2. Sweat gland
   a. Sweat duct
   b. Sweat pore
3. Hair
   a. Hair shaft
   b. Hair root
   c. Hair papilla
   d. Hair bulb
   e. Hair follicle
   f. Arrector pili muscle
4. Nail
   a. Nail plate
   b. Nail fold (proximal and lateral)
   c. Eponychium
   d. Lunula
   e. Nail matrix
5. Hypodermis

TABLE **6.1** Model Inventory for the Integumentary System

Model/Diagram	Structures Identified

Procedure 2 Time to Draw

In the space below, draw, color, and label one of the skin models that you examined. In addition, write the main function of each structure that you label.

Exercise 6-2

Histology of Integument

MATERIALS

- ❑ Light microscope
- ❑ Slide of thick skin
- ❑ Slide of thin skin
- ❑ Colored pencils

6

In this exercise we will examine prepared slides of skin and hair. The skin sections are taken from different regions of the body so we can compare and contrast two types of skin: (a) **thick skin**, found on the palms and soles of the feet, and (b) **thin skin**, found everywhere else (Fig. 6.6).

Before moving on, review the basics of microscopy from Units 3 and 5. Remember to follow a step-by-step approach when examining the slides: Look at the slide with the naked eye first, then begin your examination on low power, and advance to higher power to see more details.

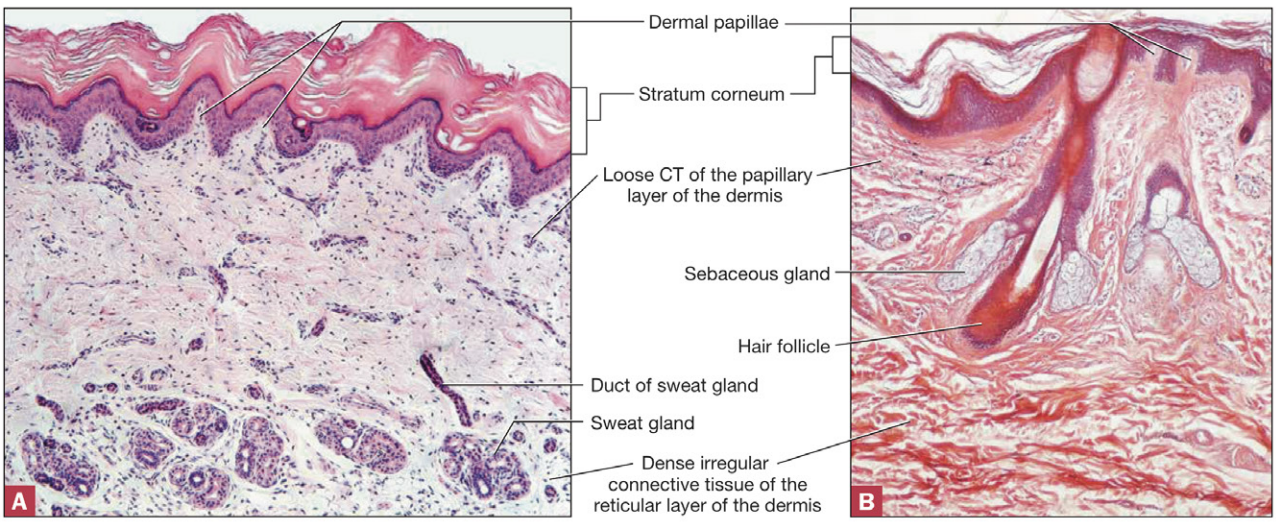

FIGURE **6.6** Skin, photomicrographs: (**A**) thick skin; (**B**) thin skin.

Procedure 1 Microscopy of Thick Skin

Obtain a prepared slide of thick skin (which may be labeled "Palmar Skin"), and examine it with the naked eye to get oriented. Once you are oriented, place the slide on the stage of the microscope, and scan it on low power. You should be able to see the epidermis with its superficial layers of dead cells and the dermis with its pink clusters of collagen bundles that make up the dense irregular collagenous connective tissue. Compare it to Figure 6.6A to make sure that are you are looking at the right slide and the right magnification. Advance to higher power to see the cells and associated structures in greater detail.

Use your colored pencils to draw what you see in the field of view (you will be able to see the most structures on low power). Label your drawing with the following terms, using Figure 6.6A for reference. When you have completed your drawing, fill in the first part of Table 6.2.



1. Epidermis
   a. Stratum corneum
   b. Stratum lucidum
   c. Stratum granulosum
   d. Stratum spinosum
   e. Stratum basale
2. Dermis
   a. Dermal papillae
   b. Collagen bundles
   c. Sweat gland

Procedure 2 Microscopy of Thin Skin

Obtain a prepared slide of thin skin (which may be labeled "Scalp Skin"). As before, examine the slide with the naked eye, then scan the slide on low power, advancing to higher power as needed to see the structures more closely. Compare what you see in your field of view to Figure 6.6B to ensure that you are looking at the correct region of the slide.

Use your colored pencils to draw what you see in the field of view (you will be able to see the most structures on low power). Label your drawing using the terms below, using Figure 6.6B for reference. When you have completed your drawing, fill in the remainder of Table 6.2.

1. Epidermis
   a. Stratum corneum
   b. Stratum granulosum
   c. Stratum spinosum
   d. Stratum basale
2. Dermis
   a. Dermal papillae
   b. Collagen bundles
3. Hair follicle
4. Sebaceous gland
5. Sweat gland
6. Arrector pili muscle



TABLE 6.2 Characteristics of Thick and Thin Skin

Characteristic	Thick Skin	Thin Skin
Thickness of stratum corneum		
Hair follicles present?		
Sebaceous glands present?		
Stratum lucidum present?		
Arrector pili muscles present?		

Procedure 3 Microscopy of Hair

Obtain a prepared slide of a sectioned hair. As before, examine the slide with the naked eye, then scan the slide on low power, advancing to higher power as needed to see the structures more closely. Compare what you see in your field of view to Figure 6.7 to ensure that you are looking at the correct region of the slide.

Use your colored pencils to draw what you see in the field of view (you will be able to see the most structures on low power). Label your drawing using the following terms, using Figure 6.7 for reference.

1. Cortex
2. Medulla
3. Hair papilla
4. Matrix
5. Hair follicle

FIGURE **6.7** Light micrograph of a sectioned hair.



Exercise 6-3

Touch Receptor Distribution

MATERIALS

- ❑ Water-soluble marking pens
- ❑ Ruler
- ❑ Monofilament

The two types of sensory receptors in the skin that detect fine touch are called **tactile corpuscles** and **Merkel (or tactile) discs**. The distribution of these receptors can be mapped using an instrument called a monofilament (Fig. 6.8) that applies 10 grams of force as it is pressed on the skin (10 grams of force is generally accepted as the maximum amount of force required to activate the tactile corpuscles and Merkel discs). In this exercise, you will compare the distribution of fine touch receptors in different parts of the body by mapping them with a monofilament. When you have completed the activity, answer Check Your Understanding questions 5 and 6 (p. 152).

Procedure 1 Mapping Touch Receptor Distribution

1. Use a centimeter ruler to measure a 2-centimeter square on your partner's palm. Mark this square with a water-soluble marking pen.
2. Have your partner close his or her eyes.
3. Apply the monofilament to one of the corners of the square. Press only until the monofilament bends slightly.
4. If your partner can perceive the sensation of the monofilament, mark this spot with a different-colored water-soluble marker.
5. Repeat this process for the remainder of the square, advancing the monofilament 1 to 2 millimeters each time. Be certain to apply the same amount of pressure with each application.
6. When you have completed the square, record the number of receptors found on the palm.

   Number of receptors on palm: _____

7. Repeat this process on the posterior scapular region. Record the number of receptors found on this location.

   Number of receptors on the posterior scapular region: _____

FIGURE **6.8** Monofilament.

Exercise 6-4

Fingerprinting

MATERIALS

- ❑ Blank glass slide (one per person)
- ❑ Ink pad
- ❑ Fingerprint card (one per person)
- ❑ Dusting powder
- ❑ Dusting brush
- ❑ Fingerprint lifting tape
- ❑ Latex gloves
- ❑ Sharpie

6

Specific patterns in the epidermis are seen in thick skin where the dermal papillae are folded into **dermal ridges**. These dermal ridges indent the overlying epidermis to create **epidermal ridges**, which increase gripping ability. They also lead to the characteristic patterns of finger, toe, palm, and footprints. The patterns of the epidermal ridges are unique to each individual, even identical twins.

Sweat pores open at the top of the epidermal ridges, which causes us to leave behind a thin film when we touch surfaces. This film can be detected in a variety of ways, most commonly using a powder that binds to it.

Fingerprinting was not a widely accepted means of identification in the United States until 1902, when the New York Civil Service began collecting and using fingerprints. Prior to this, fingerprints had been studied widely and even were used to solve a murder case in Argentina in 1892.

Fingerprints can be broadly classified into three ridge flow patterns: loop, arch, and whorl (Fig. 6.9). Once the ridge flow pattern has been identified, the characteristics of the ridges, also called *Galton points*, are examined (Fig. 6.10). In professional laboratories the fingerprint is analyzed further on the basis of minute details, or "points," in the fingerprint. Much of this is done currently with the help of computers.

In this exercise you will be playing the role of detective, searching for a "thief" among your group members (which may end up being you!). Your group will determine the thief's identity by analyzing the ridge flow patterns and ridge characteristics of the fingerprints of your group members. When you have completed the activity, answer Check Your Understanding question 7 (p. 152).



FIGURE **6.9** The three basic patterns of fingerprints.

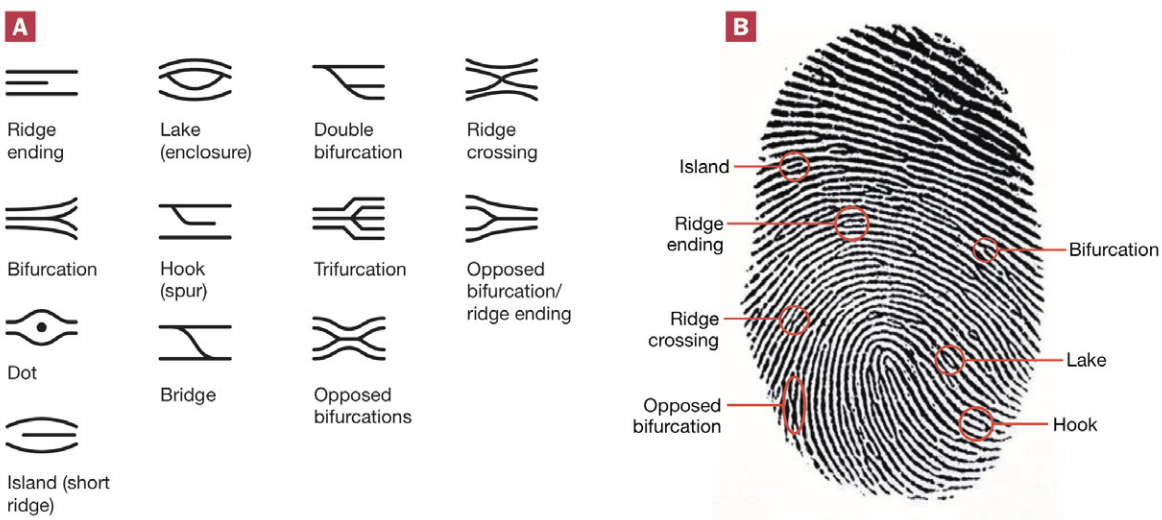

FIGURE **6.10** Fingerprinting: (**A**) Galton points; (**B**) sample loop fingerprint.

Procedure 1 Fingerprint Analysis

1. Assemble into groups of a minimum of four people.
2. Obtain one blank glass slide, and handle it by the edges as you clean it off with a paper towel and water.
3. Once the slide is clean and dry, place two or three large fingerprints (use different fingers) somewhere on one side of the slide.
4. After placing one or more fingerprints on the slide, put on gloves, and use the Sharpie at your table to write your initials on the upper right-hand corner of the slide.
5. Bring the slides for the entire table to your instructor, and your instructor will pick one slide from the group, cover the initials in the corner, and designate that person as the "thief." The thief is one of your group members, so you are all suspects.
6. Fingerprint each member of the group (using the ink and cards provided):
   a. Obtain a blank fingerprinting card or a blank sheet of paper.
   b. Roll each finger individually on the ink pad from right to left. Be certain not to get excessive ink on your fingers.
   c. Roll each finger individually on the fingerprinting card slowly from left to right.
7. When all of the fingerprinting is completed, don a pair of latex gloves.
8. Use a dusting brush to lightly sweep some dusting powder onto the slide containing the thief's fingerprints. Use the dusting powder *sparingly*, because too much powder will obscure your prints. Brush away the excess dusting powder. (You can tap the slide on its side to help with this.)
9. Place a piece of fingerprint lifting tape on the fingerprints that have appeared. Pat the tape into place firmly, and remove it slowly. Place the tape on a blank sheet of white paper for comparison.
10. With the help of Figures 6.9 and 6.10, identify the thief by comparing the fingerprints lifted from the slide with the fingerprints taken from the suspects. Be careful not to tell your group mates which fingers you used. Remember—you don't want to be caught!

    Who is the thief from your table?

    How did you arrive at this conclusion?

Name _____

Section _____ Date _____

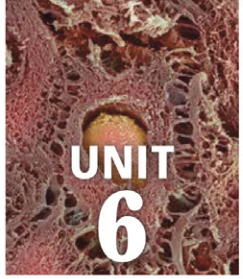

REVIEW

Check Your Recall

1 Label the following parts of the skin on Figure 6.11.

- ❑ Arrector pili muscle
- ❑ Cutaneous blood vessels
- ❑ Dermal papillae
- ❑ Dermis
- ❑ Epidermis
- ❑ Hair papilla
- ❑ Hair follicle
- ❑ Hair shaft
- ❑ Sebaceous gland
- ❑ Sweat gland
- ❑ Sweat pore

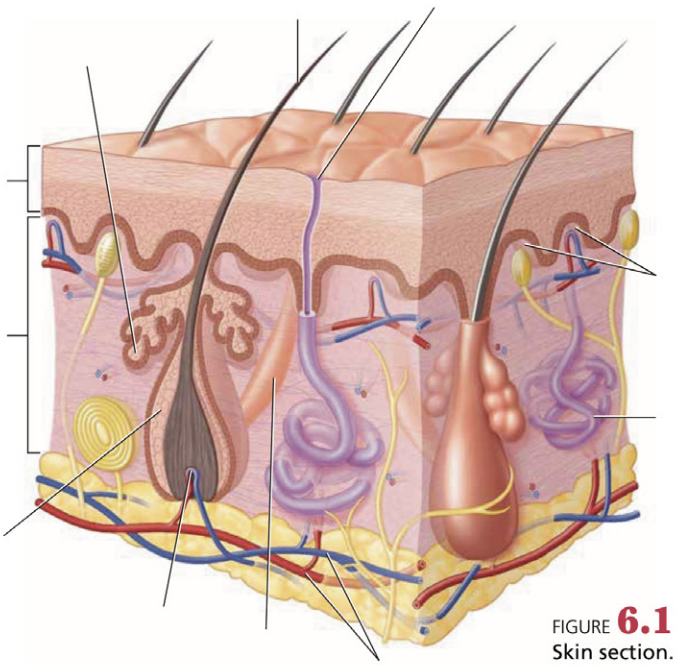

FIGURE **6.11**
Skin section.

2 The primary protein produced by the main cell type in skin is

a. actin.
b. melanin.
c. keratin.
d. collagen.

3 Mark the layers of the epidermis that contain living cells with a check mark.

_____ Stratum lucidum

_____ Stratum basale

_____ Stratum corneum

_____ Stratum spinosum

_____ Stratum granulosum

4 In which layer of the epidermis are melanocytes found?

a. Stratum corneum.
b. Stratum granulosum.
c. Stratum basale.
d. Stratum lucidum.
e. Stratum spinosum.

5 From where do the cells of the epidermis obtain oxygen and nutrients?

a. From blood vessels in the epidermis.
b. Diffusion from blood vessels in the dermis.
c. Diffusion from the air.
d. From blood vessels in other epithelial tissues.

6 *Matching:* Match the following terms with the correct description.

_____ Papillary layer
_____ Sebaceous gland
_____ Lamellated corpuscle
_____ Hair follicle
_____ Dermal papillae
_____ Hair shaft
_____ Reticular layer
_____ Sweat gland

A. Secrete product through a pore
B. Pressure receptor in the dermis
C. Projections of the dermis that indent the epidermis
D. Superficial layer of the dermis; loose connective tissue
E. Sheath of epithelial and connective tissue around a hair
F. Deep layer of the dermis; dense irregular collagenous connective tissue
G. Secretes sebum (oil)
H. Portion of the hair that projects from the skin's surface

7 Which of the following are characteristics of thin skin? (*Circle all that apply.*)

a. Located over the palms and the soles of the feet.
b. Contains hair and arrector pili muscles.
c. Contains sweat glands.
d. Very thick stratum corneum.
e. Contains sebaceous glands.
f. Contains a stratum lucidum.

8 *True/False:* Mark the following questions as true (T) or false (F). If the question is false, correct it to make it a true statement.

_____ a. An arrector pili muscle is composed of skeletal muscle tissue.

_____ b. The dividing cells of a nail are located in the eponychium.

_____ c. Both hairs and nails are composed primarily of dead keratinocytes.

_____ d. A hair follicle is composed of epithelium and connective tissue.

9 *Fill in the blanks:* _____ corpuscles in the dermis detect pressure, whereas _____ corpuscles in the dermis detect fine touch.

10 Eccrine sweat is released into a _____, and sebum is released into a _____.

a. a duct; a hair follicle
b. a hair follicle; a blood vessel
c. a duct; a blood vessel
d. a hair follicle; a duct

Name _____

Section _____ Date _____

REVIEW

Check Your Understanding

Critical Thinking and Application Questions

1 You develop a *callus*, which is a thickening of the epidermis, from a pair of ill-fitting shoes.

a To treat the callus, you decide to shave off some of the excess epidermis. While doing this, you notice that there is no pain or bleeding. Why wouldn't it cause pain to remove only the superficial part of the epidermis? Why wouldn't it bleed?

b Unfortunately, you go a bit overboard and feel a sudden pinch, after which you notice you are bleeding. What has happened? Are you still in the epidermis? Explain.

2 Shampoos and hair conditioners often claim to have nutrients and vitamins your hair must have to grow and be healthy.

a What is the composition of the hair shaft onto which shampoos and conditioners are applied?

b Taking into account the composition of the hair shafts, do you think these vitamins and nutrients will be beneficial? Why or why not?

3 A treatment for ingrown nails is to remove the nail and apply a chemical such as phenol to the cells of the nail matrix, which kills the cells. What effect will killing the cells of the nail matrix have on the nail? Explain.

4 *Carcinomas* are cancers of epithelial tissue, and sarcomas are cancers of connective tissue. Are epidermal cancers carcinomas or sarcomas? What about dermal cancers? Explain.

5 Would you have expected to have found more tactile corpuscles and Merkel discs on the palm or on the posterior shoulder? Why?

6 In which areas of the body would you expect to find the most Merkel discs and tactile corpuscles? Why?

7 You're discussing a forensic crime scene show with your roommate, who insists that fingerprints are left behind due to the sebum on our fingertips. What do you tell him? (***Hint:*** What kind of skin is on the fingertips?)

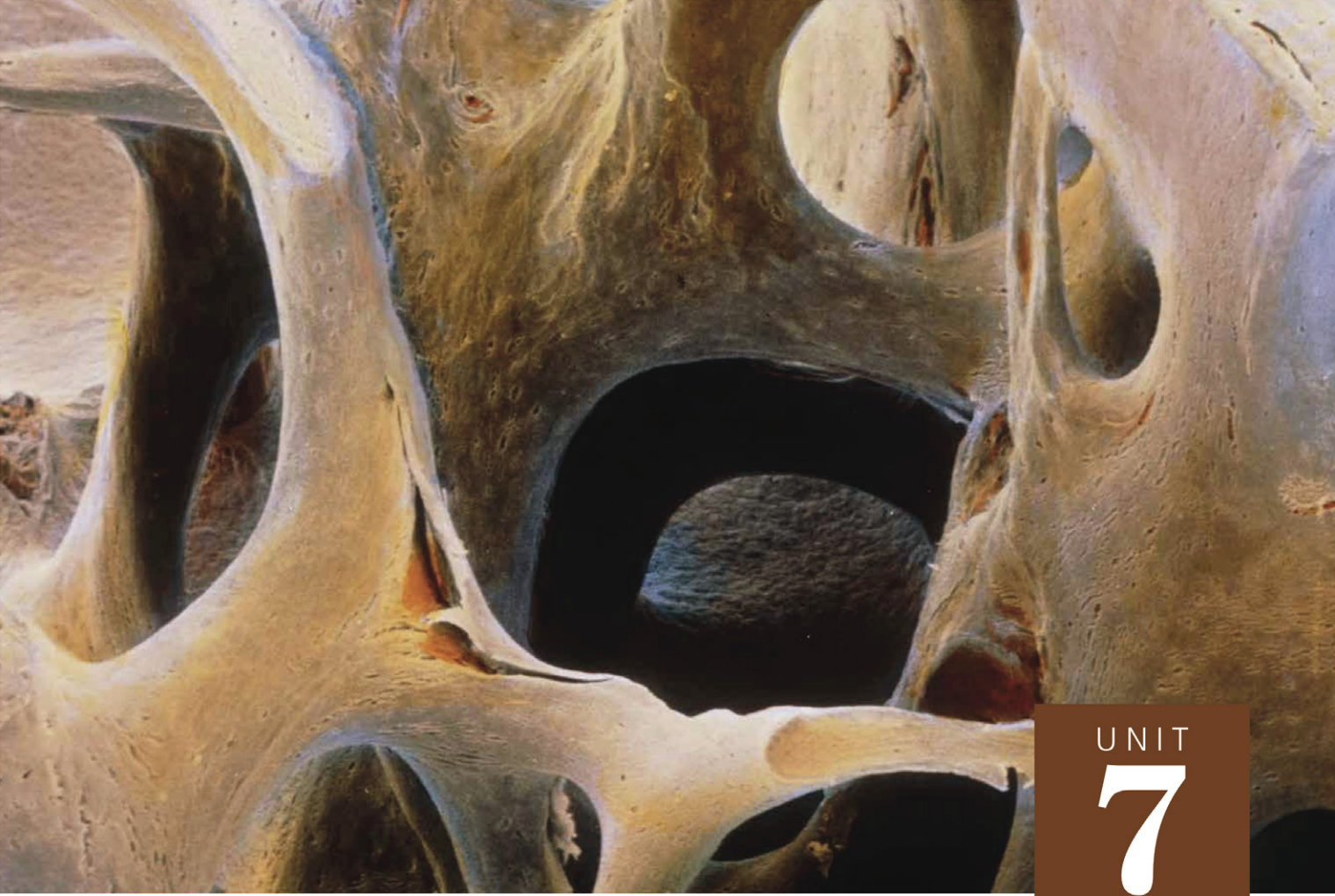

UNIT
7

Introduction to the Skeletal System

Once you have completed this unit, you should be able to:

1. Identify the structures and components of osseous tissue.
2. Explain the role of extracellular matrix in the function of osseous tissue.
3. Classify bones according to their shape and describe the functions of bone markings.
4. Identify the parts of the long bone.
5. Describe the structure and function of the epiphyseal plate.

Name _____ Section _____ Date _____

PRE-LAB EXERCISES

Complete the following exercises prior to coming to lab, using this lab manual and your textbook for reference.

Pre-Lab Exercise 7-1



Key Terms

You should be familiar with the following terms before coming to lab.

Term	Definition

Types of Bone Tissue

Compact bone _____

Spongy bone _____

Structures of the Osteon

Osteon _____

Lamellae _____

Central canal _____

Perforating canal _____

Lacunae _____

Osteocytes _____

Canaliculi _____

Periosteum _____

Endosteum _____

Bone Shapes

Long bone _____

Short bone _____

Flat bone _____

Irregular bone _____

Other Types of Bones

Sesamoid bone _____

Sutural bone _____

Structures of Long Bones

Diaphysis _____

Epiphysis _____

Epiphyseal plate/line _____

Medullary cavity _____

Bone marrow _____

Name _____ Section _____ Date _____

Pre-Lab Exercise 7-2

Microscopic Anatomy of Compact Bone

Label and color the microscopic anatomy of compact bone tissue in Figure 7.1 with the terms from Exercise 7-1 (p. 159). Use your text and Exercise 7-1 in this unit for reference.

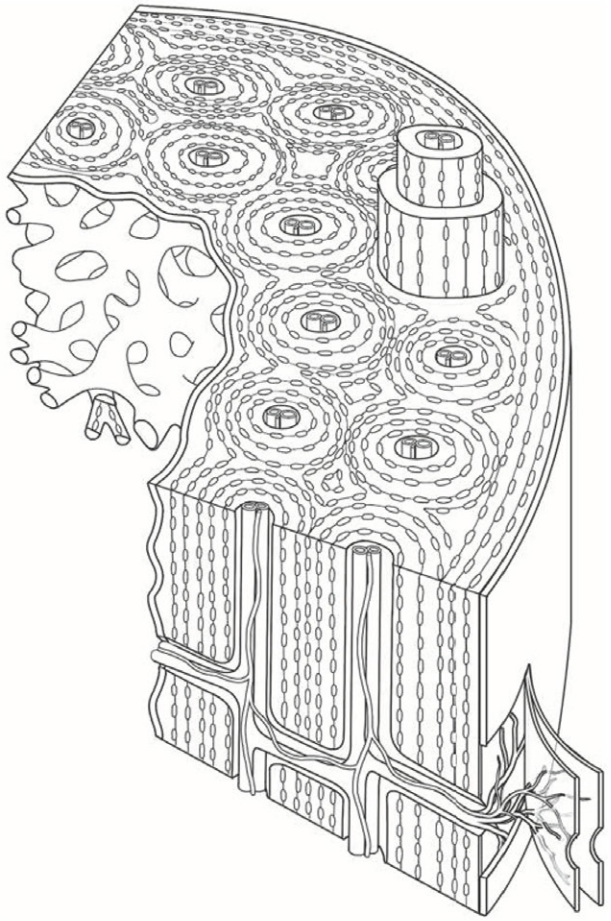

FIGURE **7.1** Microscopic anatomy of compact bone.

Pre-Lab Exercise 7-3

Structure of a Long Bone

Label and color the diagram of a long bone (the femur) in Figure 7.2 with the terms from Exercise 7-4 (p. 166). Use your text and Exercise 7-4 in this unit for reference.

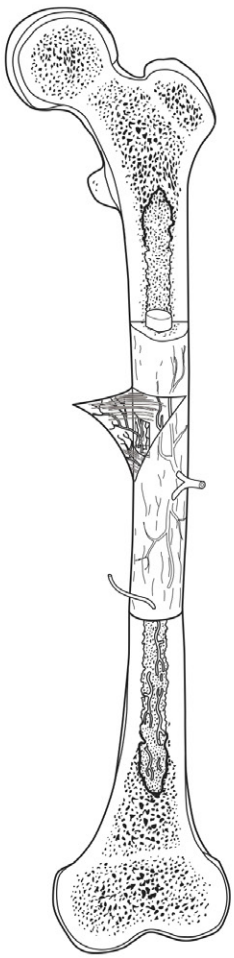

FIGURE **7.2** Adult long bone: the femur.

Colored SEM of trabeculae in spongy bone tissue of the femur.

EXERCISES

The **skeletal system** consists of the bones and their cartilages. At first it might seem odd that a set of bones makes up an organ system, but remember that each bone is an organ. A bone consists of many tissue types, including osseous tissue, dense irregular collagenous connective tissue, and adipose tissue. The following exercises will introduce you to these complex organs and the histology of osseous tissue.

Exercise 7-1

Histology of Osseous Tissue

MATERIALS

- ❑ Osteon model
- ❑ Slide of compact bone
- ❑ Light microscope
- ❑ Colored pencils

The most superficial tissue of a bone is called the **periosteum** (pehr-ee-AH-stee-um; Fig. 7.3). The outer layer of the periosteum is composed of dense irregular collagenous connective tissue richly supplied with blood vessels and nerves. Extensions of the collagen fibers from this layer, called **perforating fibers**, anchor the periosteum to the bone.

The innermost layer of the periosteum contains **osteogenic cells** (ah-stee-oh-JEN-ik), or *osteoprogenitor cells*, that can become cells called **osteoblasts** (AH-stee-oh-blasts). Osteoblasts are "builder" cells that secrete bone extracellular matrix (ECM). Also within this layer are cells known as **osteoclasts** (AH-stee-oh-klasts). These are the "breakdown" cells, as they secrete enzymes that catalyze the digestion of bone ECM.

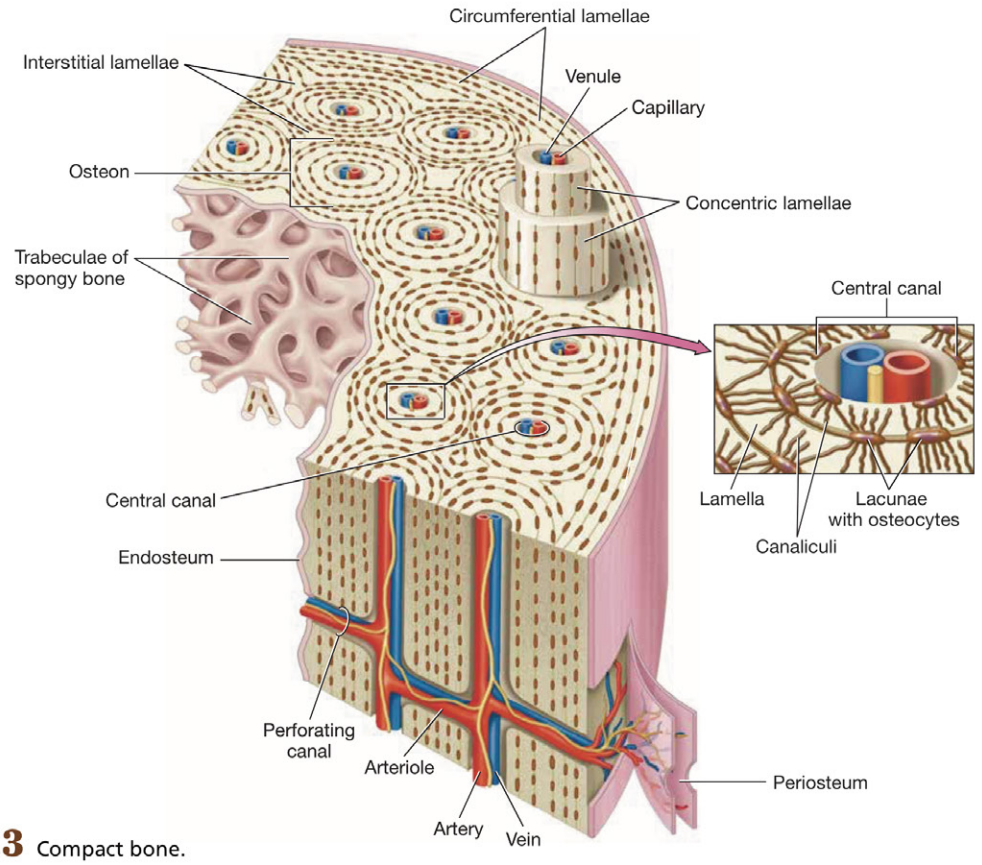

FIGURE **7.3** Compact bone.

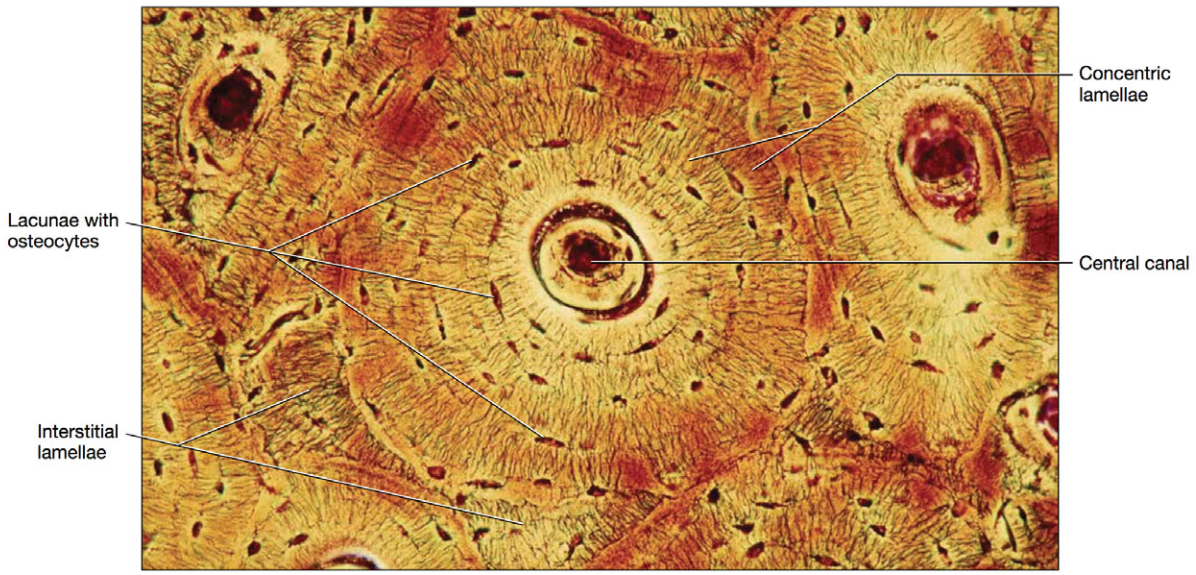

FIGURE **7.4** Compact bone, light micrograph.

Deep to the periosteum we find **osseous tissue,** which is composed of a hardened ECM and different types of bone cells. The two general forms of osseous tissue are compact bone and spongy bone. C**ompact bone** is hard, dense bone tissue found immediately deep to the periosteum. Its hardness comes from its structure, which consists of repeating, densely packed subunits called **osteons** (AHS-tee-ahnz; Figs. 7.3 and 7.4). Osteons have several features, including the following:

1. **Central canal.** Running down the center of each osteon is a **central canal.** Each central canal contains blood vessels and nerves and is lined with a connective tissue membrane called **endosteum** (en-DAH-stee-um). Like the periosteum, the endosteum has an inner layer of osteoblasts, which secrete bone ECM, and osteoclasts, which degrade bone.
2. **Lamellae.** Surrounding the central canal are rings of bone ECM called **lamellae** (lah-MELL-ee). The lamellae give compact bone a great deal of strength, much like a tree's rings. The lamellae in osteons are known as **concentric lamellae** due to the way they encircle the osteon. However, osteons are constantly remodeled, with osteoclasts breaking down old bone and osteoblasts building new bone. This leaves parts of old lamellae behind as new ones are built. These old lamellae, which are known as **interstitial lamellae,** are located between osteons.
3. **Lacunae.** Situated between the lamellae are small cavities called **lacunae** (lah-KOO-nee). Lacunae contain mature osteoblasts called **osteocytes,** which monitor and maintain the bone ECM. Neighboring lacunae and osteocytes are connected to each other by tiny canals called **canaliculi** (kan-ah-LIK-yoo-lee).
4. **Perforating canals.** The **perforating canals** run perpendicular to the lamellae and carry blood vessels deep into the bone from the periosteum. Like the central canals, perforating canals are lined by endosteum.

Notice in Figure 7.3 that there are additional lamellae lining the outside and inside of the compact bone. These are called **circumferential lamellae,** and are laid down by osteoblasts in the periosteum and endosteum. They give the compact bone additional strength.

Spongy bone is found on the inside of a bone deep to compact bone, and as its name implies, it somewhat resembles a sponge. It consists of a latticework-type structure with tiny bone spicules called **trabeculae** (trah-BEK-yoo-lee; Fig. 7.5) that are lined with endosteum. The latticework-structure of spongy bone allows it to house another important tissue, the **bone marrow.** The two types of bone marrow are **red bone marrow,** which produces blood cells, and **yellow bone marrow,** which is composed primarily of adipose tissue.

As you can see in Figure 7.5, trabeculae are composed of lamellae but are not organized into osteons. For this reason, spongy bone lacks the hardness of compact bone. Between the lamellae are osteocytes in lacunae, and they are connected by canaliculi, as in compact bone.

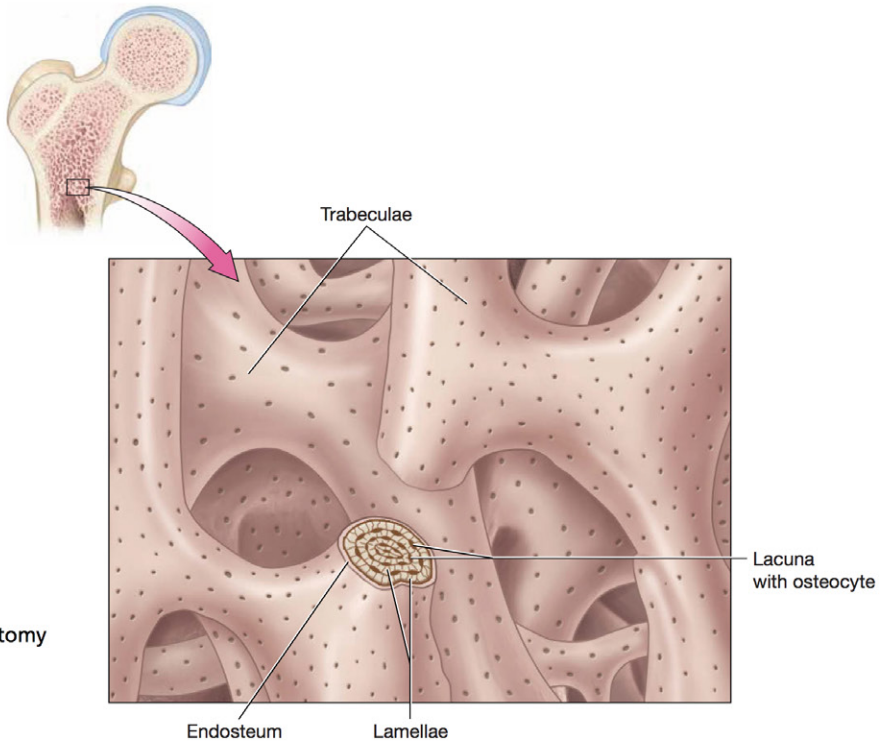

FIGURE **7.5** Microscopic anatomy of spongy bone tissue.

Procedure 1 Model Inventory for Compact and Spongy Bone

Identify the following structures of compact and spongy bone on models and diagrams, using your textbook and this unit for reference. As you examine the anatomical models and diagrams, record the name of the model and the structures you were able to identify on the model inventory in Table 7.1. When you have completed the activity, answer Check Your Understanding questions 1 through 3 (p. 171).

Compact Bone Structures

1. Periosteum
2. Perforating fibers
3. Osteons
   a. Central canal
   b. Endosteum
   c. Lamellae
      (1) Concentric lamellae
      (2) Interstitial lamellae
   d. Lacunae
   e. Osteocyte
   f. Canaliculi
   g. Perforating canal
4. Circumferential lamellae

Spongy Bone Structures

1. Trabeculae
2. Endosteum
3. Red bone marrow
4. Yellow bone marrow
5. Lamellae
6. Osteocytes
7. Lacunae
8. Canaliculi

TABLE **7.1** Model Inventory for Osseous Tissue

Model/Diagram	Bone Structures Identified

Procedure 2 Microscopy

View a prepared slide of compact bone. The structures on the slide should look similar to the osteon models you viewed in lab earlier and Figure 7.4.

Use colored pencils to draw what you see under the microscope, and label your drawing with the compact bone structures from Procedure 1.



Exercise 7-2

Chemical Components of Bone Tissue

MATERIALS

- ❑ 1 piece of normal bone
- ❑ 1 piece of oven-heated bone
- ❑ 1 piece of bone soaked in nitric acid
- ❑ Plastic or metal tray

The ECM of osseous tissue is made of two main chemical components:

1. The **organic component** consists of ground substance and protein fibers such as **collagen fibers.** The organic matrix provides a supportive network that gives the bone *tensile strength* (the ability to withstand stretching and twisting forces). Tensile strength is very important to bone function, as it prevents bones from breaking when muscles pull on them.
2. The **inorganic component** consists mostly of calcium salts in the form of calcium hydroxyapatite crystals. The inorganic component provides the bone with *compressional strength* (the ability to withstand compressive forces). Compressional strength is similarly important to bone function, as it allows bones to bear weight without breaking.

Procedure 1 Examining the Chemical Components of Bone Tissue

In this exercise you will compare the effects of removing different chemical components of bone. One sample has been heated in an oven. This destroys the organic component of the bone, leaving behind only the calcium hydroxyapatite crystals. The other sample has been treated with nitric acid to destroy the bone's inorganic component, leaving behind mostly ground substance and collagen fibers (Fig. 7.6). You will compare these two bone samples to an untreated bone to see how each component of the ECM contributes to the function of osseous tissue. When you have completed the activity, answer Check Your Understanding questions 4 through 6 (p. 172).

Safety Note
Safety glasses and gloves are required!

1 Obtain and place three pieces of bone on a tray, including

a. one piece of untreated bone;
b. one piece of bone that has been baked in an oven for a minimum of two hours; and
c. one piece of bone that has been soaked in nitric acid.

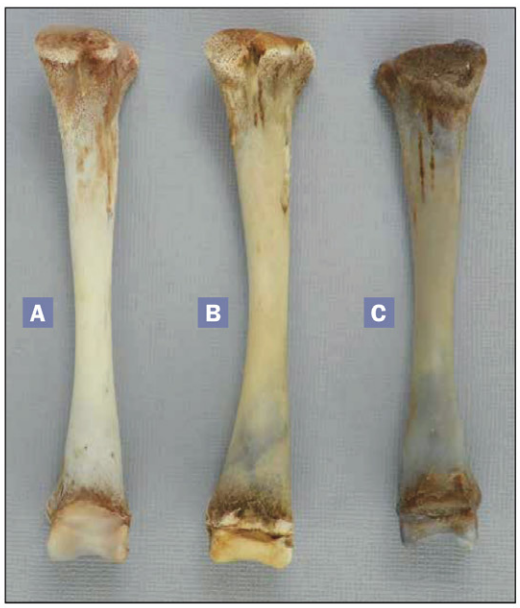

FIGURE **7.6** Three samples of bone: (**A**) untreated; (**B**) heated; (**C**) soaked in nitric acid.

2 Place the three pieces of bone side by side. Describe their appearance. Do they look different from one another?

_____

_____

_____

3 Squeeze each bone between your fingers, twist each sample between your fingers, and tap each sample on the tray. What happens to

a the untreated bone? _____

b the heated bone? _____

c the bone treated with nitric acid? _____

Exercise 7-3

Bone Markings and Bone Shapes

MATERIALS

- ❑ Disarticulated bones
- ❑ Articulated skeleton

When you examine a skeleton closely, you'll notice that few bones have smooth, flat surfaces. Instead, most bones contain depressions, openings, and projections. These features, collectively known as **bone markings**, perform numerous functions: *Depressions* provide pathways along which blood vessels and nerves travel, or allow two bones to come together to form a joint; *openings* house and protect structures such as blood vessels and special sensory organs; and *projections* provide points of attachment for ligaments and tendons. The major types of bone markings are defined in Table 7.2.

Another thing you might notice about the skeleton is the variety of ways that the bones are shaped. As shown in Figure 7.7, there are four general shapes of bones:

1. **Long bones** are longer than they are wide and include the bones of the upper and lower limbs, excluding the ankle and wrist bones.
2. **Short bones** are about as long as they are wide. The bones of the wrist and the ankle are short bones.
3. **Flat bones** are shaped exactly as they're named—they are flat. Flat bones include the ribs, the sternum, certain skull bones, and the hip bones.
4. **Irregular bones** are those whose shape doesn't fit into any of the other classes. Irregular bones include the vertebrae, the sacrum, and certain bones of the skull, such as the sphenoid bone.

TABLE **7.2** Bone Markings

Bone Marking	Description
Depressions	
Facet	Shallow indented surface where two bones meet to form a joint
Fossa	Deeper indented surface in a bone, usually allows a rounded surface of another bone to fit inside of it
Fovea	Shallow pit; often the site for the attachment of a ligament
Groove	Long, typically shallow depression that usually allows a nerve or blood vessel to travel along the bone's surface
Sulcus	Another name for a groove
Openings	
Canal	Passageway through a bone
Fissure	Slit within a bone or between bones
Foramen	Hole in a bone through which a structure such as a nerve or blood vessel passes
Meatus	Another name for a canal
Projections	
Condyle	Round end of a bone that fits into a fossa or facet of another bone at a joint
Crest	Ridge along a bone; generally a site of muscle attachment
Epicondyle	Small projection usually proximal to a condyle; generally the site of muscle attachment
Head	Rounded end of the bone that fits into a fossa to form a joint
Line	Ridge along a bone where a muscle attaches
Process	Any bony projection; generally the site of muscle attachment
Protuberance	An outgrowth from a bone due to repetitive pull from a muscle
Trochanter	Large bony projection to which muscles attach; only examples are in the femur (thigh bone)
Tubercle	Small rounded projection where muscles attach
Tuberosity	A larger, more prominent tubercle

HINTS & TIPS

Bone Shape, Not Length

Note that long bones are not named for their length but rather for their shape. Many long bones actually are quite small, such as the phalanges (the bones of the fingers and the toes). Be careful when identifying bone shapes to look at the overall shape of the bone rather than its size.

Note that there are two other classes of bones: sesamoid bones and sutural bones. **Sesamoid bones** are roughly oval-shaped bones located within tendons. The sesamoid bone with which you are most likely familiar is the patella, or the kneecap. **Sutural bones** (SOO-tchur-uhl) are small bones located between the flat bones of the skull. You will likely see sutural bones when you study the skull in the next unit.

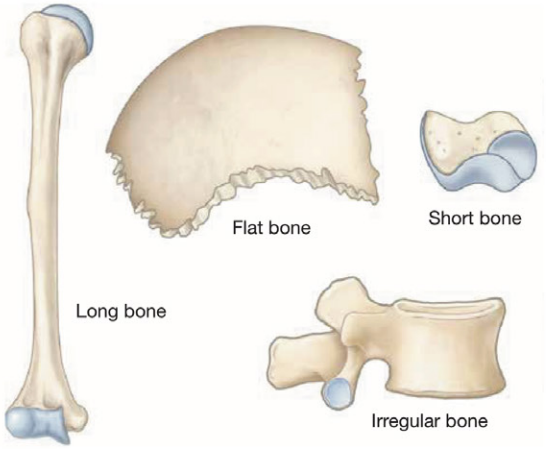

FIGURE **7.7** The four shapes of bones.

Procedure 1 Identifying Bone Shapes and Markings

Obtain a set of disarticulated bones, and classify them according to their shape. Identify examples of long bones, short bones, flat bones, and irregular bones, and record them in Table 7.3. Then, closely examine each bone and identify examples of bone markings on the bone. You may wish to use the figures in your text or Unit 8 (pp. 173–224) to help you identify the disarticulated bones and their markings.

TABLE **7.3** Examples of Bone Shapes and Markings

Bone	Shape	Marking(s) on the Bone

Exercise 7-4

Anatomy of Long Bones

MATERIALS

- ❑ Long bone, sectioned
- ❑ X-rays, if available
- ❑ Light microscope
- ❑ Slide of epiphyseal plate
- ❑ Colored pencils

7

All long bones share common structures and parts, illustrated in Figure 7.8 with the example of the femur. The **diaphysis** (dy-AEH-fih-sis) is the shaft of the long bone. As you can see in the figure, it consists of a thick collar of compact bone surrounding a hollow area called the **medullary cavity**. This collar of compact bone makes long bones quite strong. The medullary cavity has sparse trabeculae and generally is filled with yellow bone marrow in adult bones.

The ends of a long bone are called the **proximal** and **distal epiphyses** (eh-PIF-ih-seez). Each epiphysis contains a shell of compact bone surrounding the inner spongy bone. The spongy bone within the epiphyses contains either red or yellow bone marrow. The end of each epiphysis is covered with **articular cartilage** (generally composed of hyaline cartilage), which allows two bones in a joint to move around one another with minimal friction.

At certain epiphysis-diaphysis junctions you will note a thin, calcified line called the **epiphyseal line** (eh-PIF-ih-seel). This structure is the remnant of the **epiphyseal plate**, a band of hyaline cartilage from which long bones grow in length in children and young adults (Figure 7.9A) As you can see in Figure 7.9B, there are five regions of an epiphyseal plate:

1. **Zone of reserve cartilage.** The first zone, or the one closest to the epiphysis, is called the zone of reserve cartilage. As its name implies, this zone contains a reserve of chondrocytes that can divide if needed.
2. **Zone of proliferation.** The next region is the zone of proliferation. Again, as suggested by its name, it consists of actively dividing (proliferating) chondrocytes.
3. **Zone of hypertrophy and maturation.** In the zone of hypertrophy and maturation, the dividing chondrocytes begin to enlarge in their lacunae as they mature.
4. **Zone of calcification.** Chondrocytes in the zone of calcification begin to die. As they die, they accumulate calcium salt deposits and harden.
5. **Zone of ossification.** The last zone, which abuts the diaphysis, is the zone of ossification. It contains calcified chondrocytes and osteoblasts, which blend with the diaphyseal bone.

When longitudinal growth ceases, the chondrocytes of the epiphyseal plate die and are replaced by calcified bone tissue.

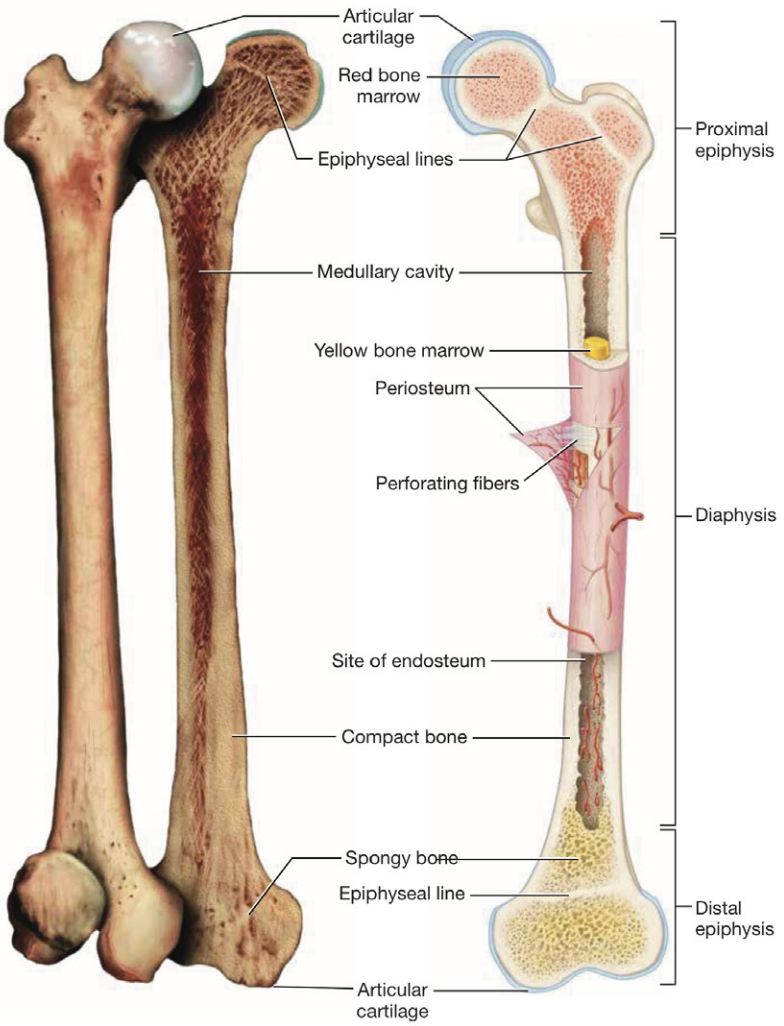

FIGURE **7.8** Adult long bone: the femur.

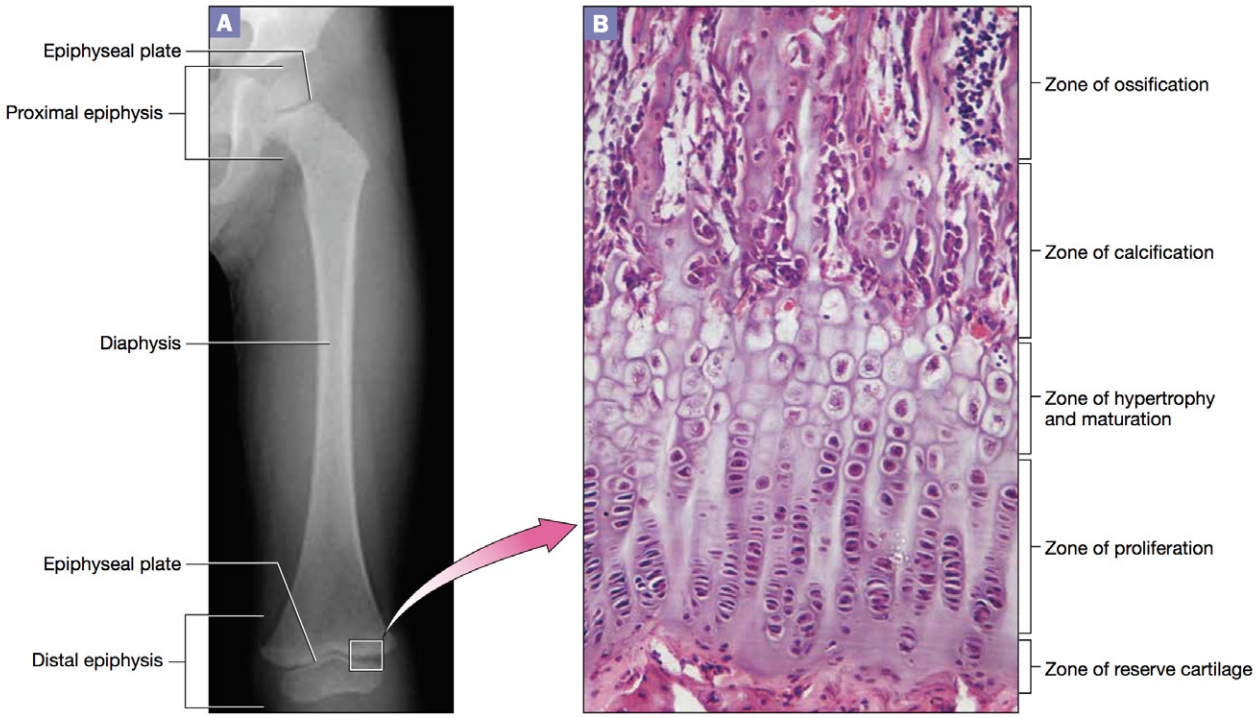

FIGURE **7.9** Epiphyseal plate: (**A**) X-ray of a child's femur; (**B**) light micrograph of the epiphyseal plate.

Procedure 1 Identification of Long Bone Structures

Identify the following structures of long bones on specimens and X-rays (if available). Check off each structure as you identify it.

- ❑ Diaphysis
- ❑ Compact bone
- ❑ Medullary cavity
- ❑ Yellow bone marrow
- ❑ Proximal epiphysis
- ❑ Distal epiphysis
- ❑ Spongy bone
- ❑ Red bone marrow
- ❑ Articular cartilage
- ❑ Epiphyseal line
- ❑ Epiphyseal plate (may be visible only on X-ray)

Procedure 2 Microscopy

View a prepared slide of an epiphyseal plate. The structures on the slide should look similar to what you see in Figure 7.9.

Use colored pencils to draw what you see under the microscope, and label your drawing with the zones of the epiphyseal plate.

Procedure 3 Time to Draw

In the space below, draw, color, and label one of the long bone sections or diagrams that you examined. In addition, write the main function of each structure that you label.

Name _____

Section _____ Date _____

REVIEW

Check Your Recall

1 Label the following parts of compact bone on Figure 7.10.

- ❑ Canaliculi
- ❑ Central canal
- ❑ Concentric lamellae
- ❑ Endosteum
- ❑ Interstitial lamellae
- ❑ Lacunae with osteocytes
- ❑ Osteon
- ❑ Perforating canal
- ❑ Periosteum
- ❑ Trabeculae of spongy bone

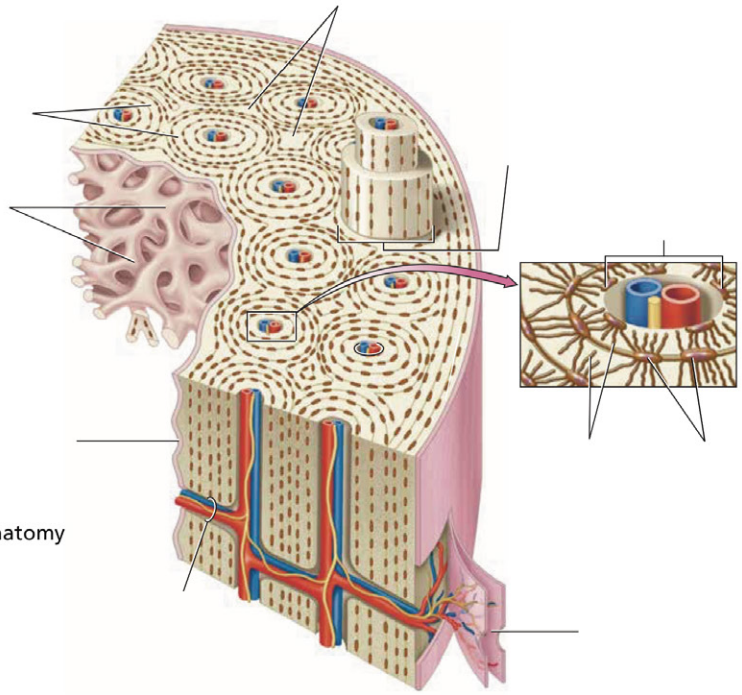

FIGURE **7.10** Microscopic anatomy of compact bone tissue.

2 *True/False:* Mark the following statements as true (T) or false (F). If the statement is false, correct it to make it a true statement.

_____ The periosteum contains osteoblasts and osteocytes.

_____ Osteoclasts secrete bone matrix.

_____ Compact bone is the hard, outer bone.

_____ Compact bone is composed of spicules called trabeculae.

_____ Spongy bone houses red and yellow bone marrow.

_____ Circumferential lamellae are located between osteons.

3 The extracellular matrix of bone consists of

a. collagen fibers.
b. calcium hydroxyapatite crystals.
c. ground substance.
d. Choices a and b only are correct.
e. Choices a, b, and c are correct.

4 Osteocytes are located in _____ and function to _____.

a. lacunae; maintain and monitor the bone ECM
b. the periosteum; maintain and monitor the bone ECM
c. lacunae; build bone matrix
d. the periosteum; build bone matrix

5 What is the general function of a bone projection?

a. It provides a pathway along which blood vessels or nerves travel.
b. It provides a point of attachment for tendons or ligaments.
c. It houses or protects structures such as blood vessels or sensory organs.
d. It allows two bones to come together to form a joint.

7

6 Examples of short bones include

a. the phalanges (bones of the fingers).
b. the sternum.
c. ankle bones.
d. Both a and b are correct.
e. Both a and c are correct.

7 Long bones are

a. named for their length.
b. about as long as they are wide.
c. irregular in shape.
d. longer than they are wide.

8 Label the following parts of a long bone on Figure 7.11.

- ❑ Articular cartilage
- ❑ Diaphysis
- ❑ Distal epiphysis
- ❑ Epiphyseal lines
- ❑ Medullary cavity
- ❑ Perforating fibers
- ❑ Periosteum
- ❑ Proximal epiphysis
- ❑ Red bone marrow
- ❑ Yellow bone marrow

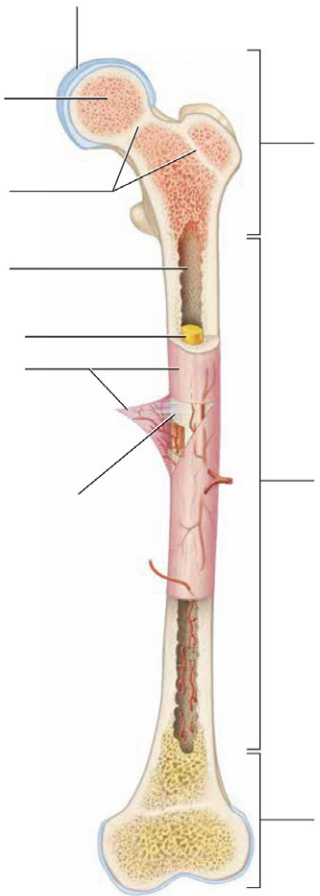

FIGURE **7.11** Adult long bone: the femur.

9 The epiphyseal line is

a. the structure from which long bones grow in length.
b. a remnant of the structure from which long bones grow in length.
c. composed of hyaline cartilage.
d. found lining the surface of the epiphysis.

10 In the zone of ossification of the epiphyseal plate

a. chondrocytes are actively dividing.
b. chondrocytes are maintained in a reserve to divide if needed.
c. chondrocytes begin to enlarge in their lacunae as they mature.
d. chondrocytes are calcified and abut the diaphysis with osteoblasts.

Name _____

Section _____ Date _____

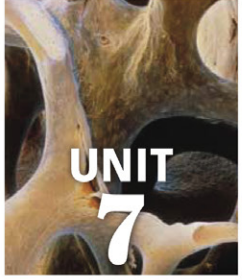

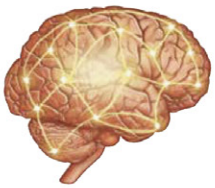

Check Your Understanding

REVIEW

Critical Thinking and Application Questions

1 Explain how the structure of each of the following relates to its function.

a Compact bone _____

b Spongy bone _____

c A long bone _____

2 A bone tumor disrupts the normal structure of osteons, replacing the organized rings with disorganized, irregular masses of bone. How will this affect the ability of a bone to perform its functions?

3 The maintenance of healthy bone depends upon the balance of osteoblast and osteoclast activity. Predict what would happen if

a osteoblast activity exceeded osteoclast activity. _____

b osteoclast activity exceeded osteoblast activity. _____

4 The disease osteoporosis often results from insufficient intake of dietary calcium salts. Of the three samples of bone you tested in Exercise 7-2, which is the most similar to the bones in osteoporosis? What symptoms would you expect to find in this disease?

5 *Osteogenesis imperfecta* is a congenital condition in which collagen synthesis is defective. Of the three samples of bone you tested in Exercise 7-2, which is most similar to the bones in osteogenesis imperfecta? What symptoms would you expect to find in this disease?

6 The disease scurvy, caused by a deficiency in vitamin C, leads to an inability to synthesize the protein collagen. Would prescribing calcium salts help to treat the primary bone problem in this disease? Why or why not?

UNIT
8

Skeletal System

Once you have completed this unit, you should be able to:

1. Identify bones and markings of the axial skeleton.
2. Identify bones and markings of the appendicular skeleton.
3. Build a skeleton using disarticulated bones.

Name _____ Section _____ Date _____

PRE-LAB EXERCISES

Complete the following exercises prior to coming to lab, using this lab manual and your textbook for reference.

Pre-Lab Exercise 8-1

Key Terms

You should be familiar with the following terms before coming to lab.

Term	Definition

8

Axial Skeleton

Cranial bones _____

Facial bones _____

Suture _____

Hyoid bone _____

Vertebrae _____

Ribs _____

Sternum _____

Appendicular Skeleton—Upper Limb and Pectoral Girdle

Pectoral girdle _____

Clavicle _____

Scapula _____

Humerus _____

Radius _____

Ulna _____

Carpals _____

Metacarpals _____

Phalanges _____

Appendicular Skeleton—Lower Limb and Pelvic Girdle

Pelvic girdle _____

Femur _____

Tibia _____

Fibula _____

Tarsals _____

Metatarsals _____

Name _____ Section _____ Date _____

Pre-Lab Exercise 8-2

Bones of the Skull

Label and color the structures of the skull in Figure 8.1 with the terms from Exercise 8-1 (p. 180). Use your text and Exercise 8-1 in this unit for reference.

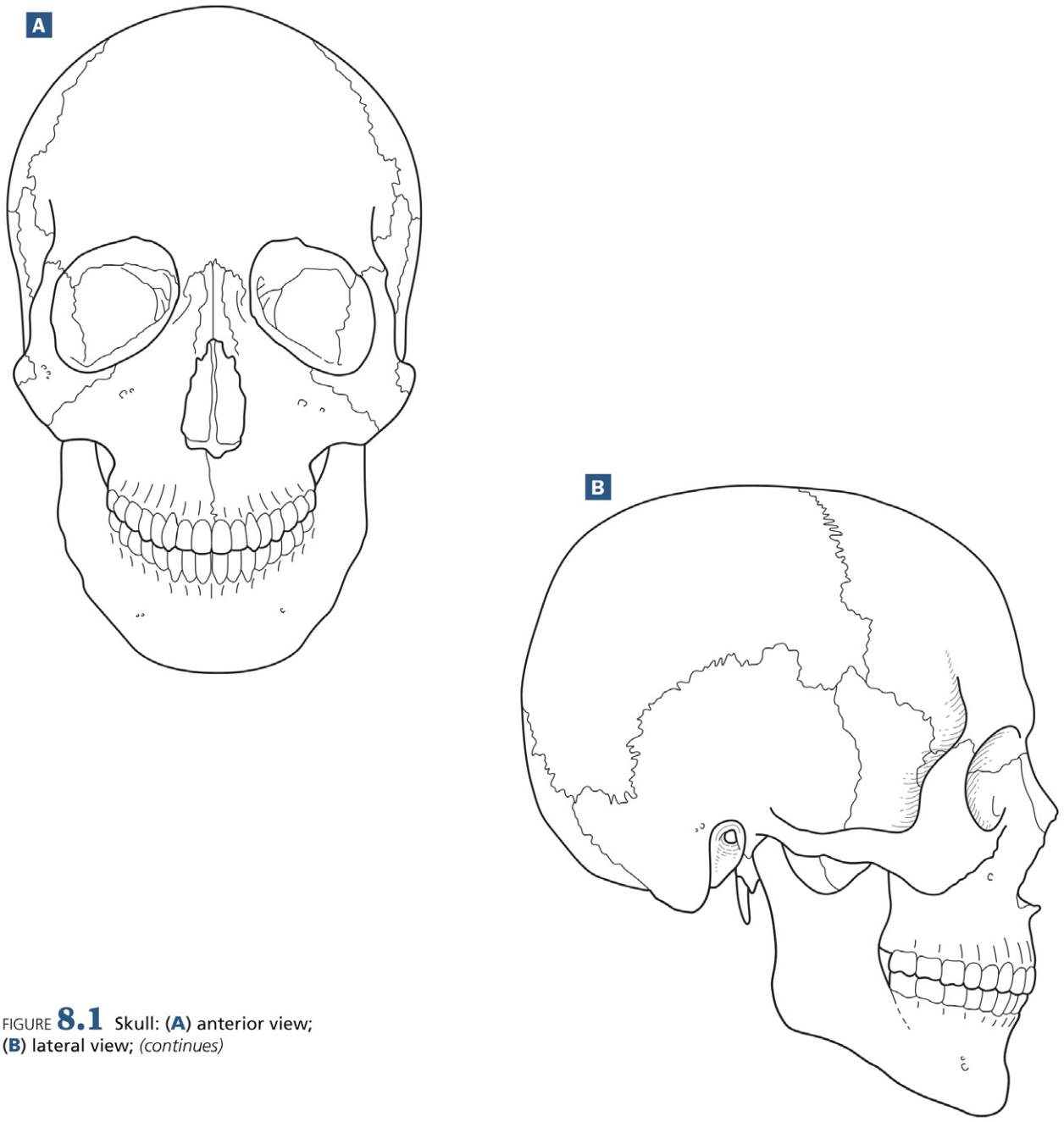

FIGURE **8.1** Skull: (**A**) anterior view; (**B**) lateral view; *(continues)*

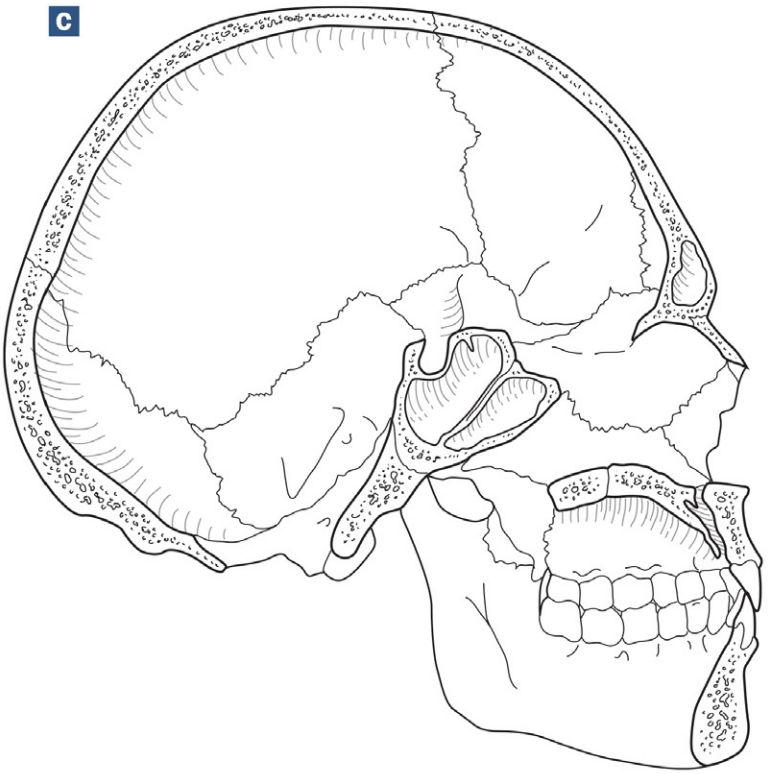

FIGURE **8.1** Skull *(cont.)*: (C) midsagittal section.

Name _____ Section _____ Date _____

Pre-Lab Exercise 8-3

Whole Skeleton

Label and color the structures of the skeleton in Figure 8.2 with the terms from Exercises 8-1 to 8-3 (pp. 180–206). Use your text and Exercises 8-1 to 8-3 in this unit for reference.

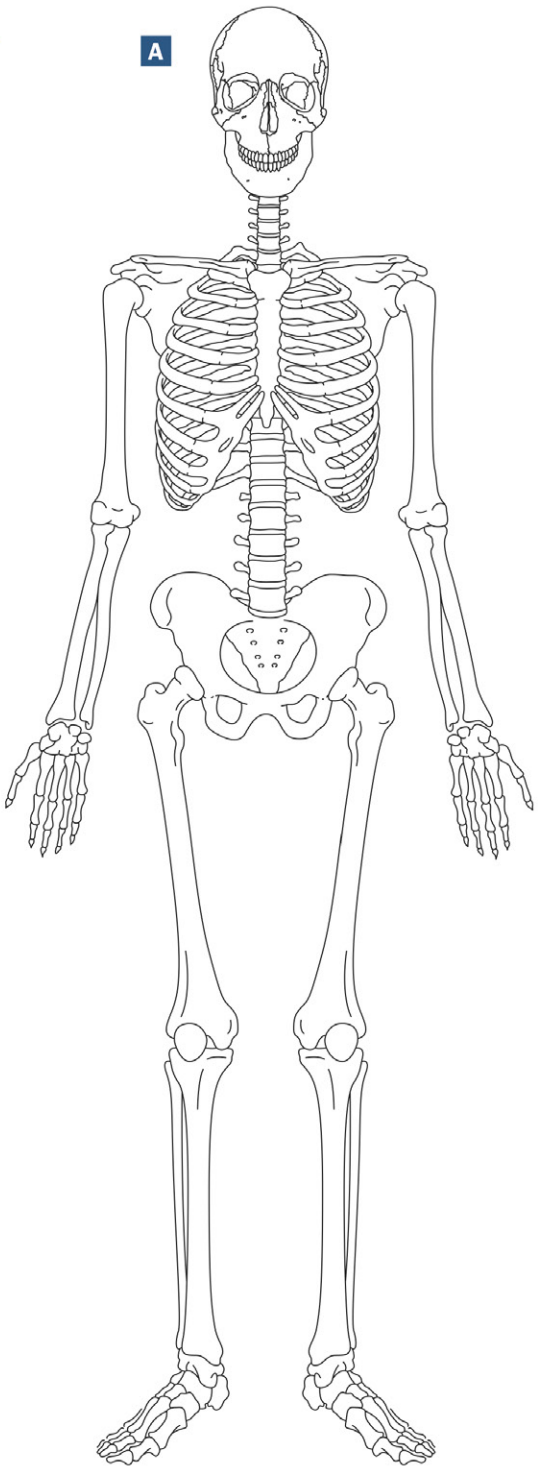

FIGURE **8.2** Skeleton: (**A**) anterior view *(continues)*

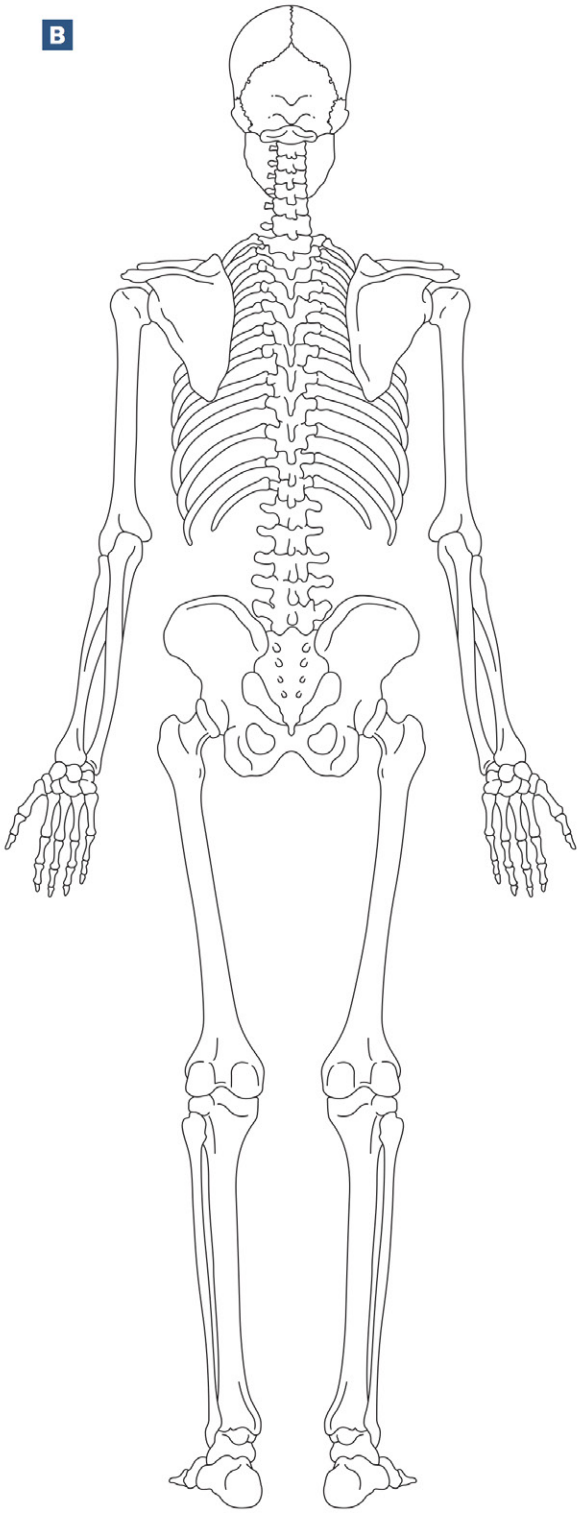

FIGURE **8.2** Skeleton *(cont.)*: **(B)** posterior view.

Computer enhanced X-ray of a skeleton holding a human skull.

EXERCISES

The **skeletal system** consists of the bones, its associated cartilages, and the joints. Its two divisions are the axial skeleton and the appendicular skeleton (Fig. 8.3). The **axial skeleton** is composed of the bones of the head, neck, and trunk—specifically, the cranial bones, the facial bones, the vertebral column, the hyoid bone, the sternum, and the ribs. The **appendicular skeleton** consists of the bones of the upper limbs, the lower limbs, the pectoral girdle (the bones forming the shoulder joint), and the pelvic girdle (the bones forming the pelvis and hip joint).

In this unit we explore the anatomy of the bones and bone markings of the skeletal system, which will serve as a foundation for later chapters. For example, the radial and ulnar arteries parallel the radius and the ulna, and the frontal, parietal, temporal, and occipital lobes of the brain are named for the cranial bones under which they are located.

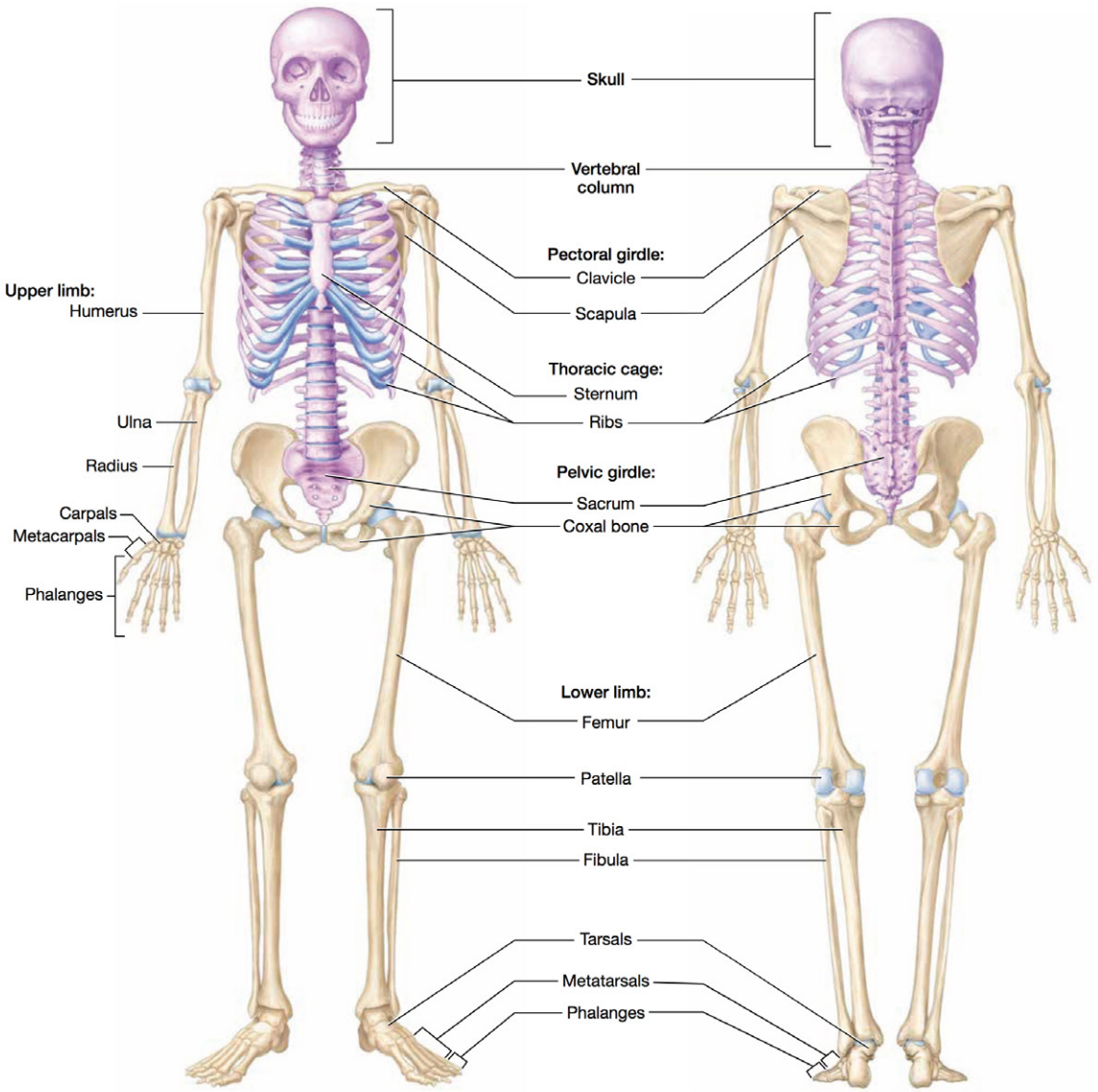

FIGURE **8.3** The axial and appendicular skeletons.

Exercise 8-1

The Skull

MATERIALS

- ❑ Skulls, whole and sectioned
- ❑ Fetal skull

The skull is composed of two classes of bones—the cranial bones and the facial bones (Figs. 8.4–8.10). The **cranial bones** encase the brain and together form the **calvaria** (kal-VEHR-ee-uh; also known as the "skullcap" or *cranial vault*), which consists of several of the cranial bones joined at immovable joints called **sutures** (SOO-tchurz). These bones also form the **cranial base**, which is made up of indentations that support the brain known as the **anterior**, **middle**, and **posterior cranial fossae** (visible in Figure 8.7). The eight cranial bones include the following:

1. **Frontal bone.** The **frontal bone** forms the anterior portion of the cranium, the superior part of the orbit, which houses the eyeball (visible in Fig. 8.4), and the anterior cranial fossa. In Figure 8.4 you can see the smooth area between the eyes called the **glabella**, and two small holes called the **supraorbital foramina**, which are located over the anterior ridge of the orbit, an area known as the **supraorbital margin**. Internally the frontal bone contains the hollow **frontal sinuses**, which are part of the **paranasal sinuses**, a group of bony cavities that surround the nasal cavity (see Fig. 8.12, p. 188). Air from the nasal cavity enters the paranasal sinuses via small openings in the bones, and in the sinuses the air gets filtered, warmed, and humidified.

2. **Parietal bones.** The paired **parietal bones** (puh-RY-ih-tuhl) form the superior and part of the lateral walls of the cranium. Note in Figures 8.9 and 8.10 that they articulate with one another and many other cranial bones at sutures: They meet one another at the **sagittal suture**, they meet the frontal bone at the **coronal suture**, they meet the occipital bone at the **lambdoid suture** (LAM-doyd), and they meet the temporal bones at the **squamous sutures** (seen in Fig. 8.5).
3. **Temporal bones.** The paired **temporal bones** form the lateral walls of the cranium (best seen in Fig. 8.5). Each temporal bone has a complex shape with four general regions.
   a. The flat **squamous region** is the temporal bone's most lateral portion. As its name implies, it is largely flat; however, it does contain a projection called the **zygomatic process** that forms part of the *zygomatic arch* or cheekbone. Just inferior to the zygomatic process is an indentation, the **mandibular fossa**, which forms the *temporomandibular joint*—or the jaw joint—with the mandible.
   b. The temporal bone's inferior region is called the **tympanic region** (tim-PAN-ik). It houses the **external acoustic (auditory) meatus**, an opening to the *external auditory canal*, which leads to the middle and inner ear. Also in this region is a needlelike projection called the **styloid process.**
   c. Posterior to the tympanic region is the **mastoid region**, which contains the large **mastoid process.** Inside the mastoid process are numerous tiny sinuses known as *mastoid air cells*.
   d. Internally, the temporal bone is shaped like a mountain ridge and is accordingly called the **petrous region.** Within this region we find several openings. The first three are best seen in Figure 8.6, and include the medial and anterior **foramen lacerum** (LAS-er-um), the middle **carotid canal**, and the posterior **jugular foramen.** The next opening, the **internal acoustic meatus**, is best seen in Figure 8.8.
4. **Occipital bone.** The posterior cranial bone is the **occipital bone** (awk-SIP-ih-tuhl; best seen in Figures 8.6 and 8.9). Its most conspicuous feature is found in its base—a large hole called the **foramen magnum** through which the spinal cord passes. Anterior and lateral to the foramen magnum are the two **occipital condyles**, which form a joint with the first cervical vertebra. The occipital bone's posterior surface has two prominent horizontal ridges: the **superior** and **inferior nuchal lines** (NOO-kuhl). In the middle of the superior nuchal line we find a bump called the **external occipital protuberance**.
5. **Sphenoid bone.** The butterfly-shaped **sphenoid bone** (SFEE-noyd) is posterior to the frontal bone on the interior part of the skull. Centrally it consists of the **body**, the superior surface of which features two canals called the **optic canals** through which the nerves for vision pass (see Fig. 8.7). Also in the body we find the second paranasal sinus, the **sphenoid sinus**, and a saddlelike formation called the **sella turcica** (SELL-uh TUR-sih-kuh) that houses the pituitary gland (see Figs. 8.7 and 8.8). Extending from the body are three sets of "wings":
   a. The small **lesser wings** are the superior and most anterior set that is best seen in Figure 8.7.
   b. The larger **greater wings** are the inferior and posterior set of wings. In Figure 8.4, you can see the **superior orbital fissure**, which is a slit between the greater and lesser wings through which nerves pass. As you can see

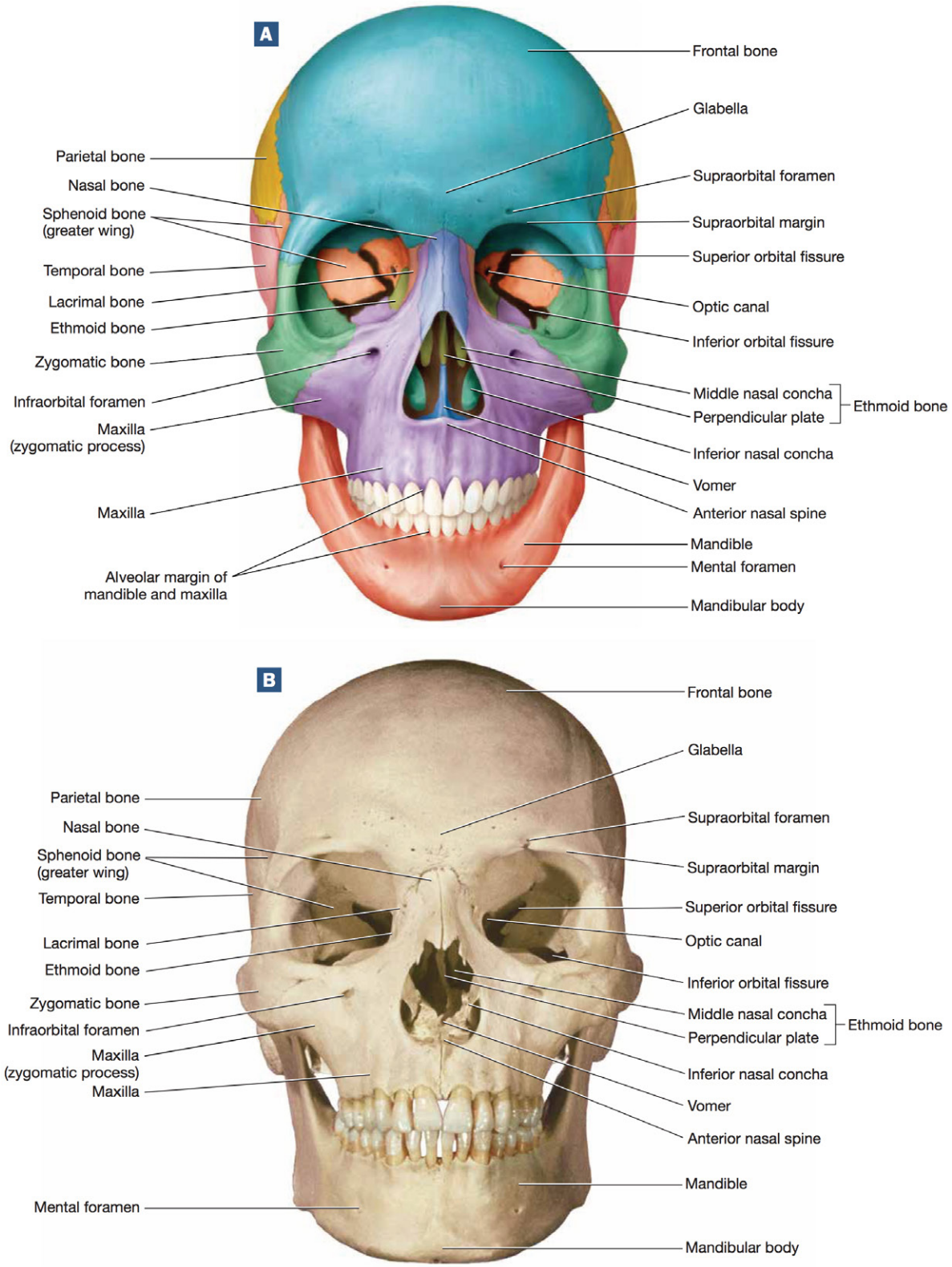

FIGURE **8.4** Anterior view of the skull: (**A**) illustration; (**B**) photograph.

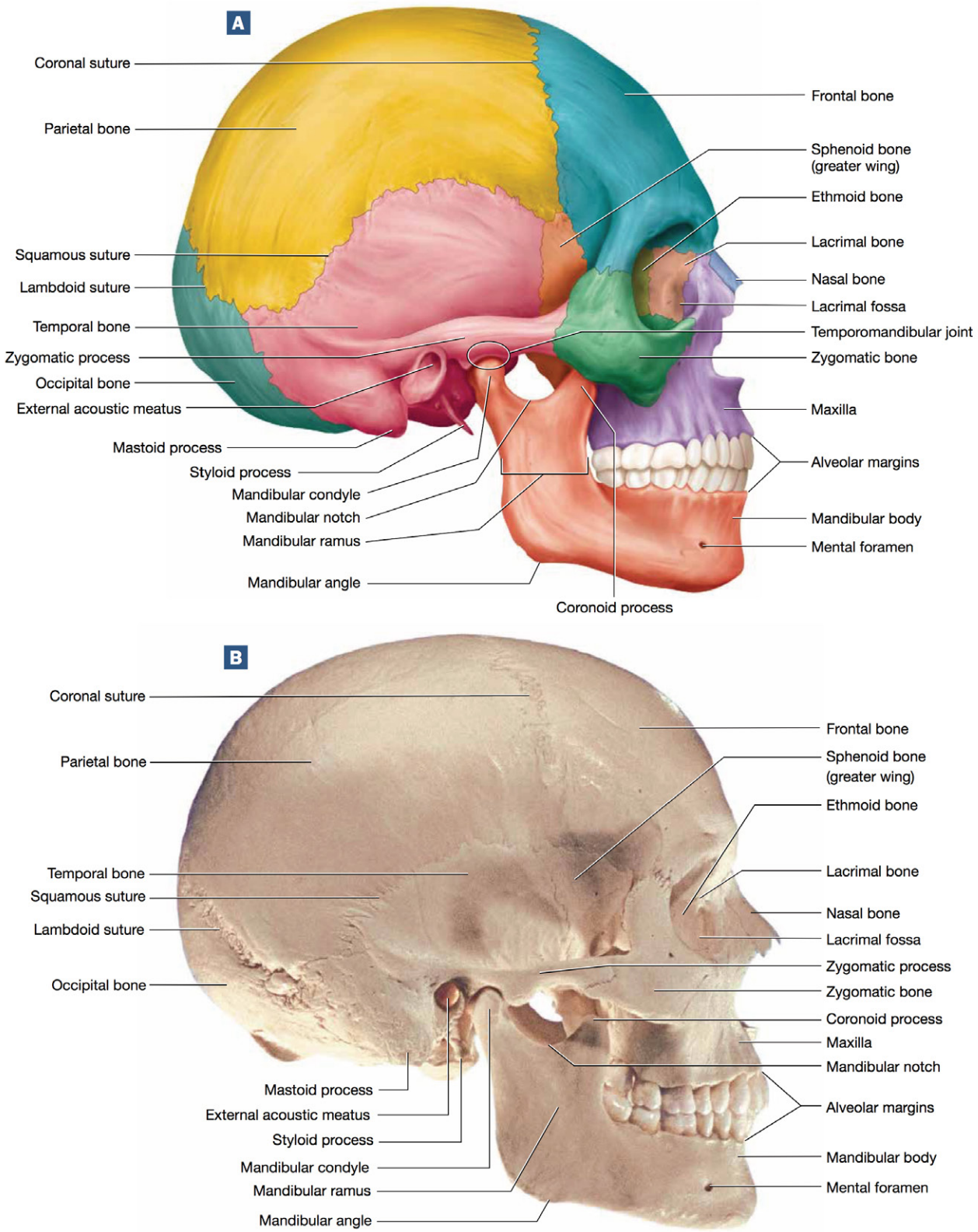

FIGURE **8.5** Lateral view of the skull: (**A**) illustration; (**B**) photograph.

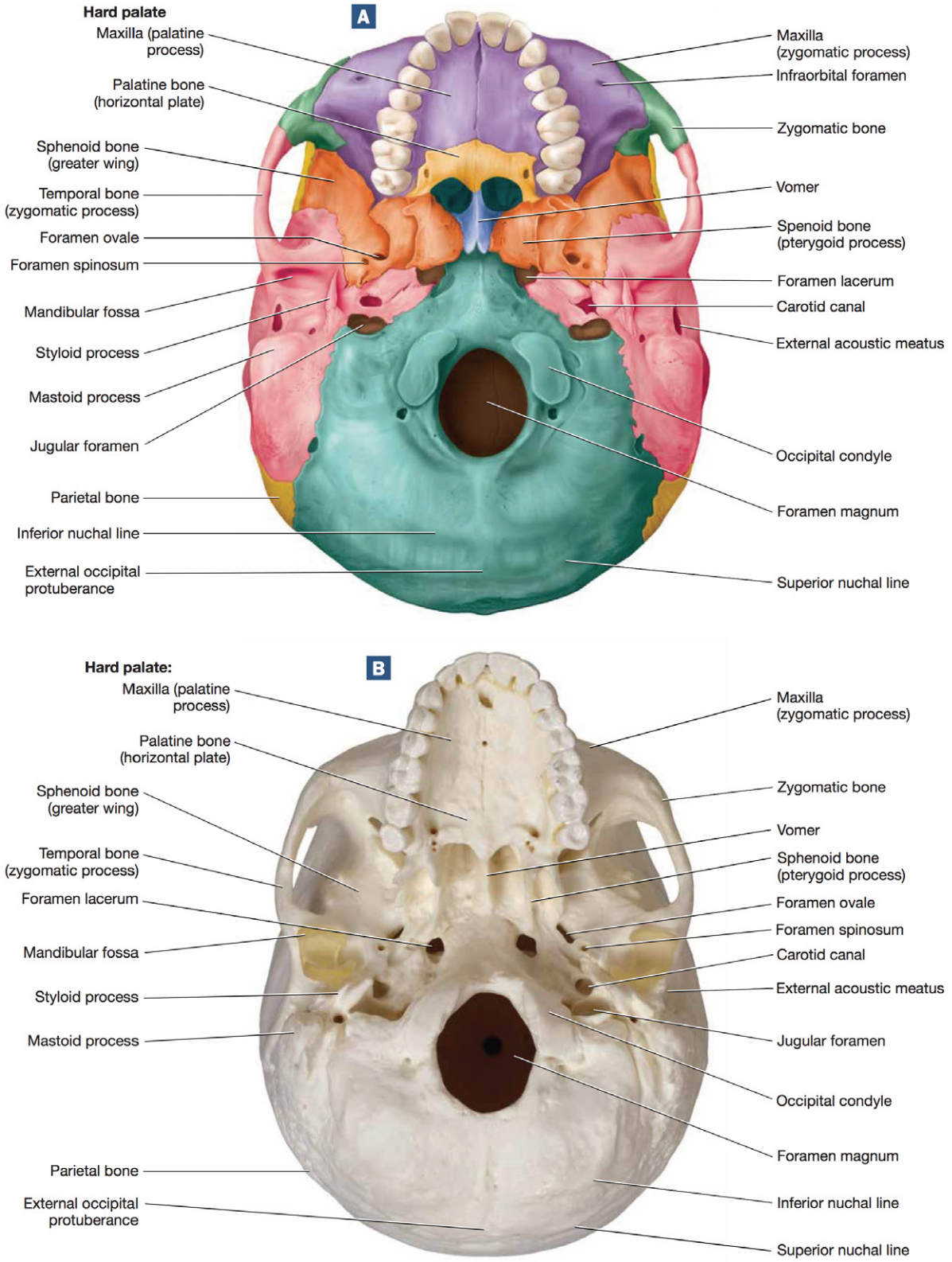

FIGURE **8.6** Inferior view of the skull (mandible removed): (**A**) illustration; (**B**) photograph.

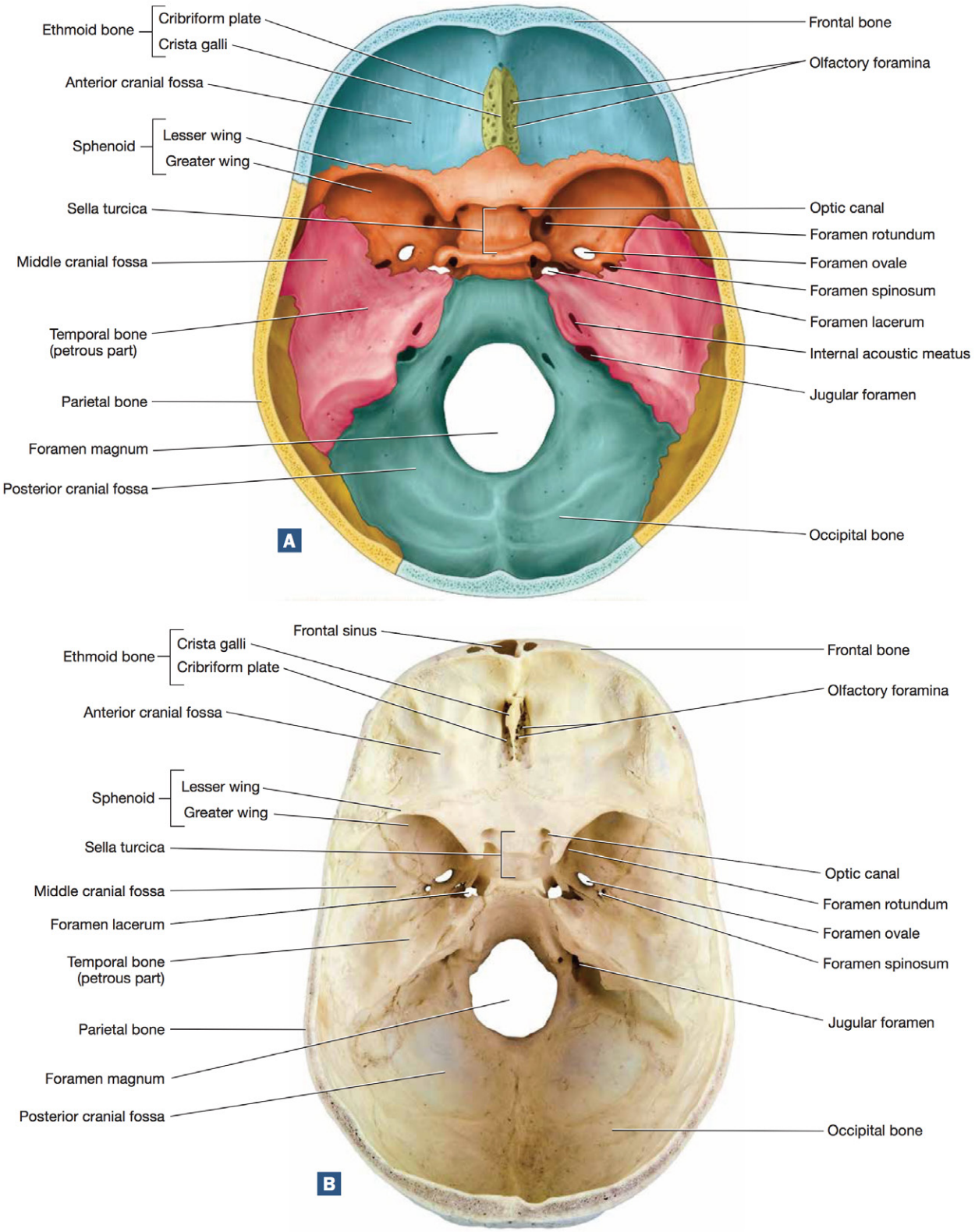

FIGURE **8.7** Interior view of the cranial base (calvaria removed): (**A**) illustration; (**B**) photograph.

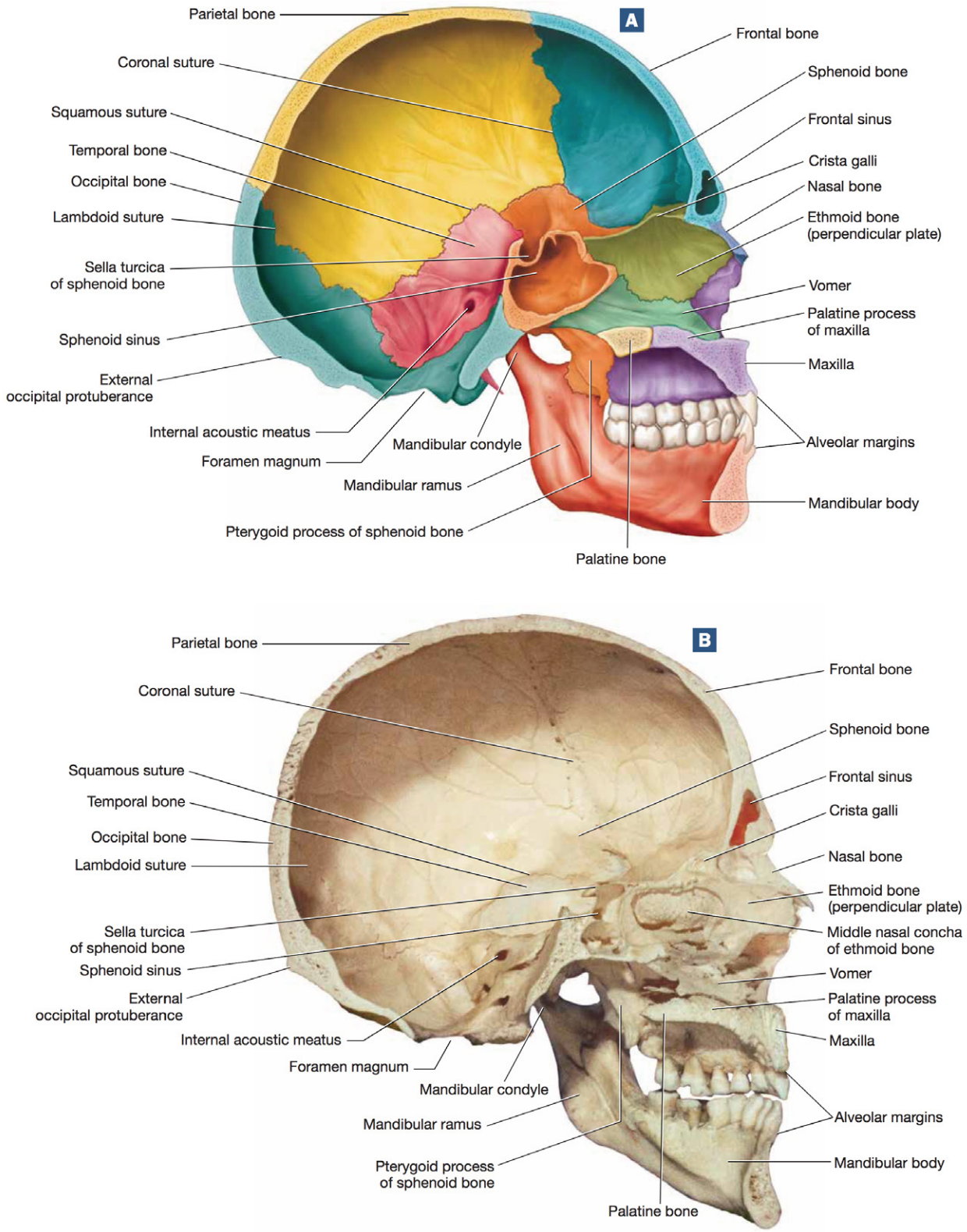

FIGURE **8.8** Midsagittal section of the skull: (**A**) illustration; (**B**) photograph.

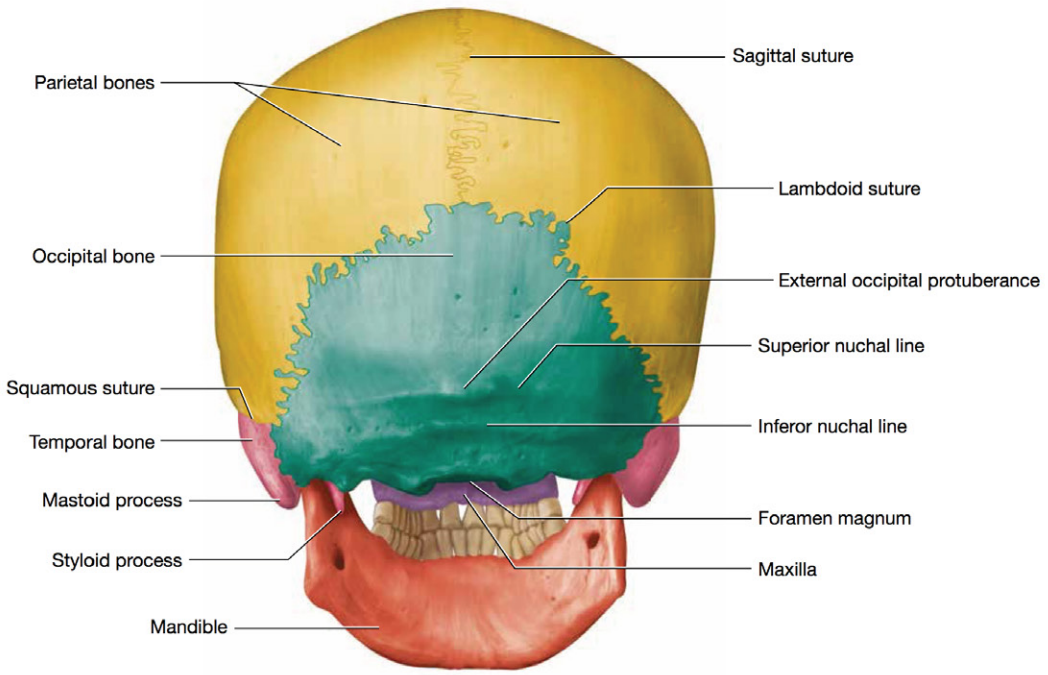

FIGURE **8.9** Posterior view of the skull.

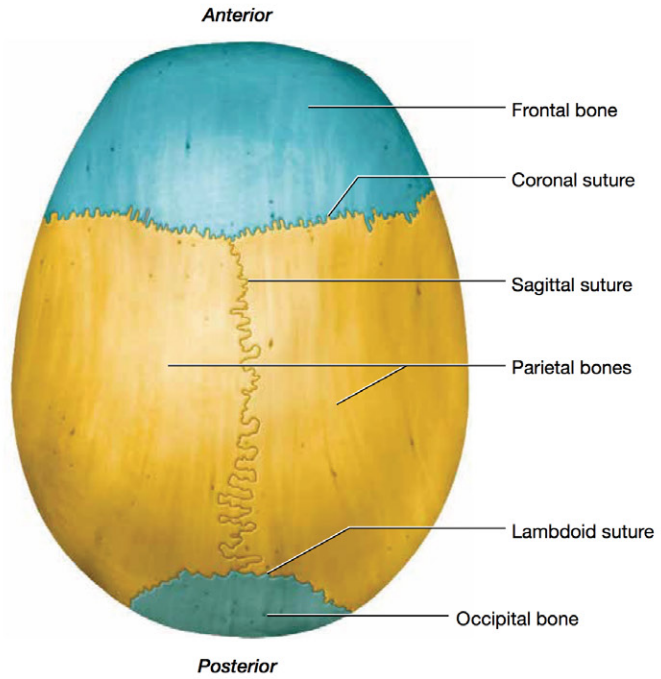

FIGURE **8.10** Superior view of the calvaria.

in Figure 8.7, each greater wing has three prominent sets of foramina: the anterior **foramen rotundum**, the middle **foramen ovale**, and the posterior **foramen spinosum** (a mnemonic that might help you remember this is "Rigatoni Over Spaghetti"). On the anterior side, the greater wings form the posterior portion of the orbit.

c. The inferior set of wings consists of the narrow **pterygoid processes** (TEHR-ih-goyd), which form part of the posterior walls of the nasal and oral cavities (see Figs. 8.6 and 8.8).

6. **Ethmoid bone.** The complex ethmoid bone is the deepest cranial bone and, as such, the most difficult to see from standard views of the skull. For this reason, it is shown in a separate illustration, Figure 8.11. Located anterior to the sphenoid bone and posterior to the nasal bones of the face, it contains a number of features, including the following:

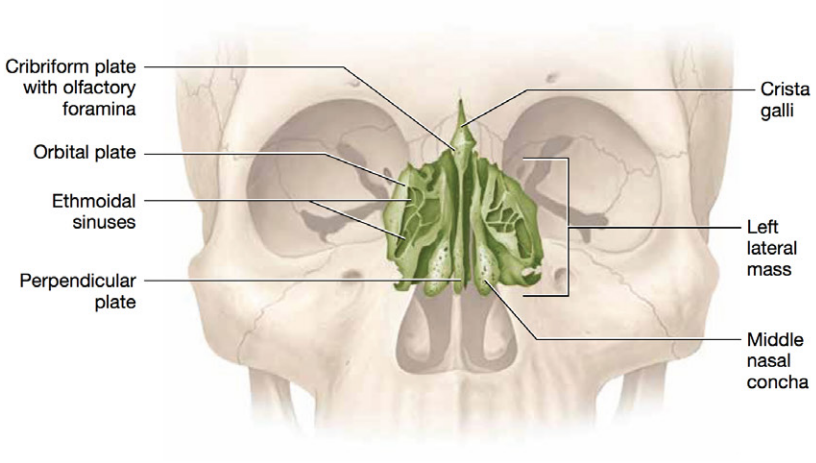

FIGURE **8.11** Ethmoid bone.

a. Its superior surface, called the **cribriform plate,** forms the roof of the nasal cavity and part of the base of the cranial cavity. It has small holes, called **olfactory foramina,** through which olfactory nerves pass, and a superior projection called the **crista galli** (KRIS-tah GAL-ee), to which certain membranes around the brain attach.

b. The **lateral masses** of the ethmoid bone form part of the orbit (the *orbital plate*) and the walls of the nasal cavity. Internally, the lateral masses contain numerous cavities called the **ethmoid sinuses,** which are the third set of paranasal sinuses (Fig. 8.12). Extending medially from the lateral masses are two projections into the nasal cavity—the **superior nasal conchae** and **middle nasal conchae** (KAHN-kee). Note that the superior nasal conchae are quite small and are usually difficult to see.

c. The middle portion of the ethmoid bone, called the **perpendicular plate,** forms the superior part of the bony nasal septum.

The 14 **facial bones** form the framework for the face, provide openings for ventilation and eating, and form cavities for the sense organs. Several of the facial bones are located deeper in the skull, and you will want to refer to several different figures (noted with each bone) to best locate them and appreciate their structures.

1. **Mandible.** The **mandible,** or the lower jaw bone, consists of a central **body** and two "arms" called the **mandibular rami** (RAY-mee; see Figs. 8.4 and 8.5). As you can see in the figures, the lower teeth are attached to the mandibular body along a border called the **alveolar margin** (al-vee-OH-lahr). On each side of the lateral mandibular body we find a small hole called the **mental foramen.** Just lateral to the mental foramina, the mandibular rami turn superiorly at the **mandibular angle.** Their superior ends have two processes separated by the **mandibular notch:** an anterior process called the **coronoid process** and a posterior process called the **mandibular condyle.** The mandibular condyle fits into the mandibular fossa in the temporal bone to form the **temporomandibular joint,** or **TMJ.**

2. **Maxillae.** The two fused **maxillae** (mak-SILL-ee) are the upper jaw bones (Figs. 8.4–8.6). They form the inferior wall of the orbit, part of the lateral wall of the nasal cavity, and part of the superior wall of the oral cavity. Inside the orbit, where the maxilla meets the sphenoid bone, we find a slit known as the **inferior orbital fissure,** which serves as a passageway for nerves and blood vessels. Just inferior to the orbit is a small hole called the **infraorbital foramen.** In Figure 8.6, you can see that the maxillae also form the anterior portion of the *hard palate* via their **palatine processes.** Within their walls are cavities called the **maxillary sinuses,** the fourth and final set of paranasal sinuses (Fig. 8.12). Laterally the maxillae have projections called **zygomatic processes** that

form part of the cheekbone. Like the mandible, the maxillae also have an alveolar margin along which the upper teeth are attached.

3. **Lacrimal bones.** The tiny **lacrimal bones** (LAK-rih-muhl) are located in the medial part of the orbit, where they form part of the structure that drains tears produced by the lacrimal gland of the eye. They are best seen in Figure 8.5, where you can see the inferior indentation called the lacrimal fossa.
4. **Nasal bones.** The two **nasal bones** form the anterior framework of the bridge of the nose.
5. **Vomer.** The single **vomer** (VOH-muhr) forms the inferior portion of the bony nasal septum (best seen in Fig. 8.8).
6. **Inferior nasal conchae.** The small **inferior nasal conchae** form part of the lateral walls of the nasal cavity. As their name implies, they are located inferior to the middle nasal conchae of the ethmoid bone (Fig. 8.4).

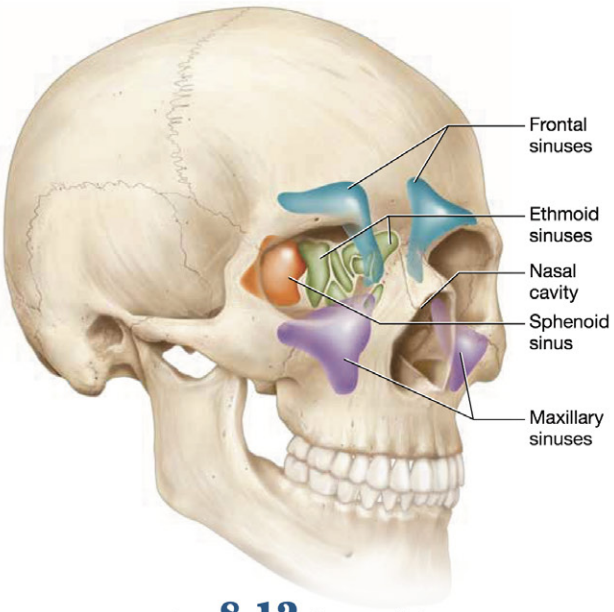

FIGURE **8.12** Paranasal sinuses.

7. **Palatine bones.** The two **palatine bones** (PAL-uh-ty'n) form the posterior part of the hard palate (seen in Fig. 8.6) and the posterolateral walls of the nasal cavity.
8. **Zygomatic bones.** The two **zygomatic bones** form the bulk of the cheek and a significant portion of the "cheekbone" or zygomatic arch (Figs. 8.4 and 8.5).

The orbit and the nasal cavity are complicated structures with contributions from several bones. The **orbit** is formed by parts of seven bones: the frontal bone, maxilla, sphenoid bone, ethmoid bone, lacrimal bone, zygomatic bone, and a tiny piece of the palatine bone (Fig. 8.4). The **nasal cavity** is formed by parts of six bones: the ethmoid bone, maxilla, palatine bone, inferior nasal concha, sphenoid bone, and vomer (Figs. 8.4 and 8.8).

The features we have been examining are found in an adult skull. However, as you can see in Figure 8.13, a fetal skull contains notable differences from an adult skull. In adults, the sutures are fused, but in the fetus, the sutures have not yet fused and are instead joined by fibrous membranes. This can be seen with the **frontal suture**, also known as the **metopic suture** (met-AHP-ik), seen where the two fetal frontal bones fuse. Where several sutures meet, we find large, membrane-covered areas called the **fontanels**, known to many as "soft spots." The two main fontanels are the **anterior fontanel**, where the sagittal and coronal sutures meet, and the **posterior fontanel**, where the sagittal and lambdoid sutures meet.

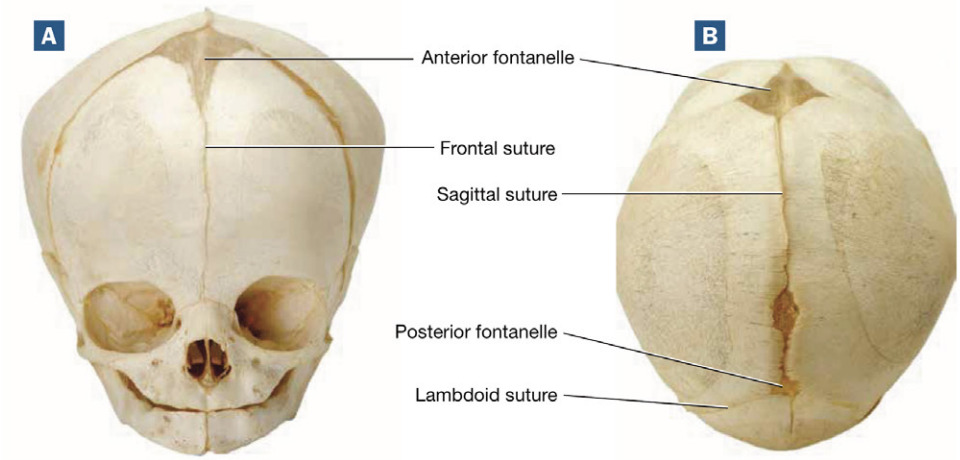

FIGURE **8.13** Fetal skull: (**A**) anterior view; (**B**) superior view.

Procedure 1 Cooperative Learning for the Skull

This exercise takes an approach called *cooperative learning*, in which you work with your lab partners to teach one another the bones and bone markings. The process may seem a bit confusing at first, but by the end of the first couple of rotations, it should move more quickly and smoothly. After you have completed the activity, answer Check Your Understanding questions 1 through 3 (p. 223).

1. Assemble into teams of a minimum of four students; five is optimum.
2. Distribute a skull to each member of the team, and assign each student one of the following five groups of bones and bone markings (the specific structures of each bone are listed below and on the following page:
   - *Group A*: Calvaria, base, and structures of the frontal bone and parietal bones.
   - *Group B*: Temporal bone and occipital bone structures.
   - *Group C*: Ethmoid bone and sphenoid bone structures.
   - *Group D*: Mandible and maxillary bone structures.
   - *Group E*: Remainder of the facial bones, orbit, sutural bones, and anterior and posterior fontanels.
3. Spend approximately 3 minutes learning the assigned structures on your own. Explore each structure thoroughly—if there are canals and foramina, pass a pipe cleaner through the holes to see where they go.
4. Then have each team member spend approximately 1 to 2 minutes teaching the team his or her assigned structures.
5. Rotate the assigned structures clockwise so each member has a new set of structures to learn (the student who was assigned group A will take group B, and so on).
6. Spend approximately 2 to 3 minutes learning your newly assigned structures.
7. Have each team member spend approximately 1 to 2 minutes teaching the group his or her assigned structures.
8. Repeat this process (it begins to speed up significantly at this point) until each team member has taught each group of structures once.

By the end of this activity, each team member will have learned and presented each group of structures.

The following is a list of bones and bone markings of the skull that will be covered in this exercise.

Cranial Bones

Group A Structures

1. Calvaria
2. Base of cranial cavity
   a. Anterior cranial fossa
   b. Middle cranial fossa
   c. Posterior cranial fossa
3. Frontal bone
   a. Glabella
   b. Supraorbital foramen
   c. Frontal sinuses
4. Parietal bones
   a. Sagittal suture
   b. Coronal suture
   c. Lambdoid suture
   d. Squamous suture

Group B Structures

1. Temporal bones
   a. Zygomatic process
   b. Mandibular fossa
   c. External acoustic (auditory) meatus
   d. Styloid process
   e. Mastoid process with mastoid air cells
   f. Foramen lacerum
   g. Carotid canal
   h. Jugular foramen
   i. Internal acoustic meatus
2. Occipital bone
   a. Foramen magnum
   b. Occipital condyles
   c. Superior nuchal line
   d. Inferior nuchal line
   e. External occipital protuberance

Group C Structures

1. Sphenoid bone
   a. Body
   b. Optic canal
   c. Sphenoid sinus
   d. Sella turcica
   e. Lesser wings
   f. Greater wings
   g. Superior orbital fissure
   h. Foramen rotundum
   i. Foramen ovale
   j. Foramen spinosum
   k. Pterygoid processes
2. Ethmoid bone
   a. Cribriform plate
   b. Olfactory foramina
   c. Crista galli
   d. Lateral masses
   e. Ethmoid sinuses
   f. Superior and middle nasal conchae
   g. Perpendicular plate

Facial Bones and Other Structures

Group D Structures

1. Mandible
   a. Body of mandible
   b. Mandibular ramus
   c. Alveolar margin
   d. Mental foramen
   e. Mandibular angle
   f. Mandibular notch
   g. Coronoid process
   h. Mandibular condyle
   i. Temporomandibular joint
2. Maxillae
   a. Inferior orbital fissure
   b. Infraorbital foramen
   c. Palatine processes
   d. Maxillary sinuses
   e. Zygomatic processes
   f. Alveolar margin

Group E Structures

1. Lacrimal bones and lacrimal fossa
2. Nasal bones
3. Vomer
4. Inferior nasal conchae
5. Palatine bones
6. Zygomatic bones and zygomatic arch
7 Orbit
8. Nasal cavity
9. Frontal (metopic) suture
10. Anterior fontanel
11. Posterior fontanel

Your instructor may wish to omit certain structures included above or add structures not included in these lists. List any additional structures below:

Exercise 8-2

Remainder of the Axial Skeleton

MATERIALS

- ❑ Vertebral column, articulated
- ❑ Disarticulated bones: vertebrae, sacrum, sternum, ribs, hyoid bone
- ❑ Skeleton, articulated

Another key component of the axial skeleton is the **vertebral column**, which consists of 24 unfused vertebrae, the five fused vertebrae of the sacrum (SAY-krum), and the coccyx (KAHX-iks). If you view the vertebral column from the lateral side, as in Figure 8.14, you can see that there are spaces between the vertebrae called **intervertebral foramina**. In addition, the vertebral column has four curvatures: the concave **cervical** and **lumbar curvatures** and the convex **thoracic** and **sacral curvatures**. The cervical and lumbar curvatures are particularly important to our ability to walk upright.

The 24 vertebrae consist of 7 cervical vertebrae, 12 thoracic vertebrae, and 5 lumbar vertebrae (remember this as "breakfast at 7, lunch at 12, dinner at 5"). Nearly all vertebrae share certain general features, which are visible in the typical cervical vertebra shown in Figure 8.15A. These features include a posterior **spinous process**, two lateral **transverse processes**, a central **vertebral foramen**, an anterior **vertebral body**, two **superior articular processes** and **facets** that articulate with the vertebra above, and two inferior articular processes and facets that articulate with the vertebra below. In between each vertebral body is a fibrocartilage pad called an **intervertebral disc** that absorbs shock as the vertebral column moves. Extending from the vertebral body to the transverse processes on both sides are two short extensions known as **pedicles**, which enclose the vertebral foramen along with two posterior extensions, the **laminae**.

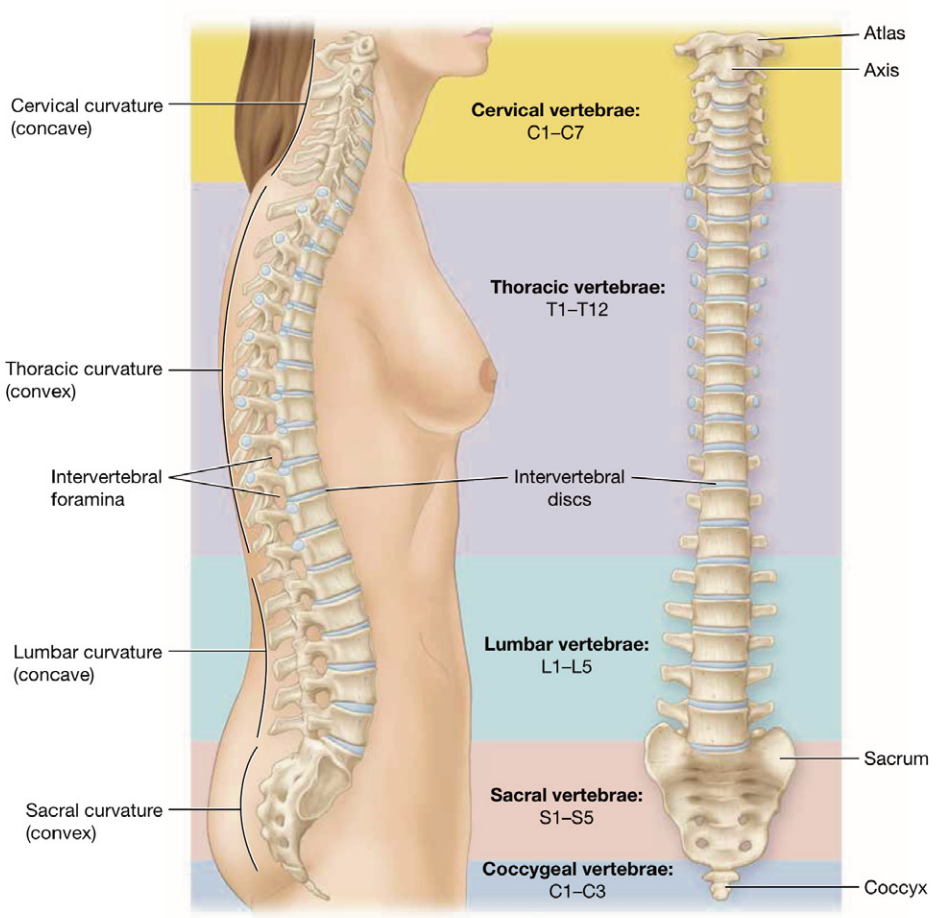

FIGURE **8.14** Vertebral column.

The basic properties of each region of the vertebral column are as follows:

1. The seven **cervical vertebrae** are located in the neck (Fig. 8.15A–C). All cervical vertebrae have holes in their transverse processes called **transverse foramina** that permit the passage of blood vessels called the *vertebral artery* and *vein*. In addition, the spinous processes of cervical vertebrae are often forked. Two cervical vertebrae are named differently than the others because of their unique features:
   a. **Atlas** (C1): The **atlas** is the first cervical vertebra, and it articulates with the occipital condyles of the occipital bone. It is easily identified because it has a large vertebral foramen, no body, and no spinous process (Fig. 8.15B).
   b. **Axis** (C2): The **axis** is the second cervical vertebra. It is also easily identified by a superior projection called the **dens** (or the **odontoid process**; Fig. 8.15C). The dens fits up inside the atlas to form the *atlanto-axial joint*, which allows rotation of the head.
2. The 12 **thoracic vertebrae** each articulate with a pair of ribs, and they share the following common features (Fig. 8.15D):
   a. The spinous processes are thin and point inferiorly.
   b. They lack transverse foramina.
   c. Most have two *costal facets* that articulate with the ribs (there are 12 pairs of ribs). They also have *transverse costal facets* on their transverse processes that articulate with a part of the rib called the *tubercle*.
   d. All have approximately triangular vertebral foramina.
   e. If you look at a thoracic vertebra from the posterolateral side, it looks like a giraffe. Try it—it really does!
3. The five large **lumbar vertebrae** share the following common features (Fig. 8.15E):
   a. All have a large, blocklike body.
   b. The spinous processes are thick and point posteriorly.
   c. They lack transverse foramina and costal facets.
   d. If you look at a lumbar vertebra from the posterolateral side, it looks like a moose.
4. The **sacrum** consists of five fused vertebrae (Figs. 8.15F and 8.15G). On its superior surface we find the **sacral promontory**, which is the portion of the first sacral body that projects anteriorly into the pelvic cavity. Lateral to the sacral promontory are smooth regions known as the **alae** (AY-lee). Just posterior to the sacral promontory is the **sacral canal**, through which the inferior bundle of spinal nerve roots passes from the vertebral foramen of the fifth lumbar vertebra. You can see the fused spinous processes of the vertebrae on the sacrum's posterior side as the **median sacral crest**. Spinal nerves pass through holes called **anterior** and **posterior sacral foramina** that flank both sides of the sacral bodies. The lateral surfaces of the sacrum, known as the *auricular surfaces*, articulate with the hip bones to form the **sacroiliac joints** (say-kroh-ILL-ee-ak).
5. The **coccyx** consists of three to five (average: four) small, fused vertebrae that articulate superiorly with the sacrum.

HINTS & TIPS

How to Tell the Different Vertebrae Apart

It's not uncommon to find yourself in a lab practical having to identify a single vertebra as being cervical, thoracic, or lumbar. Fortunately, they're really easy to tell apart if you remember a few key things.

- Only cervical vertebrae have transverse foramina. So if you see holes in the transverse processes of the vertebra, you know you're holding a cervical vertebra. From there, you might need to know if you're holding the atlas (C1) or the axis (C2):
  - Only the atlas lacks a vertebral body, which gives it a huge vertebral foramen.
  - Only the axis has a superior projection—the dens. If you get confused as to which is the axis and which is the atlas, here's a simple visual analogy: Think about the dens as being a projection you could stick something like a DVD on top of, and the DVD would be able to spin on its axis.
- Only thoracic vertebrae have costal facets. So if you find yourself with a vertebra that lacks transverse foramina but has indentations (facets) on its body where it articulates with ribs, you've got a thoracic vertebra.
- Lumbar vertebrae are easy to identify by their large, blocky shape, but they can also be identified by process of elimination. If there are no transverse foramina and no costal facets, you're left with only lumbar vertebrae. If the costal facets on your bones aren't very well-defined and you're stuck between thoracic and lumbar, you can also use the giraffe/moose trick. The thoracic vertebra really does look like a giraffe and the lumbar like a "lumbering moose."

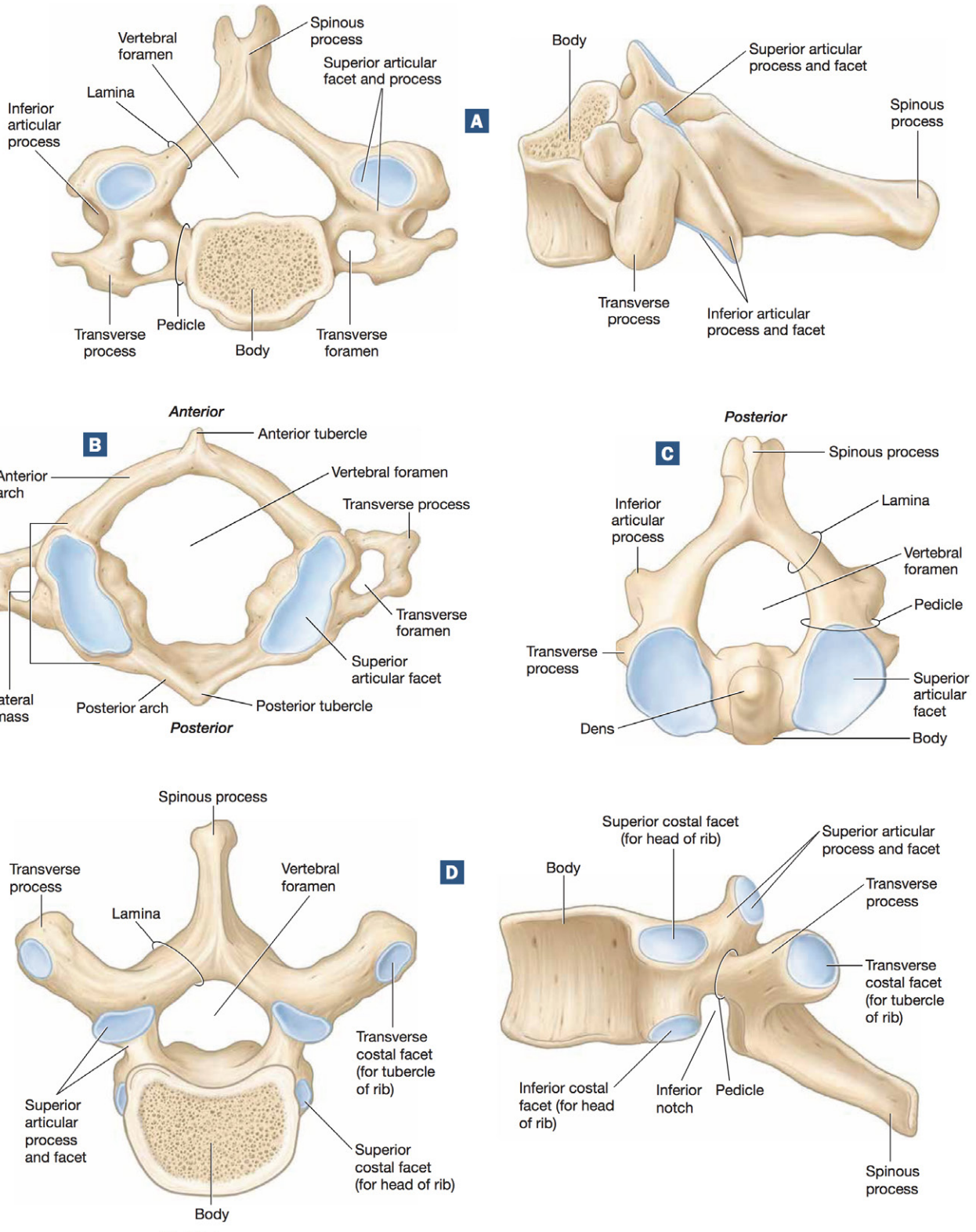

FIGURE **8.15** Vertebrae: (**A**) typical cervical vertebra, superior and lateral views; (**B**) atlas (C1); (**C**) axis (C2); (**D**) typical thoracic vertebra, superior and lateral views; *(continues)*

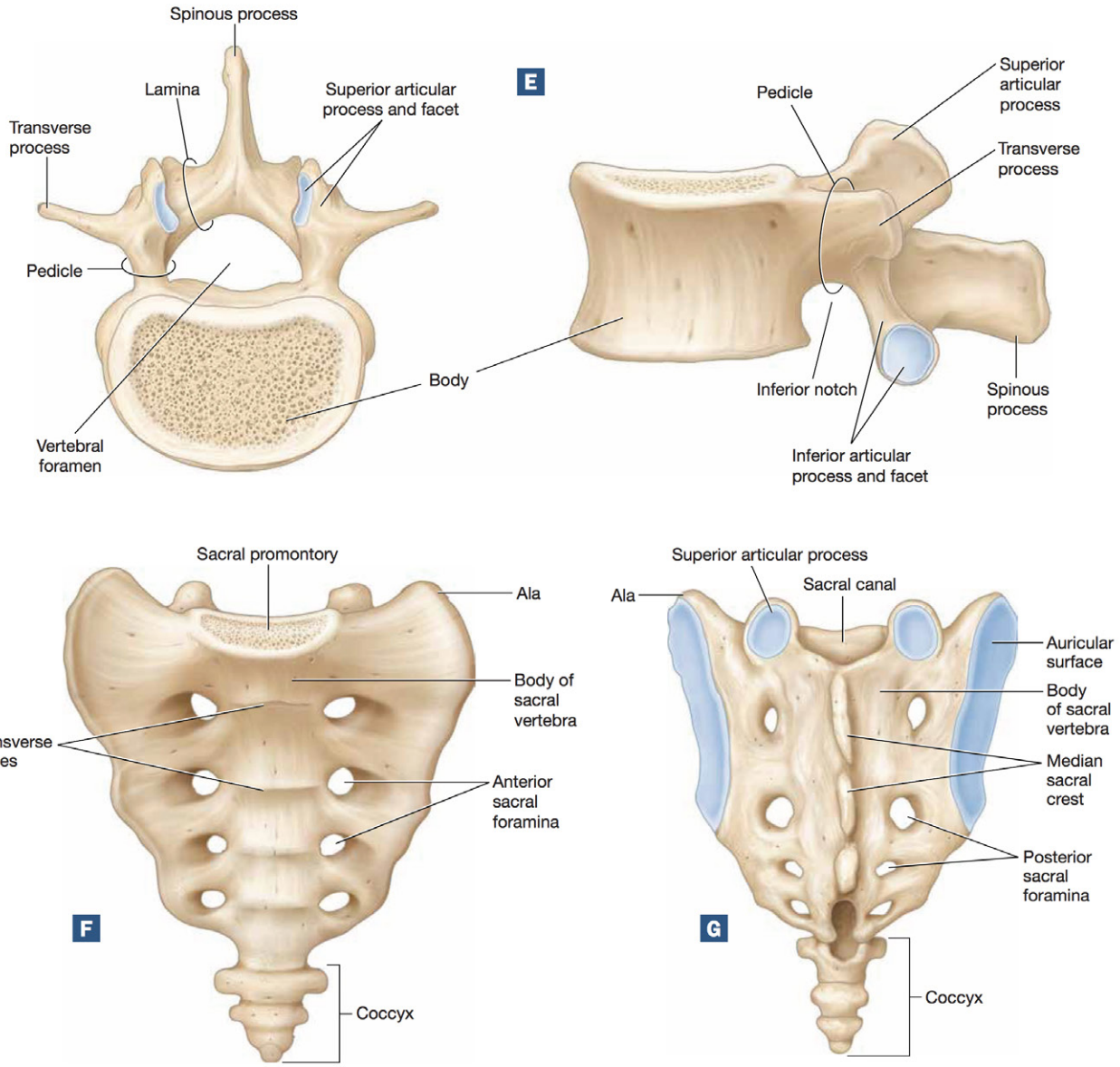

FIGURE **8.15** Vertebrae *(cont.)*: (**E**) typical lumbar vertebra, superior and lateral views; (**F**) sacrum, anterior view; (**G**) sacrum, posterior view.

The remainder of the axial skeleton consists of the bones of the thoracic cavity (the sternum and the ribs, Figs. 8.16 and 8.17) and the hyoid bone in the neck (Fig. 8.18). The **sternum** is the central bone of the thorax. It is divided into three parts—the superior **manubrium** (mah-NOO-bree-um), the middle **body**, and the inferior **xiphoid process** (ZY-foyd). It is the body of the sternum that you compress during the chest compressions of cardiopulmonary resuscitation (CPR), and the xiphoid process that you must take care not to break.

The twelve pairs of **ribs** enclose the thoracic cavity and protect its vital organs (note that men and women have the same number of ribs). The spaces between the ribs are known as **intercostal spaces**, and they contain muscles, blood vessels, nerves, and lymphatic vessels. Ribs articulate anteriorly with the sternum via **costal cartilage**. They are classified according to the structure of their costal cartilage: Ribs 1–7 are considered **true ribs** or **vertebrosternal ribs**, because they attach directly to the sternum by their own costal cartilage, whereas ribs 8–12 are classified as **false ribs**, because they lack this direct attachment to the sternum. However, ribs 8–10 do attach to the sternum via the cartilage of the true ribs and so

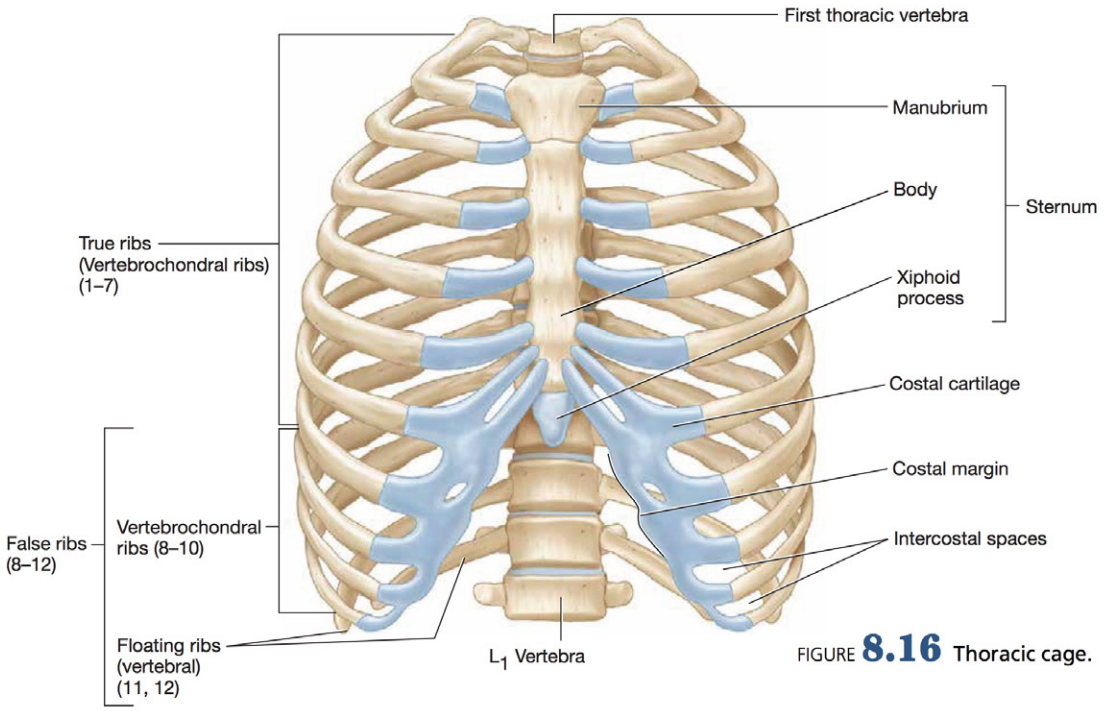

FIGURE **8.16** Thoracic cage.

they are called **vertebrochondral ribs.** Ribs 11–12 lack any attachment to the sternum, so they are often referred to as **floating ribs** or **vertebral ribs.** The medial border of the costal cartilage of the false ribs is known as the **costal margin.**

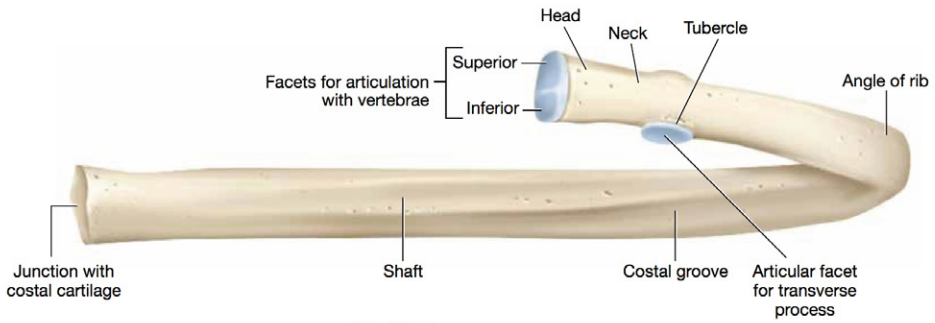

FIGURE **8.17** A rib, posterior view.

In Figure 8.17, you can see the rib's **superior** and **inferior facets** on the rib's posterior **head.** Here the rib straddles two thoracic vertebral bodies—the superior facet of the rib articulates with the inferior costal facet of the vertebra above, and the inferior facet of the rib articulates with the superior costal facet of the rib below. Lateral to the head we find the **neck,** which contains a **tubercle** that articulates with a vertebra's transverse process. The rib curves around anteriorly at its **angle,** after which the main anterior portion becomes known as the **shaft.** On the shaft's interior surface is the **costal groove,** which is where blood vessels and nerves travel.

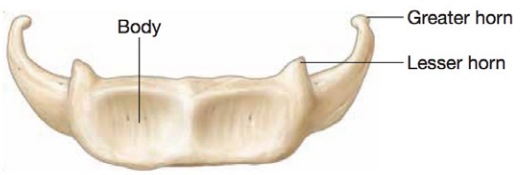

FIGURE **8.18** Hyoid bone.

The **hyoid bone,** shown in Figure 8.18, is located in the superior neck where it is occasionally classified as a skull bone. Note, however, that it does not articulate with any skull bone, or any other bone for that matter. It is held in place in the superior neck by muscles and ligaments, and it helps to form part of the framework for the larynx (LEHR-inks; voice box). It also serves as an attachment site for the muscles of the tongue and aids in swallowing. When a person is choked manually, the hyoid bone is often broken.

The bones and bone markings of the axial skeleton are listed with Exercise 8-3 (p. 196), where they will be included with another cooperative learning exercise.

Exercise 8-3

The Appendicular Skeleton

MATERIALS

- ❑ Disarticulated bones
- ❑ Skeleton, articulated
- ❑ Male and female pelvises

The bones of the appendicular skeleton can be divided into those of the **pectoral girdle**, the upper limb, the **pelvic girdle**, and the lower limb. Let's look at each individually.

Pectoral Girdle

The **pectoral girdle** consists of the two bones that frame the shoulder—the scapula and the clavicle (Fig. 8.19). The **scapula** (SKAP-yoo-lah), shown in Figure 8.20, is a roughly triangular-shaped bone with **superior, lateral,** and **medial borders.** The corners of the "triangle" are known as the **superior, lateral,** and **inferior angles.** The scapula's broad, flat surface is the **body.** On the anterior surface (Fig. 8.20A), the body has a broad indentation, the **subscapular fossa.** On its lateral surface (Fig. 8.20B) is a shallow depression called the **glenoid cavity** that forms the shoulder joint with the humerus. From this side you can also get a good view of its two superior projections: the anterior **coracoid process** (KOHR-ah-koyd) and the posterior **acromion** (ah-KROH-mee-ahn). The acromion forms a joint with the lateral portion of the clavicle called the **acromioclavicular** (ah-KROH-mee-oh-klah-VIK-yoo-lur; **AC**) joint. When we turn to the scapula's posterior surface (Fig. 8.20C), we find a prominent ridge called the **spine** that you can feel under your skin as your "shoulder blade." Superior and inferior to the scapular spine are two depressions: the **supraspinous** and **infraspinous fossae.**

The **clavicle** is a small S-shaped bone that spans between the acromion of the scapula at its

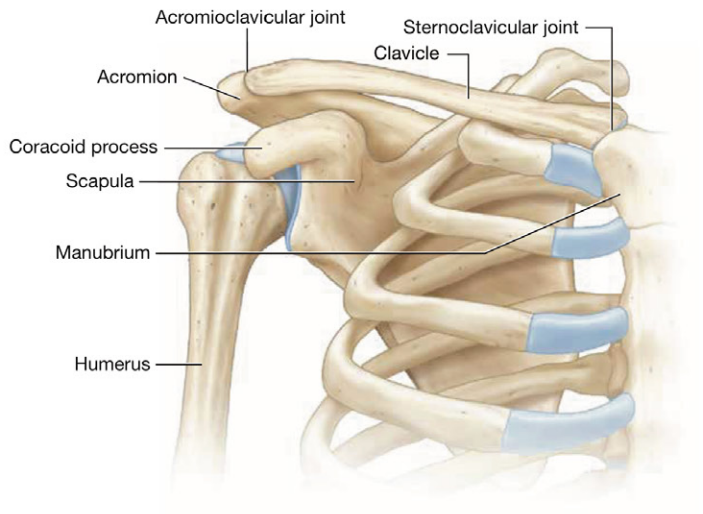

FIGURE **8.19** Pectoral girdle.

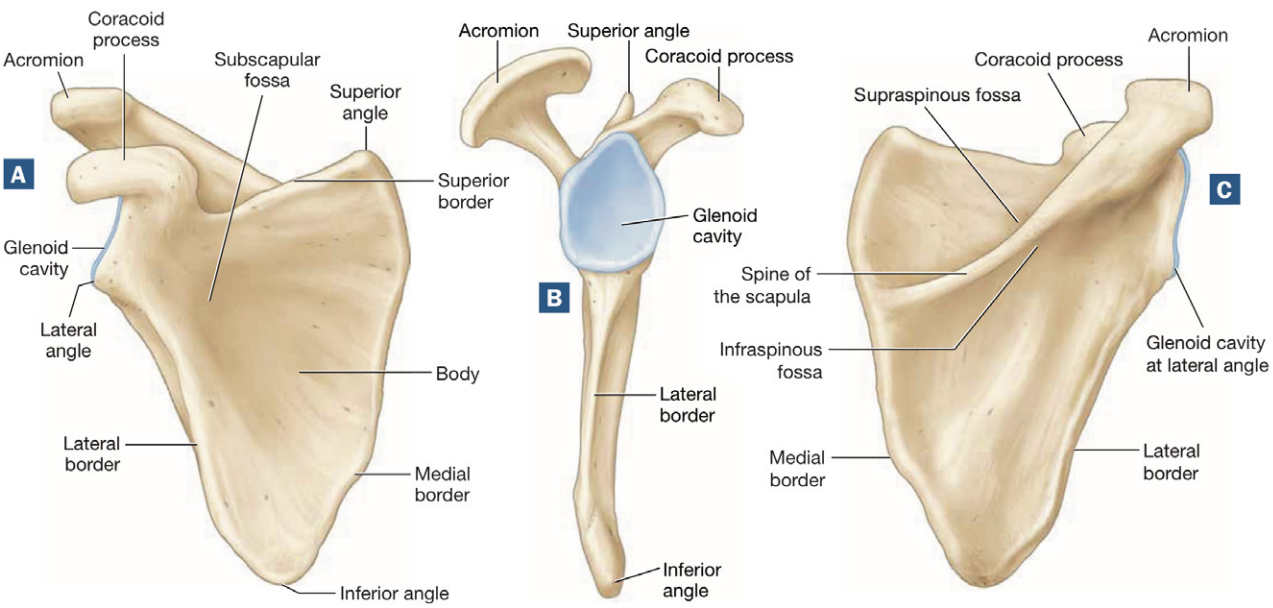

FIGURE **8.20** Right scapula: (**A**) anterior view; (**B**) lateral view; (**C**) posterior view.

lateral acromial end and the manubrium of the sternum at its medial **sternal end**. Note its S-shape is best appreciated from the superior view shown in Figure 8.21, as the clavicle appears nearly straight from an anterior view. Functionally, the clavicle acts somewhat like a brace, holding the upper limb in place away from the body.

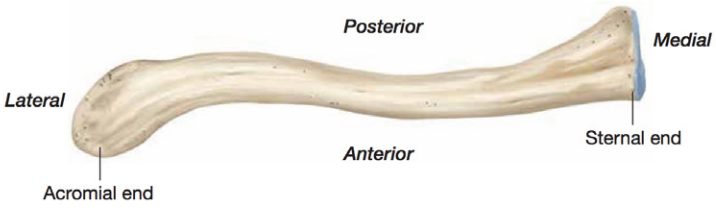

FIGURE **8.21** Clavicle, superior view.

Upper Limb

The **upper limb** consists of the arm, the forearm, the wrist, and the hand. The only bone within the arm is the **humerus** (HYOO-mur-us), a long bone that forms the shoulder joint with the scapula at its proximal end and the elbow joint with the ulna and radius at its distal end. The humerus has a number of features, including the following (Fig. 8.22):

- At its proximal end is a rounded **head** that fits into the glenoid cavity. Just lateral to the head is the **greater tubercle**, separated from the smaller **lesser tubercle** by the **intertubercular sulcus** (in-ter-too-BUR-kyoo-lur SUL-kuss).
- The diaphysis of the humerus features a projection called the **deltoid tuberosity**, where the deltoid muscle attaches. On the posterior diaphysis we find another feature—the **radial groove**—which is an indentation along which the radial nerve travels.
- At the humerus' distal end we find two small projections called the **medial** and **lateral epicondyles**. Distal to these are two larger condyles—the medial **trochlea** (TROH-klee-uh), which is shaped like a spool of thread, and the lateral **capitulum** (kah-PIT-yoo-lum), which is ball-shaped. Just proximal to the trochlea are indentations in the humerus where the ulna and radius articulate—the anterior **coronoid and radial fossae** and the posterior **olecranon fossa** (oh-LEK-rah-nahn).

The two forearm bones, shown in Figures 8.23, are the lateral **radius** (RAY-dee-us) and medial **ulna** (if you have a hard time remembering which is which, stand in anatomical position and take your radial pulse; the pulse is on the lateral side

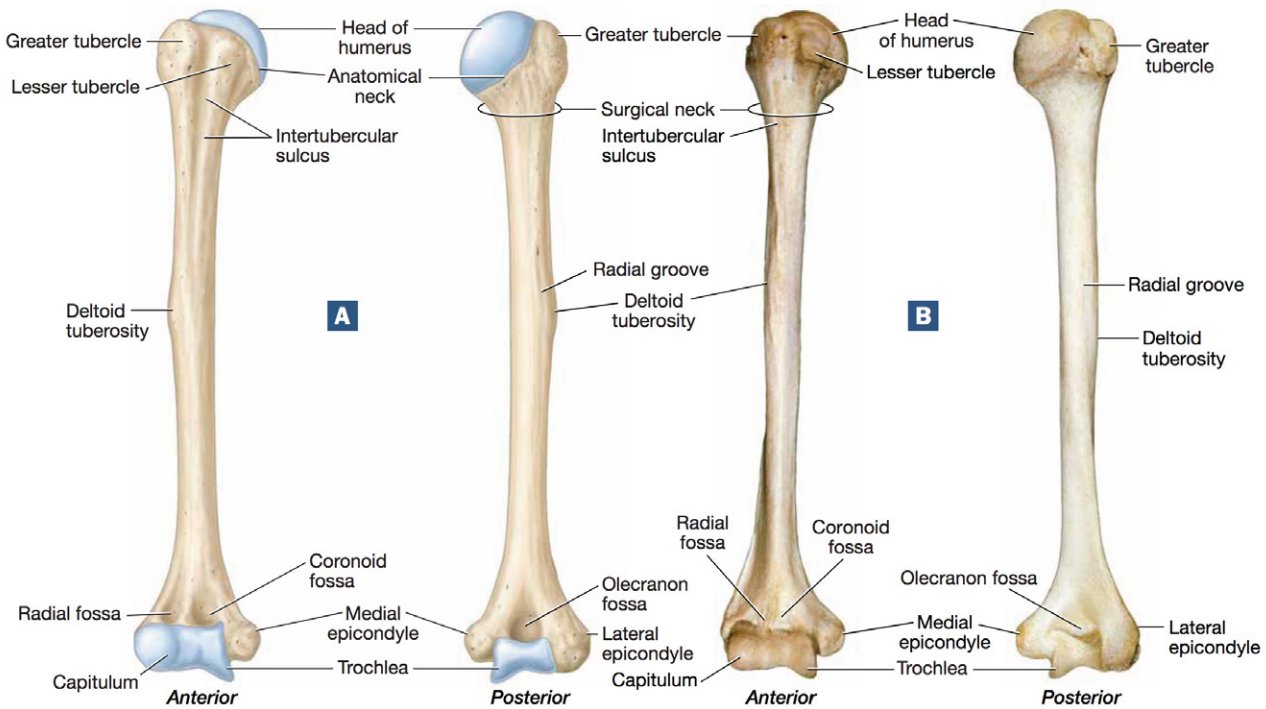

FIGURE **8.22** Right humerus: (**A**) illustration; (**B**) photograph.

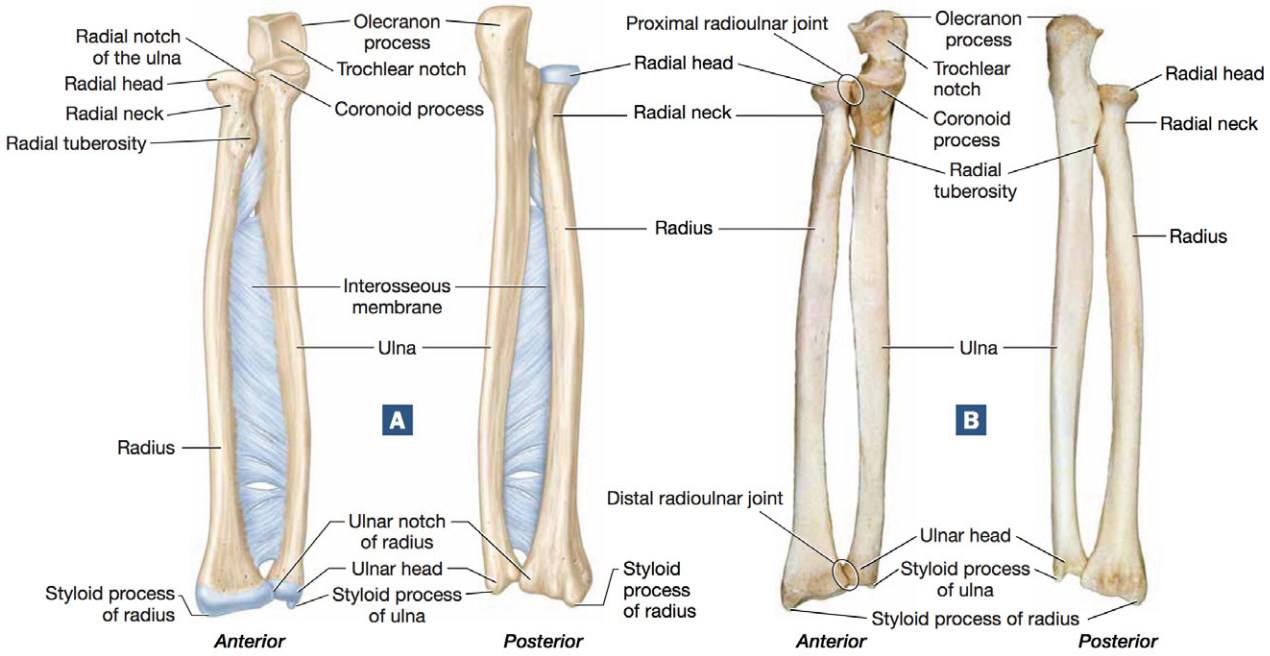

FIGURE **8.23** Right radius and ulna: (**A**) illustration; (**B**) photograph.

of the forearm, just like the radius). The ulna is wide proximally where it articulates with the humerus and thin distally where it articulates with the bones of the wrist. Its proximal end has two processes—the large, posterior **olecranon process** and the smaller, anterior **coronoid process**—separated by a deep curve called the **trochlear notch**.

As its name implies, the trochlear notch fits around the trochlea of the humerus to form the elbow joint. The olecranon process is the actual "elbow bone," which you can feel on your posterior arm. The trochlear notch and the ulna's two processes form a "U" shape when the ulna is held on its side. This makes the ulna easy to differentiate from the radius (think "U" for "ulna").

The distal end of the ulna is known as the **ulnar head.** It articulates with one of the wrist (or *carpal*) bones known as the *lunate*. On its medial side, it has a small projection called the **styloid process** that is palpable through the skin.

The radius' shape is opposite to that of the ulna: It is skinny proximally and wide distally. Proximally it consists of a round, flattened **radial head** that articulates with the capitulum of the humerus to help form the elbow joint. Distal to the radial head we find the **radial neck** and a projection called the **radial tuberosity**. At its most distal end, the radius articulates with several carpal bones. It also features a lateral **styloid process**, just as we found on the ulna.

Notice in Figure 8.23 that the radius and ulna also articulate with one another. On the ulna, just distal to the coronoid process, we find the **radial notch**, which is where the radius and ulna articulate at the **proximal radioulnar joint**. At the distal end of the radius is an indentation called the **ulnar notch** where the ulna fits into the radius. This joint is known as at the **distal radioulnar joint.** These joints are stabilized by a band of dense regular collagenous connective tissue that joins the radius and ulna along their length known as the *interosseous membrane*.

The wrist is composed of eight short bones called **carpals**, which are arranged into two rows. The proximal row, from medial to lateral, consists of the *triquetrum*, *pisiform*, *lunate*, and *scaphoid* bones. The distal row, from medial to lateral, includes the *hamate*, *capitate*, *trapezoid*, and *trapezium* bones (Fig. 8.24; remember that the thumb is lateral because we are in anatomical position). The carpals articulate proximally with the radius and the ulna, and distally with the five long bones in the hand called the **metacarpals**. The metacarpals articulate distally with the fingers, which are formed from 14 long bones called **phalanges** (fuh-LAN-jeez). The second through fifth digits have three phalanges each (the *proximal*, *intermediate* [or *middle*], and *distal phalanges*); the thumb has only two (a *proximal* and a *distal phalanx*).

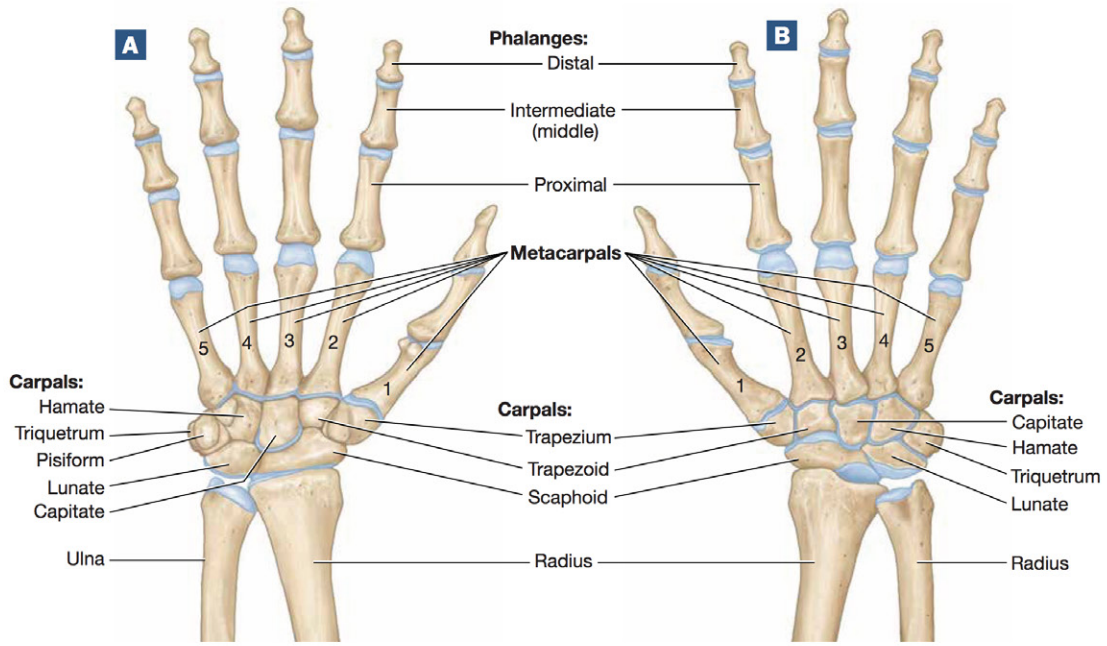

FIGURE **8.24** Right wrist and hand: (**A**) anterior view; (**B**) posterior view.

Pelvic Girdle

The **pelvis** connects the lower limbs to the trunk, supports the pelvic organs, and transmits the weight of the trunk to the legs. It is formed by the sacrum and the **pelvic girdle**, which itself is composed of two **coxal bones** (Fig. 8.25). The coxal bones meet the sacrum at the two **sacroiliac joints** (say-kroh-ILL-ee-ak). The opening into the pelvis is known as the **pelvic inlet**; the ridge around the inlet is the **pelvic brim**. The pelvic inlet and brim separate what is known as the **greater pelvis**, which sits superior to the pelvic inlet, from the **lesser pelvis**, which sits inferior to it. As you can see in Figure 8.25B, we find the **pelvic outlet** at the inferior edge of the lesser pelvis.

Each coxal bone is also known as a **hemipelvis**. Three fused bones—the ilium, the ischium, and the pubis—make up each coxal bone (Fig. 8.26). You can see in the lateral view the place where all three bones come together to form a deep

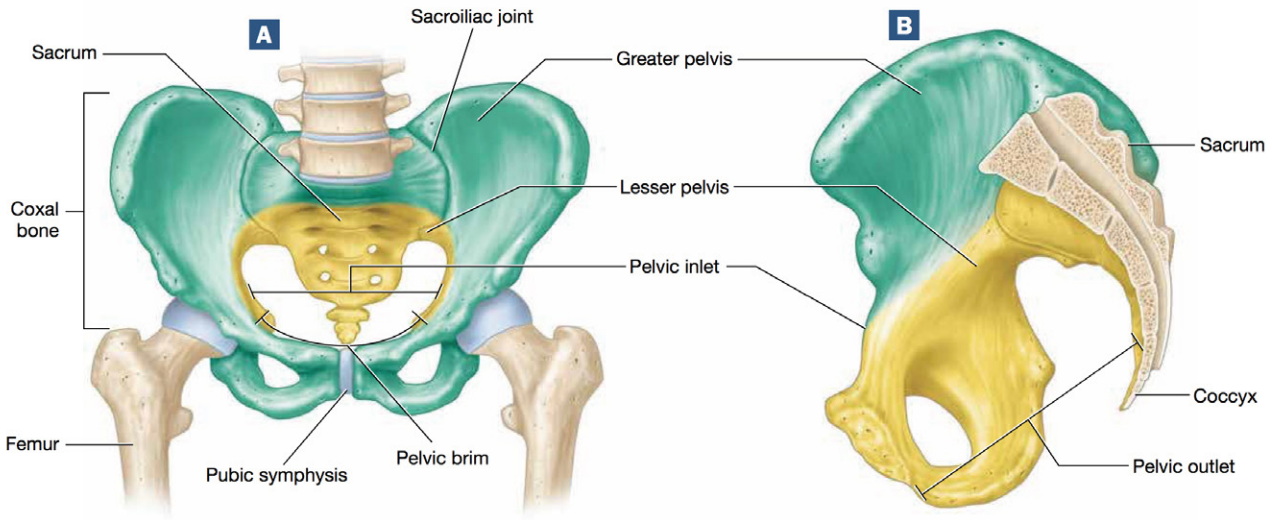

FIGURE **8.25** Pelvis: (**A**) anterior view; (**B**) midsagittal section.

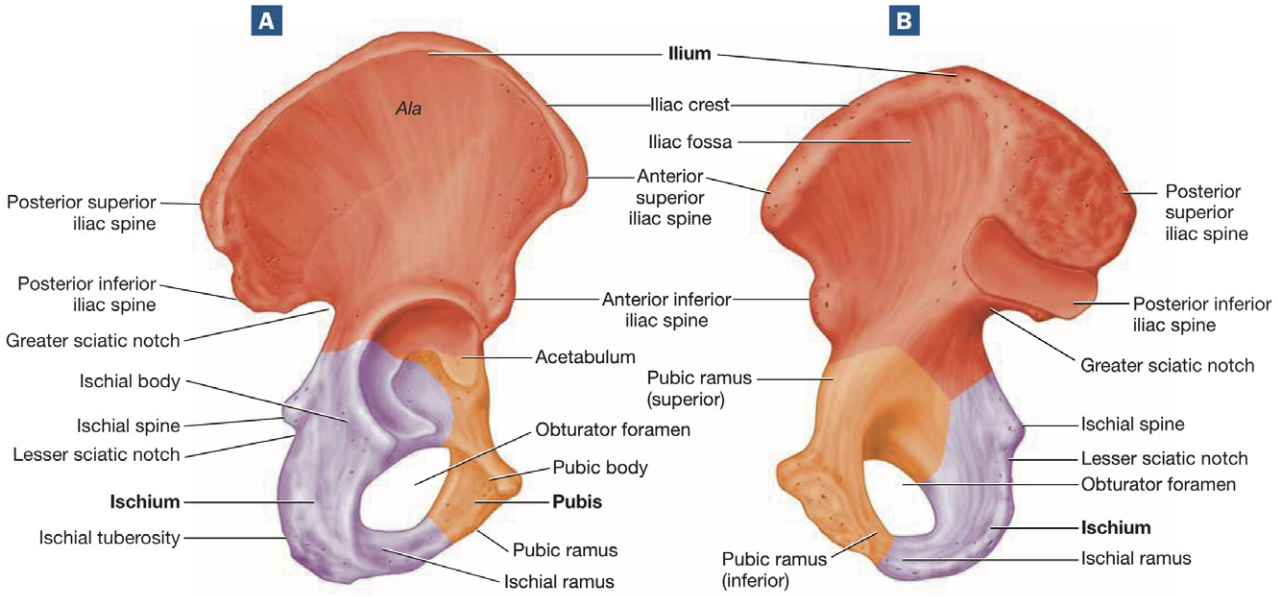

FIGURE **8.26** Hemipelvis: (**A**) right coxal bone, lateral view; (**B**) right coxal bone, medial view.

socket. This socket, called the **acetabulum** (aeh-seh-TAB-yoo-lum), forms the hip joint with the femur. Notice also that where the ischium and pubis meet there is a large hole called the **obturator foramen** (AHB-too-ray-tur). In a living person this hole is covered with a membrane and allows only small blood vessels and nerves to pass through.

Let's look more closely at the three bones of the pelvic girdle and their features.

1. **Ilium.** The **ilium** (ILL-ee-um) is the largest of the three bones. Its main portion is called the **body,** and its superior "wing" is called the **ala** (AY-luh). The medial side of the ala is concave; this indentation is called the **iliac fossa.** The ridge of the ala, called the **iliac crest,** is where you rest your hands when your hands are on your hips. At the anterior end of the crest we find a projection called the **anterior superior iliac spine,** and inferior to it the smaller **anterior inferior iliac spine.** A similar but smaller **posterior superior iliac spine** is located posteriorly, with a corresponding **posterior inferior iliac spine.** The posterior ilium also features a notch called the **greater sciatic notch** (sy-AEH-tik), which allows the greater sciatic nerve to pass from the pelvis to the thigh.
2. **Ischium.** The **ischium** (ISS-kee-um) makes up the posteroinferior pelvis. It contains three features on its posterior side: the superior **ischial spine,** the middle **lesser sciatic notch,** and the thick, inferior **ischial tuberosity.** The ischial tuberosities are the "butt bones": the bones that bear your weight when you sit down. On the ischium's anterior side we find the **ischial ramus,** which articulates with the pubis.

HINTS & TIPS

How to Determine Sex Based upon Pelvic Features

A skeleton's sex can be determined based upon the differences between the male and female pelvises. In general, the male and female pelvis can be distinguished by the features listed below, shown in Figure 8.27:

Feature	Female Pelvis	Male Pelvis
Pelvic inlet shape	Wider and oval-shaped	Narrower and heart-shaped
Pubic arch	Wide angle	Narrow angle
Acetabulae	Farther apart	Closer together
Ischial tuberosities	Everted	Inverted
Coccyx	Straighter, more movable	Curved anteriorly, less movable

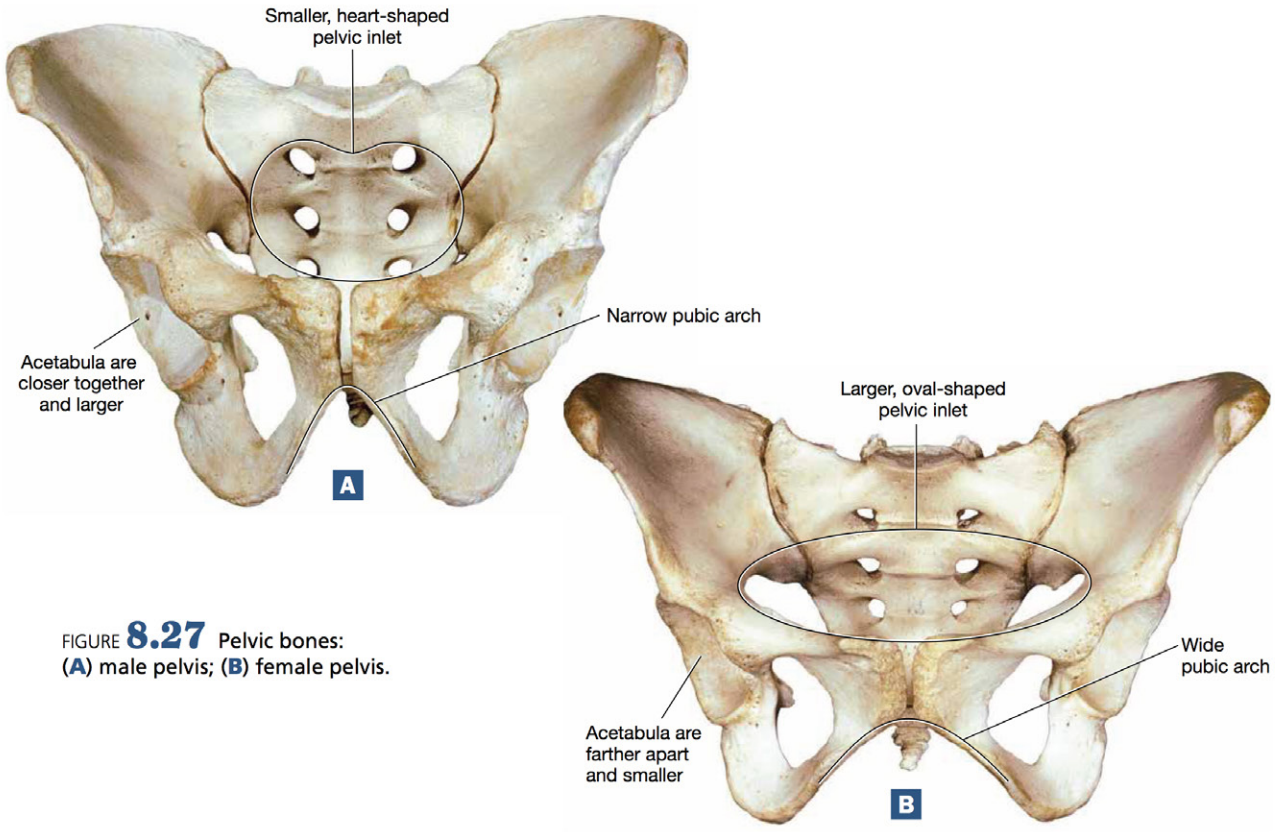

FIGURE **8.27** Pelvic bones: (**A**) male pelvis; (**B**) female pelvis.

3. **Pubis.** The pelvis' anterior portion is formed by the **pubis** (PYOO-bis) or the **pubic bone.** The pubis consists of a **body** and two extensions called the **superior** and **inferior rami.** The bodies of the two pubic bones meet at a fibrocartilage pad called the **pubic symphysis** (SIM-fih-sis; see Fig. 8.25). The angle that these bones form when they meet, called the **pubic arch,** can help to determine the sex of a skeleton (see the "Hints and Tips" box).

Lower Limb

The lower limb consists of the thigh, the **patella** (kneecap), the leg, the ankle, and the foot. The thigh contains only a single bone, the large, heavy **femur** (Fig. 8.28). Proximally, the femur articulates with the acetabulum at its rounded **head.** In the center of the femoral head we find a pit called the **fovea capitis** (FOH-vee-uh CAP-ih-tiss). This is the point of attachment for a ligament that holds the femur in the acetabulum. Just distal to the femoral head is the **neck** of the femur, the weakest part of the femur and the most common location for it to fracture (when the femoral neck fractures, it is usually called a "broken hip," even though the hip itself doesn't fracture). Where the femoral neck meets the femoral shaft, we find two large prominences—the anterolateral **greater trochanter** (TROH-kan-tur) and the posteromedial **lesser trochanter.** Between the two trochanters on the anterior side is a ridge called the **intertrochanteric line** (in-ter-troh-kan-TEHR-ik), and on the posterior side is another ridge in the same location known as the **intertrochanteric crest.**

The femoral diaphysis is mostly smooth, save for a few features that mark the attachment points for specific muscles on the posterior side:

- The proximal **gluteal tuberosity** is a rough projection that serves as the attachment spot for one of the gluteal muscles (the gluteus maximus muscle).
- The **linea aspera** (LIN-ee-ah ASS-per-ah) is a prominent line that runs along the femoral diaphysis. It serves as an attachment point for many muscles that move the femur.
- Near the femoral epiphysis, the linea aspera splits into the **medial** and **lateral supracondylar lines** (soo-prah-KAHN-dah-lar), where hamstring muscles attach to the femur.

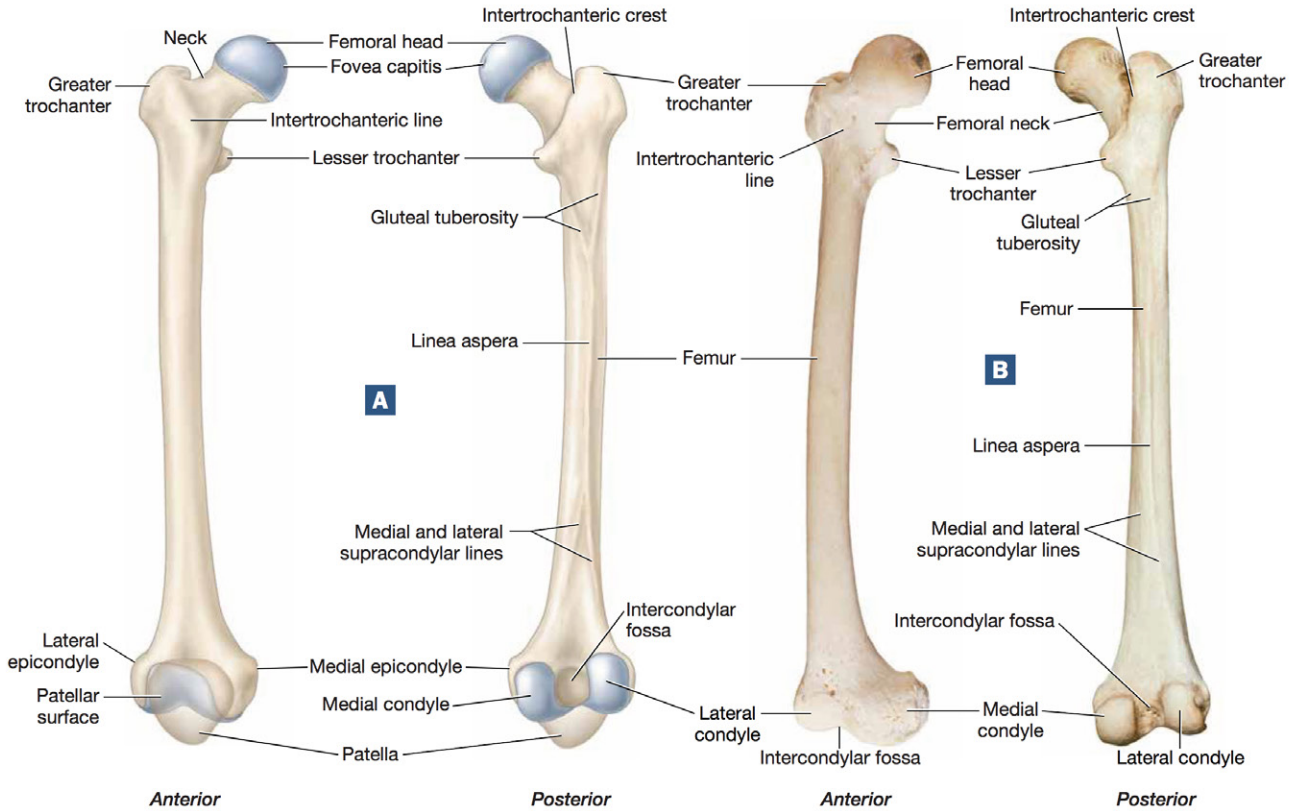

FIGURE **8.28** Right femur: (**A**) illustration; (**B**) photograph.

Distally, the femur expands into two small projections, the **medial** and **lateral epicondyles** (ep-ih-KAHN-dyl′z), distal to which we find the large **medial** and **lateral condyles,** which form the knee joint with the largest bone of the leg, the tibia. On the posterior side of the femur is a depression between the two condyles, the **intercondylar fossa.**

The **tibia** (TIB-ee-ah) is the medial and larger of the two leg bones (Fig. 8.27). It is flattened proximally at its articular surface, the *tibial plateau*, where its **medial** and **lateral condyles** fit together with those of the femur. Between the medial and lateral condyles is a ridge called the *intercondylar eminence*. Just distal to the condyles on the tibia's anterior surface is a rough projection called the **tibial tuberosity,** which is where the patellar ligament inserts. Along the anterior tibial diaphysis is a sharpened ridge known as the **anterior crest,** which is commonly known as the "shin." At the tibia's distal epiphysis, it articulates with a tarsal bone called the **talus** (TAY-luss), with which it forms the ankle joint. At its terminal end is a projection called the **medial malleolus** (mal-ee-OH-lus), which you may think of as your "medial ankle bone."

The other leg bone is the thin, lateral **fibula** (FIB-yoo-lah). The proximal fibular end is called the **head,** and its distal end is the **lateral malleolus** (which you may think of as your "lateral ankle bone"). The head has no articulation with the femur, but the lateral malleolus articulates with the talus to help form the ankle joint.

If you notice in Figure 8.29, the tibia and fibula articulate with one another just as the radius and ulna do. At the proximal end we find the **proximal tibiofibular joint,** and at the distal end we find the **distal tibiofibular joint.** The two bones are also held together by a stabilizing interosseous membrane.

The ankle is composed of seven short bones called **tarsals** (Fig. 8.30). The largest tarsal bone is the **calcaneus** (kal-KAYN-ee-us), or the heel bone. Resting on top of the calcaneus is the **talus,** which forms the ankle joint with the tibia and fibula. Distally, the talus articulates with a ship-shaped bone called the *navicular*. The remaining tarsals are, from medial to lateral, the *medial cuneiform*, *intermediate cuneiform*, *lateral cuneiform*, and *cuboid* bones. The tarsals articulate distally with the five long bones in the foot called **metatarsals.** Notice in Figure 8.30B that there are two small *sesamoid bones* at the head of the first metatarsal—these bones are found in a tendon located here. Like the bones of the fingers, the bones of the toes also consist of 14 **phalanges.** The second through fifth digits have three phalanges each (the *proximal*, *intermediate* [or *middle*], and *distal phalanges*); and the big toe or *hallux* has only two (a *proximal* and a *distal phalanx*).

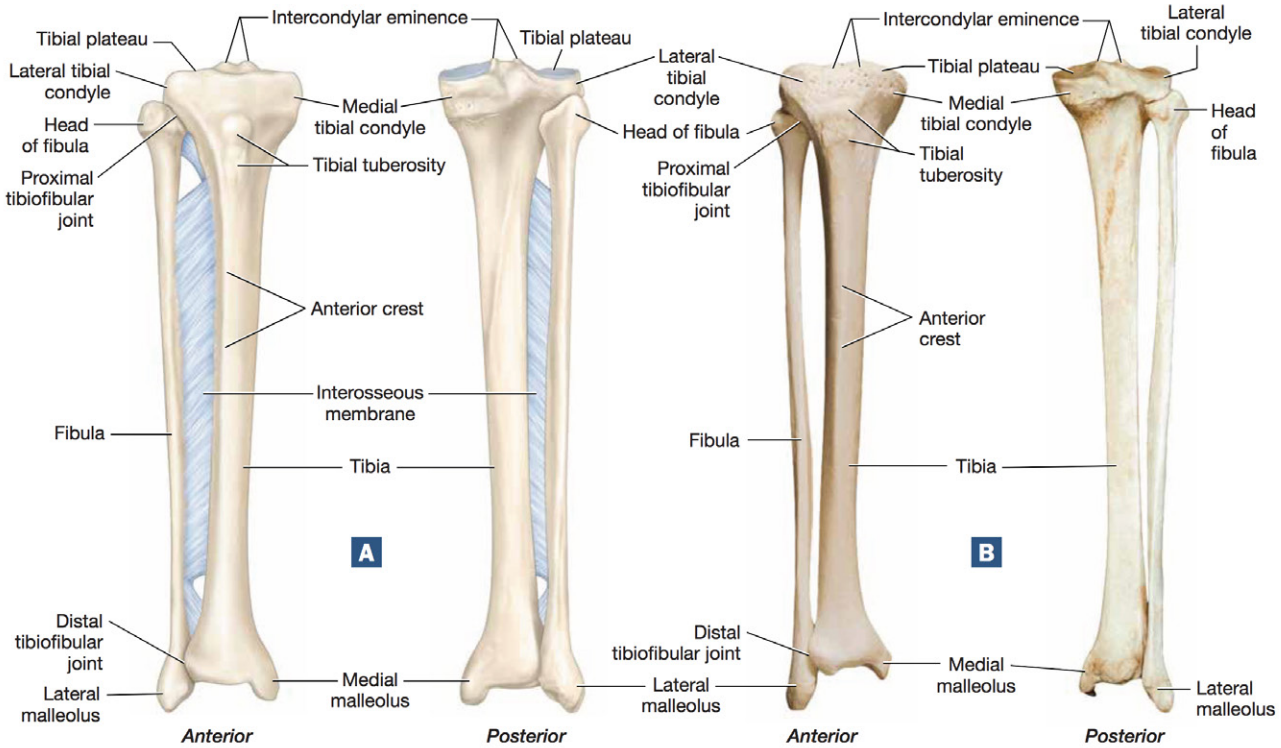

FIGURE **8.29** Right tibia and fibula: (**A**) illustration; (**B**) photograph.

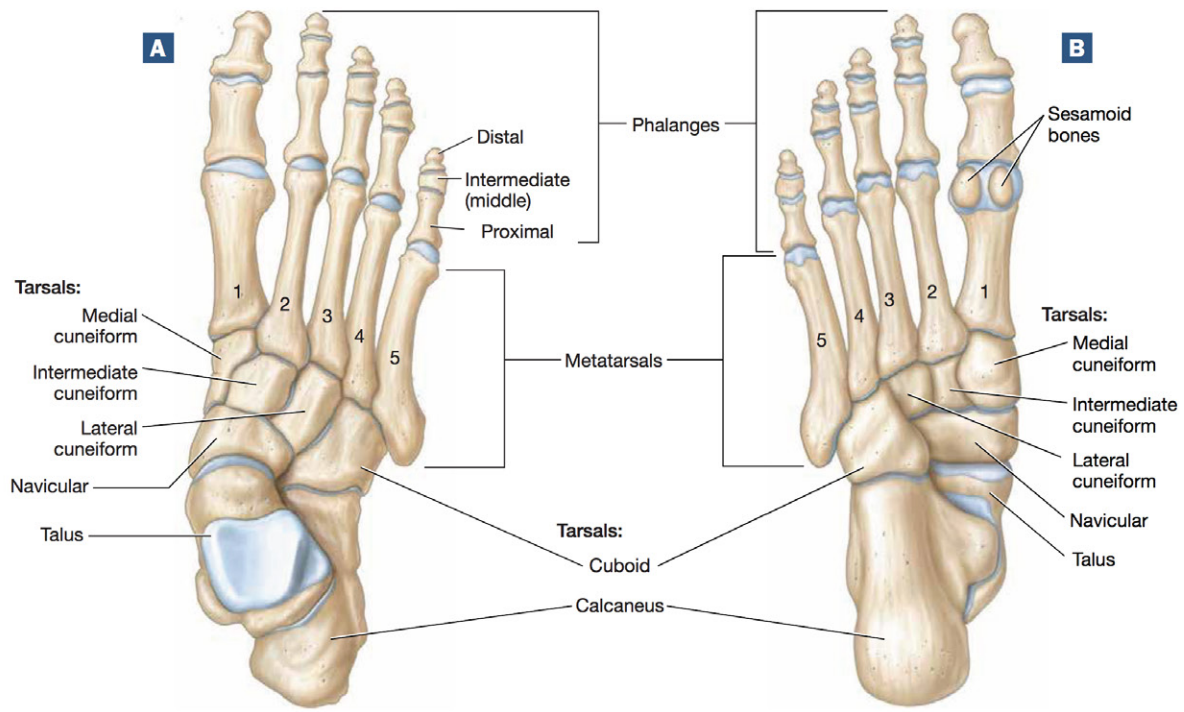

FIGURE **8.30** Right foot and ankle: (**A**) superior view; (**B**) inferior view.

Procedure 1 Cooperative Learning for the Axial and Appendicular Skeletons

We will follow essentially the same procedure here as we did in Exercise 8-1, but with different groups of bones and bone markings. Note that this cooperative learning exercise includes the structures from Exercises 8-2 and 8-3. When you have completed this activity, answer Check Your Understanding questions 4 through 6 (p. 224).

1. Assemble into teams with a minimum of four students; five is optimum.
2. Distribute a bone or set of bones to each member of the team, and assign each student one of the following five groups of bones and bone markings (the specific structures of each bone are listed on pp. 204 through 206):

   Group A: Cervical, thoracic, and lumbar vertebrae and vertebral markings; ribs and rib markings; sternum structures and the hyoid bone.

   Group B: Scapula structures, clavicle structures, humerus structures.

   Group C: Radius and ulna markings, carpals, metacarpals, and phalanges.

   Group D: Ilium, ischium, and pubis structures, and the difference between the male and female pelvises.

   Group E: Femur, tibia, fibula structures, tarsals, metatarsals, phalanges.
3. Spend approximately 3 minutes learning the assigned structures on your own.
4. Then have each team member spend approximately 1 to 2 minutes teaching the team his or her assigned structures.
5. Rotate the assigned structures clockwise so each member has a new set of structures to learn (the student that was assigned group A will take group B, and so on).
6. Spend approximately 2 to 3 minutes learning your newly assigned structures.
7. Have each team member spend approximately 1 to 2 minutes teaching the group his or her assigned structures.
8. Repeat this process (it begins to speed up significantly at this point) until each team member has taught each group of structures once.

The following is a list of bone and bone markings of the axial and appendicular skeletons covered in this exercise.

Remaining Structures of the Axial Skeleton

Group A Structures

1. Vertebral column
   - a. Intervertebral foramina
   - b. Cervical curvature
   - c. Lumbar curvature
   - d. Thoracic curvature
   - e. Sacral curvature
2. Vertebrae
   - a. Spinous process
   - b. Transverse processes
   - c. Vertebral foramen
   - d. Vertebral body
   - e. Intervertebral disc
   - f. Pedicle
   - g. Lamina
3. Cervical vertebrae
   - a. Transverse foramina
   - b. Atlas
   - c. Axis
   - d. Dens
4. Thoracic vertebrae
   - a. Costal (articular) facets
5. Lumbar vertebrae
6. Sacrum
   - a. Sacral promontory
   - b. Sacral canal
   - c. Anterior sacral foramina
   - d. Posterior sacral foramina
7. Coccyx
8. Sternum
   - a. Manubrium
   - b. Body
   - c. Xiphoid process
9. Ribs
   - a. Intercostal spaces
   - b. Costal cartilage
   - c. True (vertebrosternal) ribs
   - d. False ribs
     - (1) Vertebrochondral ribs
     - (2) Floating ribs (vertebral ribs)
   - e. Costal margin
   - f. Head of rib
   - g. Neck of rib
   - h. Shaft of rib
10. Hyoid bone

Pectoral Girdle and Upper Limb

Group B Structures

1. Scapula
   a. Superior, lateral, and medial borders
   b. Superior, lateral, and inferior angles
   c. Subscapular fossa
   d. Glenoid cavity
   e. Coracoid process
   f. Acromion
   g. Spine
   h. Supraspinous fossa
   i. Infraspinous fossa
2. Clavicle
3. Humerus
   a. Head
   b. Greater tubercle
   c. Lesser tubercle
   d. Intertubercular sulcus
   e. Deltoid tuberosity
   f. Trochlea
   g. Capitulum
   h. Coronoid fossa
   i. Radial fossa
   j. Olecranon fossa

Group C Structures

1. Ulna
   a. Olecranon process
   b. Coronoid process
   c. Trochlear notch
   d. Ulnar head
   e. Styloid process
2. Radius
   a. Radial head
   b. Radial neck
   c. Radial tuberosity
   d. Styloid process
3. Carpals
   a. Triquetrum
   b. Pisiform
   c. Lunate
   d. Scaphoid
   e. Trapezium
   f. Trapezoid
   g. Capitate
   h. Hamate
4. Metacarpals
5. Phalanges

Pelvic Girdle and Lower Limb

Group D Structures

1. Pelvis
   a. Sacroiliac joints
   b. Pelvic inlet
   c. Pelvic brim
   d. Greater pelvis
   e. Lesser pelvis
   f. Pelvic outlet
2. Coxal bone (hemipelvis)
3. Acetabulum
4. Obturator foramen
5. Ilium
   a. Ala
   b. Iliac crest
   c. Anterior superior iliac spine
   d. Anterior inferior iliac spine
   e. Posterior superior iliac spine
   f. Greater sciatic notch
6. Ischium
   a. Ischial spine
   b. Lesser sciatic notch
   c. Ischial tuberosity
7. Pubis
   a. Body
   b. Superior and inferior rami
   c. Pubic symphysis
   d. Pubic arch
8. Male and female pelvises

Group E Structures

1. Femur
   a. Head
   b. Fovea capitis
   c. Neck
   d. Greater trochanter
   e. Lesser trochanter
   f. Intertrochanteric line and crest
   g. Gluteal tuberosity
   h. Linea aspera
   i. Medial and lateral condyles
   j. Intercondylar fossa
2. Patella
3. Tibia
   a. Tibial tuberosity
   b. Anterior crest
   c. Medial malleolus
4. Fibula
   a. Head
   b. Lateral malleolus
5. Tarsals
   a. Calcaneus
   b. Talus
   c. Navicular
   d. Cuneiforms
   e. Cuboid
6. Metatarsals
7. Phalanges

Your instructor may wish to omit certain structures included above or add structures not included in these lists. List any additional structures below:

Exercise 8-4

More Practice

MATERIALS

- ❑ Disarticulated bones in a box
- ❑ Skeleton, articulated
- ❑ Colored pencils

On average, the human body contains 206 bones and thousands of bone markings, processes, fossae, and foraminae. The previous cooperative learning exercises gave you a solid foundation on which to build your knowledge of the skeleton—but a good foundation is just a start. A lot more practice is needed to actually build a house on that foundation. This exercise contains activities to help you build that "house" and practice what you learned in Exercises 8-1 through 8-3.

Procedure 1 Building a Skeleton

1. Obtain a set of disarticulated bones (real bones are best).
2. Assemble the bones into a full skeleton. (If you have an articulated vertebral column and rib cage, go ahead and use them.)
3. Be certain to keep your skeleton in anatomical position. Figure 8.31 gives an overall "big picture" view of the skeleton that you may use for reference.
4. Assemble the bones into a full skeleton.

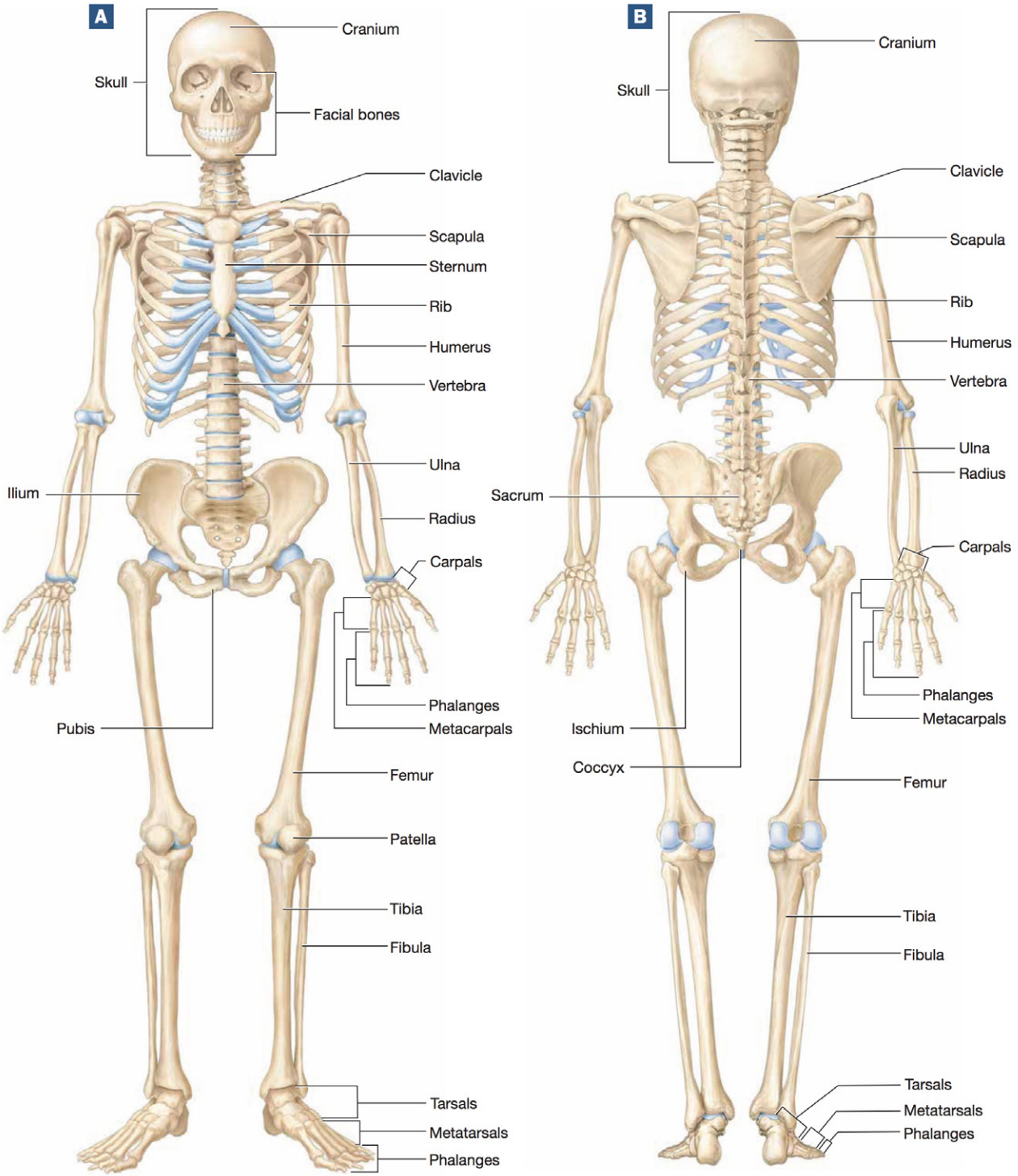

FIGURE **8.31** Articulated skeleton: (**A**) anterior view; (**B**) posterior view.

Procedure 2 Identifying Bones Blindly

1. Place your set of disarticulated bones in a box.
2. Working with your lab partner, close your eyes, reach into the box, grab a bone randomly, and attempt to identify it only by its feel.
3. If you are unable to identify the bone, have your lab partner give you hints to help you work out the bone's identity.

Procedure 3 Comparing Bones on the Right and Left Sides

Examine the following bones, and figure out how you can determine if the bones are from the left or the right side of the body.

Femur

Tibia

Humerus

Scapula

Procedure 4 Time to Draw

Remember from your previous drawing exercises that drawing even the crudest picture of an anatomical structure or physiological pathway engages multiple parts of the brain and greatly enhances memory. So, with that in mind: (1) Draw a skull and a skeleton in the spaces provided; and (2) label and color your drawings.

These drawings are not meant to be works of art, so don't worry if you aren't even remotely skilled as an artist (however, if they turn out well, feel free to take them out of your lab book and put them on your refrigerator).

1 Skull: anterior view

2 Skull: lateral view

3 Skeleton: anterior view

8

Name _____

Section _____ Date _____

UNIT 8 REVIEW

Check Your Recall

1 Label the following bones in Figure 8.32.

- ❑ Clavicle
- ❑ Femur
- ❑ Fibula
- ❑ Humerus
- ❑ Ilium
- ❑ Metacarpals
- ❑ Pubis
- ❑ Radius
- ❑ Sternum
- ❑ Tarsals
- ❑ Tibia
- ❑ Ulna

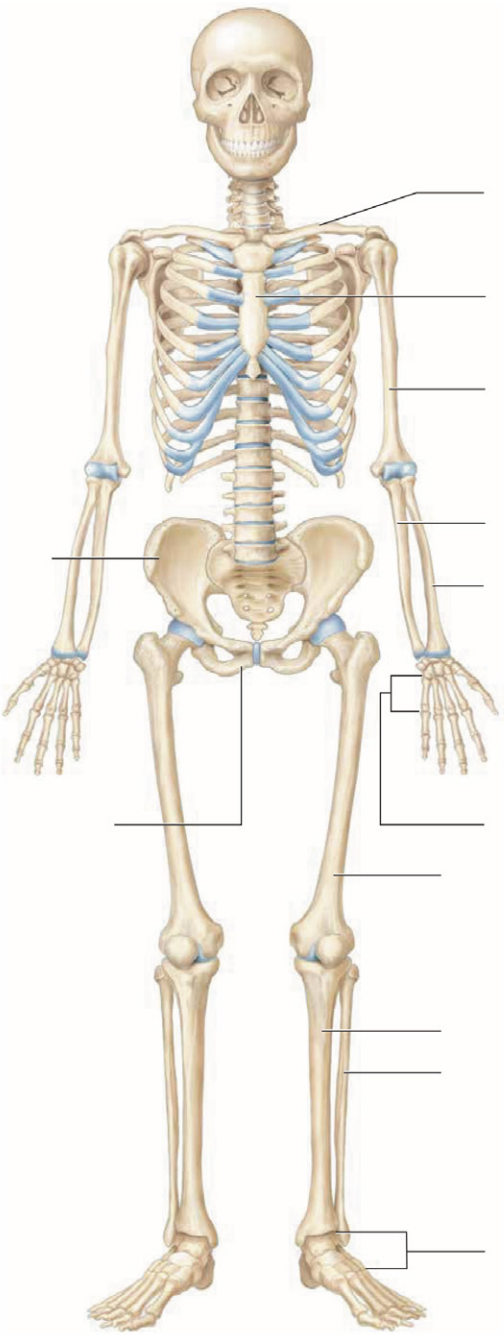

FIGURE **8.32** Anterior view of the skeleton.

2 Label the following bones of the skull in Figure 8.33.

- ❑ Ethmoid bone
- ❑ Frontal bone
- ❑ Inferior nasal concha
- ❑ Lacrimal bone
- ❑ Mandible
- ❑ Maxilla
- ❑ Nasal bones
- ❑ Occipital bone
- ❑ Palatine bone
- ❑ Parietal bone
- ❑ Sphenoid bone
- ❑ Temporal bone
- ❑ Vomer
- ❑ Zygomatic bone

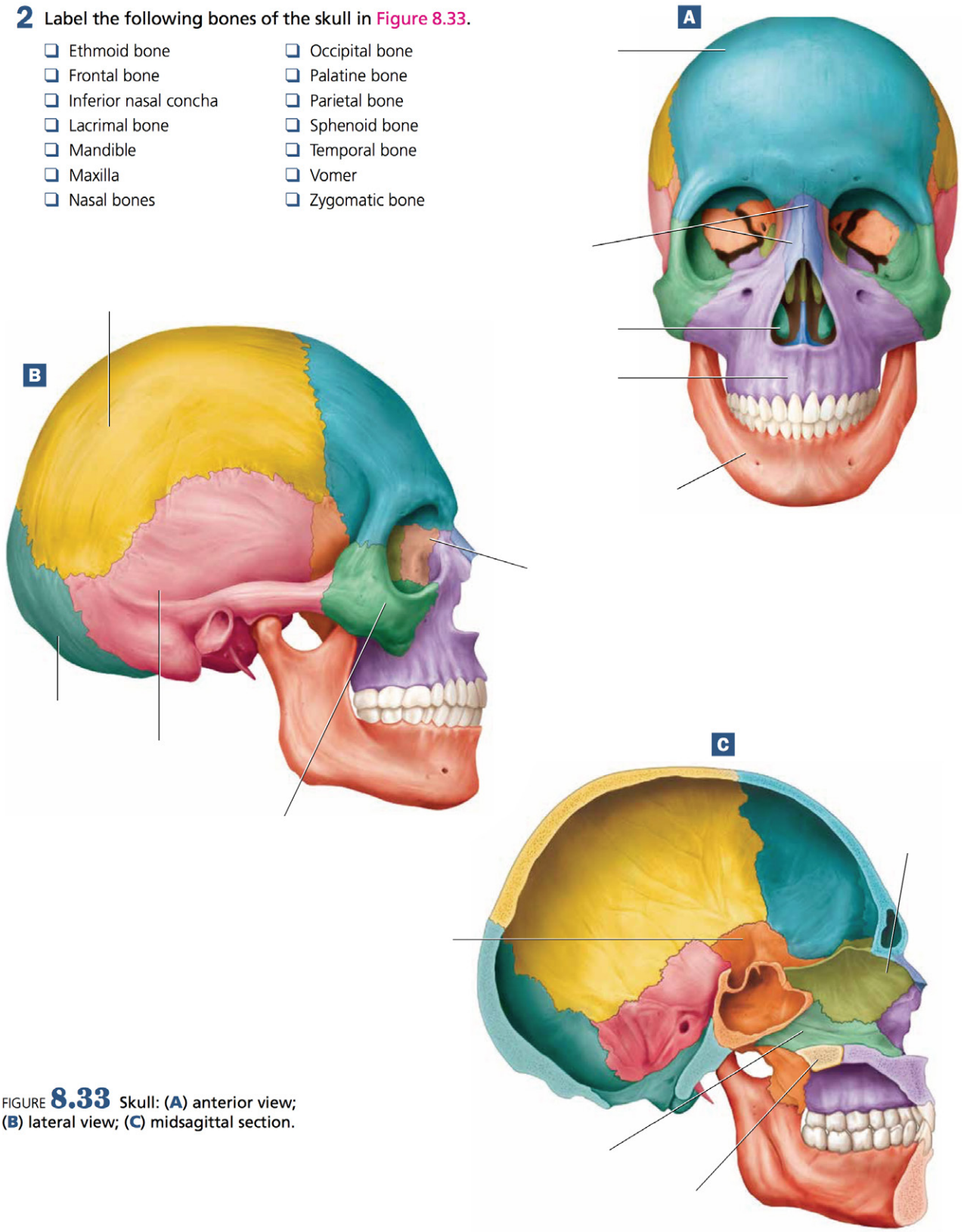

FIGURE **8.33** Skull: (**A**) anterior view; (**B**) lateral view; (**C**) midsagittal section.

Name _____

Section _____ Date _____

3 Label the following skull markings and processes in Figure 8.34.

- ❑ Coronoid process
- ❑ Cribriform plate
- ❑ Jugular foramen
- ❑ Optic canal
- ❑ Mastoid process
- ❑ Palatine process of maxilla
- ❑ Perpendicular plate of ethmoid bone
- ❑ Pterygoid process
- ❑ Sella turcica
- ❑ Sphenoid sinus
- ❑ Styloid process

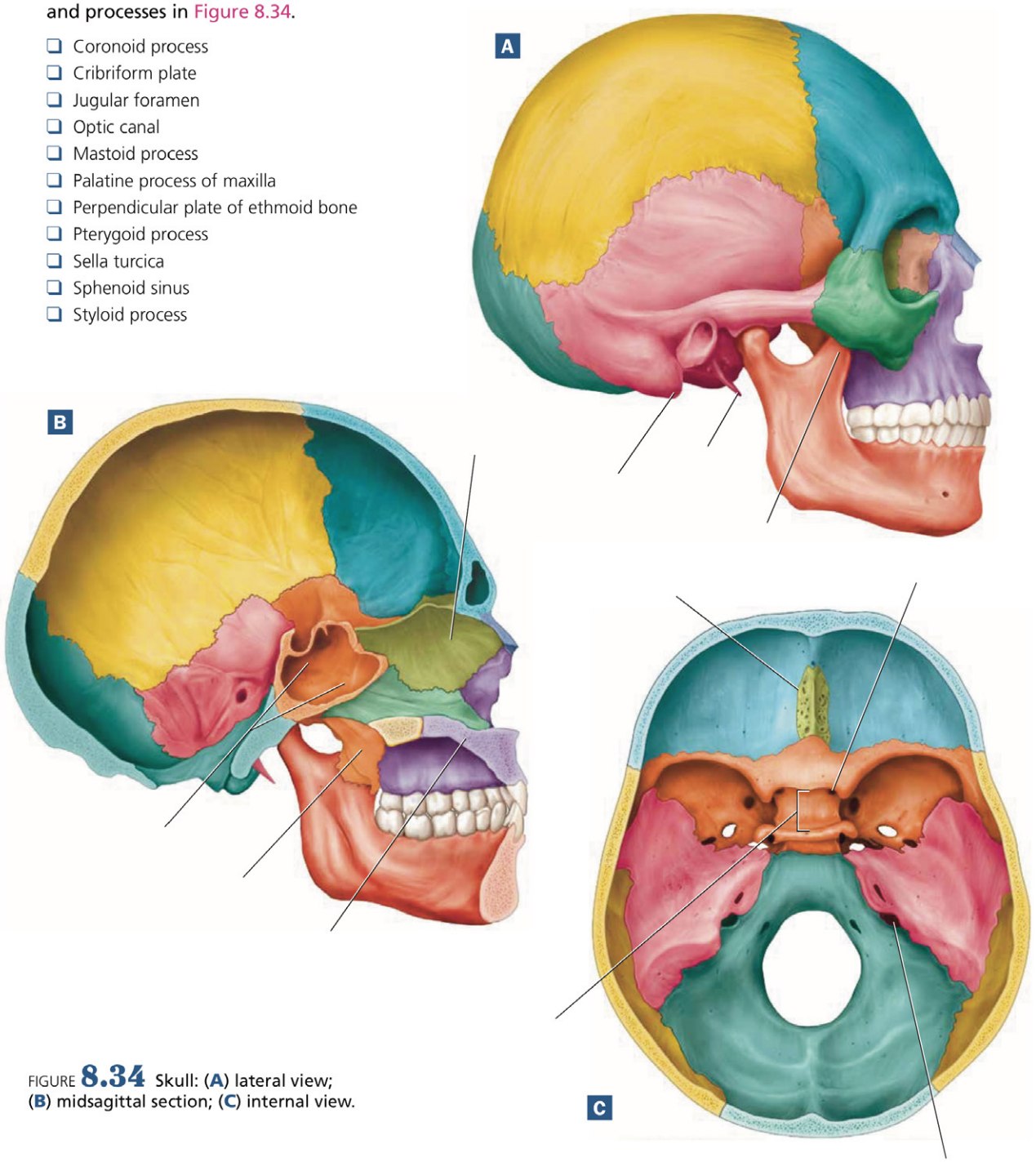

FIGURE **8.34** Skull: (**A**) lateral view; (**B**) midsagittal section; (**C**) internal view.

4 Label the following parts of the vertebral column in Figure 8.35.

- ❑ Atlas
- ❑ Thoracic vertebrae
- ❑ Cervical curvature
- ❑ Lumbar vertebrae
- ❑ Cervical vertebrae
- ❑ Lumbar curvature
- ❑ Sacral curvature
- ❑ Axis
- ❑ Sacrum
- ❑ Thoracic curvature
- ❑ Coccyx

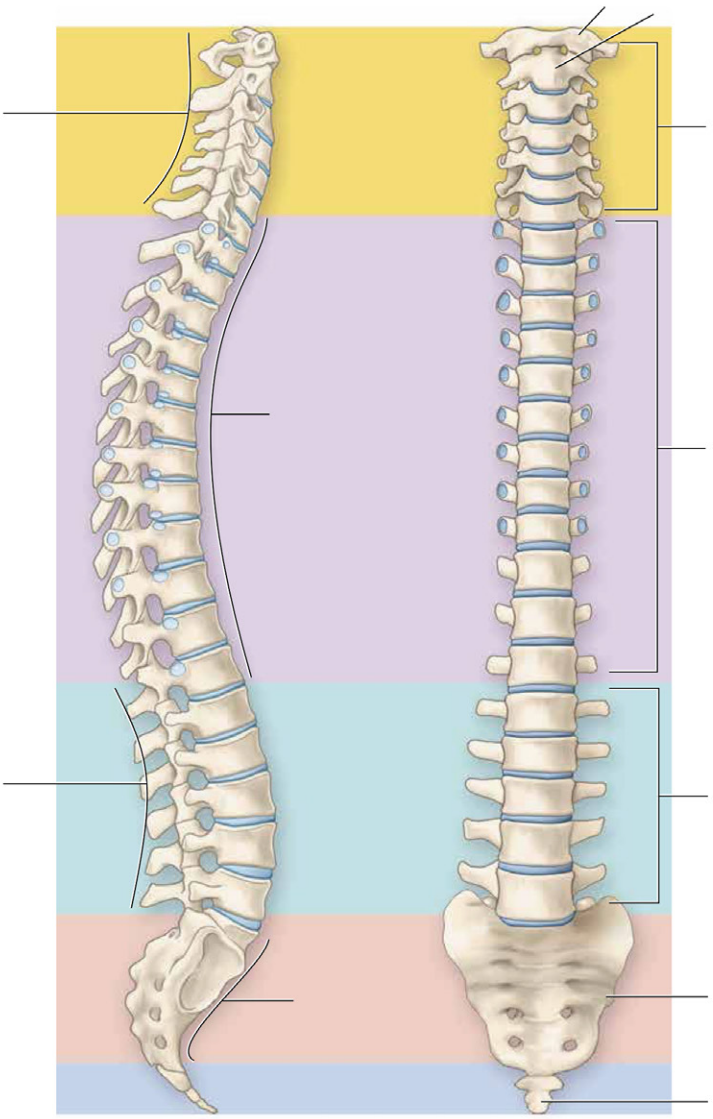

FIGURE **8.35** Vertebral column.

Name _____

Section _____ Date _____

5 Label the following parts of the axial skeleton in Figure 8.36.

- ❑ False ribs
- ❑ Floating ribs
- ❑ Inferior articular process (and facet)
- ❑ Lamina
- ❑ Manubrium
- ❑ Pedicle
- ❑ Spinous process
- ❑ Superior articular process (and facet)
- ❑ Transverse process
- ❑ True ribs
- ❑ Vertebral body
- ❑ Xiphoid process

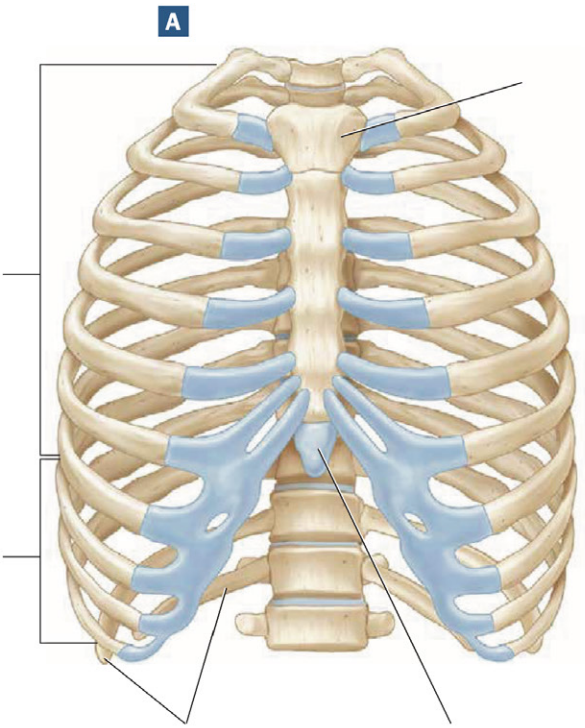

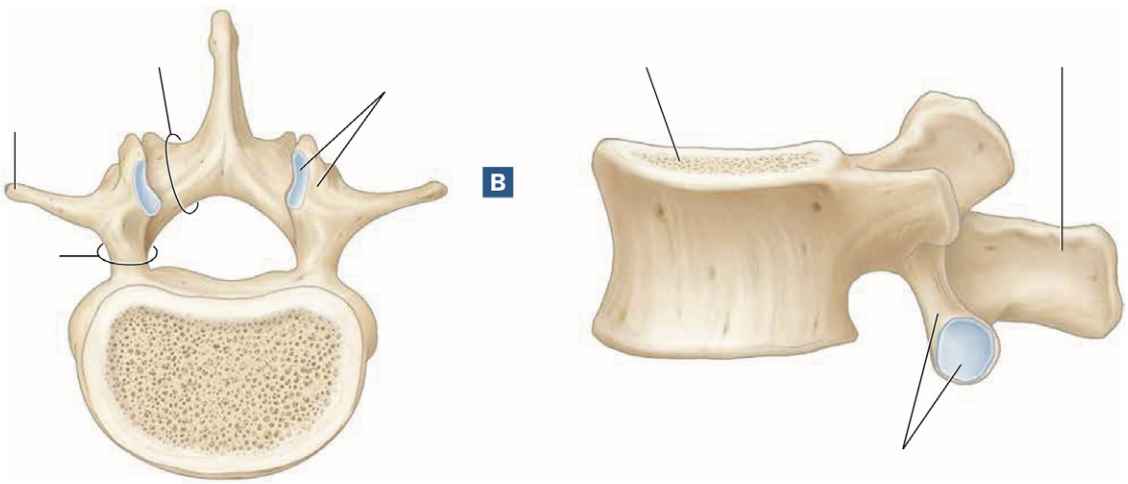

FIGURE **8.36** Axial skeleton: (**A**) thoracic cage; (**B**) a typical vertebra, superior and lateral views.

6 Identify each of the following vertebrae in Figure 8.37 as being cervical, thoracic, lumbar, cervical-axis, or cervical-atlas. Additionally, explain how you arrived at this conclusion.

a _____

b _____

c _____

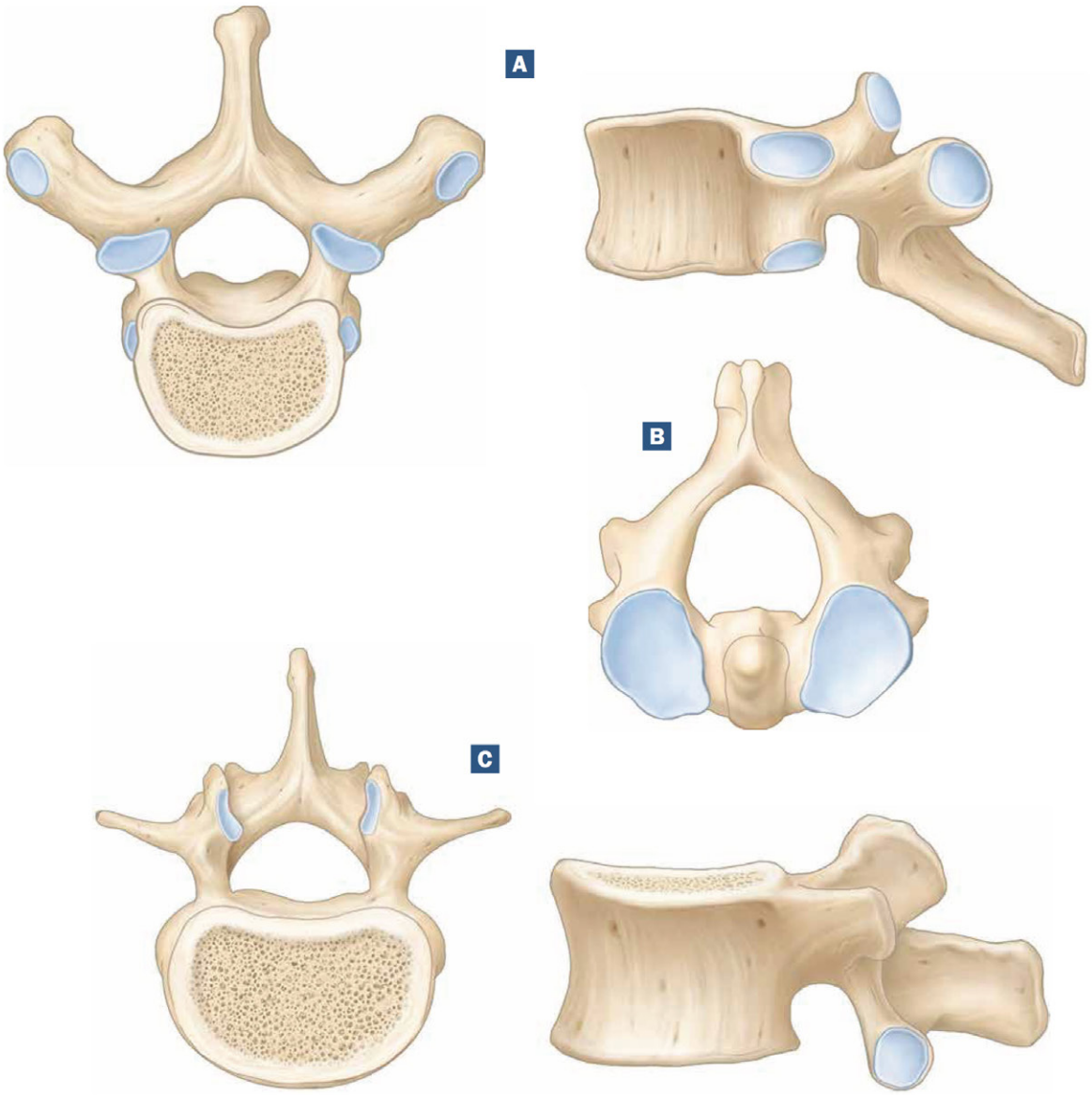

FIGURE **8.37** Unknown vertebrae: (**A**) unknown vertebra 1; (**B**) unknown vertebra 2; (**C**) unknown vertebra 3.

Name _____

Section _____ Date _____

7 Label the following parts of the scapula in Figure 8.38.

- ❑ Acromion
- ❑ Coracoid process
- ❑ Glenoid cavity
- ❑ Infraspinous fossa
- ❑ Spine
- ❑ Subscapular fossa
- ❑ Supraspinous fossa

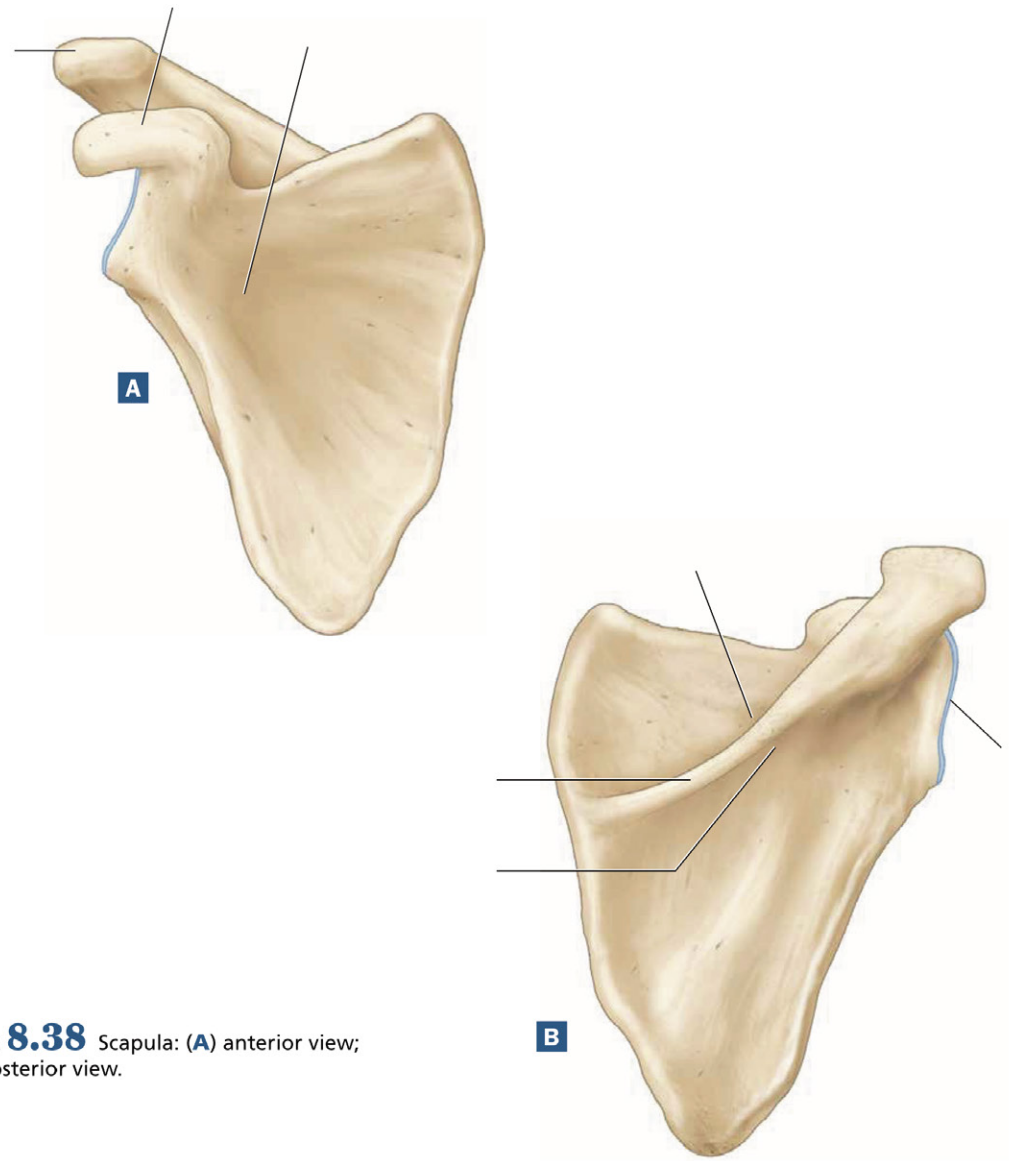

FIGURE **8.38** Scapula: (**A**) anterior view; (**B**) posterior view.

8 Label the following parts of the upper limb in Figure 8.39.

- ❑ Capitulum
- ❑ Coronoid process
- ❑ Deltoid tuberosity
- ❑ Greater tubercle
- ❑ Humeral head
- ❑ Intertubercular sulcus
- ❑ Olecranon
- ❑ Radial head
- ❑ Styloid process
- ❑ Trochlea
- ❑ Trochlear notch

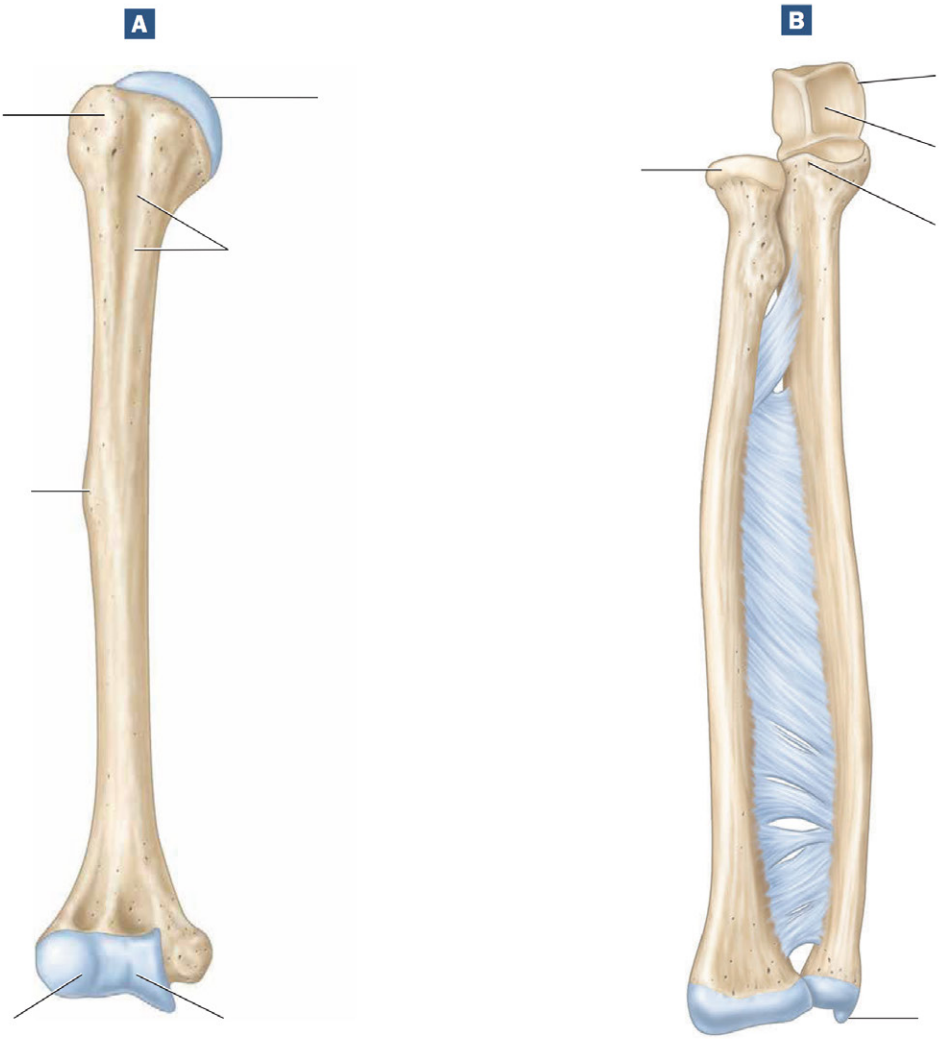

FIGURE **8.39** Upper limb: (**A**) arm, anterior view; (**B**) forearm, anterior view.

Name _____

Section _____ Date _____

9 Label the following parts of the coxal bone (hemipelvis) in Figure 8.40.

- ❑ Acetabulum
- ❑ Anterior superior iliac spine
- ❑ Greater sciatic notch
- ❑ Iliac crest
- ❑ Ilium
- ❑ Ischial spine
- ❑ Ischial tuberosity
- ❑ Ischium
- ❑ Obturator foramen
- ❑ Posterior superior iliac spine
- ❑ Pubis

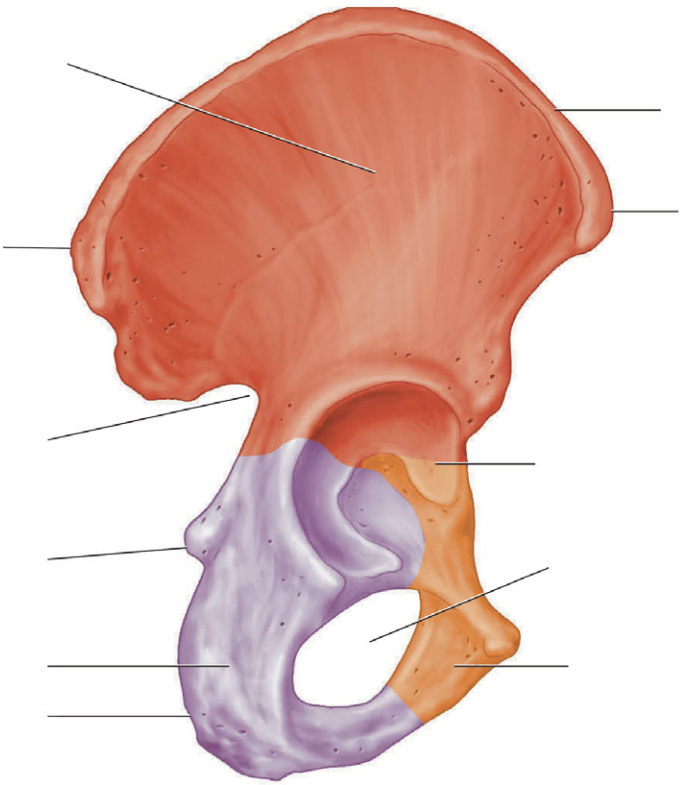

FIGURE **8.40** Right coxal bone, lateral view.

10 Label the following parts of the lower limb in Figure 8.41.

- ❑ Anterior crest
- ❑ Calcaneus
- ❑ Femoral head
- ❑ Femoral neck
- ❑ Greater trochanter
- ❑ Intertrochanteric line
- ❑ Lateral femoral condyle
- ❑ Lateral malleolus
- ❑ Lesser trochanter
- ❑ Medial femoral condyle
- ❑ Medial malleolus
- ❑ Metatarsals
- ❑ Talus
- ❑ Tibial tuberosity

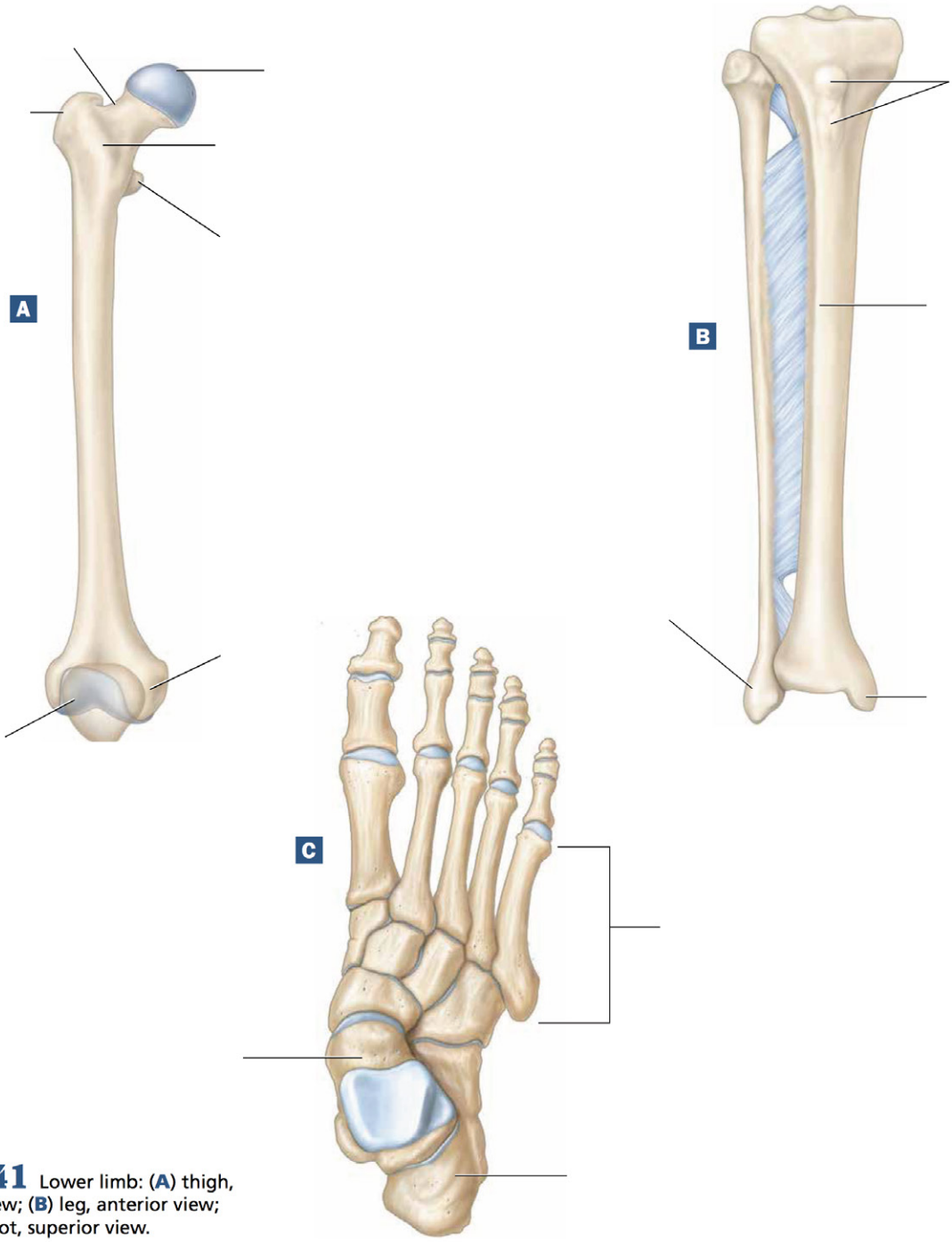

FIGURE **8.41** Lower limb: (**A**) thigh, anterior view; (**B**) leg, anterior view; (**C**) right foot, superior view.

Name _____

Section _____ Date _____

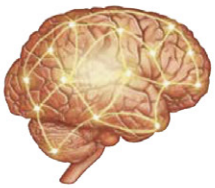

Check Your Understanding

REVIEW

Critical Thinking and Application Questions

1 A patient has persistent jaw pain after a motor vehicle accident. An X-ray reveals a fracture in the anterior part of the temporal bone. Why would a fracture in the anterior temporal bone cause jaw pain?

2 Your friend has suffered a "broken nose." Which bones could potentially be injured in a fracture involving the nose and the nasal cavity?

3 Why do you think a fracture involving the bones of the nasal cavity could affect the cranial cavity?

4 A gymnast lands badly after a vault and "twists" her ankle. She now has significant pain and swelling over her lateral ankle area, and her coach is worried that she might have an ankle fracture. Which bone is involved in her injury? What is the specific part of the bone that is injured?

5 Predict what might happen if the greater and/or lesser sciatic notches of the ilium were abnormally small and narrow. Explain. (***Hint:*** Consider the function of these notches.)

6 You are presented the following X-ray from a six-year-old child (Fig. 8.42).

a Identify the bones in the X-ray.

b Your colleague thinks that there may be a fracture present at the arrow in Figure 8.42. What do you think? Is this a fracture or a normal anatomical feature? Explain. (***Hint:*** Think about bone development in children. What structure is present in many bones at the epiphysis?)

FIGURE **8.42** X-ray from six-year-old child.

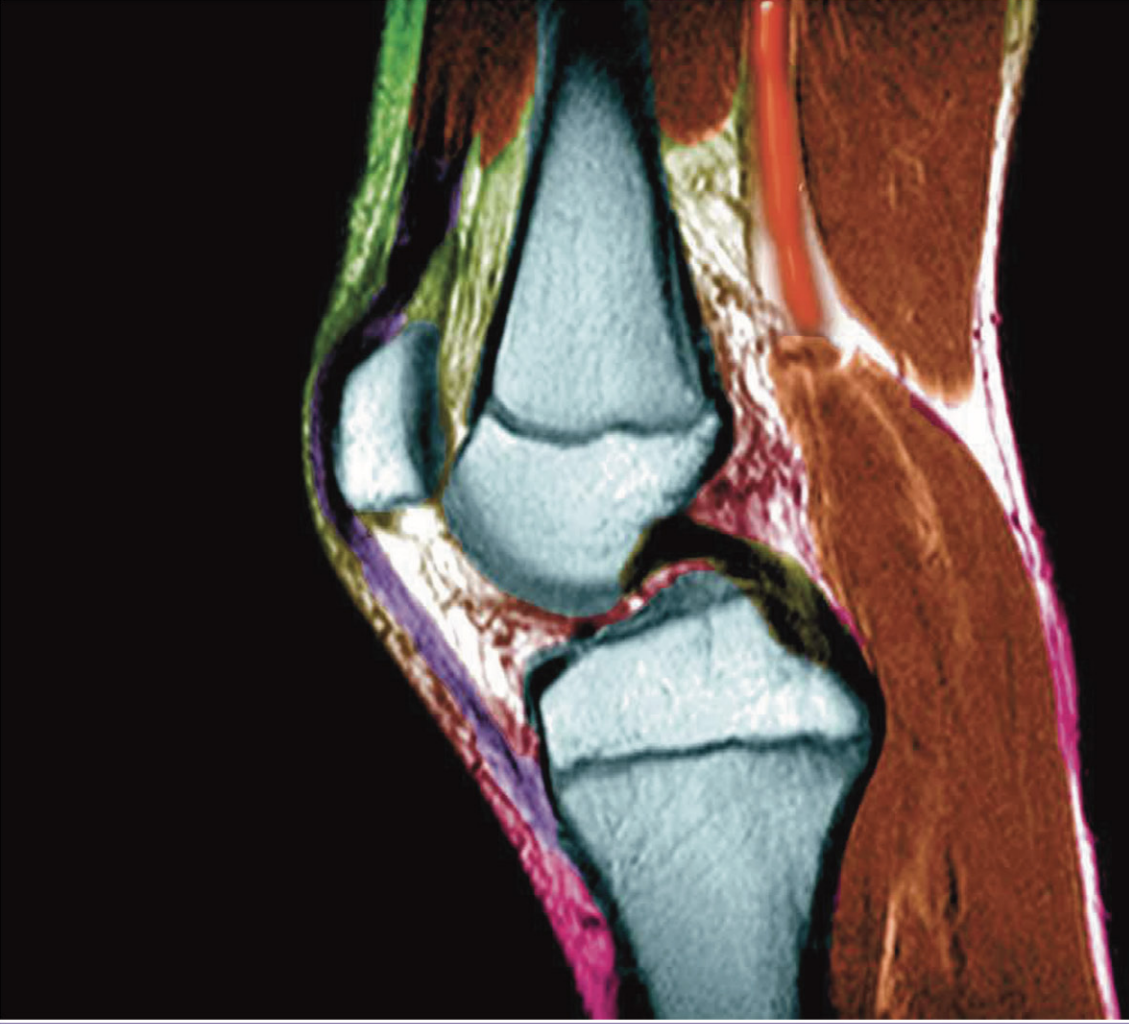

UNIT
9

Articulations

Once you have completed this unit, you should be able to:

1. Classify joints based upon structure and function.
2. Identify examples of the different types of joints.
3. Identify structures associated with synovial joints.
4. Classify synovial joints according to range of motion.
5. Identify structures of the knee and shoulder joints.
6. Demonstrate and describe motions allowed at synovial joints.

Name _____ Section _____ Date _____

PRE-LAB EXERCISES

Complete the following exercises prior to coming to lab, using this lab manual and your textbook for reference.

Pre-Lab Exercise 9-1



Key Terms

You should be familiar with the following terms before coming to lab.

Term	Definition

Classes of Joints by Function

Synarthrosis _____

Amphiarthrosis _____

Diarthrosis _____

Classes of Joints by Structure

Fibrous _____

Cartilaginous _____

Synovial _____

Classes of Synovial Joints by Structure

Plane _____

Hinge _____

Pivot _____

Condyloid _____

Saddle _____

Ball and socket _____

Types of Movement in Synovial Joints

Flexion _____

Extension _____

Abduction _____

Adduction _____

Circumduction _____

Rotation _____

Inversion _____

Eversion _____

Plantarflexion _____

Dorsiflexion _____

Pronation _____

Supination _____

Elevation _____

Depression _____

Opposition _____

Anatomy of Synovial Joints

Label and color the structures of synovial joints in Figure 9.1 with the terms from Exercise 9-2 (p. 235). Use your text and Exercise 9-2 in this unit for reference.

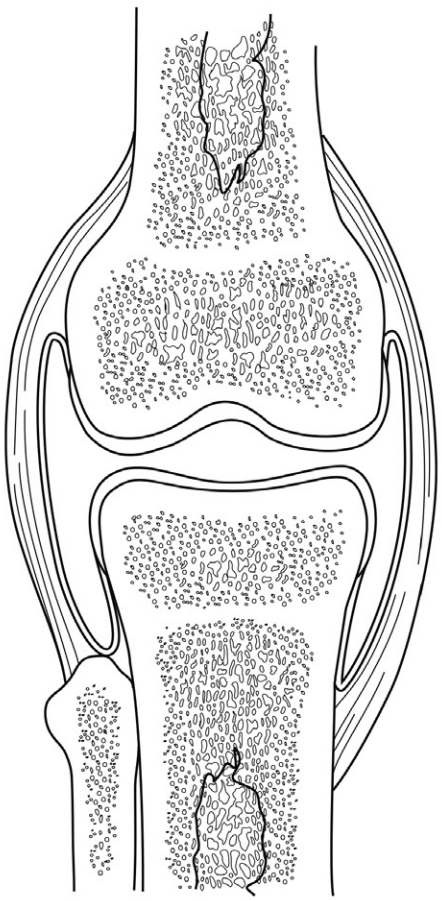

FIGURE **9.1** Structure of a basic synovial joint.

Name _____ Section _____ Date _____

Pre-Lab Exercise 9-3

The Knee Joint

Label and color the knee joint in Figure 9.2 with the terms from Exercise 9-3 (p. 238). Use your text and Exercise 9-3 in this unit for reference.

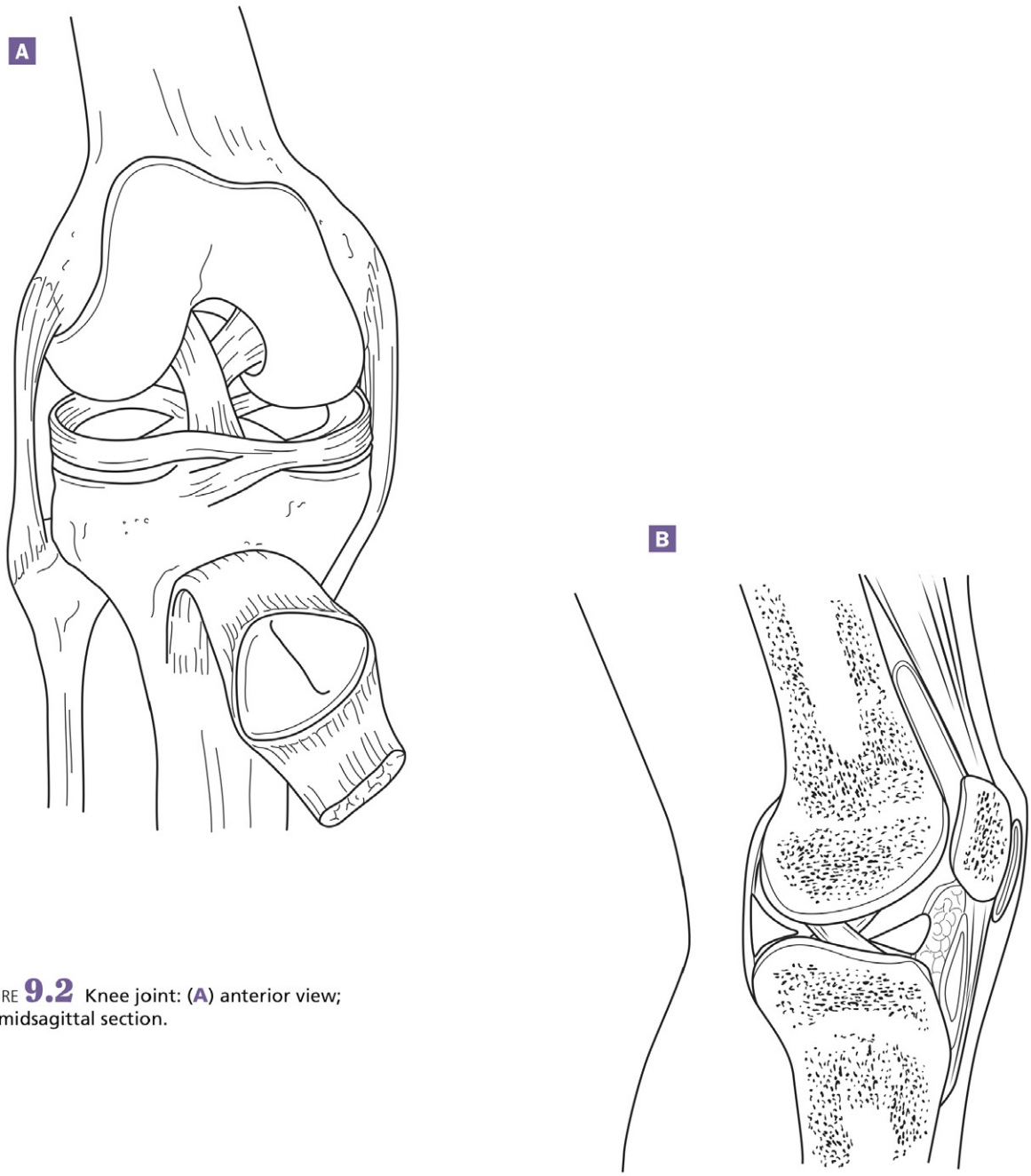

FIGURE 9.2 Knee joint: (A) anterior view; (B) midsagittal section.

The Shoulder Joint

Label and color the shoulder joint in Figure 9.3 with the terms from Exercise 9-4 (p. 241). Use your text and Exercise 9-4 in this unit for reference.

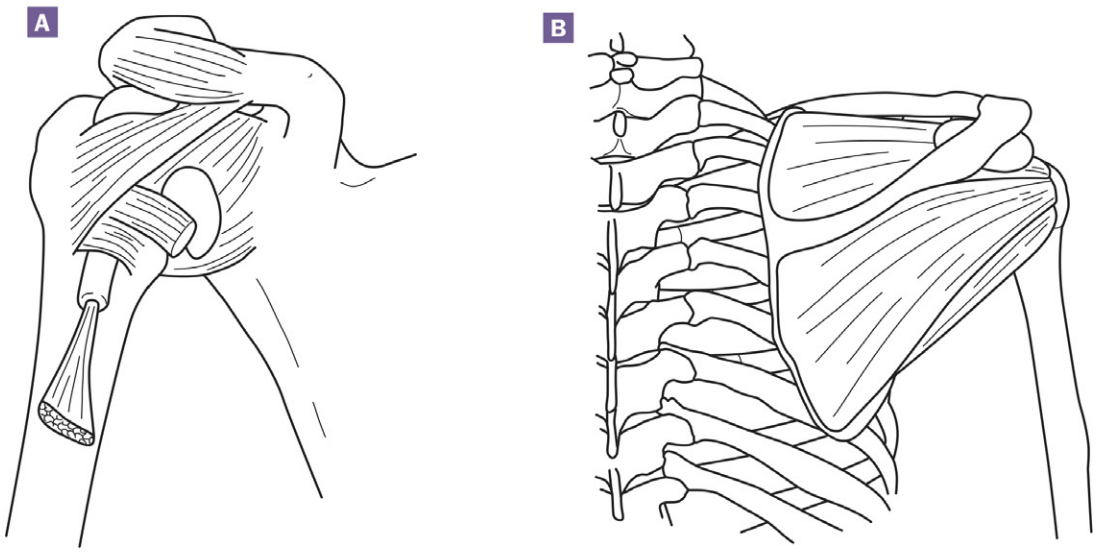

FIGURE 9.3 Shoulder joint: (A) anterior view of the joint capsule; (B) posterior view of the musculature.

Color-enhanced sagittal (lateral) MRI of a child's knee.

EXERCISES

Most bones in the body form **articulations**, or **joints**, with another bone. These articulations provide stability and allow you to perform the wide variety of motions involved in everyday movement. You probably don't realize just how many joints are articulating when you perform routine activities such as answering the phone, walking to the door, or holding a model in A&P lab. In the following exercises you will identify and classify joints according to structure, function, and the amount of motion that they allow; examine the knee and shoulder joints; and determine which joints are involved in simple everyday movements.

Exercise 9-1

Classification of Joints

MATERIALS

- ❑ Skeleton, articulated
- ❑ Skull

Joints are classified according to both their structure and their function. Functionally, joints are classified by the amount of motion that they allow. There are three functional classes of joints:

1. **Synarthroses** (sin-ar-THROH-seez)—immovable joints.
2. **Amphiarthroses** (am-fee-ar-THROH-seez)—joints that allow some motion.
3. **Diarthroses** (dy-ar-THROH-seez)—freely moveable joints.

Structurally, joints are classified by the type of connecting elements we find between the two bones. There are also three structural joint classes (Fig. 9.4):

1. **Fibrous joints. Fibrous joints** consist of bones joined by short collagen fibers. Most fibrous joints allow no motion and are synarthroses. Their main function is to provide stability between the bones. There are three subclasses of fibrous joints:
   a. **Sutures. A suture,** which you learned about in the previous unit, is a joint between two bones of the skull. The edges of the bones feature interlocking wavy ridges that are united by short collagen fibers to make these joints very stable.

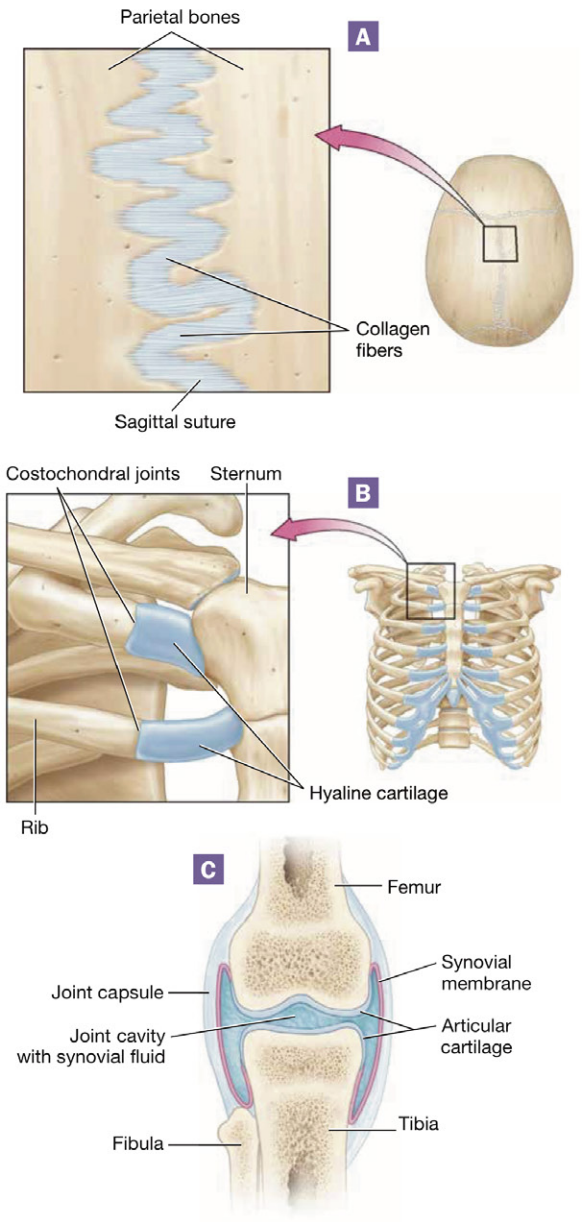

FIGURE **9.4** Structural classes of joints: (**A**) fibrous joint; (**B**) cartilaginous joint; (**C**) synovial joint.

b. **Gomphosis.** A **gomphosis** (gahm-FOH-sis) is located between a tooth and its alveolus in the mandible or maxilla. It is held in place by a fibrous membrane called the *periodontal ligament*.

c. **Syndesmosis. Syndesmoses** (sin-dez-MOH-seez) are located between two parallel articulating bones such as the radius and ulna. The bones in a syndesmosis are joined by a long fibrous membrane called an interosseous membrane. There is some movement allowed between the bones in a syndesmosis, so these joints are classified as amphiarthroses.

2. **Cartilaginous joints. Cartilaginous joints,** as their name implies, consist of bones united by cartilage, which may be hyaline cartilage or fibrocartilage. Most cartilaginous joints in the body allow some motion and are amphiarthroses. The function of cartilaginous joints is also to provide stability, although most provide somewhat less stability than fibrous joints. There are two types of cartilaginous joints:

   a. **Symphyses.** A common type of cartilaginous joint in the body is the **symphysis** (SIM-fih-sis), in which the bones are joined by a tough cartilaginous pad. Examples include the intervertebral joints and the pubic symphysis.

   b. **Synchondroses. Synchondroses** (sin-khan-DROH-seez) consist of bones joined by hyaline cartilage. The epiphyseal plate is an example of a synchondrosis that is a temporary joint. After the plate closes and becomes the epiphyseal line, the joint ceases to exist. Permanent synchondroses include the costochondral joints and the first sternocostal joint.

3. **Synovial joints. Synovial joints** (sih-NOH-vee-uhl) have a true joint cavity, which makes them diarthroses. The two bones are united by a **joint capsule** composed of dense irregular collagenous connective tissue that surrounds and encloses the joint cavity, which is filled with a liquid called *synovial fluid*. The function of synovial joints is to allow motion to occur between two bones, which makes synovial joints much less stable than either fibrous or cartilaginous joints. The subtypes of synovial joints include the following (Fig. 9.5):

   a. **Plane.** The bones of **plane joints** have flat articular surfaces that allow the bones to glide past one another (Fig. 9.5A). There are several examples of plane joints in the body, including the intertarsal joints, the intercarpal joints, and the articulations between the superior and inferior articular processes of the vertebrae.

   b. **Condyloid. Condyloid joints** consist of one bone that fits into the concave surface of another bone, such as the radiocarpal and metacarpophalangeal joints (Fig. 9.5B).

   c. **Saddle.** Note in Figure 9.5C that **saddle joints** somewhat resemble condyloid joints but permit a greater range of motion. An example of a saddle joint is the first carpometacarpal joint of the thumb.

   d. **Hinge.** In a **hinge joint,** the bones fit together much like the hinge of a door (Fig. 9.5D). Generally, the convex articular surface of one bone fits into a concave articular surface of another bone. Examples of hinge joints include the elbow, knee, and interphalangeal joints.

   e. **Pivot.** In a **pivot joint,** one bone rotates or "pivots" around another bone (Fig. 9.5E). Generally, pivot joints consist of one bone with a rounded projection that fits into a groove of another bone, as seen with the atlantoaxial and proximal radioulnar joints.

   f. **Ball-and-socket. Ball-and-socket joints** are named for the rounded, ball-like end of one bone that fits into the concave "socket" of another bone (Fig. 9.5F). The only examples of ball-and-socket joints in the body are the shoulder and hip joints.

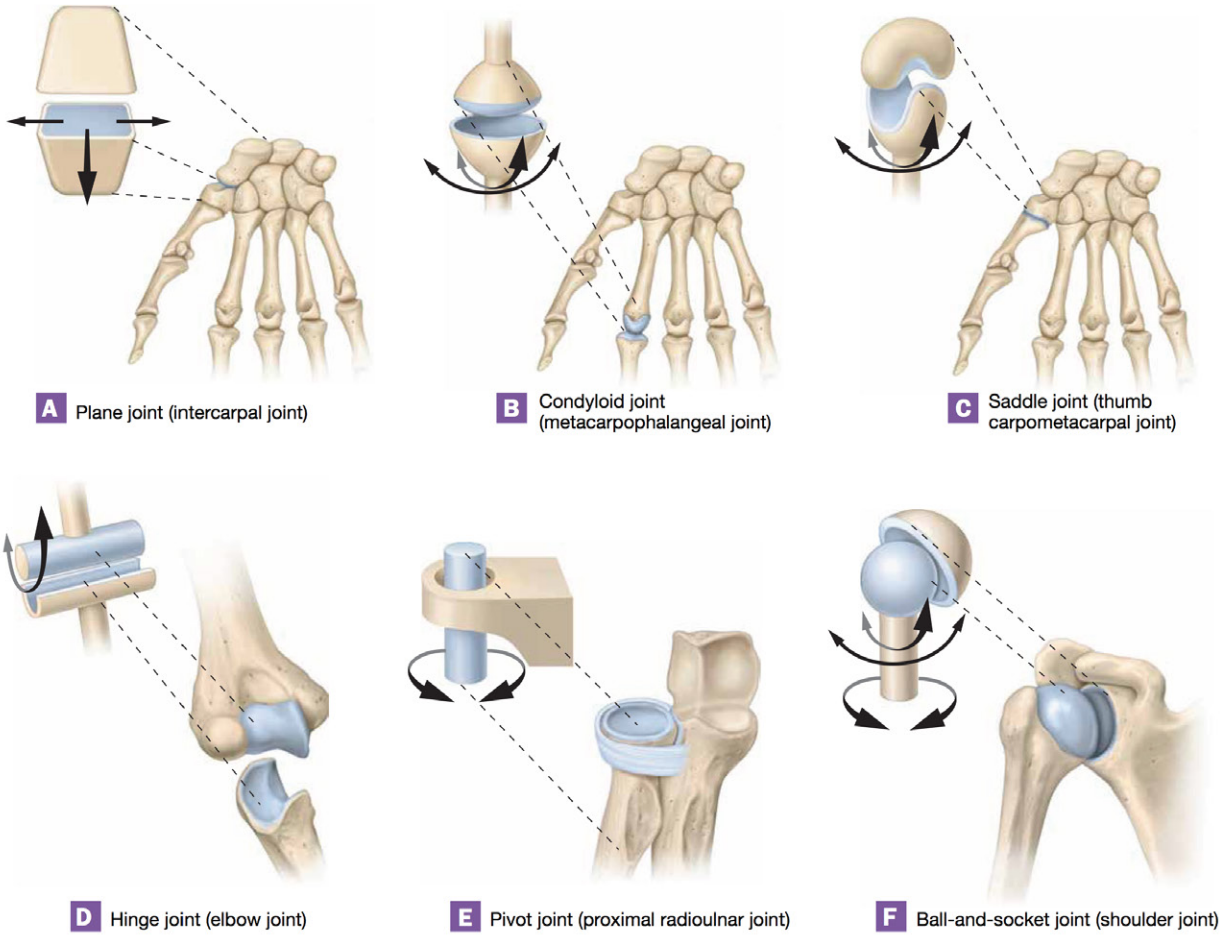

FIGURE **9.5** Structural classes of synovial joints.

Procedure 1 Classifying Joints by Structure and Function

Classify each joint listed in Table 9.1 by its structure. Then examine the joint to determine its structural subcategory. Finally, manipulate the joint to determine its functional classification and how much motion is allowed at the joint. After you have completed the activity, answer Check Your Understanding questions 1 through 3 (p. 251).

TABLE **9.1** Structural and Functional Classification of Joints

Joint	Structural Classification	Structural Subcategory	Functional Classification and Amount of Motion Allowed
Intervertebral joint			
Shoulder (glenohumeral) joint			
Intercarpal joint			
Coronal suture			
Costochondral joint			
Atlantoaxial joint			
Tooth in its alveolus			
Interphalangeal joint			

Exercise 9-2

Synovial Joints

MATERIALS

- ❑ Fresh pig or chicken joints
- ❑ Dissection trays and kits
- ❑ Skeleton, articulated
- ❑ Knee joint model

Synovial joints are freely moveable joints in which the bones are separated by a **joint cavity**. Features common to synovial joints are the following:

- **Articular cartilage.** The articulating ends of the bones are covered with **articular cartilage,** which is usually hyaline cartilage. The cartilage provides a smooth, nearly frictionless surface for articulation.
- **Joint capsule.** As you just read, the **joint capsule** is made of dense irregular collagenous connective tissue. The irregularly arranged collagen fibers allow the capsule to resist pulling forces in many different planes, which provides strength and structural reinforcement for the joint. Internally, the joint capsule is lined by a thin layer of connective and epithelial tissue known as the **synovial membrane.** This membrane secretes **synovial fluid,** which fills the joint cavity, reducing friction and exchanging oxygen, nutrients, and wastes with the cells of articular cartilage.
- **Ligaments.** The bones in a synovial joint are held together by **ligaments,** cords of dense collagenous connective tissue, which further reinforce the joint. Some ligaments (called *extrinsic ligaments*) are within the joint cavity, whereas others (*intrinsic ligaments*) are embedded in the capsule (they are called "intrinsic" because they are an intrinsic part of the capsule).
- **Articular discs.** Also known as **menisci** (men-ISS-kee), **articular discs** are fibrocartilage pads that improve the fit of two bones to prevent dislocation.

Synovial joints typically are surrounded by **tendons,** the collagenous cords that generally attach a muscle to a bone. Fluid-filled sacs called **bursae** (BURR-see) are often located between tendons and joints, and this also reduces friction. Specialized, elongated bursae are found around certain tendons that are subject to a great deal of friction; such bursae are known as **tendon sheaths.**

Procedure 1 Identifying Structures of Synovial Joints

Identify the following structures on fresh specimens such as pigs' feet. If fresh specimens are not available, use anatomical models instead. When you have completed the activity, answer Check Your Understanding question 4 (p. 251).

- ❑ Joint cavity
- ❑ Articular cartilage
- ❑ Joint capsule
- ❑ Synovial membrane
- ❑ Synovial fluid
- ❑ Ligaments
  - ▪ Extrinsic
  - ▪ Intrinsic
- ❑ Articular discs (menisci)
- ❑ Bursae
- ❑ Tendon with tendon sheath

Types of Synovial Joints

The range of motion of a synovial joint is described conventionally in terms of an invisible *axis* about which the bone moves. Synovial joints are classified according to the number of planes of motion in which the bones can move around this axis. The classes are as follows:

1. **Nonaxial joints.** As implied by its name, a **nonaxial joint** does not move around an axis. Instead, the bones in a nonaxial joint simply glide past one another. An example of a nonaxial joint is the vertebrocostal joint (the joint between a thoracic vertebra and a rib).
2. **Uniaxial joints.** Joints that allow motion in one plane or direction around a single axis of motion are called **uniaxial joints.** A classic example is the elbow, which permits only flexion and extension.
3. **Biaxial joints.** Joints that allow motion in two planes around two axes of motion are called **biaxial joints.** An example of a biaxial joint is the wrist, which allows both flexion/extension and abduction/adduction.
4. **Multiaxial joints.** The joints with the greatest range of motion are **multiaxial joints,** which allow motion in multiple planes around all three axes of motion. An example of a multiaxial joint is the shoulder joint.

Procedure 2 Classifying Synovial Joints

For each of the following joints, first list the joint's structural classification in Table 9.2. Then obtain an articulated skeleton so you can manipulate each joint and determine if the joint is nonaxial, uniaxial, biaxial, or multiaxial.

TABLE 9.2 Classification of Synovial Joints

Joint	Structural Classification	Range of Motion (nonaxial, uniaxial, biaxial, or multiaxial)
Shoulder joint		
Intercarpal joint		
Proximal radioulnar joint		
Radiocarpal joint		
Thumb carpometacarpal joint		
Interphalangeal joint		
Knee joint		
Atlantoaxial joint		
Hip joint		

Exercise 9-3

Knee Joint

MATERIALS

❑ Knee joint model

The **knee joint**, illustrated in Figure 9.6, is a modified hinge joint made up of the medial and lateral femoral condyles and the tibial plateau. It is stabilized by numerous ligaments, including intrinsic ligaments (which are part of the joint capsule) and extrinsic ligaments. Four important extrinsic ligaments include the following:

1. **Anterior cruciate ligament (ACL).** The **anterior cruciate ligament** (KROO-shee-iht), or **ACL**, extends from the anterior tibial plateau to the posterior part of the lateral femoral condyle. Its function is to prevent hyperextension of the knee.
2. **Posterior cruciate ligament (PCL).** The **posterior cruciate ligament**, or **PCL**, extends from the posterior tibial plateau to the anterior part of the medial femoral condyle. It crosses under the ACL, and the two together form an "X." The PCL prevents posterior displacement of the tibia on the femur (i.e., it stops the tibia from sliding backward on the femur).
3. **Tibial collateral ligament.** The **tibial collateral ligament**, also known as the *medial collateral ligament (MCL)*, extends from the medial tibia to the medial femur. It resists stresses that pull the tibia laterally on the femur.
4. **Fibular collateral ligament.** The **fibular collateral ligament**, also known as the *lateral collateral ligament (LCL)*, extends from the lateral fibula to the lateral femur. It resists stresses that pull the tibia medially on the femur.

Two other important supportive structures of the knee joint are the **medial** and **lateral menicsi.** These half-moon-shaped articular discs are located on the outer edges of the tibial plateau, and they help to improve the fit of the tibia and femur. The tibial collateral ligament attaches to the medial meniscus, a fact that becomes apparent when the tibial collateral ligament is injured, as the medial meniscus is often injured along with it.

As you can see in Figure 9.6B, there are also a number of **bursae** around the knee joint. These bursae are particularly concentrated around the patella, as this bone generates a great deal of friction over the femur during motion. For this reason, these bursae can become inflamed as a result of repetitive activities or simply "overdoing" it.

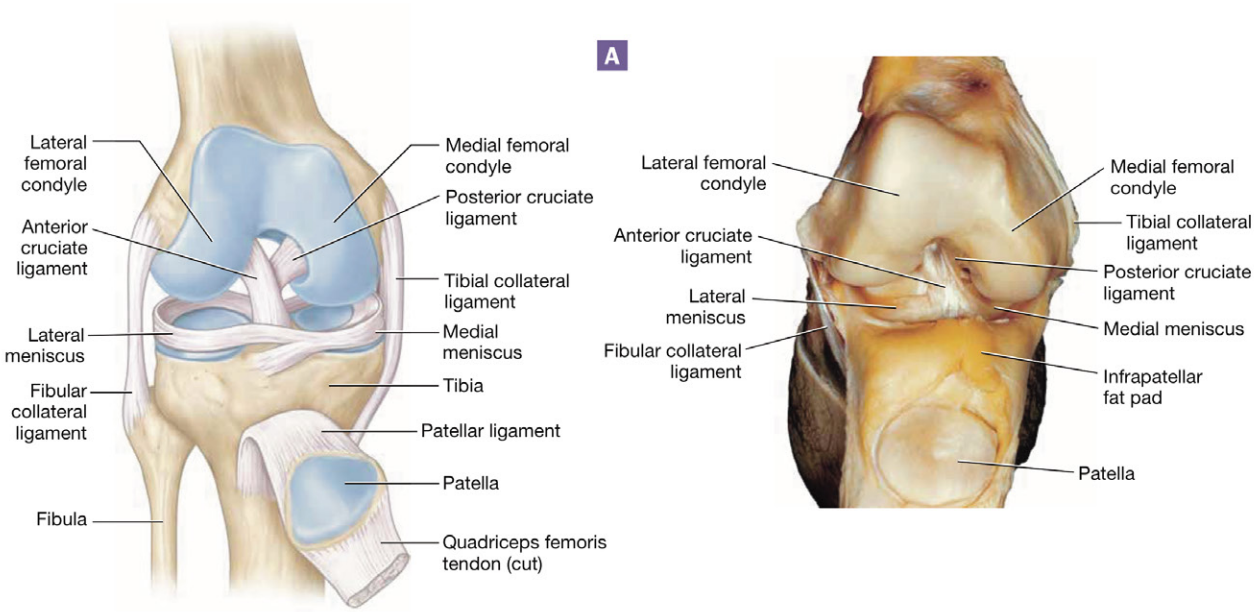

FIGURE **9.6** Right knee joint: (**A**) anterior view; *(continues)*

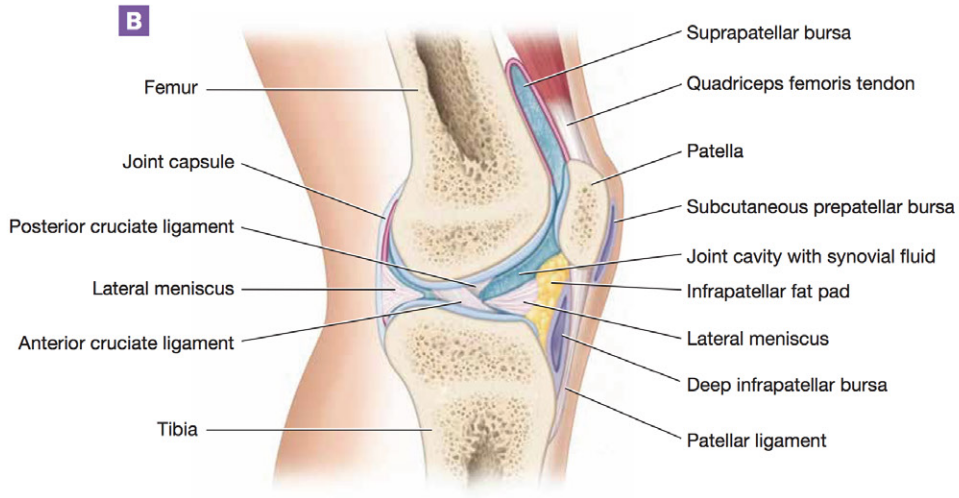

FIGURE **9.6** Right knee joint *(cont.)*: **(B)** midsagittal section.

Procedure 1 Identifying Structures of the Knee Joint

Identify the following structures of the knee joint on anatomical models or fresh specimens. Check off each structure as you identify it.

- ❑ Medial and lateral femoral condyles
- ❑ Tibial plateau
- ❑ Joint capsule
- ❑ Ligaments
  - Anterior cruciate ligament (ACL)
  - Posterior cruciate ligament (PCL)
  - Tibial collateral ligament
  - Fibular collateral ligament
- ❑ Menisci
  - Medial meniscus
  - Lateral meniscus
- ❑ Patella
- ❑ Patellar bursae

Procedure 2 Time to Draw

In the space below, draw, color, and label one of the knee models that you examined. In addition, write the function of each structure that you label.

Procedure 3 Testing the Integrity of the ACL and PCL

One of the more common knee injuries is a torn ACL and/or PCL. To assess the integrity of the ACL and PCL, tests known as the **anterior drawer** and **posterior drawer**, respectively, are performed. A normal result of both tests is a minimum amount of motion when the tibia is moved anteriorly and posteriorly. When you have completed the tests, answer Check Your Understanding question 5 (p. 252).

1. Have your partner sit with the knees bent at 90° and relaxed.
2. Grasp your partner's leg with both hands around the proximal tibia and fibula.
3. Gently pull the leg anteriorly, being careful not to extend the knee joint.
   - Amount of motion: _____
   - Which ligament was being assessed (ACL or PCL)? _____
4. Now gently push the leg posteriorly. Be careful not to flex the knee joint.
   - Amount of motion: _____
   - Which ligament was being assessed (ACL or PCL)? _____

Exercise 9-4

Shoulder Joint

MATERIALS

❑ Shoulder joint model

The **shoulder joint**, more properly called the **glenohumeral joint** (glen´-oh-HYOO-mur-uhl), is a multiaxial joint that consists of the head of the humerus and the *glenoid cavity* of the scapula (Fig. 9.7). Like the knee joint, the shoulder is supported by a number of surrounding structures, including the following:

- **Glenoid labrum.** The **glenoid labrum** (LAY-brum) is a fibrocartilaginous ring along on the rim of the glenoid cavity that improves the fit of the humeral head in the glenoid cavity (Fig. 9.7A).
- **Ligaments.** The shoulder joint has a much greater range of motion than the knee, and as a result its joint capsule is thinner and weaker and its ligaments are fewer in number. One ligament is the **coracohumeral ligament** (kohr'-uh-koh-HYOO-muhr-uhl), located in the anterior articular capsule between the humeral head and the coracoid process (Fig. 9.7B). In addition, three **glenohumeral ligaments** may be found reinforcing the anterior joint capsule.

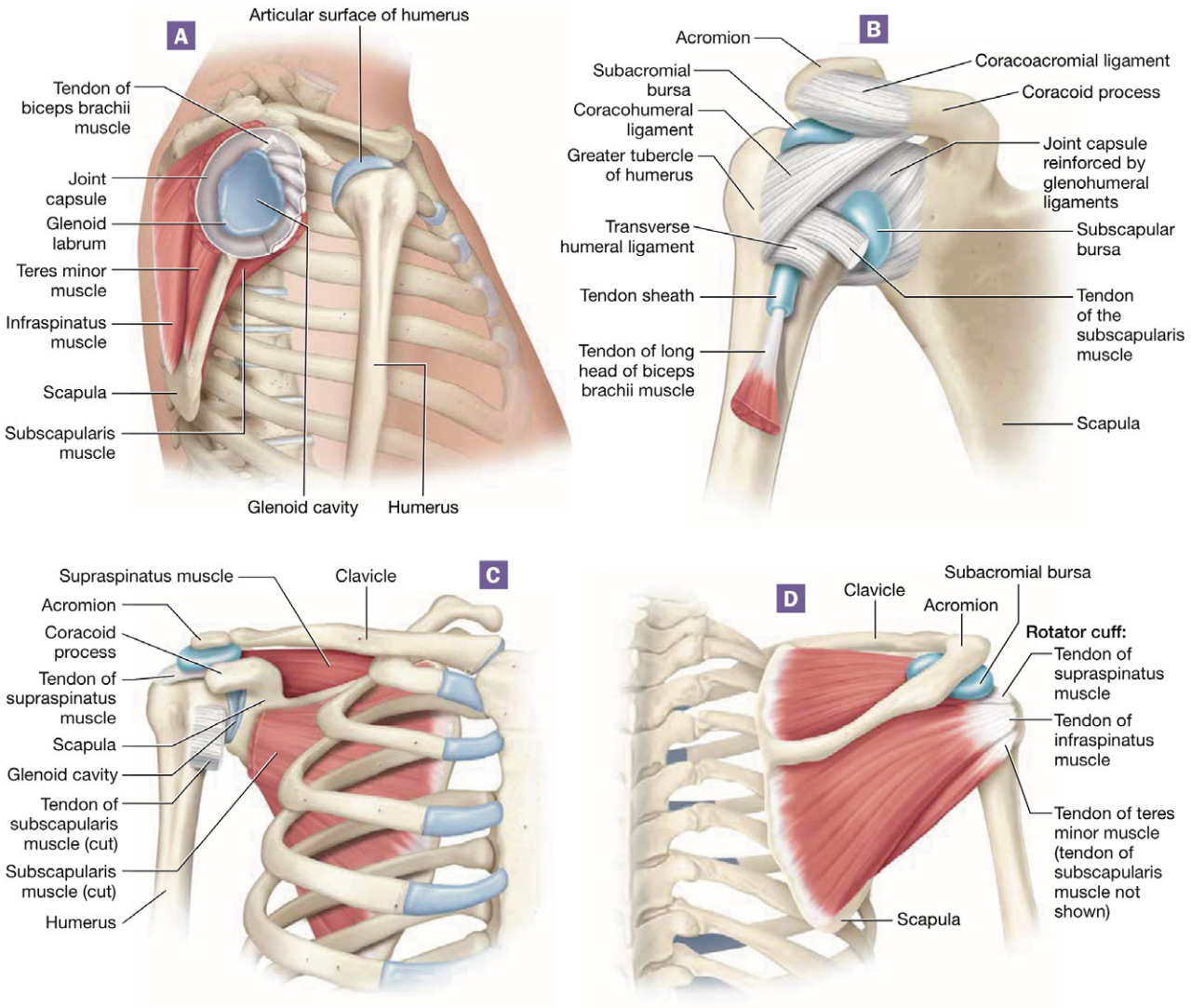

FIGURE **9.7** Right shoulder joint: (**A**) lateral view; (**B**) anterior view of joint capsule; (**C**) anterior view of musculature; (**D**) posterior view of musculature.

- **Biceps brachii tendon.** Another stabilizing force comes from the tendon of the *biceps brachii muscle*, found in the anterior arm. This tendon passes through the articular capsule of the shoulder joint on its way to its attachment point on the scapula.
- **Rotator cuff.** One of the major stabilizing forces of the shoulder joint is a group of four muscles and their tendons—the supraspinatus, infraspinatus, teres minor, and subscapularis—collectively called the **rotator cuff** (Figs. 9.7C and D). One of the most common injuries of the shoulder joint is a rotator cuff tear.

Several bursae and tendon sheaths are found around the shoulder joint. One of the largest bursae, the *subacromial bursa*, is frequently inflamed secondary to overuse injuries.

Procedure 1 Identifying Structures of the Shoulder Joint

Identify the following structures of the shoulder joint on anatomical models or fresh specimens. Check off each structure as you identify it. When you have completed the activity, answer Check Your Understanding question 6 (p. 252).

- ❑ Humeral head
- ❑ Glenoid cavity
  - Glenoid labrum
- ❑ Ligaments
  - Coracohumeral ligament
  - Glenohumeral ligaments
- ❑ Biceps brachii tendon
- ❑ Tendons of rotator cuff muscles
  - Supraspinatus tendon
  - Infraspinatus tendon
  - Teres minor tendon
  - Subscapularis tendon
- ❑ Bursae
- ❑ Joint capsule

Exercise 9-5

Motions of Synovial and Cartilaginous Joints

Each time you move your body in a seemingly routine fashion (such as walking or climbing stairs), you are producing motion at a tremendous number of joints. Many possible motions can occur at synovial and cartilaginous joints. These motions are illustrated in Figure 9.8.

In the following procedure you will determine which joints you are moving with some commonly performed actions and which motions are occurring at each joint.

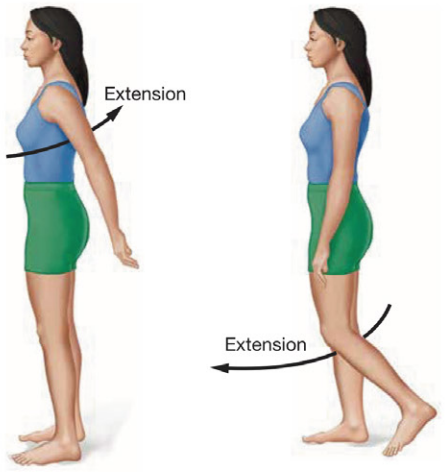

A Angular movements: Extension and flexion at the shoulder and knee

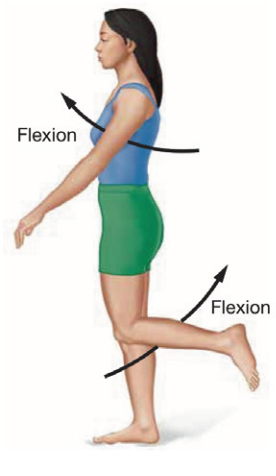

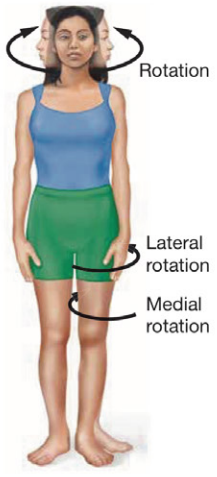

B Rotation of the head, neck, and lower limb

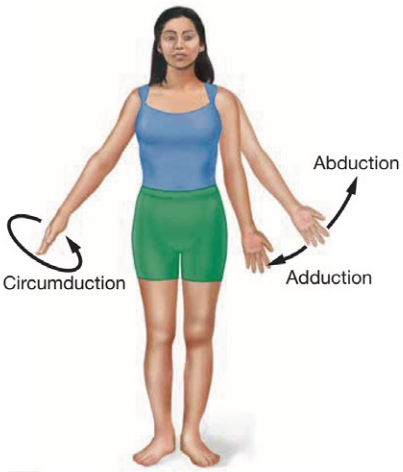

C Angular movements: adduction, abduction, and circumduction of the upper limb at the shoulder

D Dorsiflexion and plantarflexion

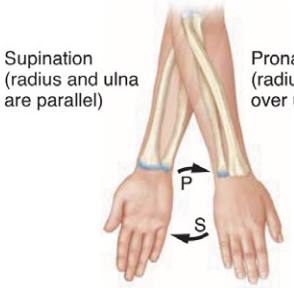

E Pronation (P) and supination (S)

F Inversion and eversion

G Opposition and reposition

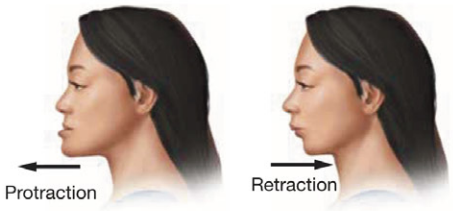

H Protraction and retraction

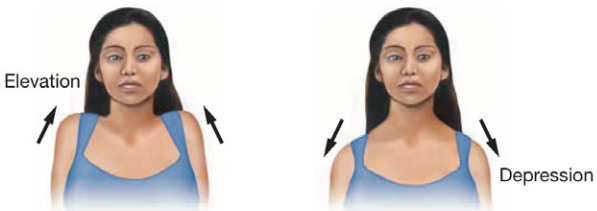

I Elevation and depression

FIGURE 9.8 Motions of synovial and cartilaginous joints.

Procedure 1 Identifying Joint Motions of Common Movements

Team up with a partner, and have your partner perform each of the following actions. Watch carefully as the actions are performed, and list the joints that are in motion.

Ask your instructor if he or she wants you to use the technical name or the common name for each joint (e.g., glenohumeral versus shoulder joint). Some of the joints, such as the hip joint and knee joint, will be obvious. Others, such as the radioulnar joint, the interphalangeal joints, and the intervertebral joints, are less obvious and easily overlooked.

Once you have listed the joints being used, determine which motions are occurring at each joint. Keep in mind the type and the range of motion of each joint as you answer each question. When you have completed the activity, answer Check Your Understanding question 7 (p. 252).

1 Walking up stairs

Joints moving:

Motions occurring:

2 Doing jumping jacks

Joints moving:

Motions occurring:

3 Answering the telephone

Joints moving:

Motions occurring:

4 Jumping rope

Joints moving:

Motions occurring:

Name _____

Section _____ Date _____

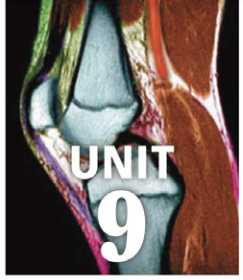

REVIEW

Check Your Recall

1 An amphiarthrosis is defined as a

a. joint that allows no motion.
b. joint that is freely moveable.
c. joint with multiple axes of motion.
d. joint that allows some motion.

2 The main function of a fibrous joint is to

a. allow motion to occur between two bones.
b. provide stability between two bones.
c. unite two bones with cartilage.
d. allow some motion while still providing stability between two bones.
e. unite two bones with a synovial cavity.

3 Synovial joints are surrounded by a/an _____ and filled with _____.

a. articular disc; serous fluid
b. joint capsule; synovial fluid
c. articular cartilage; serous fluid
d. articular disc; synovial fluid

4 Which of the following describes a hinge joint correctly?

a. The convex articular surface of one bone fits into a concave articular surface of another bone.
b. One bone rotates around another bone.
c. The flat articular surfaces of two bones glide past one another.
d. The rounded, ball-like end of one bone fits into a concave depression of another bone.

5 *True/False:* Mark the following statements as true (T) or false (F). If the statement is false, correct it so it is a true statement.

_____ a. The articulating ends of the bones in a synovial joint are covered by articular cartilage.

_____ b. Bursae improve the fit between two bones in a synovial joint.

_____ c. The tendon sheath of a synovial joint is lined with a synovial membrane.

_____ d. Articular discs provide a smooth, nearly frictionless surface for articulation.

_____ e. Fluid-filled sacs called ligaments often lie between tendons and the joint capsule of a synovial joint.

6 How do nonaxial, uniaxial, biaxial, and multiaxial synovial joints differ?

7 Which of the following correctly describes a pivot joint?

a. The convex articular surface of one bone fits into a concave articular surface of another bone.
b. One bone rotates around another bone.
c. The flat articular surfaces of two bones glide past one another.
d. The rounded, ball-like end of one bone fits into a concave depression of another bone.

8 Label the following parts of the knee joint in Figure 9.9.

- ❑ Anterior cruciate ligament
- ❑ Fibular collateral ligament
- ❑ Lateral meniscus
- ❑ Medial meniscus
- ❑ Patellar ligament
- ❑ Posterior cruciate ligament
- ❑ Tibial collateral ligament

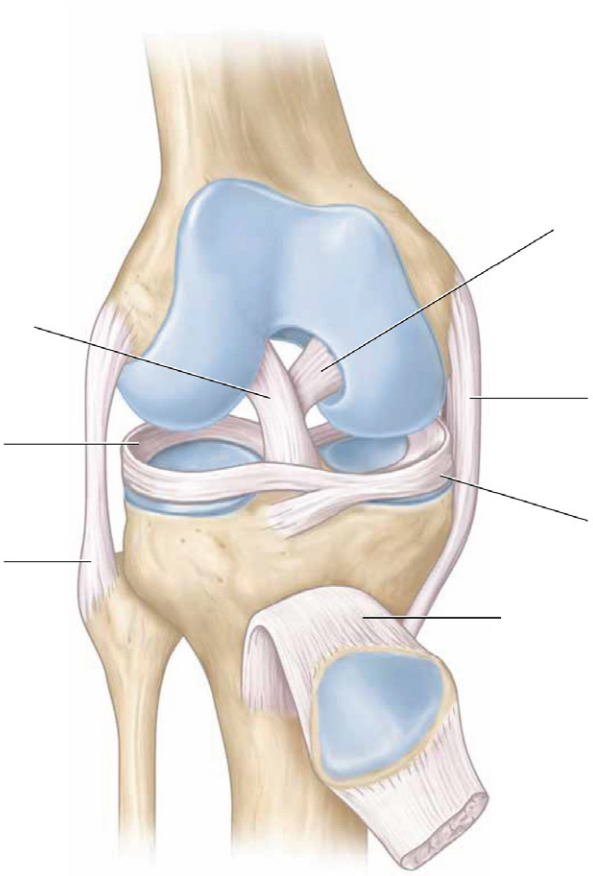

FIGURE **9.9** Knee joint.

Name _____

Section _____ Date _____

9 Label the following parts of the shoulder joint in Figure 9.10.

- ❑ Biceps brachii tendon
- ❑ Coracohumeral ligament
- ❑ Glenoid labrum
- ❑ Infraspinatus tendon
- ❑ Joint capsule
- ❑ Subscapularis tendon
- ❑ Supraspinatus tendon
- ❑ Teres minor tendon

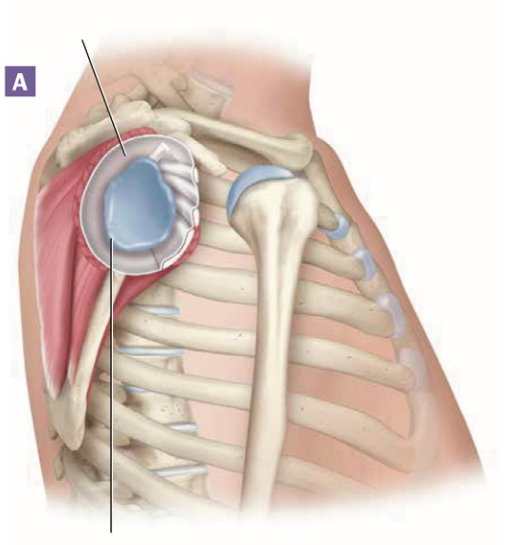

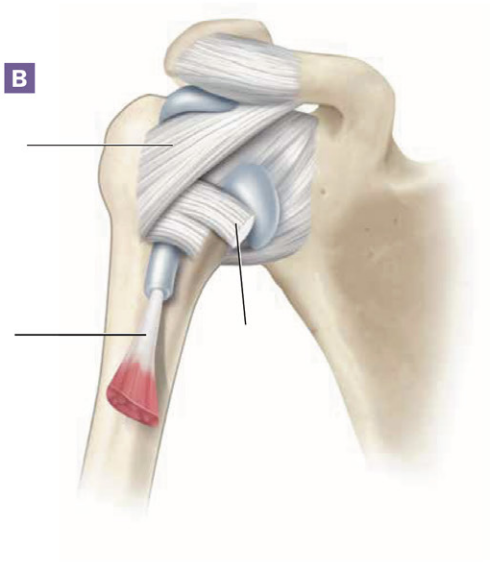

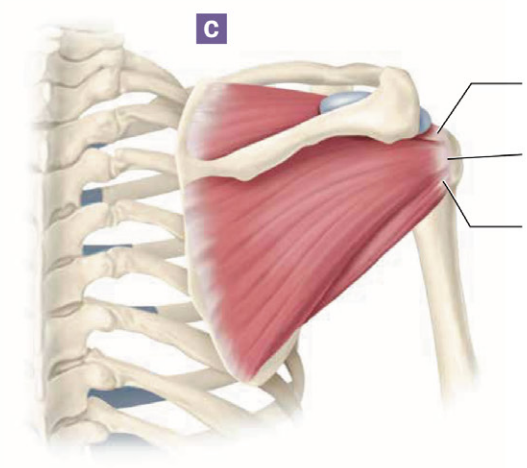

FIGURE **9.10** Shoulder joint: (A) lateral view; (B) anterior view; (C) posterior view.

10 *Matching:* Match the following terms with the correct description.

_____ Flexion	A. Movement of a body part toward the midline
_____ Circumduction	B. Movement around a central axis
_____ Adduction	C. Turning the palm over to face down
_____ Extension	D. Decreasing the angle between two bones
_____ Dorsiflexion	E. Movement of a body part away from the midline
_____ Abduction	F. Increasing the angle between two bones
_____ Rotation	G. Movement of the ankle that decreases the angle between the foot and leg
_____ Pronation	H. Movement in a circle

Name _____

Section _____ Date _____

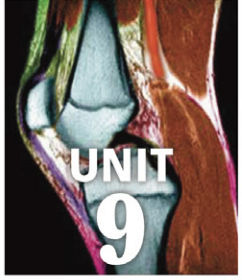

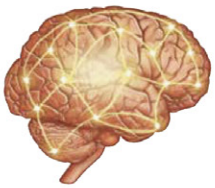

Check Your Understanding

REVIEW

Critical Thinking and Application Questions

1 How would the function of synovial joints be changed if they lacked joint cavities? Explain.

2 Could a fibrous joint perform its functions if it were a diarthrosis? Explain your reasoning.

3 Which class of synovial joint do you think would be the most stable? Which class would be the least stable? Explain your choices.

4 In the condition *synovitis* the synovial membrane secretes excess synovial fluid. How might this affect the function of a synovial joint?

5 Your friend is on the basketball court when she is pushed over the leg of a fallen player and lands on the court on her bent knee. She tries to get up, but immediately realizes something is wrong. The trainer examines her knee and finds excessive motion with the posterior drawer test. What has happened? Explain the results of the posterior drawer test.

6 When the shoulder joint dislocates, it most commonly dislocates posteriorly, meaning that the joint capsule tears on the posterior side and the head of the humerus pushes partly out through the capsule. Why do you think the posterior capsule more commonly tears? (***Hint:*** Consider the structure of the capsule and look at the ligaments of the shoulder joint.)

7 Regarding circumduction and rotation:

a Compare and contrast circumduction and rotation.

b Give examples of joints where:

(1) both circumduction and rotation can occur.

(2) circumduction but not rotation can occur.

(3) rotation but not circumduction can occur.

UNIT
10

Muscular System:
The Gross Anatomy of Muscles

Once you have completed this unit, you should be able to:

1. Identify muscles of the upper and lower limbs, trunk, head, and neck.
2. Describe the origin, insertion, and action of selected muscles.
3. Describe the muscles required to perform common movements.

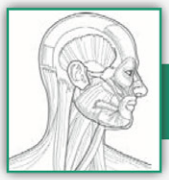

Name _____ Section _____ Date _____

PRE-LAB EXERCISES

Complete the following exercises prior to coming to lab, using this lab manual and your textbook for reference.

Pre-Lab Exercise 10-1



Key Terms

You should be familiar with the following terms before coming to lab. Please note that the individual skeletal muscles are covered in Table 10.1 (p. 259).

Term	Definition
General Terms	

Origin _____

Insertion _____

Muscle action _____

Name _____ Section _____ Date _____

Pre-Lab Exercise 10-2

Skeletal Muscle Anatomy

Label and color the muscles in Figure 10.1 with the terms from Exercise 10-1 (p. 261). Use your text and Exercise 10-1 in this unit for reference.

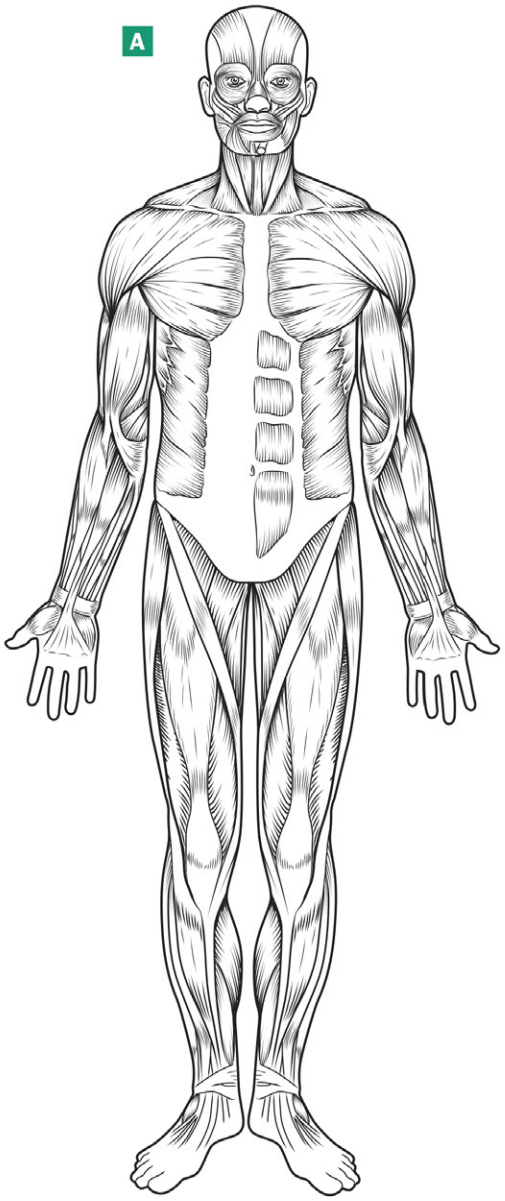

FIGURE **10.1** Human musculature: (**A**) anterior view; *(continues)*

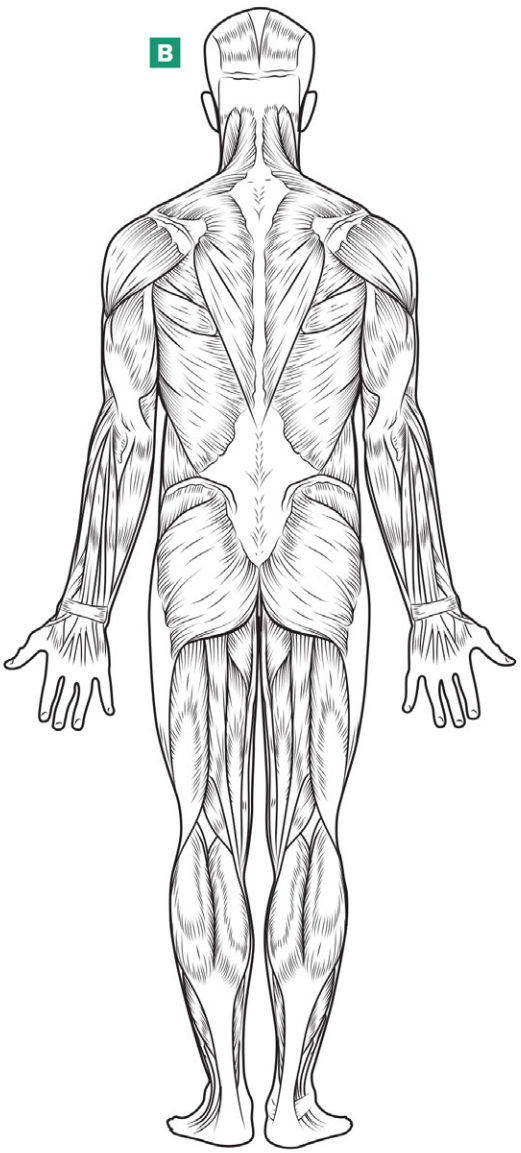

FIGURE **10.1** Human musculature *(cont.)*: (**B**) posterior view; *(continues)*

C

D

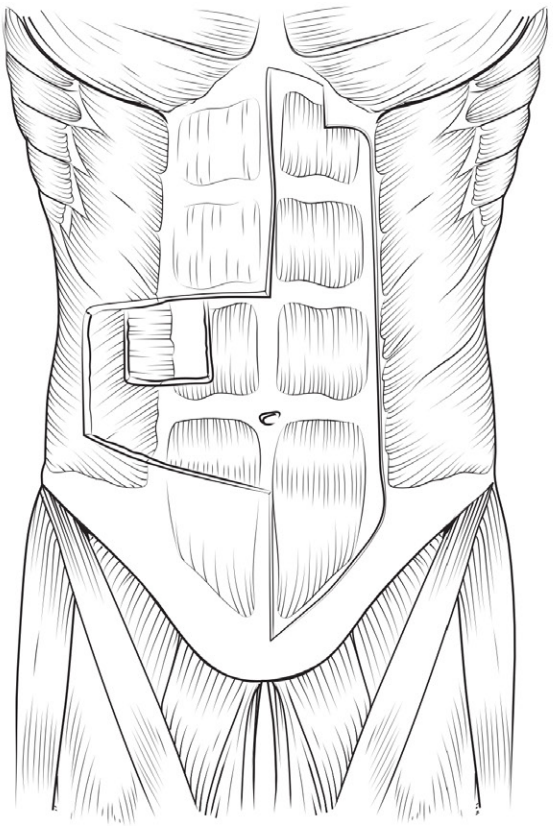

FIGURE **10.1** Human musculature *(cont.)*: (C) lateral view of the head and neck; (D) abdominal muscles; *(continues)*

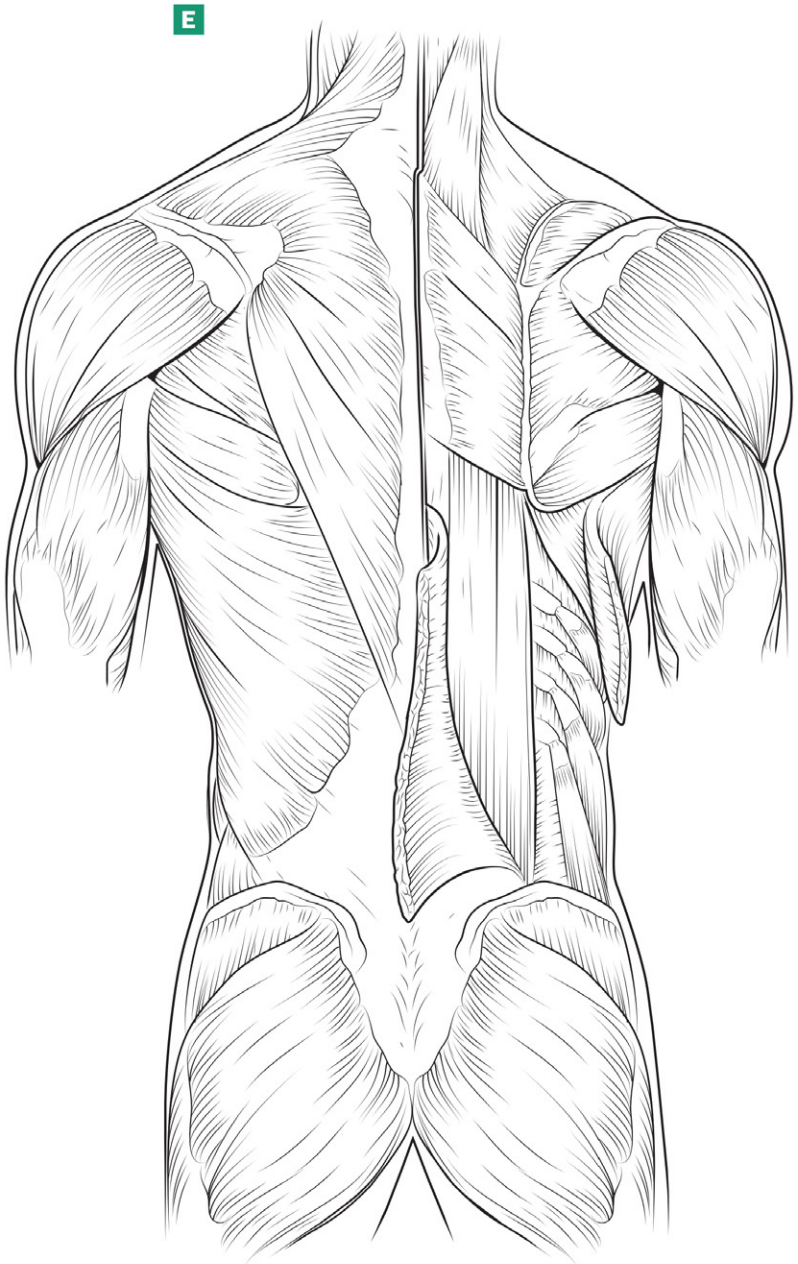

FIGURE **10.1** Human musculature *(cont.)*: **(E)** posterior torso.

Name _____ Section _____ Date _____

Pre-Lab Exercise 10-3

Muscle Origins, Insertions, and Actions

Complete Table 10.1 with the origins, insertions, and *main* actions for the listed muscles. You may notice in your textbook that the origin and insertion of a muscle often are extensive. For example, the latissimus dorsi muscle originates from T7–L5, the lower three or four ribs, the inferior angle of the scapula, and the thoracolumbar fascia. This obviously is quite a bit to write and to remember, so I suggest shortening it to something that makes sense to you (e.g., "inferior back and scapula"). You also will notice that most muscles have more than one action, which you may wish to simplify as well. If your instructor prefers that you learn the more technical version, learning a simplified version first may be helpful.

TABLE **10.1** Selected Muscle Origins, Insertions, and Actions

Muscle	Origin	Insertion	Action(s)
Muscles of the Head and Neck			
Orbicularis oculi m.			
Orbicularis oris m.			
Masseter m.			
Sternocleidomastoid m.			
Trapezius m.			
Muscles of the Thorax, Abdomen, and Back			
Rectus abdominis m.			
External oblique m.			
Internal oblique m.			
Erector spinae m.			
Deltoid m.			
Pectoralis major m.			
Latissimus dorsi m.			

(continues)

TABLE **10.1** Selected Muscle Origins, Insertions, and Actions *(cont.)*

Muscle	Origin	Insertion	Action(s)
Muscles of the Upper Limb			
Biceps brachii m.			
Triceps brachii m.			
Brachioradialis m.			
Muscles of the Lower Limb			
Iliopsoas m.			
Gluteus maximus m.			
Gluteus medius m.			
Sartorius m.			
Rectus femoris m.			
Vastus muscle group			
Adductor muscle group			
Biceps femoris m.			
Semitendinosus m.			
Semimembranosus m.			
Gastrocnemius m.			
Tibialis anterior m.			

Preserved dissected cadaver at the Bodyworlds exhibit.

EXERCISES

The human body has nearly 700 skeletal muscles that range dramatically in size and shape from the large trapezius muscle to the tiny corrugator supercilii muscle. Luckily for you, we will be learning only about 70 muscles rather than the full 700.

A muscle generally has two main attachment points. First is its **origin**, which is generally the body part that remains stationary, and second is its **insertion**, which is generally the part that the muscle moves. We are most familiar with muscles that insert into and move bones. Many muscles, however, insert into structures other than bones. Examples include the diaphragm, which inserts into its own central tendon, and the muscles of facial expression, which insert into skin or other muscles.

The exercises in this unit help you become familiar with the main muscle groups and their component muscles. The first exercise introduces you to muscle anatomy. The second exercise focuses on muscle origins and insertions, and the third and final exercise explores muscle actions.

Exercise 10-1

Skeletal Muscles

MATERIALS

- ❑ Muscle models: upper limb, lower limb, trunk, head, neck

In this exercise, we divide skeletal muscles into muscle groups that have similar functions. For example, we classify the latissimus dorsi muscle with the muscles of the upper limb, rather than the muscles of the back or trunk, because it moves the upper limb. We will use the following groupings of skeletal muscles in this unit: muscles that move the head, neck, and face; muscles that move the trunk; muscles that move the scapula; muscles that move the arm; muscles that move the forearm, hand, and fingers; muscles that move the thigh and leg; and muscles that move the foot and toes.

Muscles That Move the Head, Neck, and Face

We can subdivide the muscles that move the head, neck, and face into the muscles of facial expression, the muscles of mastication, and the muscles that move the head and neck. The muscles of facial expression control the various facial expressions humans are capable of making, and they all insert into skin or other muscles (Figs. 10.2 and 10.3). One of the largest muscles of facial expression is the *epicranius muscle* (eh-pih-KRAY-nee-uhs), which elevates the eyebrows and skin of the forehead. The muscle is bipartite, meaning it has two parts. Those parts, the **frontalis** (frun-TAL-iss) and **occipitalis** (awk-sip-ih-TAL-iss) **muscles**, are connected by a sheet of connective tissue called the *epicranial aponeurosis* (ap-oh-noo-ROH-sis). Just inferior to the frontalis muscle are the two circular **orbicularis oculi muscles** (ohr-bik-yoo-LEHR-iss AWK-yoo-lye). Their circular structure enables them to close and squint the eyes.

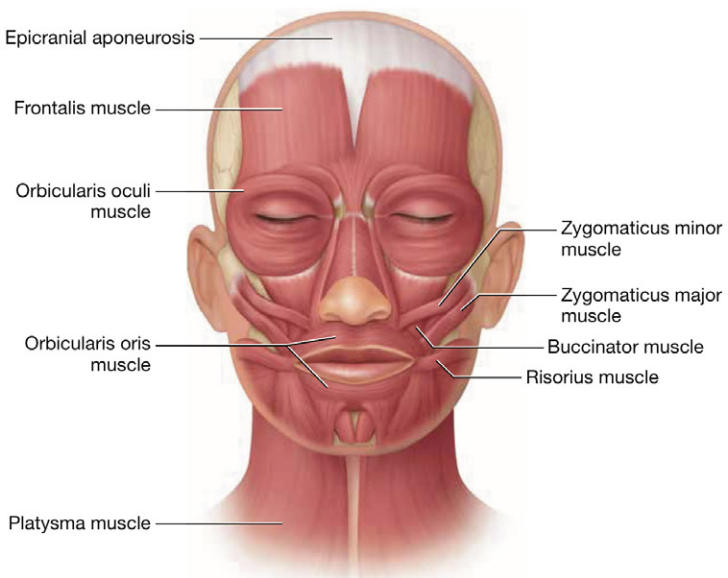

FIGURE **10.2** Facial musculature, anterior view.

Other muscles of facial expression move the lips and skin around the mouth:

- The most obvious muscle around the mouth is the circular **orbicularis oris muscle**, which purses the lips.
- Under the skin of the cheeks we find the **buccinator muscle** (BUK-sin-ay-tur) (remember "buccal" means "cheek"). It pulls the cheeks inward to produce sucking and whistling movements.
- Covering the superficial surface of the neck is broad, flat **platysma muscle** (plah-TIZ-muh). It depresses the mandible (opens the jaw) and tightens the skin of the neck.
- Three muscles are involved in smiling: The **zygomaticus major** and **minor muscles** pull the corners of the mouth superiorly and laterally during smiling while the **risorius muscle** (ry-ZOHR-ee-uhs) pulls the corners of the mouth nearly directly laterally to produce a closed-mouth smile or smirk.

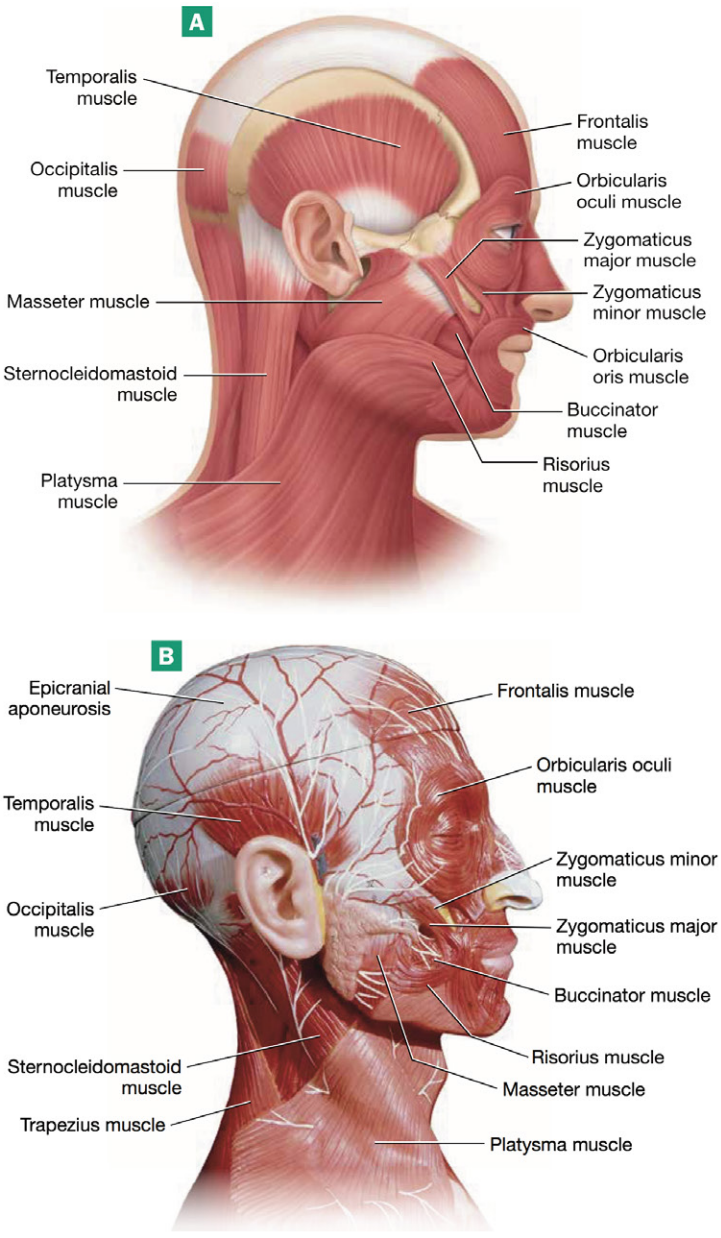

FIGURE **10.3** Muscles of the head and neck, lateral view: (**A**) illustration; (**B**) anatomical model photo.

The **muscles of mastication**, another group of muscles found in the head, are involved in *mastication*, or chewing (Fig. 10.3). They include the thick **masseter muscle** (MASS-uh-tur), located over the lateral mandible, and the fan-shaped **temporalis muscle** (tem-pur-AL-iss), located over the temporal bone.

Several muscles move the head, including the diamond-shaped **trapezius muscle** (trah-PEE-zee-uhs) on the back, which holds the head upright and hyperextends the head and the neck (best seen in Figure 10.9A, p. 264). In the neck we find the strap-like **sternocleidomastoid muscle** (stern-oh-kly-doh-MASS-toy'd). When the two muscles contract together, they flex the head and neck. Acting individually, each muscle rotates the head toward the opposite side and flexes the head and neck laterally. On the posterior neck, two muscles called the **splenius capitis** (SPLEN-ee-uhs CAP-it-uhs) and **splenius cervicis muscles** (SIR-vih-sis) extend and hyperextend the head and neck (Fig. 10.4).

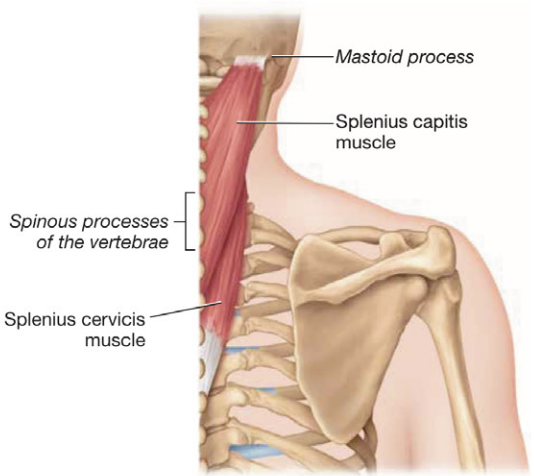

FIGURE **10.4** Splenius muscles of the neck.

Muscles That Move the Trunk

The muscles that move the trunk include the muscles of the thorax, muscles of the abdominal wall, and postural muscles of the back.

1. The muscles of the thorax are generally involved in the muscle movements that produce ventilation: the **external** and **internal intercostal muscles** are located between the ribs and are involved in both inspiration and expiration, respectively (Fig. 10.5); the dome-shaped **diaphragm muscle** (DY-uh-fram) produces the movements necessary for inspiration; and the small **pectoralis minor muscle** draws the scapula anteriorly and the rib cage superiorly during forced inspiration and expiration (Fig. 10.6).

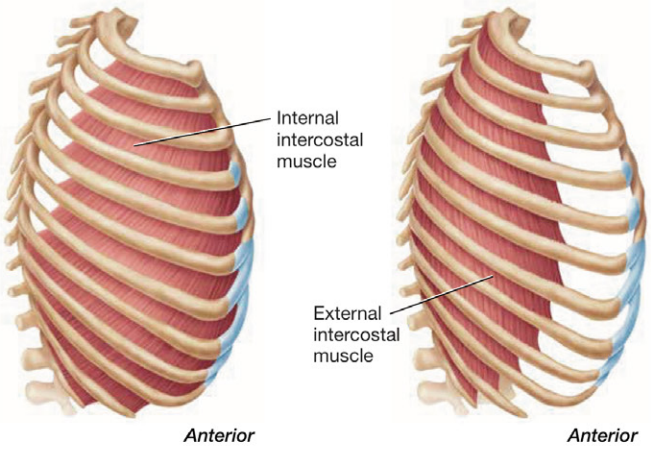

FIGURE **10.5** Internal and external intercostal muscles, lateral view.

2. The abdominal muscles move the trunk and increase intra-abdominal pressure (Figs. 10.7 and 10.8). The **rectus abdominis muscle** is the central and superficial muscle that flexes the trunk. It is covered by a thick layer of connective tissue called the *rectus sheath*. On the lateral torso we find the **external** and **internal oblique muscles**, which rotate and laterally flex the trunk. Deep to all three muscles, the **transversus abdominis muscle** squeezes the abdominal contents like a belt to increase intra-abdominal pressure.

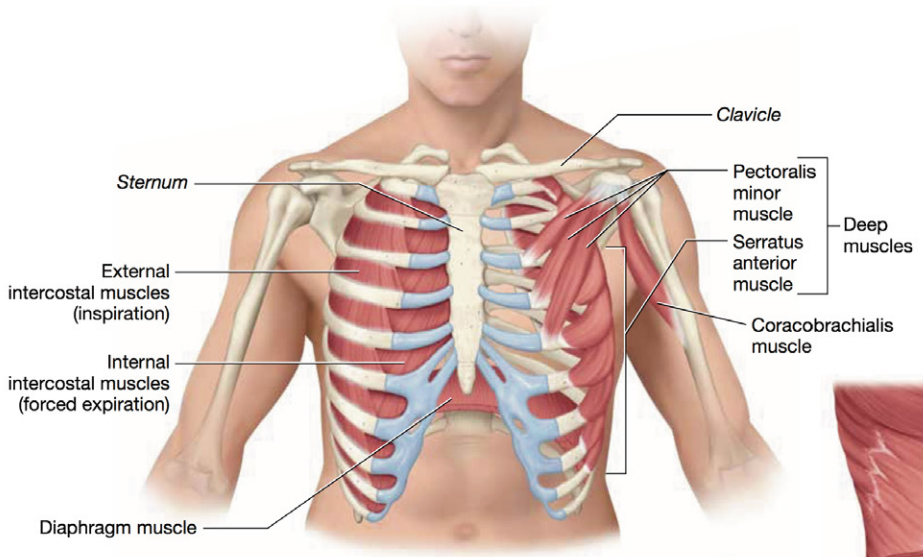

FIGURE **10.6** Deep muscles of the anterior thorax.

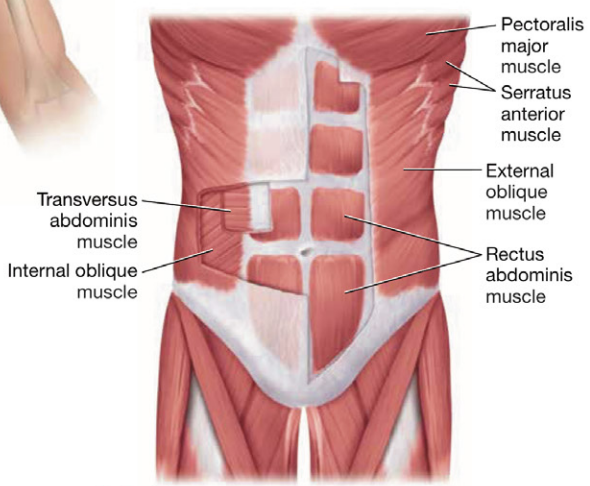

FIGURE **10.7** Anterior view of the abdominal muscles.

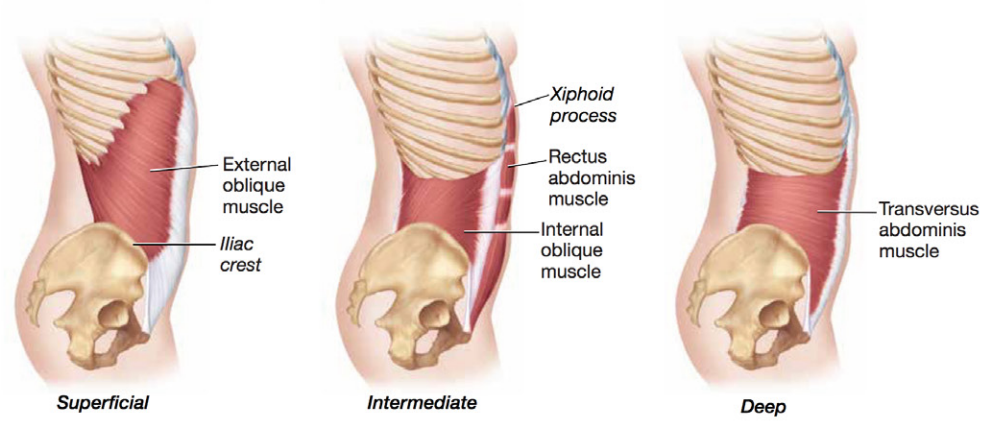

FIGURE **10.8** Lateral view of the individual abdominal muscles.

3. The postural muscles of the back work to ensure that we remain upright. Most of these postural muscles also extend the back. One of the main postural muscles is a group known collectively as the **erector spinae muscle** (eh-REK-tohr SPY-nee). The three components of the erector spinae muscle include the lateral **iliocostalis** (ill-ee-oh-kawst-AL-iss), the middle **longissimus** (lawn-JISS-ih-muss), and the medial **spinalis muscles** (spy-NAL-iss) (Fig. 10.9). Another postural muscle group is the *transversospinal group*, which runs along the vertebral column and includes the *multifidus* and *semispinalis muscles*. A final postural muscle is the deep *quadratus lumborus muscle* in the lumbar region of the back.

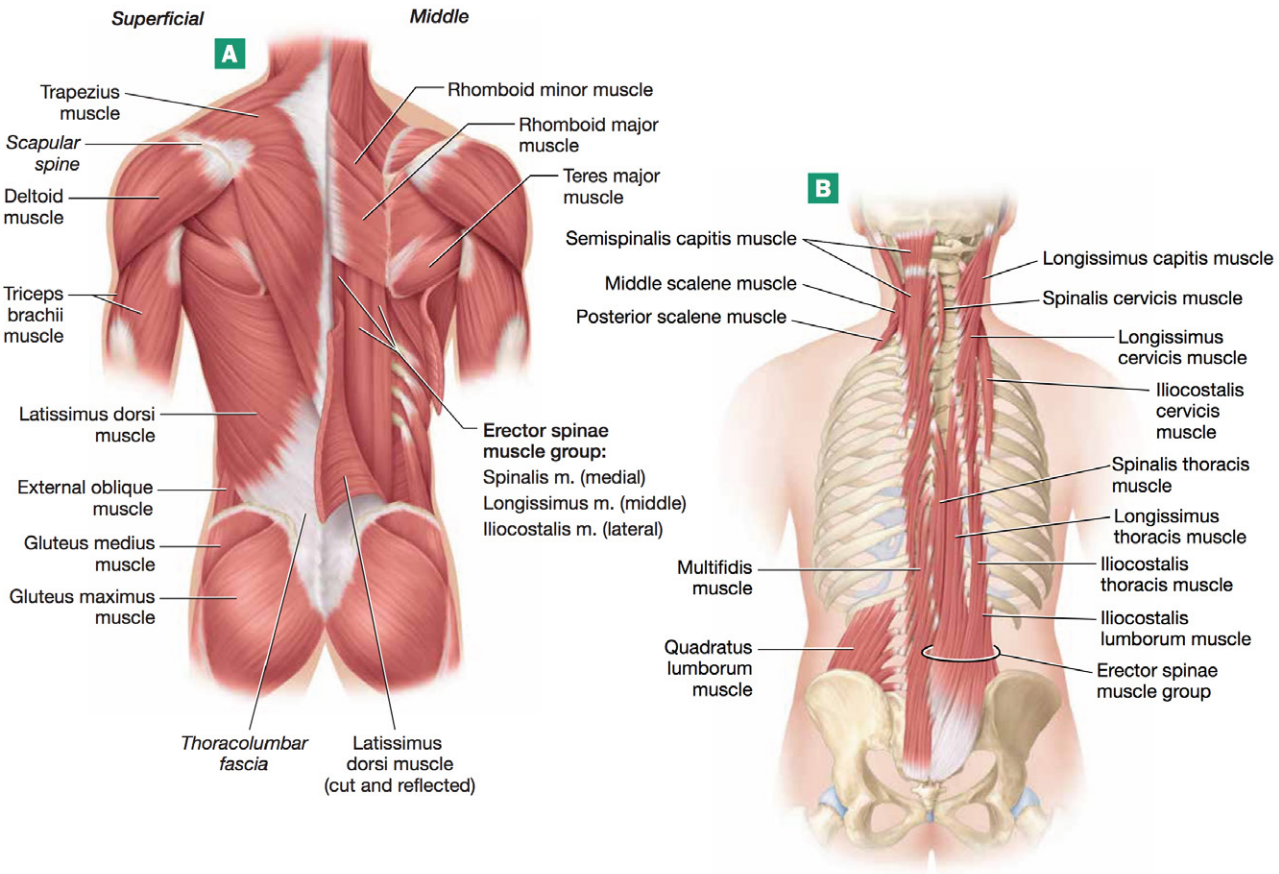

FIGURE **10.9** Muscles of the trunk, posterior view: (**A**) superficial and middle dissection; (**B**) deep dissection.

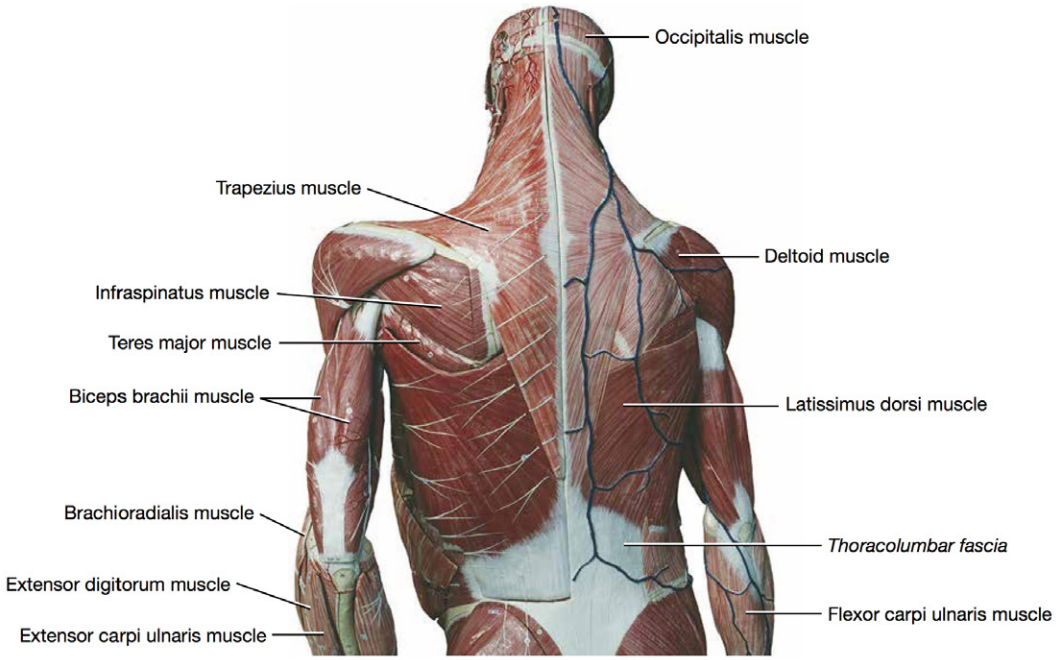

FIGURE **10.10** Anatomical model photo of muscles of the trunk, posterior view.

Muscles That Move the Scapula

The **serratus anterior muscle** (ser-AY-tuhs), located on the lateral thorax, pulls the scapula anteriorly, protracting it (as in when throwing a punch) and rotating it superiorly (as in when doing a bench press; see Figures 10.6 and 10.7). On the posterior neck and back is the **trapezius muscle**, which due to its multiple insertions on the scapula has several actions, including elevation, retraction, and protraction. Deep to the trapezius are the **rhomboid major** and **rhomboid minor muscles**, both of which retract the scapula (see Fig. 10.9).

Muscles That Move the Arm

As you learned in the articulations unit, the shoulder joint has the greatest range of motion of any joint in the body. For this reason, there are many muscles acting on it, both to move the arm and to stabilize the joint. Some of these muscles include:

- The posterior **latissimus dorsi muscle** (lah-TISS-ih-muss DOHR-sye) is the prime muscle of arm extension, and it also adducts and rotates the arm. It is assisted in its actions by the **teres major muscle** on the posterior scapula (Figs. 10.9 and 10.10).
- The **pectoralis major muscle**, or "chest muscle," is the prime muscle of arm flexion, and it also adducts the arm (Fig. 10.11). It is assisted by the *coracobrachialis muscle* on the proximal humerus.
- The **deltoid muscle**, or "shoulder muscle," is the prime abductor of the arm, and assists in both flexion and extension (Fig. 10.11).
- The **rotator cuff muscles**, visible in Figure 10.12, reinforce the capsule of the shoulder joint to prevent dislocation of the humerus from the scapula. They include the **infraspinatus muscle** (in-frah-spin-AY-tuhs), which is inferior to the scapular spine; **teres minor muscle** (TEHR-eez), which is superior to the teres major muscle; the **supraspinatus muscle** (soo-prah-spin-AY-tuhs), which is superior to the scapular spine; and the **subscapularis** muscle, which is on the anterior surface of the scapula (sub-skap-yoo-LEHR-uhs; see Figure 9.7, p. 241).

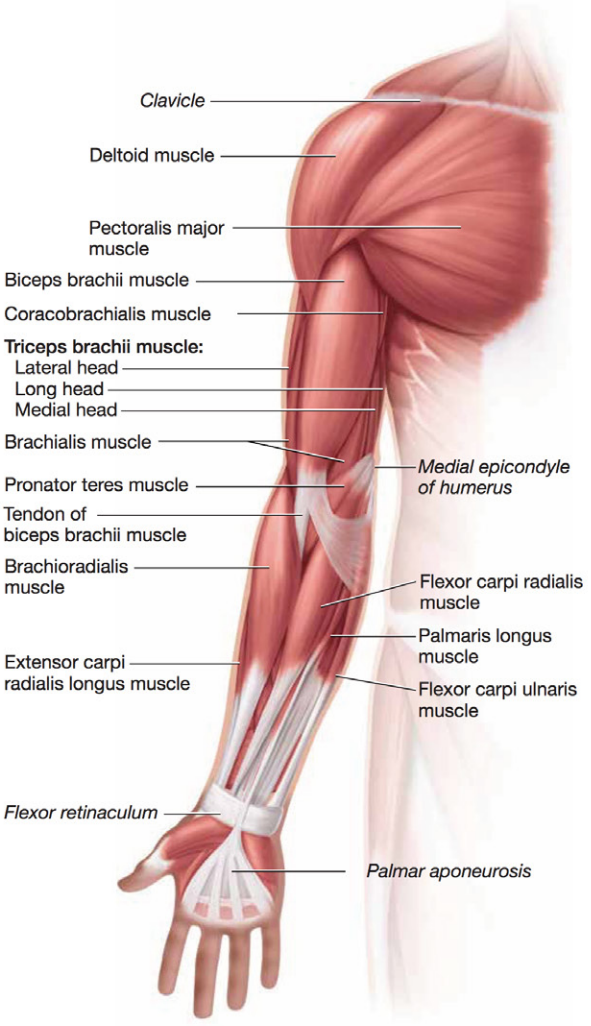

FIGURE **10.11** Anterior view of the muscles of the right upper limb.

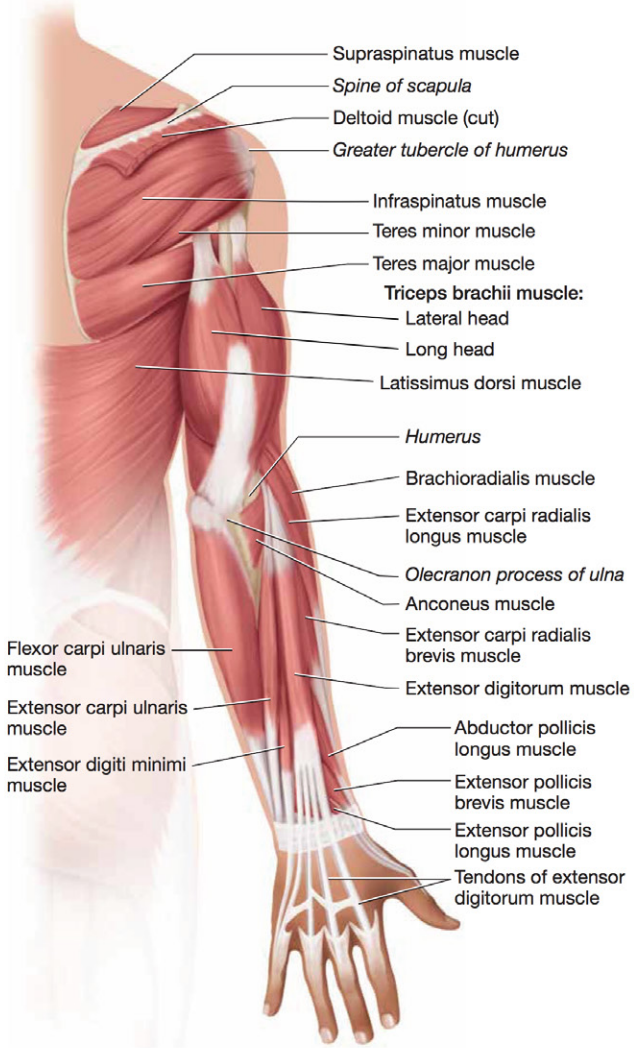

FIGURE **10.12** Posterior view of the muscles of the right upper limb.

Muscles That Move the Forearm, Hand, and Fingers

The four main muscles that move the forearm are the anterior **biceps brachii** (BY-seps BRAY-kee-aye), the anterior and deep **brachialis** (bray-kee-AL-iss), the anterior and lateral **brachioradialis** (bray-kee-oh-ray-dee-AL-iss), and the posterior **triceps brachii muscles** (Figs. 10.11 and 10.12). The first three muscles flex the forearm, while the triceps brachii extends the forearm.

The remainder of the muscles of the upper limb act on the hand at the wrist, the hand itself (the *intrinsic hand muscles*), and/or the digits. Muscles that flex the hand, located on the anterior forearm, are the **flexor carpi radialis** (KARP-aye ray-dee-AL-iss), **flexor carpi ulnaris** (uhl-NEHR-iss), **flexor digitorum superficialis**, and **flexor digitorum profundus muscles** (Fig. 10.13). As implied by their names, the flexor digitorum superficialis and flexor digitorum profundus muscles also flex the digits. Muscles that extend the hand, located on the posterior forearm, are the **extensor carpi radialis longus**, **extensor digitorum**, and **extensor carpi ulnaris muscles** (Fig. 10.14). The extensor digitorum also extends the digits. Other muscles that move the hand and digits are labeled in Figures 10.13 and 10.14 for your reference.

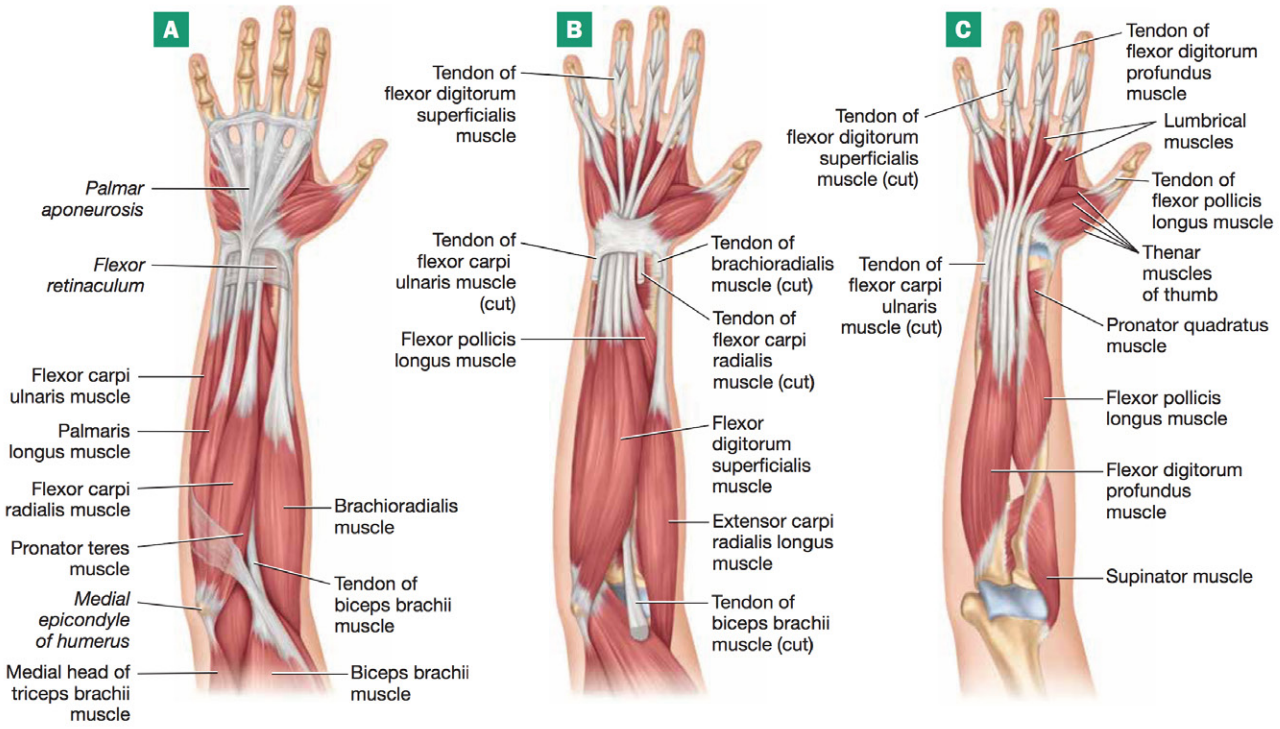

FIGURE **10.13** Muscles of the anterior right forearm: (A) superficial muscles; (B) intermediate muscles; (C) deep muscles.

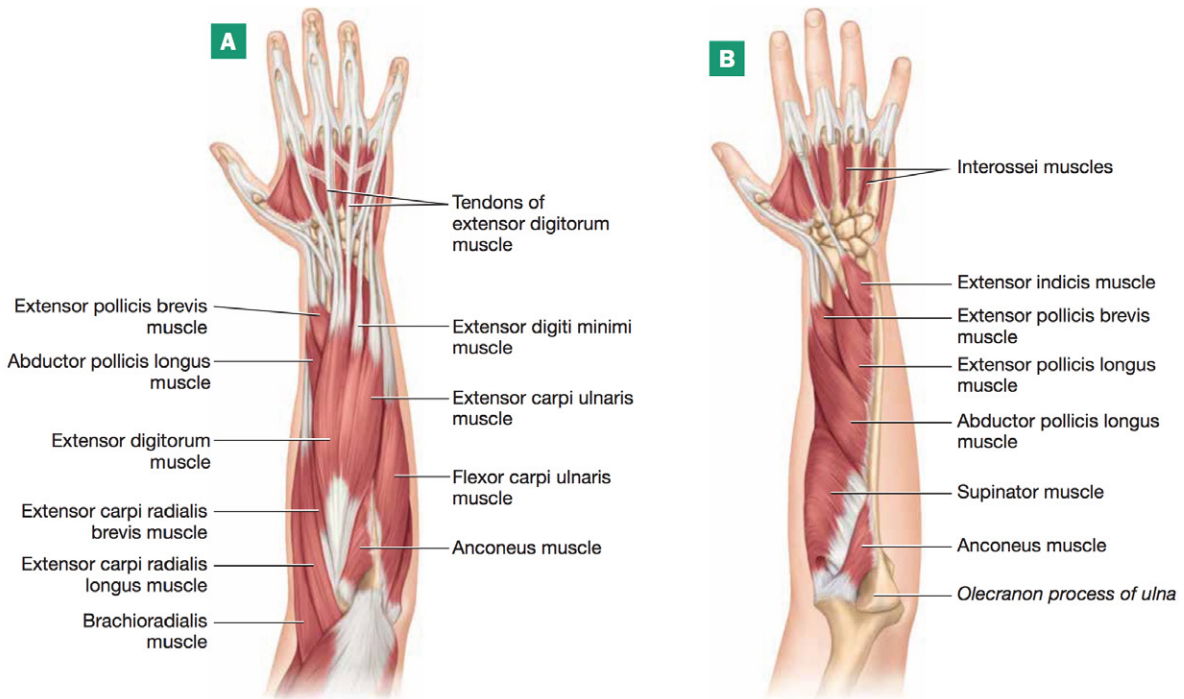

FIGURE **10.14** Muscles of the posterior right forearm: (A) superficial muscles; (B) deep muscles.

Muscles that Move the Thigh and Leg

We can divide muscles that move only the thigh into three groups:

- The *gluteal muscles* consist of three muscles on the posterior pelvis. The large, superficial **gluteus maximus muscle** is the prime extensor of the thigh (Fig. 10.15). The **gluteus medius muscle** (MEE-dee-uhs), which is deep to the gluteus maximus muscle, is a major abductor of the thigh. The small, deep *gluteus minimus muscle* assists the gluteus medius muscle in its actions. (Other deep muscles of the gluteal region are illustrated in Figure 10.15 for your reference.)
- As implied by their names, the muscles in the *adductor group*, located on the medial femur, are the prime adductors of the thigh (Fig. 10.16). This group includes the superior **adductor brevis**, the inferior **adductor longus**, and the deep, broad **adductor magnus muscles**.
- The **iliopsoas muscle** (ill-ee-oh-SOH-uhs) is composed of two parts—the *iliacus muscle* (ill-ee-AK-uhs), originating from the iliac fossa of the ilium, and the *psoas major muscle*, originating from the lumbar vertebrae (Fig. 10.17). The two muscles come together to form the iliopsoas muscle, which inserts via a common tendon into the lesser trochanter of the femur. The iliopsoas muscle is the prime flexor of the thigh and is assisted by the **pectineus muscle** (pek-TIN-ee-uhs) in the proximal thigh.

10

The remainder of the thigh muscles may move both the thigh and leg, or just the leg. One of the most prominent groups of thigh muscles is located in the anterior thigh and is known as the **quadriceps femoris group**. It includes the **rectus femoris, vastus medialis, vastus intermedius,** and **vastus lateralis muscles**. These four muscles converge to form the common quadriceps femoris or patellar tendon, which envelops the patella. Distal to the patella, the tendon becomes the *patellar ligament*, and inserts into the tibial tuberosity. Note that the vastus intermedius muscle is deep to the rectus femoris muscle and so is not visible in Figure 10.17. The rectus femoris muscle both flexes the thigh and extends the leg, but the vastus group doesn't cross the hip joint and so only extends the leg.

Other prominent thigh muscles include the strap-like **sartorius muscle** (sar-TOHR-ee-uhs), which crosses from lateral to medial across the thigh, and the medial **gracilis muscle** (gruh-SILL-iss). Both of these muscles have the dual action of flexing the thigh and extending the leg. The sartorius muscle also laterally rotates the thigh (it pulls your leg and thigh into the position you assume when you're looking at something on the bottom of your shoe). The posterior thigh muscles include the three muscles of the **hamstrings group:** the lateral **biceps femoris** and the medial **semitendinosus** (sem-aye-ten-din-OH-suhs) and **semimembranosus**

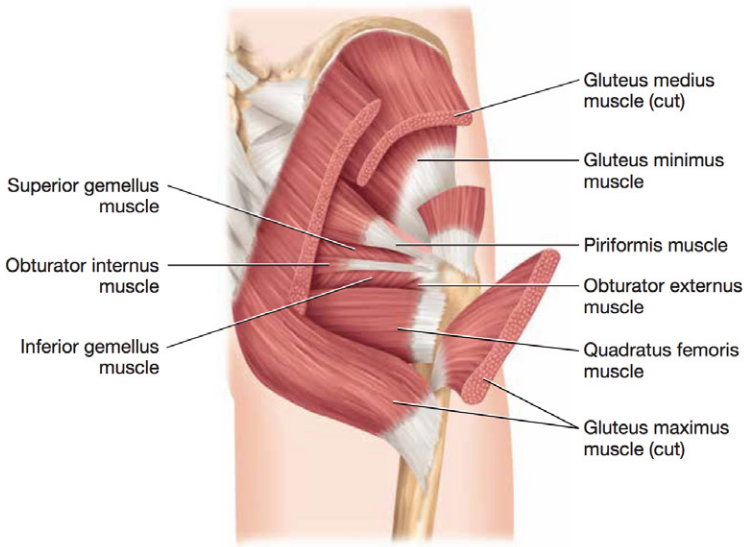

FIGURE **10.15** Deeper muscles of the gluteal region.

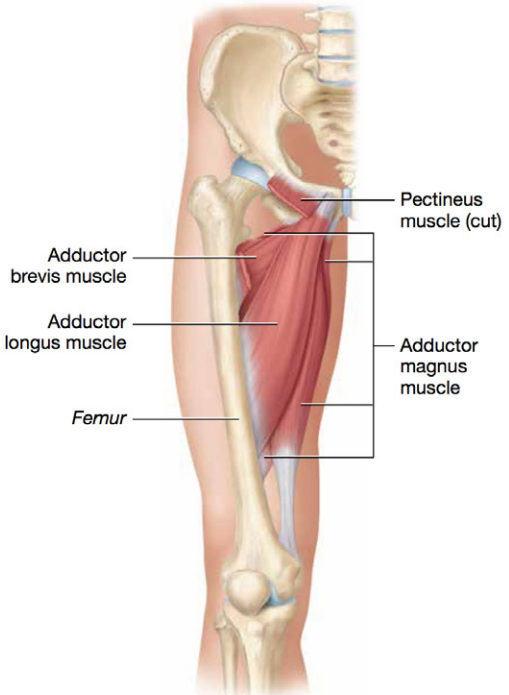

FIGURE **10.16** Muscles of the adductor muscle group.

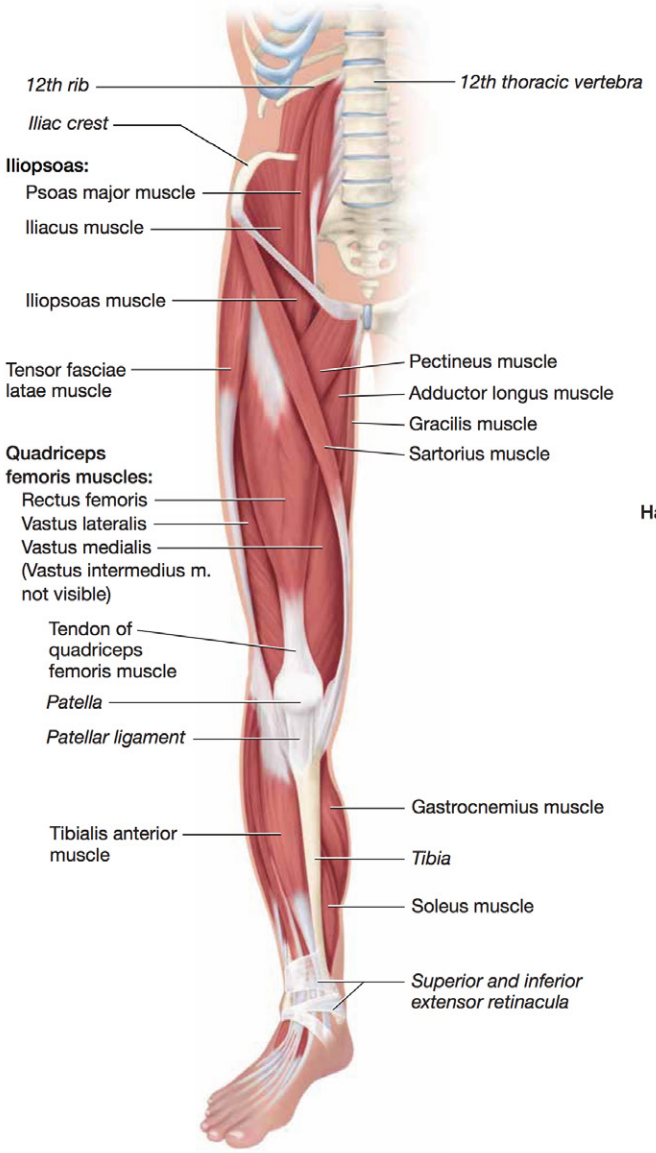

FIGURE **10.17** Muscles of the right lower limb, anterior view.

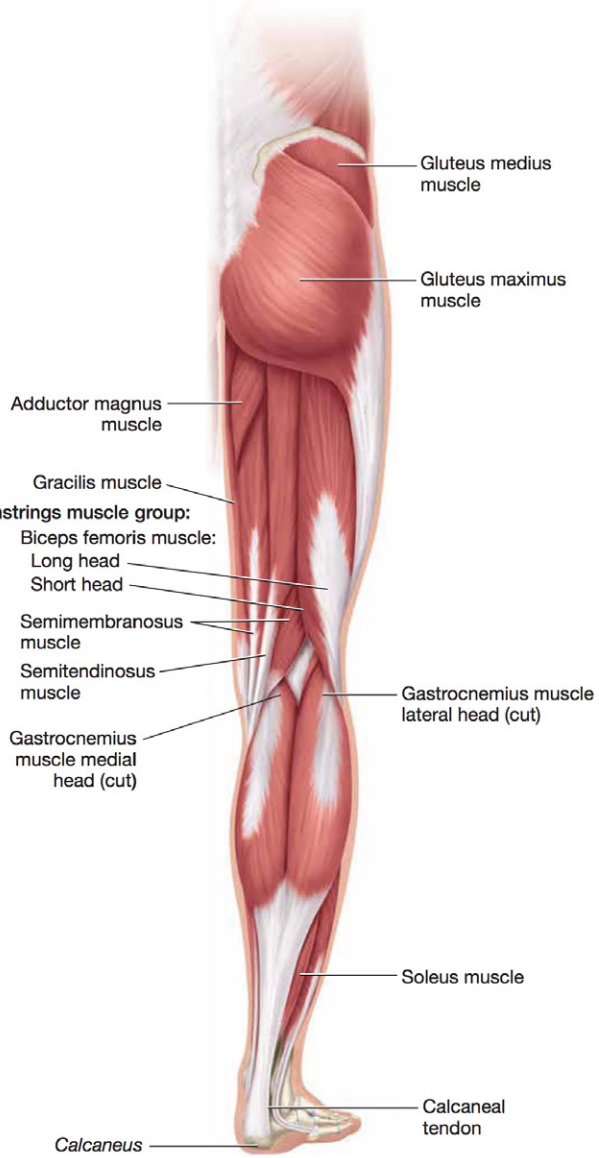

FIGURE **10.18** Muscles of the right lower limb, posterior view.

(sem-aye-mem-brah-NOH-suhs) **muscles** (Fig. 10.18). Notice in the figure that the superficial semitendinosus muscle is named for its long, narrow tendon. These three muscles both extend the thigh and flex the knee.

Muscles That Move the Foot and Toes

The most obvious muscle of the posterior leg is the large **gastrocnemius** muscle (gas-trawk-NEE-mee-uhs), also known as the "calf muscle," a two-headed muscle that originates from the distal femur. Just deep to the gastrocnemius muscle is the **soleus** muscle (SOHL-ee-uhs). Together, these two muscles insert into the posterior calcaneus via a common tendon called the **calcaneal tendon** (kal-KAY-nee-uhl), more commonly known as the *Achilles tendon*. The gastrocnemius and soleus muscles, also known as the *triceps surae muscle*, are the prime plantarflexors of the foot. The gastrocnemius also contributes to flexion of the leg, as it crosses the knee joint.

Deep to the triceps surae muscle is the **tibialis posterior muscle** (tib-ee-AL-is), the main inverter of the foot, as well as the muscles that plantarflex the foot and the digits (Fig. 10.18). On the lateral leg we find two muscles, the **fibularis longus** (fib-yoo-LEHR-iss) and **fibularis brevis muscles,** the main everters of the foot. Anteriorly on the leg we find extensors such as the **extensor digitorum longus,** which extends the toes, and the **tibialis anterior,** which dorsiflexes the foot. These and other leg muscles are labeled in Figures 10.19 and 10.20 for reference purposes.

Figures 10.21 and 10.22 provide whole-body views of many of the muscles we have just discussed. Other muscles and anatomical landmarks are labeled to help orient you and for your reference.

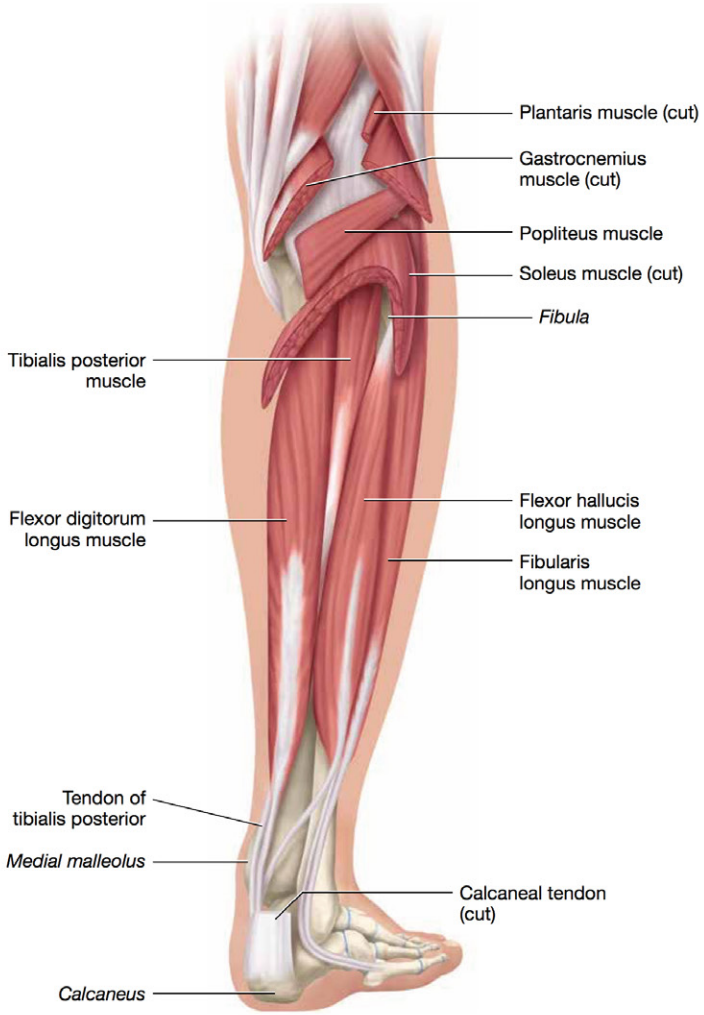

FIGURE **10.19** Deep muscles of the posterior leg.

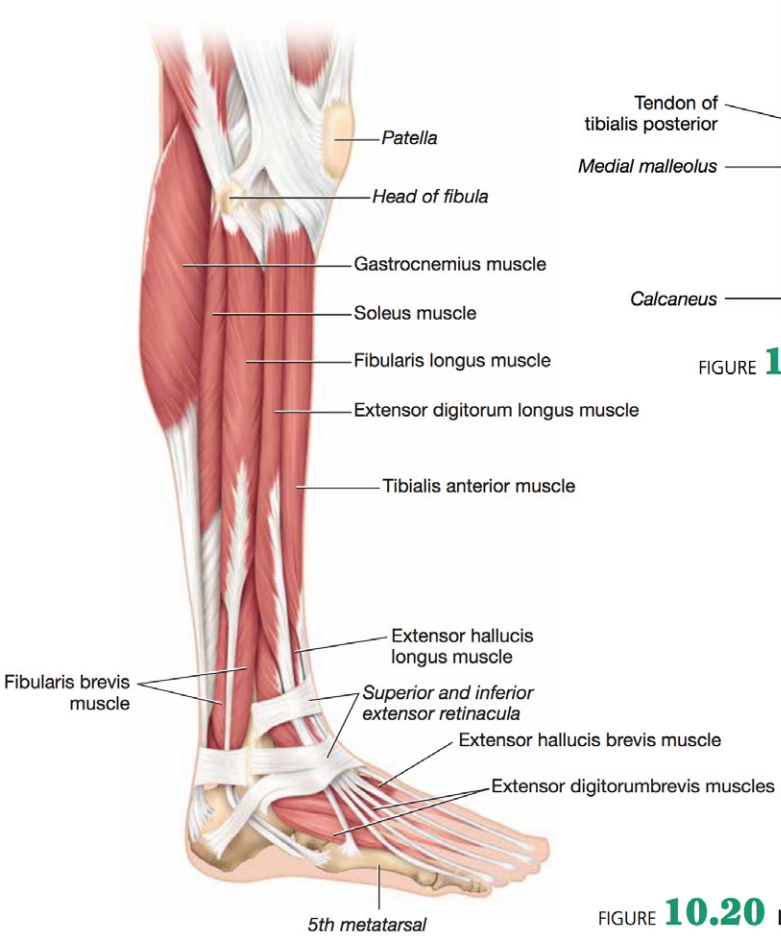

FIGURE **10.20** Lateral view of muscles of the leg.

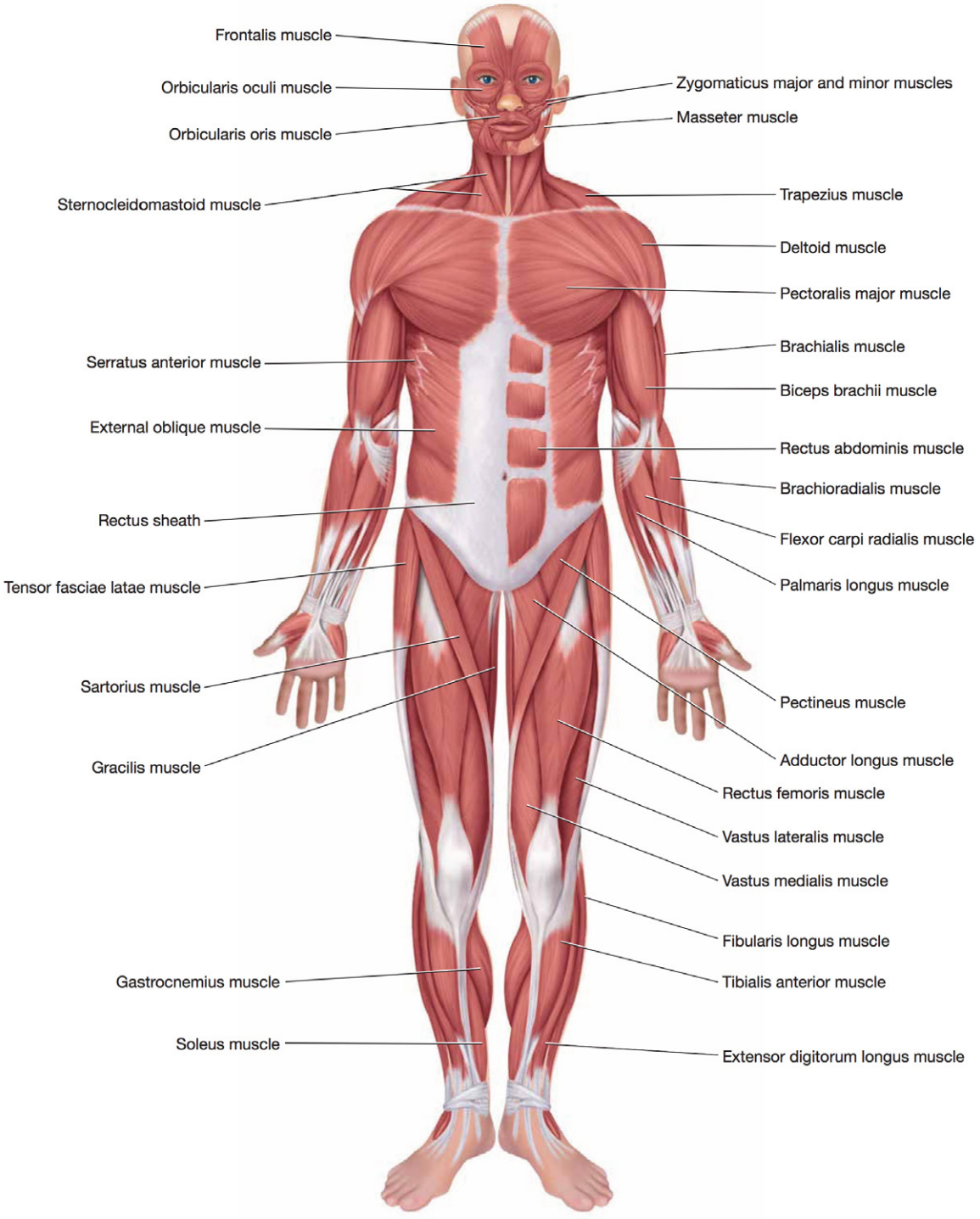

FIGURE **10.21** Muscles of the body, anterior view.

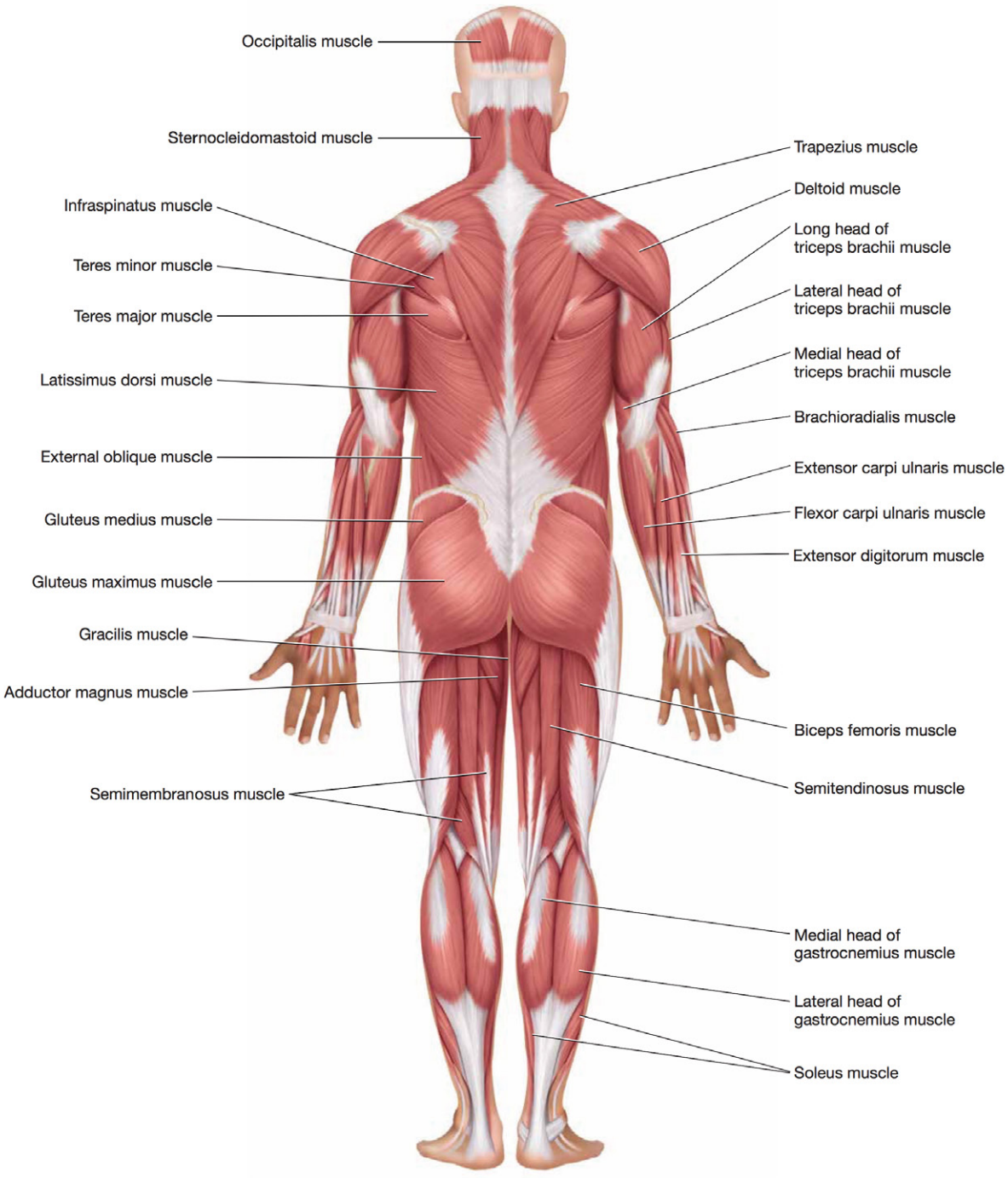

FIGURE **10.22** Muscles of the body, posterior view.

HINTS & TIPS

Muscle Names

What's in a name? When it comes to a skeletal muscle, there's often a lot. The number of muscles that we cover in this lab may seem intimidating, but it can be easier to figure out a muscle's location or actions than you may think. This is because many muscles have very descriptive names, which you may have noticed from your reading of the preceding section. Some of the common features used in muscle names include the following:

- **Size.** Many muscle names include clues about their size. Some of these are obvious—*longus* describes a long muscle, and a pair of *major* and *minor* muscles describes a set in which one is larger and one is smaller. Others are a little less obvious, such as *brevis*, which means short (think "brief"), or *vastus*, which means wide (think "vast").
- **Location.** A great many muscles are named for their location. This can include directional terms, such as *lateralis*, *superficialis*, or *anterior*. It can also include regional terms such as *abdominis*, *cervicis* (neck), *brachii* (arm), and *costal* (rib). Finally, some of the terms that describe location use words or prefixes with which you're likely already familiar such as *sub-* (below) and profundus (*deep*—think "profound").
- **Appearance or shape.** Several muscles have names based on their appearance or shape. For example, the semitendinosus muscle has a very long tendon, and the rhomboid major and minor muscles are shaped like a rhombus. Similarly, the orbicularis oris and orbicularis oculi muscles are named for their circular structure, as "orb" means "sphere."
- **Points of origin.** Related to appearance is a muscle's number of points of origin, or "heads." We see this with muscles named *biceps*, *triceps*, and *quadriceps*, which mean "two-headed," "three-headed," and "four-headed," respectively.
- **Function.** Finally, the function of many muscles is revealed in their names. As you can imagine, an *extensor* has extension as a primary action, and an *adductor* has adduction as a primary action.

When you take all of this into consideration, it's much easier to figure out the location, appearance, and, occasionally, function of complicated-sounding muscles. For example, if you are tasked with identifying the brachioradialis muscle, just from its name you can infer that it is a muscle that attaches to the arm (brachio-) and the radius (radialis). Similarly, the tibialis anterior muscle is clearly a muscle on the anterior tibia, and the iliocostalis muscle has attachments to the ilium and the ribs. If we take a more complicated muscle name, such as the extensor carpi radialis longus muscle, we can say that it is a long muscle that originates from the radius, inserts into the carpals, and extends the hand at the wrist. See? It's not as difficult as you thought.

Procedure 1 Model Inventory for the Skeletal Muscles

Identify the following muscles on models and diagrams, using your textbook and this unit for reference. As you examine the anatomical models and diagrams, record the name of the model and the structures you were able to identify on the model inventory in Table 10.2. When you have completed the activity, answer Check Your Understanding questions 1 through 3 (p. 287).

Muscles That Move the Head, Neck, and Face

1. Muscles of facial expression
   a. Frontalis m.
   b. Occipitalis m.
   c. Orbicularis oculi m.
   d. Orbicularis oris m.
   e. Buccinator m.
   f. Platysma m.
   g. Zygomaticus major and minor mm.
   h. Risorius m.
2. Muscles of mastication
   a. Masseter m.
   b. Temporalis m.
3. Muscles of head and neck
   a. Sternocleidomastoid m.
   b. Splenius capitis m.
   c. Splenius cervicis m.

Muscles That Move the Trunk

1. Muscles of the thorax
   a. External intercostal mm.
   b. Internal intercostal mm.
   c. Diaphragm m.
   d. Pectoralis minor m.
2. Muscles of the abdominal wall
   a. Rectus abdominis m.
   b. External oblique m.
   c. Internal oblique m.
   d. Transversus abdominis m.
3. Postural muscles of the back
   a. Erector spinae m.
      (1) Iliocostalis m.
      (2) Longissimus m.
      (3) Spinalis m.

Muscles That Move the Scapula

1. Serratus anterior m.
2. Trapezius m.
3. Rhomboid major and minor mm.

Muscles That Move the Arm

1. Latissimus dorsi m.
2. Teres major m.
3. Pectoralis major m.
4. Deltoid m.
5. Rotator cuff muscles
   a. Infraspinatus m.
   b. Teres minor m.
   c. Supraspinatus m.
   d. Subscapularis m.

Muscles That Move the Forearm and Hand

1. Muscles of the arm
   a. Biceps brachii m.
   b. Brachialis m.
   c. Brachioradialis m.
   d. Triceps brachii m.
2. Flexors of the forearm
   a. Flexor carpi radialis m.
   b. Flexor carpi ulnaris m.
   c. Flexor digitorum superficialis m.
   d. Flexor digitorum profundus m.
3. Extensors of the forearm
   a. Extensor carpi radialis longus m.
   b. Extensor digitorum m.
   c. Extensor carpi ulnaris m.

10

Muscles That Move the Thigh and Leg

1. Muscles that move the thigh only
   a. Gluteus maximus m.
   b. Gluteus medius m.
   c. Adductor brevis m.
   d. Adductor longus m.
   e. Adductor magnus m.
   f. Iliopsoas m.
   g. Pectineus m.
2. Muscles that move the thigh and the leg
   a. Quadriceps femoris group
      (1) Rectus femoris m.
      (2) Vastus medialis m.
      (3) Vastus intermedius m.
      (4) Vastus lateralis m.
   b. Sartorius m.
   c. Gracilis m.
   d. Hamstrings group
      (1) Biceps femoris m.
      (2) Semitendinosus m.
      (3) Semimembranosus m.

Muscles That Move the Foot and Toes

1. Gastrocnemius m.
2. Soleus m.
3. Tibialis posterior m.
4. Fibularis longus m.
5. Fibularis brevis m.
6. Extensor digitorum longus m.
7. Tibialis anterior m.

Your instructor may wish to omit certain muscles included above or add muscles not included in these lists. List any additional structures below:

TABLE **10.2** Model Inventory for Skeletal Muscles

Model/Diagram	Structures Identified

Exercise 10-2

Muscle Origins, Insertions, and Actions

MATERIALS

- ❑ Small skeletons
- ❑ Modeling clay in five colors

Before you can fully understand a muscle's actions, you must understand a muscle's origin and insertion. As we discussed in the introduction to this unit, the **origin** of a muscle generally is the more stationary part, and the muscle typically **inserts** into the part that it moves. For example, you can see in Figure 10.23 that the biceps brachii muscle originates on the coracoid process of the scapula and crosses the elbow joint, where it inserts into the radial tuberosity. Notice also that the triceps brachii muscle originates from the humerus and the inferior scapula and crosses the elbow joint to insert into the olecranon process.

Once you determine a muscle's origin and insertion, figuring out its actions becomes easy. Let's examine the biceps brachii and triceps brachii muscles again. The biceps brachii muscle inserts into the radial tuberosity, so we know it will move the forearm. Given how it crosses the anterior elbow joint, we can conclude it will cause forearm *flexion* at the elbow joint. The triceps brachii muscle inserts into the olecranon process, so we know it also will move the forearm. Given how it crosses the posterior elbow joint, we can conclude that it will cause forearm *extension* at the elbow joint. Now wasn't that easy? So you don't need to actually memorize most muscle actions—all you need to do is look at a muscle's origin and insertion and use some basic logic to figure out its actions. We practice doing this in the next two procedures.

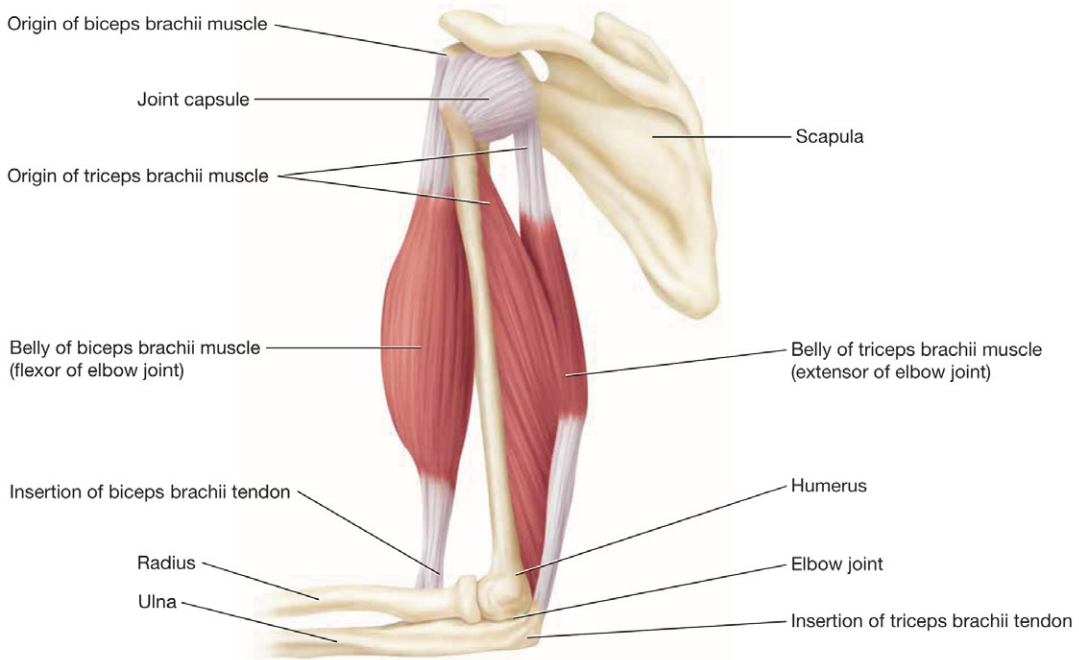

FIGURE **10.23** Origin and insertion of the biceps brachii and triceps brachii muscles, posterior view.

Procedure 1 Build Muscles

In this exercise you will use small skeletons and modeling clay to build specific muscle groups. This may sound easy, but there is a catch: You must determine the actions of the muscle by looking only at the origin and insertion of each muscle you build. Use Pre-Lab Exercise 10-3 (p. 259) as a guide to each muscle's origin and insertion. When you have finished the activity, answer Check Your Understanding questions 4 and 5 (pp. 287–288).

1. Obtain a small skeleton and five colors of modeling clay.
2. Build the indicated muscles, using a different color of clay for each muscle. As you build, pay careful attention to the origin and insertion of each muscle.
3. Determine the primary actions for each muscle you have built by looking *only* at the origin and insertion. Record this information in Tables 10.3 through 10.5.

TABLE **10.3** Muscles and Actions for Group 1

Muscle	Actions
Biceps femoris m.	
Rectus femoris m.	
Gluteus medius m.	
Adductor m. group	

TABLE **10.4** Muscles and Actions for Group 2

Muscle	Actions
Biceps brachii m.	
Triceps brachii m.	
Deltoid m.	
Pectoralis major m.	

TABLE **10.5** Muscles and Actions for Group 3

Muscle	Actions
Gastrocnemius m.	
Tibialis anterior m.	
Rectus abdominis m.	
Trapezius m.	

Procedure 2 Identifying Muscle Actions of Common Movements

This procedure should look familiar, because you did a similar exercise in Unit 9 (Articulations, p. 225). As before, you will be performing various activities to demonstrate which joints are moving with each activity. In this exercise, however, rather than focusing on the motions that occur at each joint, you will be determining *which muscles* are causing the motions at each joint. Following is an example:

Walking in Place

Part 1

First list all motions occurring at each joint (as before, the joints are listed with their common names, and the lists are certainly *not* all-inclusive):

- Vertebral column and neck: extension
- Shoulder: flexion/extension
- Elbow: flexion
- Hip: flexion/extension, abduction/adduction
- Knee: flexion/extension
- Ankle: dorsiflexion/plantarflexion, inversion/eversion

Part 2

Now refer to Table 10.1 in Pre-Lab Exercise 10-3 (p. 259) to determine which muscles are causing each joint to move. Please note that these lists are far from complete. With nearly 700 muscles in the human body, a complete list could take all day!

- Vertebral column and neck
  - Extension: erector spinae and trapezius muscles
- Shoulder
  - Flexion: pectoralis major muscle
  - Extension: latissimus dorsi muscle

- Elbow
  - Flexion: biceps brachii, brachialis, and brachioradialis muscles
- Hip
  - Flexion: iliopsoas, sartorius muscles
  - Extension: biceps femoris, semitendinosus, semimembranosus, and gluteus maximus muscles
  - Abduction: tensor fasciae latae, sartorius, and gluteus medius muscles
  - Adduction: gracilis and adductor muscles
- Knee
  - Flexion: biceps femoris, semitendinosus, semimembranosus, and gastrocnemius muscles
  - Extension: rectus femoris, vastus medialis, vastus intermedius, and vastus lateralis muscles
- Ankle
  - Dorsiflexion: tibialis anterior muscle
  - Plantarflexion: gastrocnemius and soleus muscles
  - Inversion: tibialis anterior and tibialis posterior muscles
  - Eversion: fibularis brevis and fibularis longus muscles

Okay, so now you're thinking, "Wow, that's a lot of work!" Following are a few hints that will make this task less daunting:

- You will notice that the following activities are the same as the activities from Exercise 9-3 (p. 238) in Unit 9. To save yourself some work, reference that exercise to complete Part 1 of this exercise.
- As before, perform the indicated activity. If you don't, you'll miss some things.
- Unless your instructor asks you to do otherwise, try to keep it simple. List only the main muscles for each action. For example, when listing the muscles to flex the hip, we easily could include 10 different muscles. To make it simpler, list only those muscles we discussed that flex the hip as their primary action (as in the example on this page).

Ready to give it a try? Determine the joints being moved for Part 1, and then determine the muscles moving the joints for Part 2. Refer to Unit 9 (p. 225) for help. When you have completed the activity answer Check Your Understanding question 6 (p. 288).

1 Walking up the stairs

Part 1:

Part 2:

2 Doing jumping jacks

Part 1:

Part 2:

3 Answering the telephone

Part 1:

Part 2:

4 Jumping rope

Part 1:

Part 2:

Name _____

Section _____ Date _____

Check Your Recall

REVIEW

1 Label the following muscles on Figure 10.24.

- ❑ Buccinator m.
- ❑ Frontalis m.
- ❑ Masseter m.
- ❑ Orbicularis oculi m.
- ❑ Orbicularis oris m.
- ❑ Platysma m.
- ❑ Risorius m.
- ❑ Sternocleidomastoid m.
- ❑ Temporalis m.
- ❑ Zygomaticus major m.

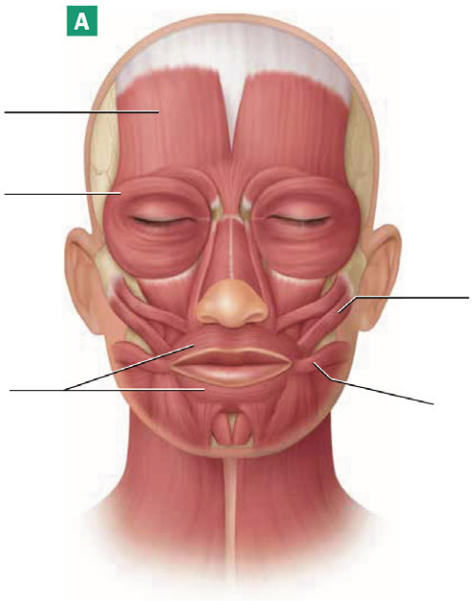

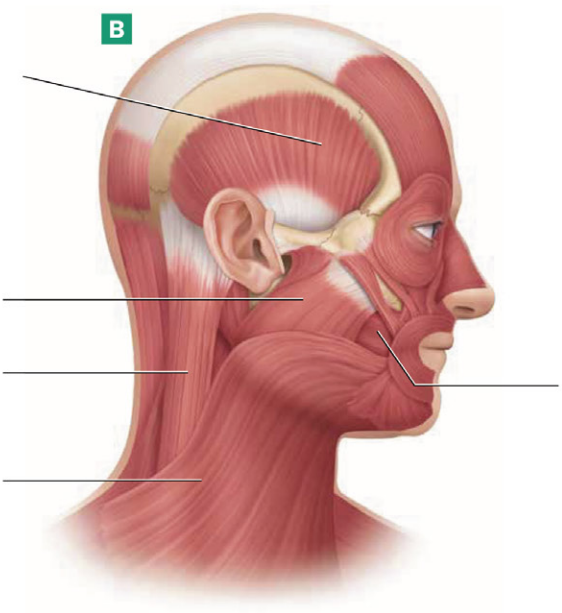

FIGURE **10.24** Facial musculature, anterior and lateral views.

2 Label the following muscles on Figure 10.25.

- ❑ Diaphragm m.
- ❑ External intercostal m.
- ❑ External oblique m.
- ❑ Internal intercostal m.
- ❑ Internal oblique m.
- ❑ Pectoralis minor m.
- ❑ Rectus abdominis m.
- ❑ Serratus anterior m.
- ❑ Transversus abdominis m.

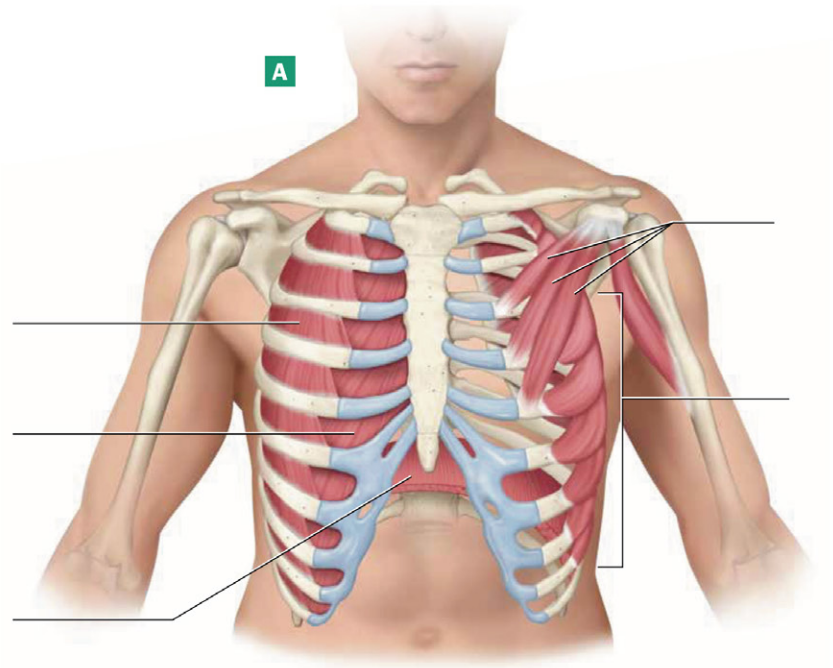

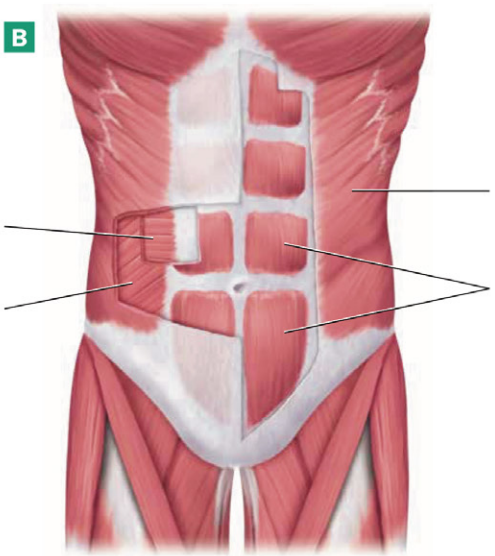

FIGURE **10.25** Muscles of the trunk, anterior view.

Name _____

Section _____ Date _____

3 Label the following muscles on Figure 10.26.

- ❑ Deltoid m.
- ❑ Gluteus maximus m.
- ❑ Iliocostalis m.
- ❑ Latissimus dorsi m.
- ❑ Longissimus m.
- ❑ Rhomboid major and minor mm.
- ❑ Spinalis m.
- ❑ Trapezius m.

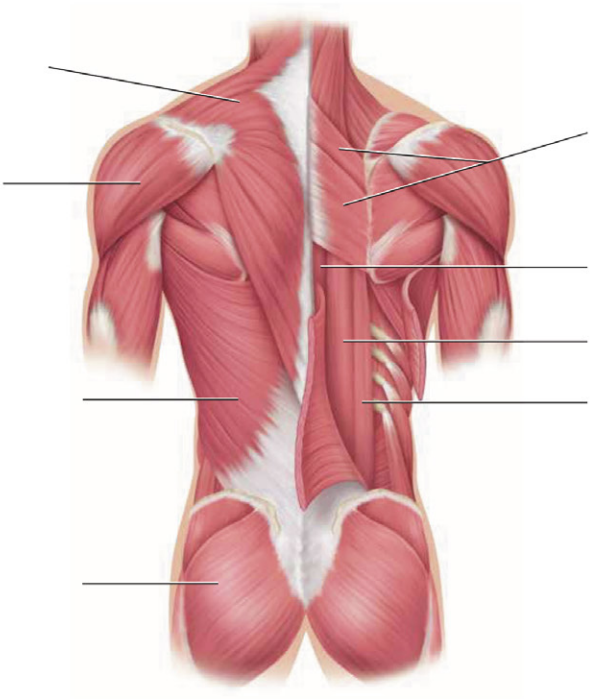

FIGURE **10.26** Muscles of the trunk, posterior view.

4 Label the following muscles on Figure 10.27.

- ❑ Biceps brachii m.
- ❑ Brachioradialis m.
- ❑ Extensor digitorum m.
- ❑ Infraspinatus m.
- ❑ Pectoralis major m.
- ❑ Supraspinatus m.
- ❑ Teres major m.
- ❑ Triceps brachii m.

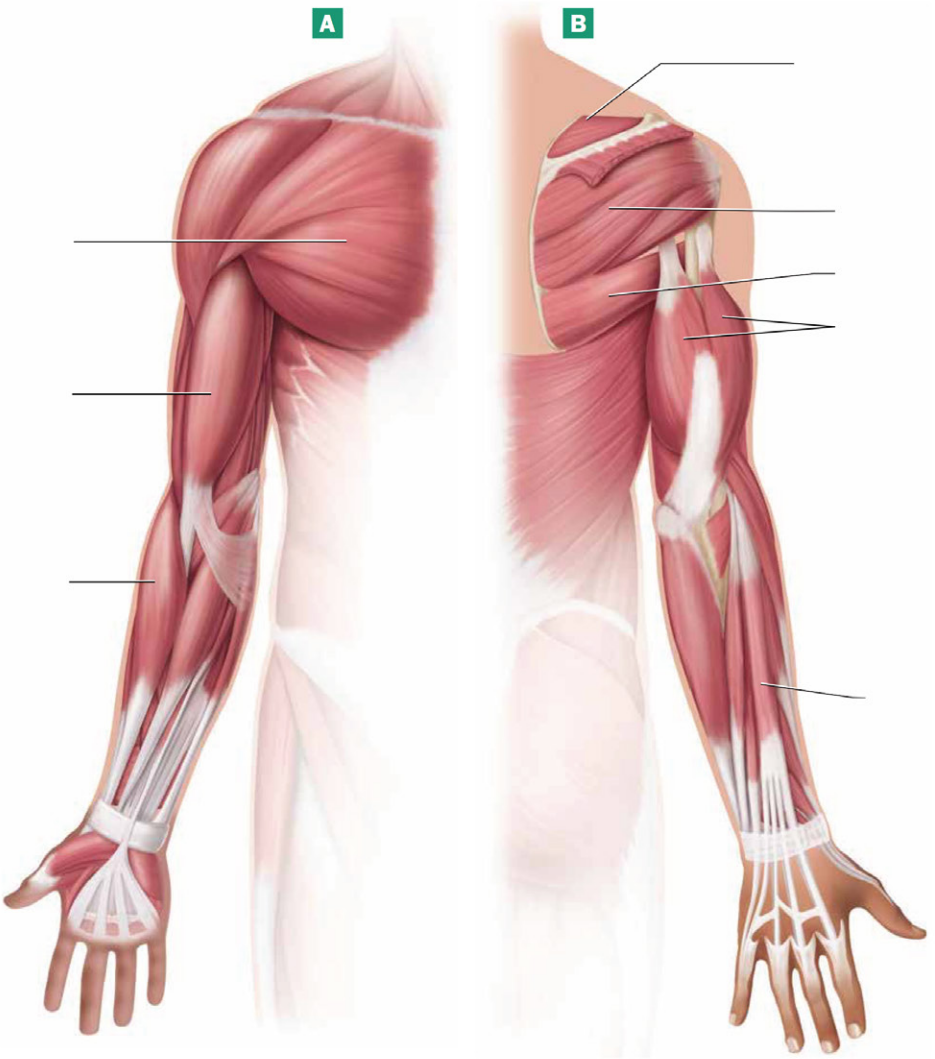

FIGURE **10.27** Muscles of the upper limb, anterior and posterior views.

Name _____

Section _____ Date _____

5 Label the following muscles on Figure 10.28.

- ❑ Biceps femoris m.
- ❑ Gastrocnemius m.
- ❑ Gluteus medius m.
- ❑ Pectineus m.
- ❑ Rectus femoris m.
- ❑ Sartorius m.
- ❑ Semimembranosus m.
- ❑ Soleus m.
- ❑ Tibialis anterior m.
- ❑ Vastus medialis m.

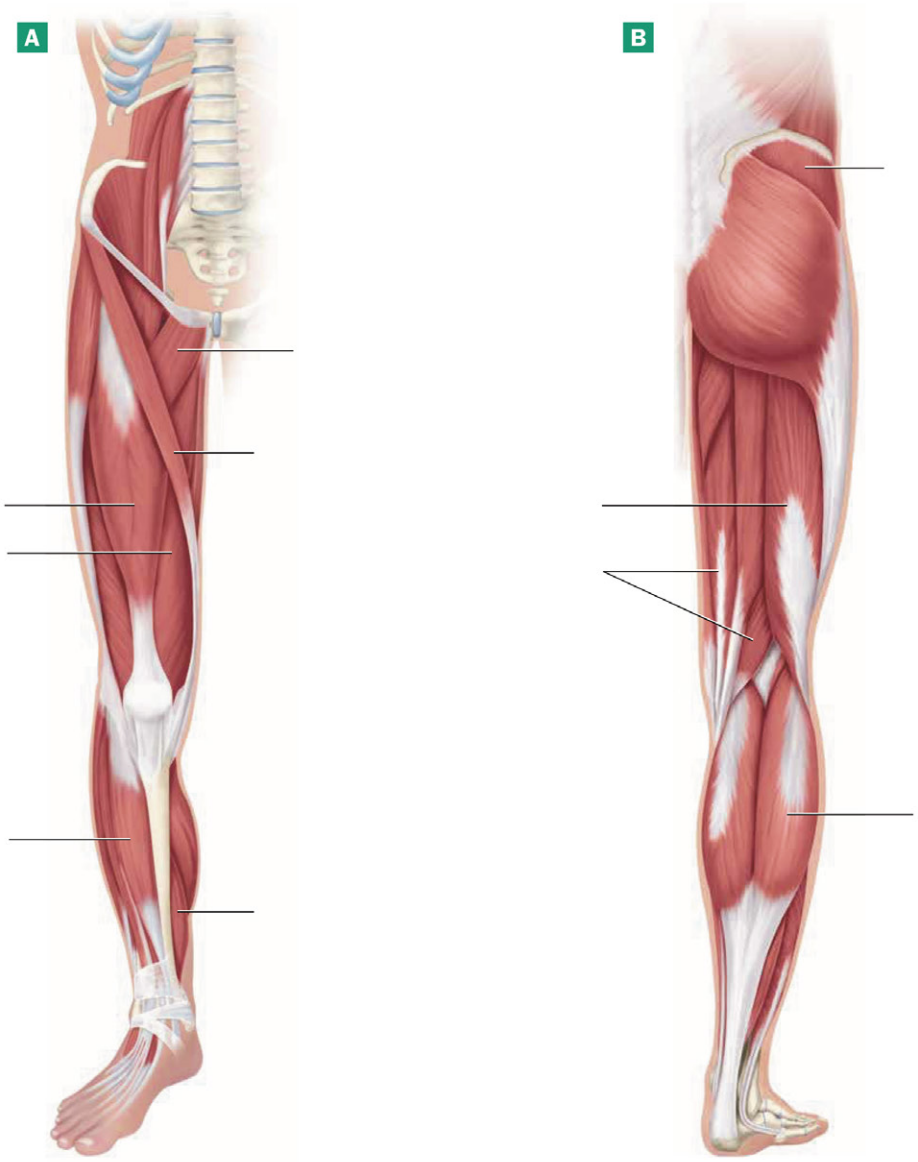

FIGURE **10.28** Muscles of the lower limb, anterior and posterior views.

6 How do a muscle's origin and insertion differ?

7 Which of the following muscles extends the forearm at the elbow joint?

a. Brachioradialis m.
b. Triceps brachii m.
c. Biceps brachii m.
d. Brachialis m.

8 Which of the following muscles flexes the thigh at the hip?

a. Iliopsoas m.
b. Biceps femoris m.
c. Vastus intermedius m.
d. Gluteus medius m.

9 What is the main action of the deltoid muscle?

a. Adduction of the arm at the shoulder joint.
b. Retraction of the scapula.
c. Depression of the scapula.
d. Abduction of the arm at the shoulder joint.

10 What is the main action of the rectus abdominis muscle?

a. Rotation of the trunk.
b. Flexion of the trunk.
c. Extension of the trunk.
d. Lateral flexion of the trunk.

Name _____

Section _____ Date _____

REVIEW

Check Your Understanding

Critical Thinking and Application Questions

1 Muscle strain, or "pulling a muscle," may result from overuse injuries or from trauma. Typically muscle strain causes pain around the muscle with movement and with pressure. Predict which muscle or muscles may be strained if a patient complains of pain in each of the following locations:

a Medial thigh _____

b Anterior arm _____

c Posterior neck _____

d Lateral abdomen (the "side") _____

e Posterolateral leg _____

f Lateral lumbar region of the back _____

2 A stroke, caused by a clot in a blood vessel of the brain, may lead to a loss of function of certain muscles. Which motions would an individual be unable to perform if the following muscles lost function?

a Buccinator m. _____

b Latissimus dorsi m. _____

c Biceps femoris m. _____

3 Predict the location, appearance, and function of the *flexor carpi radialis longus* muscle by looking only at its name.

_____

_____

_____

4 The serratus anterior muscle normally originates from the first nine ribs and inserts into the medial border of the scapula. Predict its action from this information.

_____

_____

_____

_____

5 When a person is in respiratory distress, the origin and insertion of the serratus anterior muscle may actually switch, and the part of the muscle attached to the medial border of the scapula acts as the origin. How will this change the muscle's action?

6 Neuromuscular diseases may lead to a condition called *drop foot*, in which a patient is unable to dorsiflex his or her foot. Which muscle(s) do you think would be involved in this condition? Which muscles may have to compensate for lack of dorsiflexion during walking? Explain.



UNIT
11

Muscle Tissue

Once you have completed this unit, you should be able to:

1. Describe the microscopic anatomy of skeletal muscle fibers.
2. Identify structures of skeletal muscle fibers on anatomical models and microscope slides.
3. Identify structures associated with the neuromuscular junction on anatomical models and microscope slides.
4. Describe the length-tension relationship of skeletal muscle fibers.
5. Distinguish between smooth and cardiac muscle tissue.

Name _____ Section _____ Date _____

PRE-LAB EXERCISES

Complete the following exercises prior to coming to lab, using this lab manual and your textbook for reference.

Pre-Lab Exercise 11-1



Key Terms

You should be familiar with the following terms before coming to lab.

Term	Definition

General Skeletal Muscle Structures

Epimysium _____

Fascicle _____

Perimysium _____

Muscle fiber _____

Endomysium _____

Structures of the Skeletal Muscle Fiber

Sarcolemma _____

T-tubule _____

Sarcoplasmic reticulum _____

Terminal cisternae _____

Myofibril _____

Myofilament _____

Name _____ Section _____ Date _____

Thick filament _____

Thin filament _____

Components of the Sarcomere

A band _____

I band _____

Z disc _____

H zone _____

M line _____

Terms of Muscle Physiology

Action potential _____

Crossbridge cycle _____

Excitation-contraction coupling _____

Sliding filament mechanism _____

Length-tension relationship _____

Pre-Lab Exercise 11-2

Basic Skeletal Muscle Anatomy

Label and color the basic structures of skeletal muscles depicted in Figure 11.1 with the terms from Exercise 11-1 (p. 295). Use your text and Exercise 11-1 in this unit for reference.

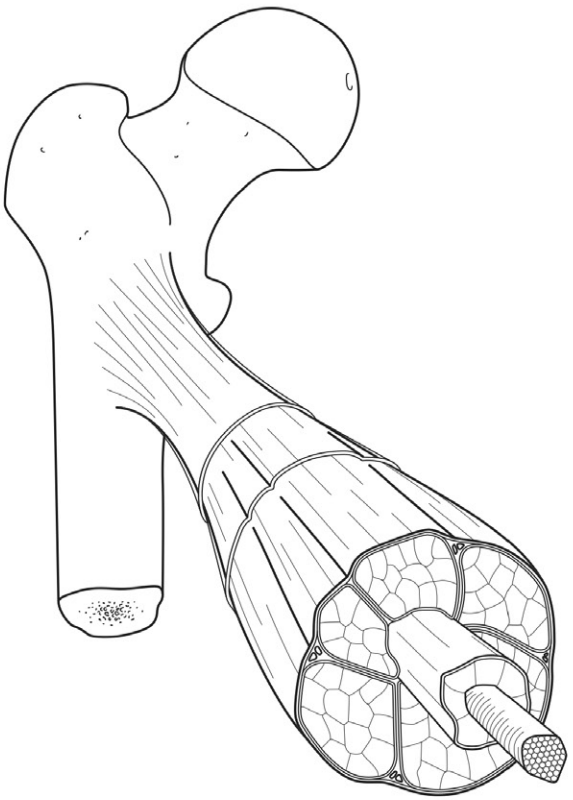

FIGURE 11.1 Skeletal muscle structural levels of organization.

Name _____ Section _____ Date _____

Pre-Lab Exercise 11-3

Muscle Fiber Microanatomy

Label and color the microscopic anatomy of the skeletal muscle fiber and neuromuscular junction in Figures 11.2 and 11.3 with the terms from Exercise 11-1 (p. 295). Use your text and Exercise 11-1 in this unit for reference.

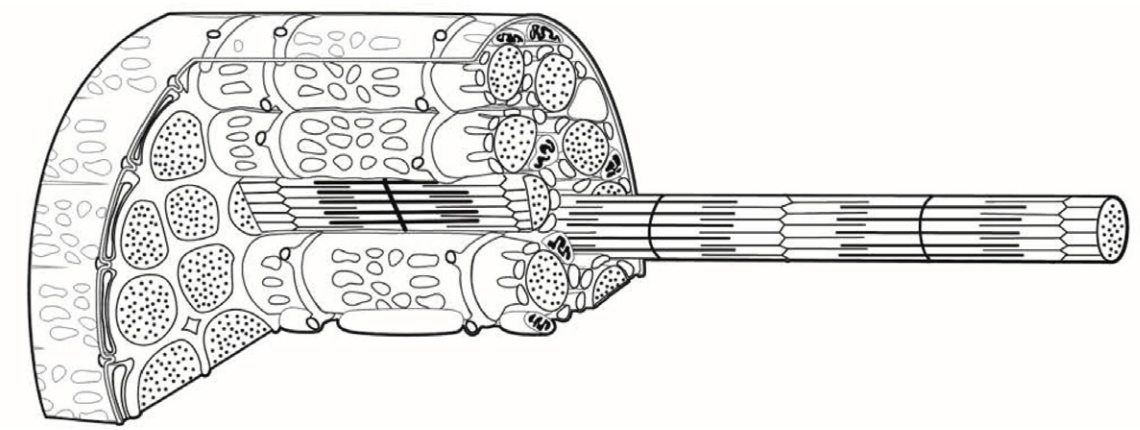

FIGURE **11.2** Skeletal muscle fiber.

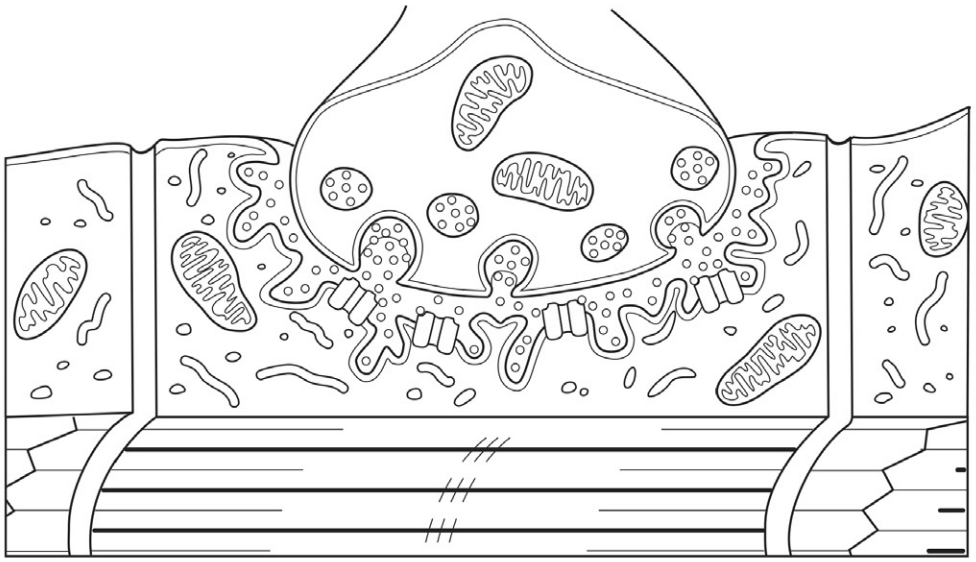

11

FIGURE **11.3** Neuromuscular junction.

Pre-Lab Exercise 11-4



Types of Muscle Tissue

You learned about the three types of muscle tissue in Exercise 5-3 (p. 121). Review the properties of each type of muscle tissue by filling in Table 11.1.

TABLE **11.1** The Three Types of Muscle Tissue

Muscle Type	Striated or Nonstriated	One or Multiple Nuclei	Size and Shape of Cells	Voluntary or Involuntary	Special Features
Cardiac muscle					
Skeletal muscle					
Smooth muscle					



Colored SEM of striated muscle fiber.

EXERCISES

This unit explores the structure and function of muscle tissue, with a focus on skeletal muscle tissue to build on what you learned in the previous unit. Although generally we study anatomy and physiology from the microscopic (chemical, cell, and tissue) level to the gross (organ and organ system) level, we do it backward with the muscular system. The reason for this is simply one of continuity—skeletal muscles as organs have a close structural and functional relationship with the skeleton and joints, and muscle tissue has a close structural and functional relationship with nervous tissue, our next topic.

You were already introduced to the basic structure and function of muscle tissue in Exercise 5-3 (p. 121). The first two exercises in this unit expand on these topics with an examination of the gross and microscopic structure of skeletal muscles and the nerve cells that supply them. In the third exercise we apply what we learned about skeletal muscle structure to skeletal muscle physiology. In the final exercise we examine the structure of smooth and cardiac muscle tissue to help you differentiate these tissue types on microscope slides.

Exercise 11-1

Microscopic Anatomy of Skeletal Muscle Tissue

MATERIALS

- ❑ Skeletal muscle models
- ❑ Skeletal muscle fiber model
- ❑ Skeletal muscle tissue slide
- ❑ Neuromuscular junction models
- ❑ Neuromuscular junction slide
- ❑ Light microscope with oil immersion objective
- ❑ Oil
- ❑ Colored pencils

Recall that skeletal muscle tissue is composed of skeletal muscle cells, also called **muscle fibers**. Individual skeletal muscle fibers are surrounded by their extracellular matrix, known as the **endomysium** (in-doh-MY-see-um). (Note that the endomysium blends with surrounding connective tissue and so is often referred to as connective tissue itself.) Muscle fibers are arranged into groups called **fascicles** (FASS-ih-kullz; Fig. 11.4). Each fascicle is surrounded by a connective tissue sheath called the **perimysium** (pehr-ih-MY-see-um). The muscle as a whole is covered by another connective tissue sheath called the **epimysium** (ep-ih-MY-see-um). The epimysium and perimysium merge near the end of a muscle to form *tendons* and *aponeuroses*, which connect the muscle to bones or soft tissue. The most superficial connective tissue around a skeletal muscle is thick **fascia** (FASH-uh), which separates individual muscles and binds them into groups.

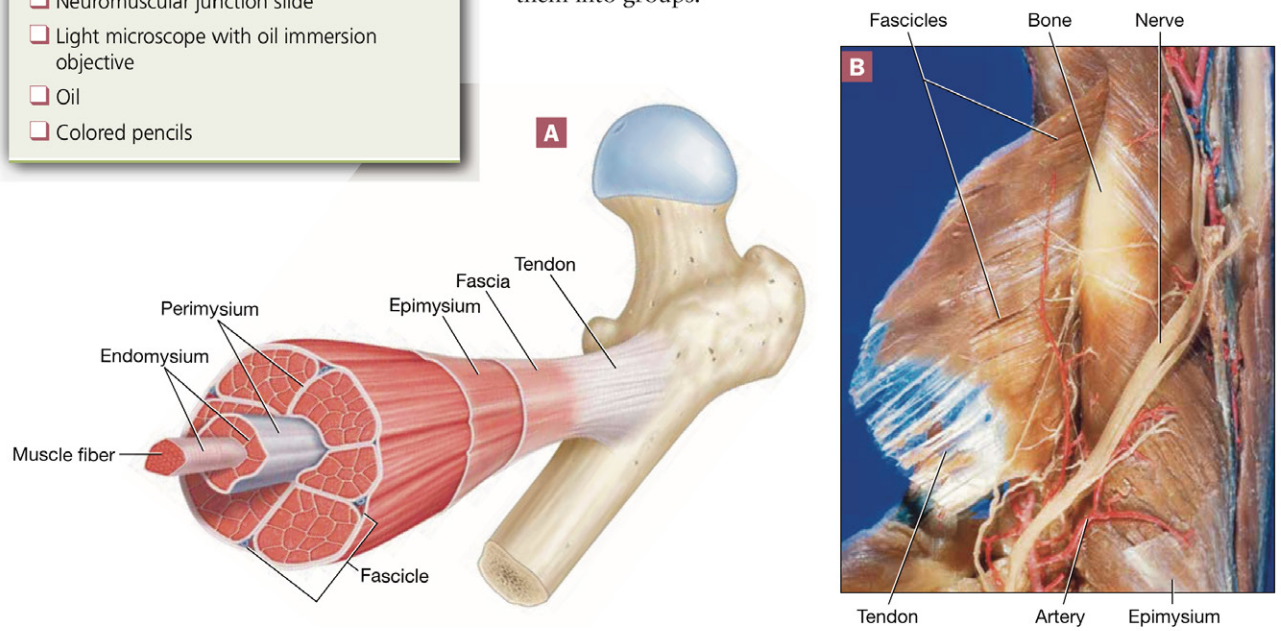

FIGURE **11.4** Overview of skeletal muscle structure: (**A**) skeletal muscle structural levels of organization; (**B**) dissected muscle.

As you can see in Figure 11.5, the long, multinucleated, cylindrical skeletal muscle fiber is quite different in appearance from the cells you are used to seeing. Due to these differences, we use different terms to describe some of a muscle fiber's structures. For example, the muscle fiber's plasma membrane is known as the **sarcolemma** (sar-koh-LEM-uh; Fig. 11.5), and its cytoplasm is called **sarcoplasm** (SAR-koh-plazm).

Small, cylindrical organelles called **myofibrils** (my-oh-FY-brillz) make up about 80 percent of the skeletal muscle fiber's sarcoplasm. Other organelles such as mitochondria are packed in between the myofibrils. Notice in the figure that myofibrils are wrapped by the weblike **sarcoplasmic reticulum** (sar-koh-PLAZ-mik reh-TIK-yoo-lum; **SR**), which is a modified smooth endoplasmic reticulum that stores calcium ions. Myofibrils are also wrapped by inward extensions of the sarcolemma known as **transverse-tubules** or **T-tubules**. On either side of a T-tubule, the SR swells to form **terminal cisternae** (sis-TER-nee); a T-tubule and two terminal cisternae form a structure called a **triad**. These structures are important for coordinating electrical stimulation of the muscle fiber with release of calcium ions from the SR and initiation of a muscle contraction.

Myofibrils are composed of protein subunits called **myofilaments**. The two types of myofilaments involved in contraction are: (1) **thick filaments**, composed of the contractile protein **myosin** (MY-oh-sin), and (2) **thin filaments**, composed of the contractile protein **actin** and the regulatory proteins **troponin** (TROH-poh-nin) and **tropomyosin** (trohp-oh-MY-oh-sin). The arrangement of myofilaments within the myofibrils is what gives skeletal muscle its characteristic **striated** appearance. The dark regions of the striations, called **A bands**, are dark because this is where we find overlapping thick and thin filaments or thick filaments alone. The light regions, called **I bands**, appear light because they contain only thin filaments.

On closer inspection, there are more lines and bands than simply the A and I bands:

- In the middle of the A band is a lighter region called the **H zone** where we find only thick filaments.
- Running down the middle of the H zone is the **M line**, which contains structural proteins that stabilize and support the thick filament.

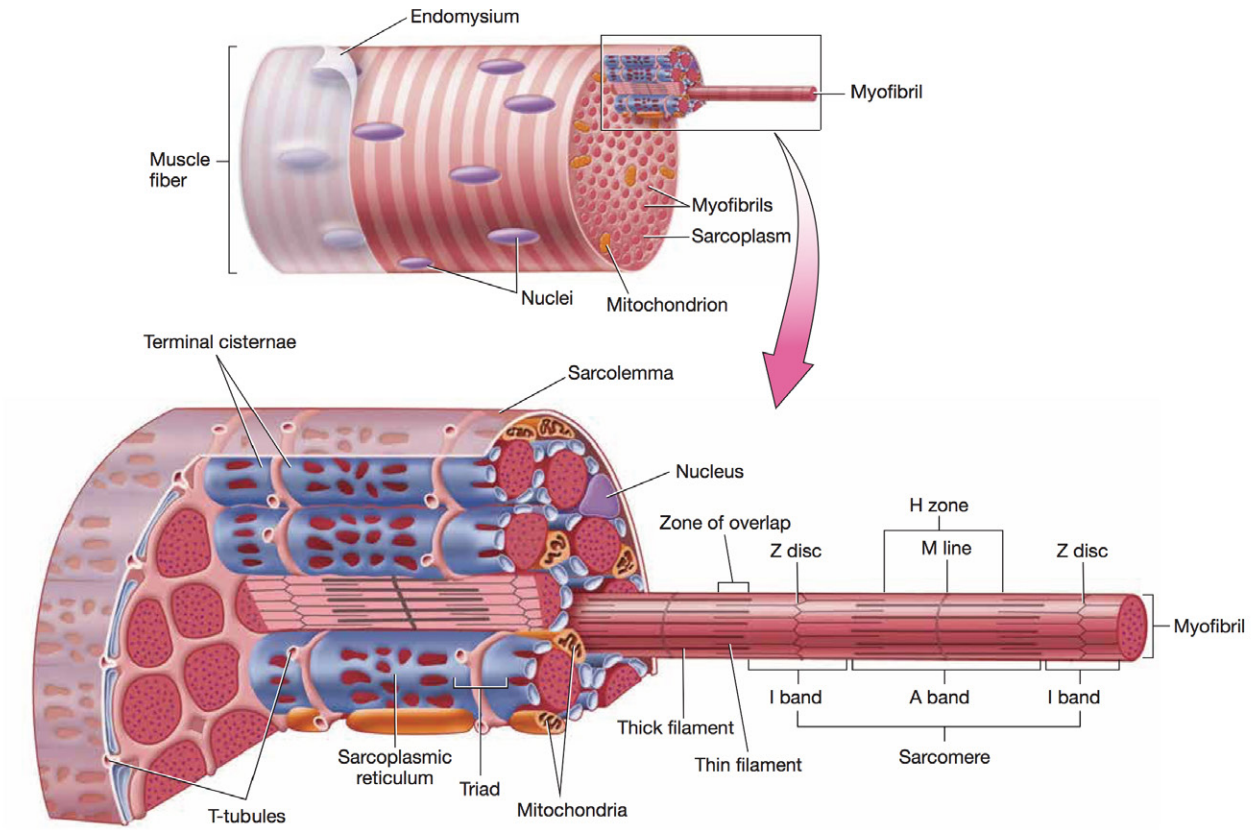

FIGURE **11.5** Skeletal muscle fiber.

- On either side of the H zone is an area where both thick and thin filaments are found in the A band; this area is known as the *zone of overlap*.
- In the middle of each I band is a dark line called the **Z disc**, which consists of structural proteins that support the thin filaments and stabilize the structure of the myofibril.

Although this might sound like alphabet soup, these terms are actually quite important, as they are used to define the fundamental unit of contraction: the **sarcomere** (SAR-koh-meer). A sarcomere, defined as the space from one Z disc to the next Z disc, consists of a full A band and two half-I bands. This is the unit that generates tension during a contraction.

Procedure 1 Model Inventory for Skeletal Muscle and Skeletal Muscle Fibers

Identify the following structures of skeletal muscle and skeletal muscle fibers on models and diagrams, using your textbook and this unit for reference. As you examine the anatomical models and diagrams, record the name of the model and the structures you were able to identify on the model inventory in Table 11.2. When you have finished the activity, answer Check Your Understanding question 1 (p. 311).

Skeletal Muscle Anatomy

1. Muscle fiber
2. Endomysium
3. Fascicles
4. Connective tissue coverings
   a. Perimysium
   b. Epimysium
   c. Fascia

Muscle Fiber Microanatomy

1. Sarcolemma
2. Sarcoplasm
3. Myofibrils
4 Sarcoplasmic reticulum
5. T-tubules
6. Terminal cisternae
7. Triad
8. Myofilaments
   a. Thick filaments
   b. Thin filaments
9. Sarcomere
   a. A band
   b. I band
   c. H zone
   d. M line
   e. Zone of overlap
   f. Z disc

TABLE **11.2** Model Inventory for Skeletal Muscle Anatomy and Microanatomy

Model/Diagram	Structures Identified

Procedure 2 Microscopy of Skeletal Muscle Tissue

View a prepared slide of skeletal muscle tissue.

1. First examine the slide with the low-power objective and advance to the high-power objective of your light microscope. See Figure 11.6A for reference.
2. Draw and color what you see, and label your drawing with the terms listed.
3. Then switch to an oil immersion lens (your instructor may have one set up as a demonstration), and identify the structures of the sarcomere. See Figure 11.6B for reference.

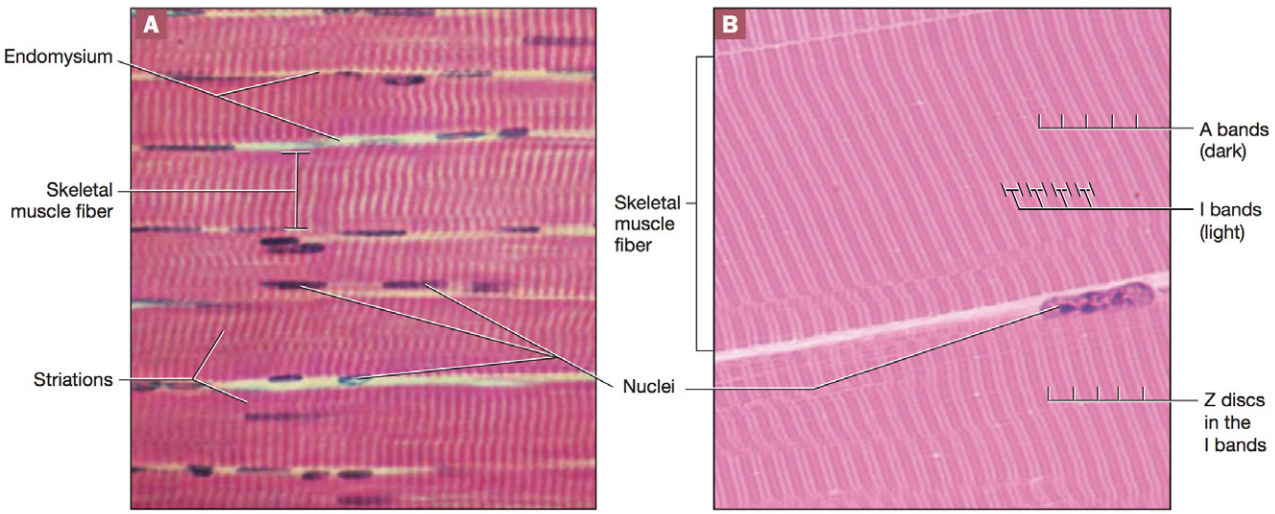

FIGURE **11.6** Skeletal muscle tissue, photomicrograph: (A) 40× objective; (B) 100× objective oil immersion.

High-Power (40×) Objective

1. Striations
   a. A band
   b. I band
2. Sarcolemma
3. Nuclei
4. Endomysium



Oil Immersion Lens

1. Sarcomere
2. A band
3. I band
4. Z disc
5. H zone
6. M line

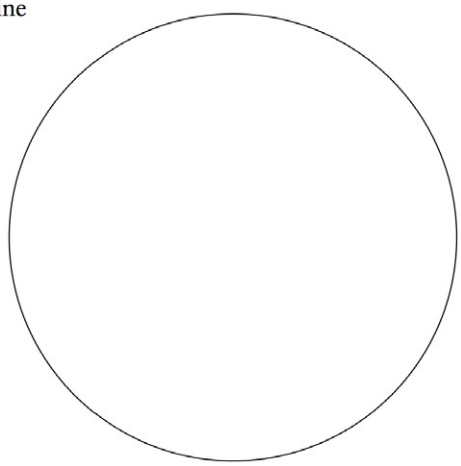

The Neuromuscular Junction

Skeletal muscle fibers are voluntary, which means that they contract under the conscious control of the nervous system. Each skeletal muscle fiber has a **motor neuron** that triggers it to contract. The place where the nerve meets the muscle fiber is called the **neuromuscular junction** (NMJ) (Fig. 11.7). The neuromuscular junction consists of three parts:

1. **Axon terminal.** At its end, a motor neuron splits into many branches, each of which terminates in a swollen **axon terminal** (or *synaptic end bulb*) that communicates with one muscle fiber. An axon terminal has **synaptic vesicles** in its cytosol that contain the neurotransmitter **acetylcholine** (ah-SEE-til-koh-leen) **or ACh.**
2. **Synaptic cleft.** The axon terminal doesn't come into direct contact with the muscle fiber; instead, there is a space between the axon terminal and the muscle fiber called the **synaptic cleft.** Within the synaptic cleft is an extracellular gel that contains the enzyme *acetylcholinesterase* (ah-see-til-kohl-in-ESS-ter-ayz; AChE) that catalyzes the breakdown of ACh.
3. **Motor end plate.** The **motor end plate** is a specialized, folded region of the sarcolemma that contains cation channels called **acetylcholine receptors** to which ACh binds. The binding of the ACh to these channels opens them, beginning the events that will eventually lead to a muscle contraction.

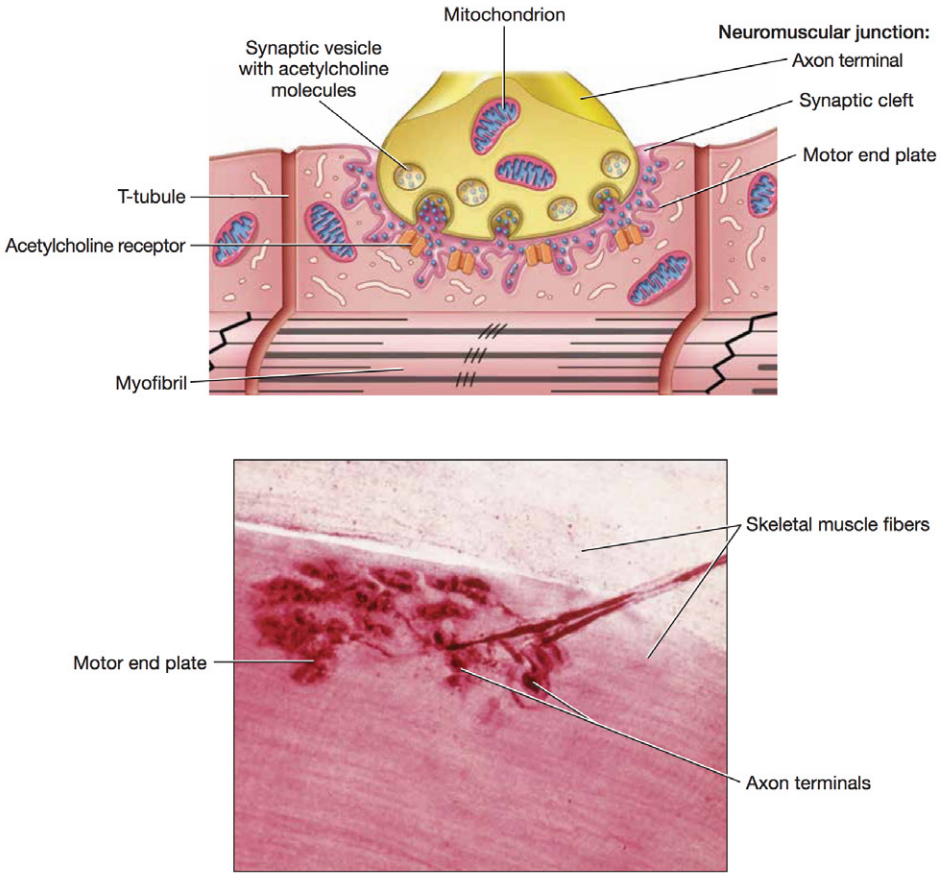

FIGURE **11.7** Neuromuscular junction.

Procedure 3 Model Inventory for the Neuromuscular Junction

Identify the following structures of the neuromuscular junction on models and diagrams, using your textbook and this unit for reference. As you examine the anatomical models and diagrams, record the name of the model and the structures you were able to identify on the model inventory in Table 11.2 (note that this is the model inventory you used for the muscle fiber anatomy). When you have finished the activity, answer Check Your Understanding questions 2 and 3 (p. 311).

1. Motor neuron
2. Axon terminal
3. Synaptic vesicles
4. Synaptic cleft
5. Motor end plate
6. Acetylcholine receptors

Procedure 4 Microscopy of the Neuromuscular Junction

Obtain a prepared slide of a neuromuscular junction. Use your colored pencils to draw what you see, and label your drawing with the following terms.

1. Motor neuron
2. Axon terminal
3. Skeletal muscle fiber
4. Striations



Exercise 11-2

Muscle Physiology

MATERIALS

- ❑ Hand dynamometer
- ❑ Model/diagram of the contraction cycle
- ❑ Colored pencils
- ❑ Glycerinated muscle, teased, in glycerol in a petri dish
- ❑ 0.25% ATP/0.05 M KCl/0.001 M MgCl solution
- ❑ 4× magnifying glass
- ❑ Blank glass slides
- ❑ Glass needles or teasing needles
- ❑ Millimeter ruler
- ❑ Light microscope
- ❑ Dissecting microscope

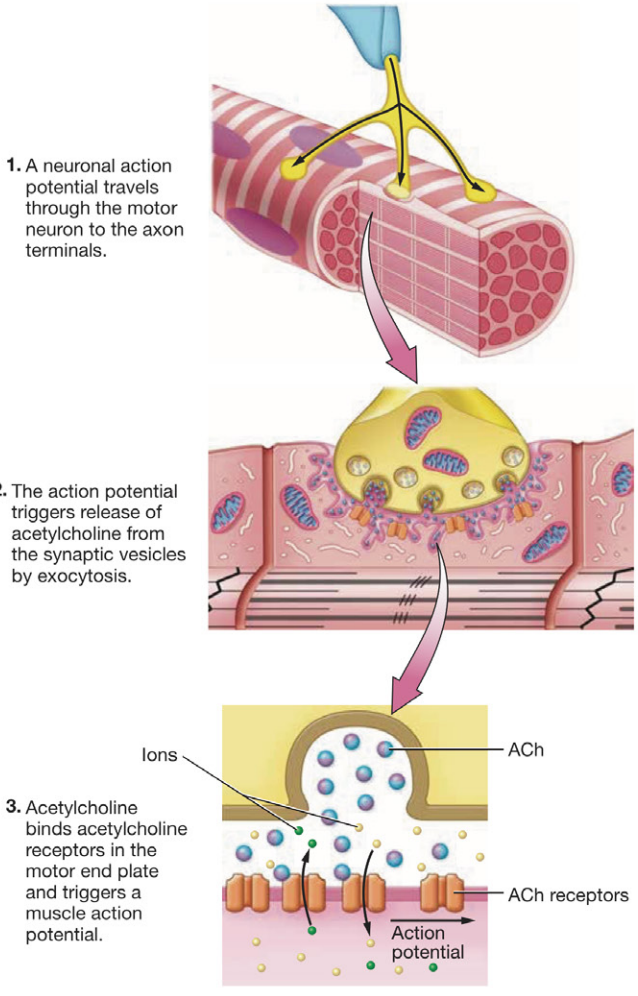

FIGURE **11.8** Events at the neuromuscular junction.

Skeletal muscle contraction begins when a skeletal muscle fiber is stimulated by a motor neuron, in a relationship known as **excitation–contraction coupling**. Notice in Figure 11.8 what happens when a nerve impulse, also called a **neuronal action potential**, reaches the axon terminal: ACh is released into the synaptic cleft by exocytosis of the synaptic vesicles. ACh then binds its cation-channel receptors in the motor end plate, and sodium ions to rush into the sarcoplasm. As the cell accumulates positive charges, the electrical difference across the sarcolemma becomes more positive, a change called **depolarization**. This initiates a series of electrical events across the sarcolemma of the muscle fiber collectively called a **muscle action potential**.

The depolarization that begins at the motor end plate propagates through the sarcolemma and dives into the interior of the muscle fiber along the T-tubules. As the action potential spreads along the T-tubules, calcium ion channels open in the adjacent terminal cisternae, and calcium ions flood the sarcoplasm. This increase in calcium ion concentration is a key event in initiating a muscle contraction: Before calcium ions enter the sarcoplasm, actin and myosin are prevented from interacting by the regulatory protein tropomyosin. When calcium ions enter, they bind to troponin, and this causes troponin to pull tropomyosin away from the actin-myosin binding site. This allows a contraction to begin.

A skeletal muscle fiber contracts by a process known as the **sliding filament mechanism**, in which the myosin heads of the thick filament pull the thin filament toward the M line of the sarcomere. As this occurs, the thick and thin filaments "slide" past one another. The key event of this mechanism is the **crossbridge cycle**, which consists of the following steps (Fig. 11.9):

1. Before the cycle starts, the myosin head is in its "relaxed" position and is unable to bind to the active site of actin. The first step of the cycle, then, is to put the myosin head into its upright, "cocked" position. This is accomplished using the energy from ATP hydrolysis. The leftover products of the reaction, ADP and P_i, remain associated with the myosin head.
2. The myosin head binds to the active site of an actin subunit, forming a **crossbridge**.

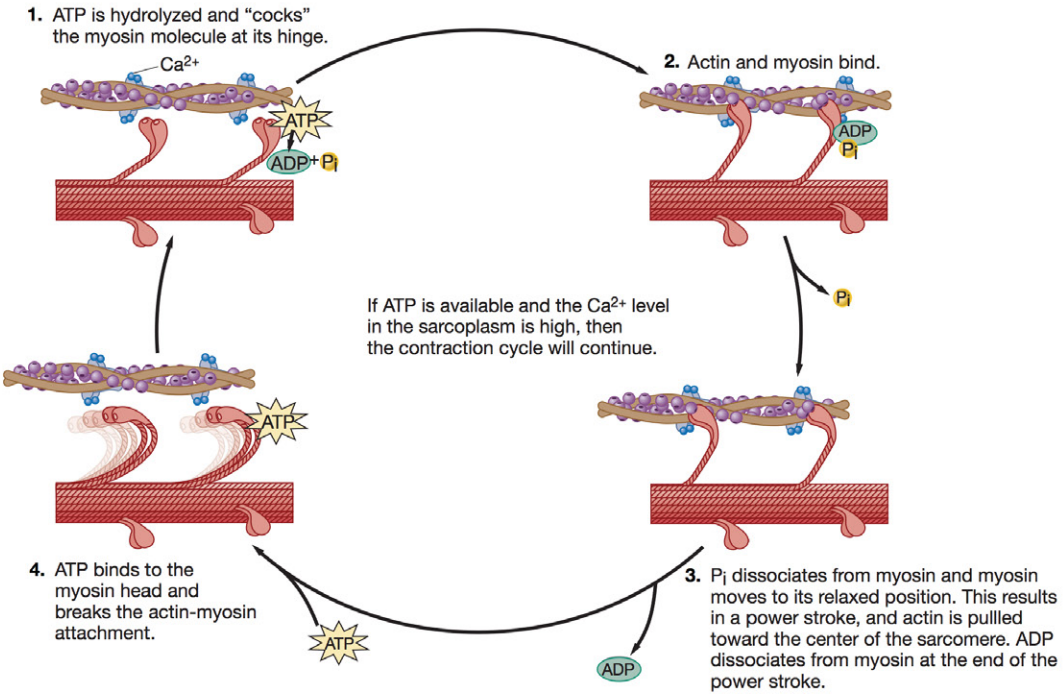

FIGURE **11.9** Single crossbridge cycle showing the sliding filament mechanism of contraction.

3. P_i dissociates from the myosin head, and the myosin molecule moves forward into its relaxed position. As it moves, it pulls the thin filament with it toward the M line in a motion known as a **power stroke.** At the end of the power stroke, ADP leaves the myosin head.
4. After the power stroke, the actin and myosin are still attached, and they will remain attached until a new ATP molecule comes in and breaks that attachment. When that ATP molecule is hydrolyzed, the myosin head will be recocked, it will bind a new actin subunit, and another crossbridge cycle will begin.

This cycle will continue as long as ACh remains in the synaptic cleft (provided that calcium ions and ATP remain available). Therefore, to terminate a contraction (1) the neuron must stop releasing ACh and (2) the body must degrade the ACh in the synaptic cleft with reactions catalyzed by the enzyme **acetylcholinesterase.** When stimulation ceases, the calcium ions are pumped back into the SR, and troponin and tropomyosin move back into their original positions. At this point, actin and myosin can no longer bind, and the muscle fiber returns to its resting length.

Procedure 1 Seeing Muscle Fiber Contraction in Action

Recently harvested muscle fibers, when stored properly, surprisingly retain their ability to contract under the correct conditions. This procedure uses *glycerinated muscle*, which is muscle tissue prepared in such a way that it removes all ions and ATP, and also disrupts the troponin/tropomyosin complex such that they no longer block the active sites of actin. For this reason, glycerinated muscle does not need calcium ions in order to contract.

However, the myosin heads in glycerinated muscle are in the relaxed position, and so they must be "cocked" by ATP hydrolysis in order for a contraction to occur. In this procedure, you will be supplying that ATP to see contractions of muscle fibers as they happen. When you have completed the activity, answer Check Your Understanding question 4 (p. 311).

1 Your instructor has placed pre-teased glycerinated skeletal muscle tissue into a petri dish under a dissecting microscope. Use a glass needle or a teasing needle to obtain a very thin thread of skeletal muscle tissue from this petri dish, and place it on a blank slide with a coverslip.

2. Examine your sample under a light microscope using the low-power objective and look for very small muscle threads. If your slide has large clumps and you are unable to see striations, get another sample and try again until you have smaller pieces and can see striations.
3. Prepare a second blank slide, and place a tiny drop of glycerol in the center of the slide with your needle. It is important not to use too much glycerol, or you will not see muscle contraction.
4. Use a glass needle or teasing needle to transfer three or more of the smallest threads to the glycerol on the second slide.
5. Using a 4× magnifying glass or your microscope, measure the length of the muscle fiber threads with a ruler in millimeters. You may find it easier to use a magnifying glass.

   Length of muscle fibers before contraction: _____ millimeters
6. Apply several drops of the 0.25% ATP/0.05 M KCl/0.001 M MgCl solution to the fibers on the slide.
7. Put the slide back on the microscope stage and observe it for one minute. Watch as the muscle fibers contract.
8. After one minute, remeasure the muscle fiber threads with a ruler in millimeters.

   Length of muscle fibers after contraction: _____ millimeters

Procedure 2 Measuring the Length-Tension Relationship

The amount of tension that can be generated during a contraction is influenced by the size of the zone of overlap of the thick and thin filaments when the muscle fiber is at rest, a principle known as the **length-tension relationship** (Fig. 11.10). The zone of overlap of the thick and thin filaments is determined by the resting length of the sarcomeres. When the muscle is stretched, the sarcomeres are longer and have a smaller zone of overlap. When the muscle is shortened, the sarcomeres are shorter and have a larger zone of overlap.

Notice in Figure 11.10 that the muscle fiber can generate the maximum amount of tension when its sarcomeres are at about 100 percent to 120 percent of their natural length. Conversely, the amount of tension generated during a contraction diminishes greatly both when the muscle is overly stretched and when it is excessively shortened.

In this experiment you will be measuring the ability of your digital flexor muscles to generate tension at different resting muscle lengths. You will take your measurements with an instrument called a **hand dynamometer**, which measures the force you apply when it is squeezed. When you have finished the experiment, answer Check Your Understanding question 5 (p. 312).

1. Position your forearm and hand as shown in Figure 11.11A, with your hand flexed at a 90° angle at the wrist.
2. Grip the dynamometer, and squeeze it with your maximum effort. Record in Table 11.3 the amount of force you generated.
3. Position your forearm and hand as shown in Figure 11.11B, with your hand extended at a 0° angle at the wrist.
4. Grip the dynamometer, and squeeze it with your maximum effort. Record in Table 11.3 the amount of force you generated.
5. Position your forearm and hand as shown in Figure 11.11C, with your hand hyperextended at a –90° angle at the wrist.

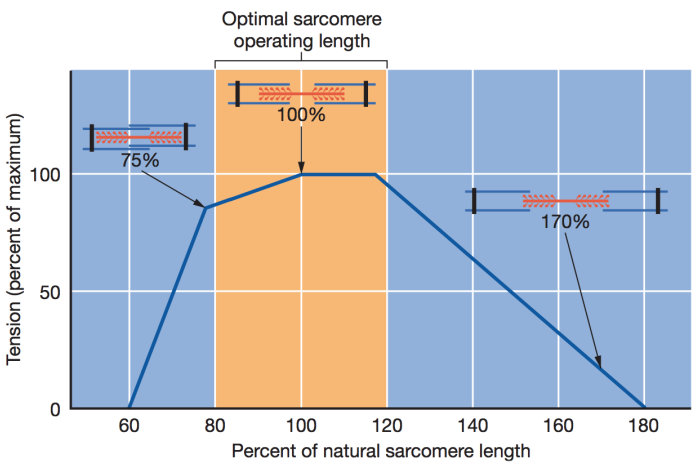

FIGURE 11.10 Length-tension relationship.

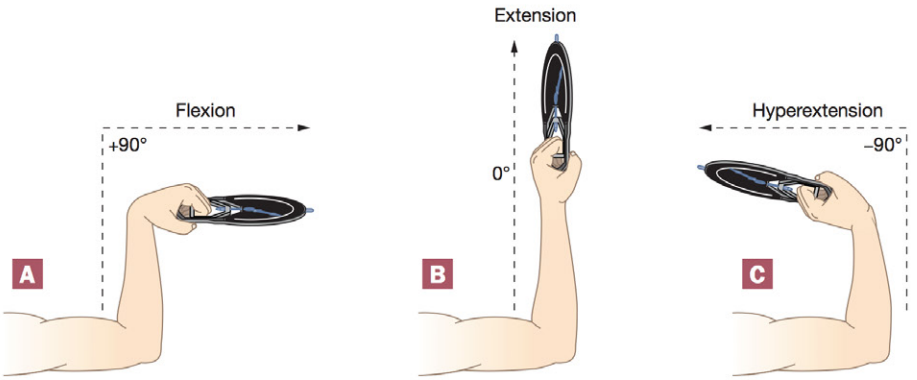

FIGURE **11.11** Hand positions for the dynamometer experiment: (**A**) flexed at 90°; (**B**) extended at 0°; (**C**) hyperextended at –90°.

6 Grip the dynamometer, and squeeze it with your maximum effort. Record in Table 11.3 the amount of force you generated.

7 Interpret your results:

a In which hand position were the muscles' sarcomeres overly stretched?

b In which hand position were the muscles' sarcomeres excessively shortened?

c Which hand position yielded the most forceful contraction? Why?

TABLE **11.3** Results of Dynamometer Experiment

Hand Position	Amount of Force Generated
Flexed at 90°	
Extended at 0°	
Hyperextended at –90°	

Exercise 11-3

Smooth and Cardiac Muscle Tissues

MATERIALS

- ❑ Smooth muscle slide
- ❑ Cardiac muscle slide
- ❑ Light microscope
- ❑ Colored pencils

Although smooth and cardiac muscle tissues differ from skeletal muscle tissue in many ways, all three share the same basic function: to generate tension. This functional similarity brings with it structural similarities, as well. Cardiac muscle tissue is structurally the most similar to skeletal muscle tissue. As you can see in Figure 11.12A, cardiac muscle tissue is also striated and consists of alternating A bands and I bands arranged into sarcomeres.

The two tissue types have notable differences, though. For one, the cells of cardiac muscle tissue, called **cardiac myocytes**, are shorter than skeletal muscle fibers, branching, and typically have only one or two nuclei. In addition, adjacent cardiac myocytes are joined by specialized structures called **intercalated discs**, which contain gap junctions and desmosomes. The intercalated discs connect all cardiac myocytes physically and electrically and allow the heart to contract as a unit. Finally, cardiac myocytes are involuntary and **autorhythmic**: They depolarize and contract without stimulation from the nervous system because of specialized cardiac myocytes called **pacemaker cells**.

Smooth muscle tissue, shown in Figure 11.12B, is not striated and, therefore, has no A bands, I bands, or sarcomeres. Smooth muscle cells tend to be long, thin, and spindle-shaped with a single, centrally located nucleus. All smooth muscle cells are involuntary, and most require extrinsic innervation to contract. Smooth muscle is found in many places in the body, including lining the walls of all hollow organs, the arrector pili muscles in the dermis, and the iris and ciliary muscle of the eye.

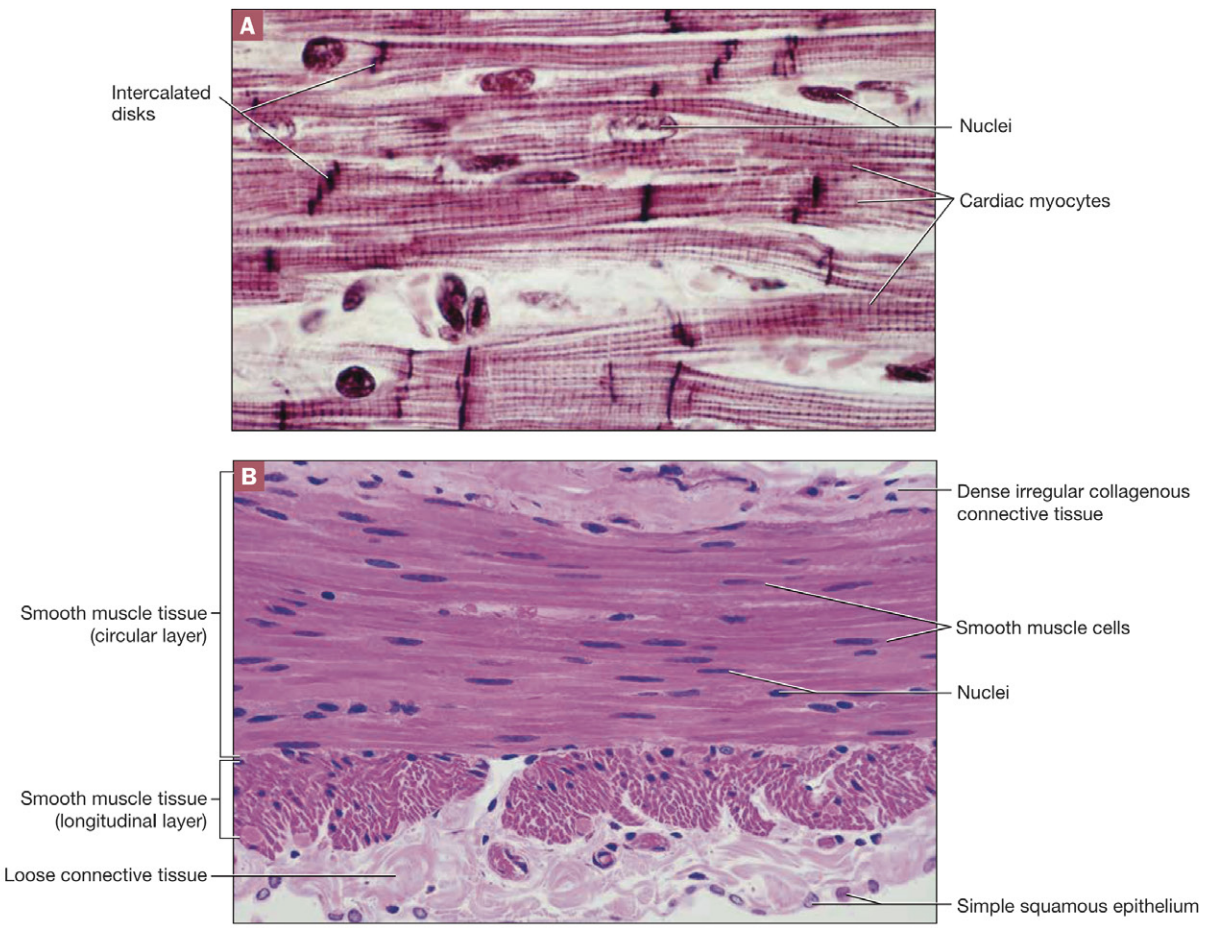

FIGURE **11.12** Other types of muscle tissue: (A) cardiac muscle tissue; (B) smooth muscle tissue.

HINTS & TIPS

How to Distinguish Between Types of Muscle Tissue

With a bit of practice, distinguishing between the three types of muscle tissue on microscope slides becomes fairly easy. Following are some hints to help you differentiate these three tissues:

Striations If striations are present, the muscle is either skeletal or cardiac. If there are no striations, it is smooth muscle.

Shape of the cells Skeletal muscle fibers are long and thin, whereas cardiac myocytes are short, wide, and branching. Smooth muscle cells are thin and flat. My past students have remarked that smooth muscle cells somewhat resemble stratified squamous epithelium or dense regular collagenous connective tissue (see pp. 106 and 113).

Location of the nucleus Each skeletal muscle fiber has multiple nuclei located next to the sarcolemma. Cardiac myocytes usually have a single, large nucleus located among the myofibrils. The single, flattened nucleus of a smooth muscle cell is usually in the middle of the cell.

Other features

- The intercalated discs of cardiac muscle tissue appear as black lines oriented parallel to the striations. No other tissue type has a similar feature, so intercalated discs are an immediate giveaway that you are looking at cardiac muscle tissue.
- Smooth muscle tissue is typically found on a slide with other types of tissue because it lines hollow organs. Scroll through the slide to see if you can find any additional tissue types, such as epithelial and/or connective tissue. If these other tissue types are on top of or below the muscle cells, there is a good chance you are examining smooth muscle tissue.

Procedure 1 Microscopy of Cardiac and Smooth Muscle Tissue

1 Obtain prepared slides of cardiac and smooth muscle tissue.

2 Use your colored pencils to draw what you see, and label your drawing with the following terms. After you have completed the activity, answer Check Your Understanding questions 6 and 7 (p. 312).

1. Cardiac muscle
   a. Striations
      (1) A band
      (2) I band
   b. Sarcolemma
   c. Nucleus
   d. Intercalated disc
   e. Cardiac myocyte

2. Smooth muscle
   a. Nucleus
   b. Smooth muscle cell
   c. Connective tissue

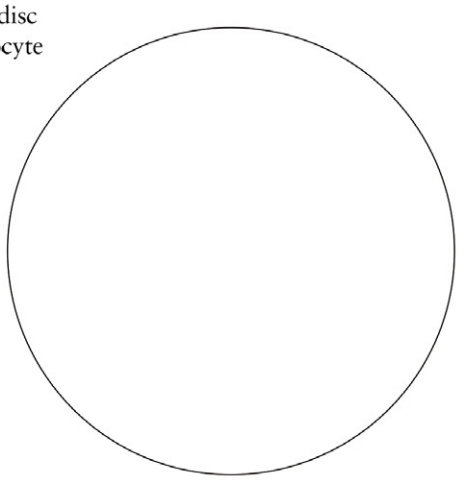



Name _____

Section _____ Date _____

UNIT 11 REVIEW

Check Your Recall

1 Label the following terms on Figure 11.13.

- ❑ Epimysium
- ❑ Fascia
- ❑ Fascicle
- ❑ Muscle fiber
- ❑ Perimysium
- ❑ Tendon

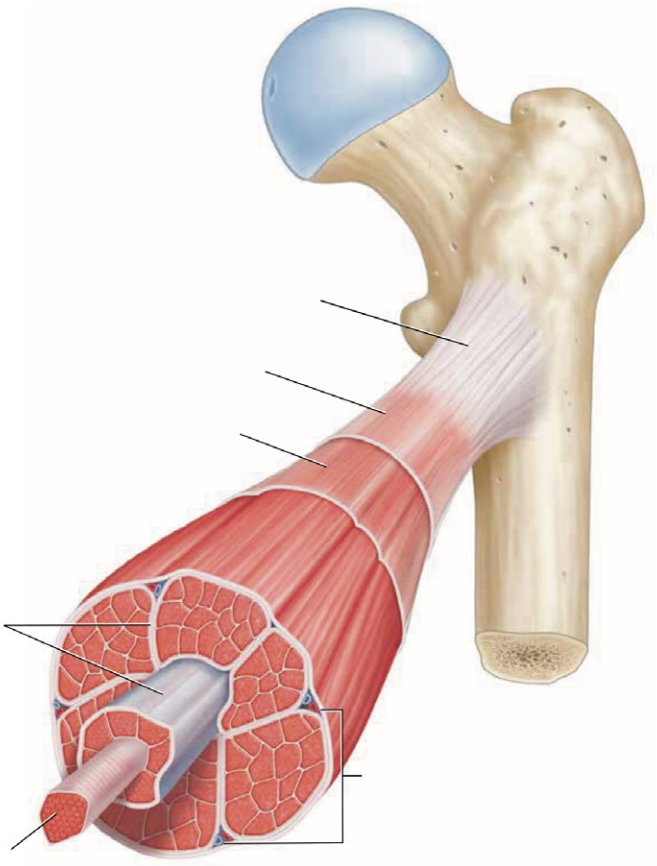

FIGURE **11.13** Skeletal muscle structural levels of organization.

2 Label the following terms on Figure 11.14.

- ❑ A band
- ❑ I band
- ❑ M line
- ❑ Mitochondrion
- ❑ Myofibril
- ❑ Nucleus
- ❑ Sarcolemma
- ❑ Sarcomere
- ❑ Sarcoplasmic reticulum
- ❑ T-tubule
- ❑ Z disc

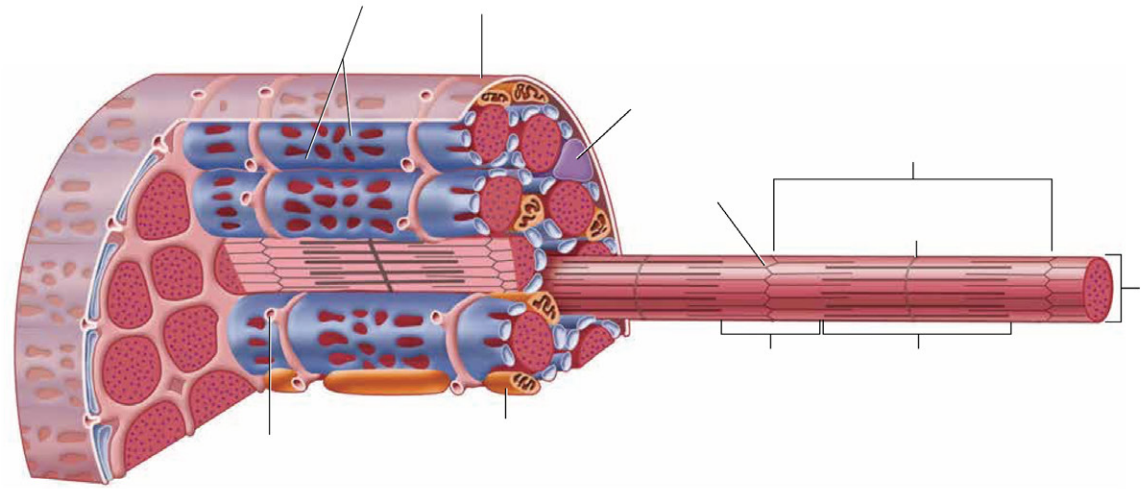

FIGURE **11.14** Skeletal muscle fiber.

3 Which of the following proteins make up a thick filament?

a. Myosin.
b. Actin.
c. Troponin.
d. Tropomyosin.
e. Choices b, c, and d are correct.

4 A transverse (T) tubule

a. stores sodium ions.
b. forms from inward extensions of the sarcolemma.
c. stores calcium ions.
d. is made of contractile proteins.

5 What is a sarcomere?

Name _____

Section _____ Date _____

6 *Fill in the blanks:* The neuromuscular junction consists of three parts: (1) the _____ terminal, which contains synaptic vesicles with the neurotransmitter _____; (2) the _____; and (3) the _____.

7 Excitation-contraction coupling refers to

a. the action potential of a neuron triggering the release of neurotransmitters from synaptic vesicles.
b. the relationship between length of the sarcomere and the tension generated.
c. the sliding of thick and thin filaments past one another.
d. the relationship between excitation at the sarcolemma and release of calcium ions from the terminal cisternae of the sarcoplasmic reticulum.

8 Number the following events of skeletal muscle contraction in the proper order, with number 1 for the first event and number 6 for the last event.

_____ A power stroke occurs as myosin moves into its relaxed position and pulls the thin filament toward the M line.

_____ Calcium ions bind to troponin, which pulls tropomyosin away from actin.

_____ ATP breaks the actin-myosin attachment, after which ATP is hydrolyzed and myosin is recocked.

_____ The myosin head binds to an actin subunit.

_____ The energy from ATP hydrolysis "cocks" the myosin head into an upright position.

_____ The terminal cisternae of the sarcoplasmic reticulum release calcium ions into the sarcoplasm.

9 Maximal tension in a skeletal muscle contraction is generated

a. when the sarcomeres are at about 100 to 120 percent of their natural length.
b. when the muscle fiber is stretched before the contraction.
c. when the muscle fiber is shortened before the contraction, and there is a maximal zone of overlap.
d. when the sarcoplasmic reticulum releases fewer calcium ions.

10 Mark the following statements as applying to skeletal muscle tissue, cardiac muscle tissue, smooth muscle tissue, or any combination of the three.

_____ The primary function is to generate tension.

_____ The tissue lines hollow organs.

_____ The cells are uninucleate.

_____ The cells are involuntary.

_____ The cells are autorhythmic.

_____ The cells must be stimulated by a neuron to contract.

_____ The cells are striated in appearance.

_____ The cells lack striations and sarcomeres.

_____ The cells are multinucleate.

11

Name _____

Section _____ Date _____



REVIEW

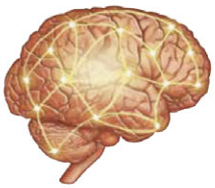

Check Your Understanding

Critical Thinking and Application Questions

1 Would a skeletal muscle fiber still have striations if it lacked thin filaments? Explain.

2 *Latrotoxin*, produced by widow spiders, causes several effects, one of which is to increase the release of ACh at the synaptic cleft. What effect do you think this action would have on muscle fibers? Why?

3 *Myasthenia gravis* is an autoimmune disease in which the immune system produces antibodies that attack the acetylcholine receptor on the motor end plate. What symptoms would you expect with this disease? Explain.

4 The ATP solution that you used in your muscle contraction procedure contains magnesium ions, which increase the strength of contraction in glycerinated muscle. In living muscle cells, magnesium ions compete with calcium ions for binding sites on troponin molecules. In the condition of *hypermagnesemia*—a high concentration of magnesium ions in the blood—magnesium ions can prevent calcium ions from binding troponin. Would this strengthen, weaken, or have no effect on the muscle contraction? Explain.

5 Your patient, Ms. Young, presents to physical therapy for evaluation and treatment of painful muscle spasms (sustained muscle contractions) in the muscles of her right shoulder. You notice upon evaluation that Ms. Young has decreased strength in her right shoulder compared with her left shoulder, which has no muscle spasms. Explain this finding. (***Hint:*** Is a muscle in spasm at its natural length?)

6 Suppose a poison were able to block the gap junctions in the intercalated discs of cardiac muscle cells. How would this affect the ability of cardiac muscle tissue to perform its functions?

7 When you walk outside into the bright daylight, the muscle cells of the irises in your eyes contract, constricting your pupils so that less light enters your eyes. Would you expect these muscle cells to be striated or smooth? Explain your reasoning.

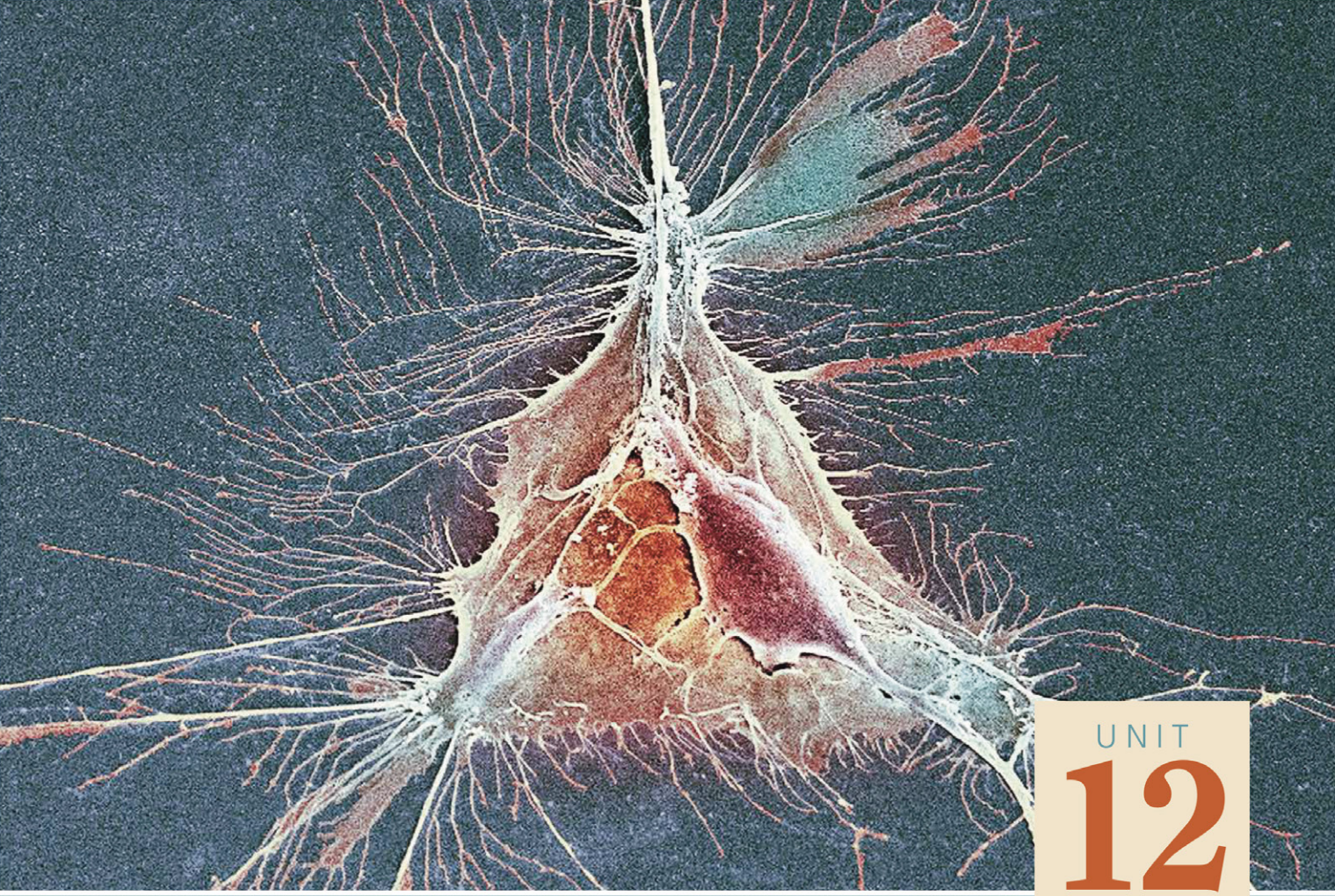

UNIT
12

Introduction to the Nervous System

Once you have completed this unit, you should be able to:

1. Describe the microanatomy of nervous tissue and the parts of a synapse.
2. Identify structures of the neuron and neuroglial cells.
3. Describe and diagram the sequence of events of chemical synaptic transmission.

Name _____ Section _____ Date _____

PRE-LAB EXERCISES

Complete the following exercises prior to coming to lab, using this lab manual and your textbook for reference.

Pre-Lab Exercise 12-1



Key Terms

You should be familiar with the following terms before coming to lab.

Term	Definition

Components of Nervous Tissue

Neuron _____

Neuroglial cell _____

Parts of the Neuron

Cell body _____

Axon _____

Dendrite _____

Myelin sheath _____

Node of Ranvier _____

Structures of the Synapse

Synapse _____

Axon terminal _____

Synaptic vesicle _____

Synaptic cleft _____

Presynaptic neuron _____

Postsynaptic neuron _____

Pre-Lab Exercise 12-2

Nervous Tissue Microanatomy

Label and color the microscopic anatomy of nervous tissue in Figure 12.1 with the terms from Exercise 12-1 (p. 317). Use your text and Exercise 12-1 in this unit for reference.

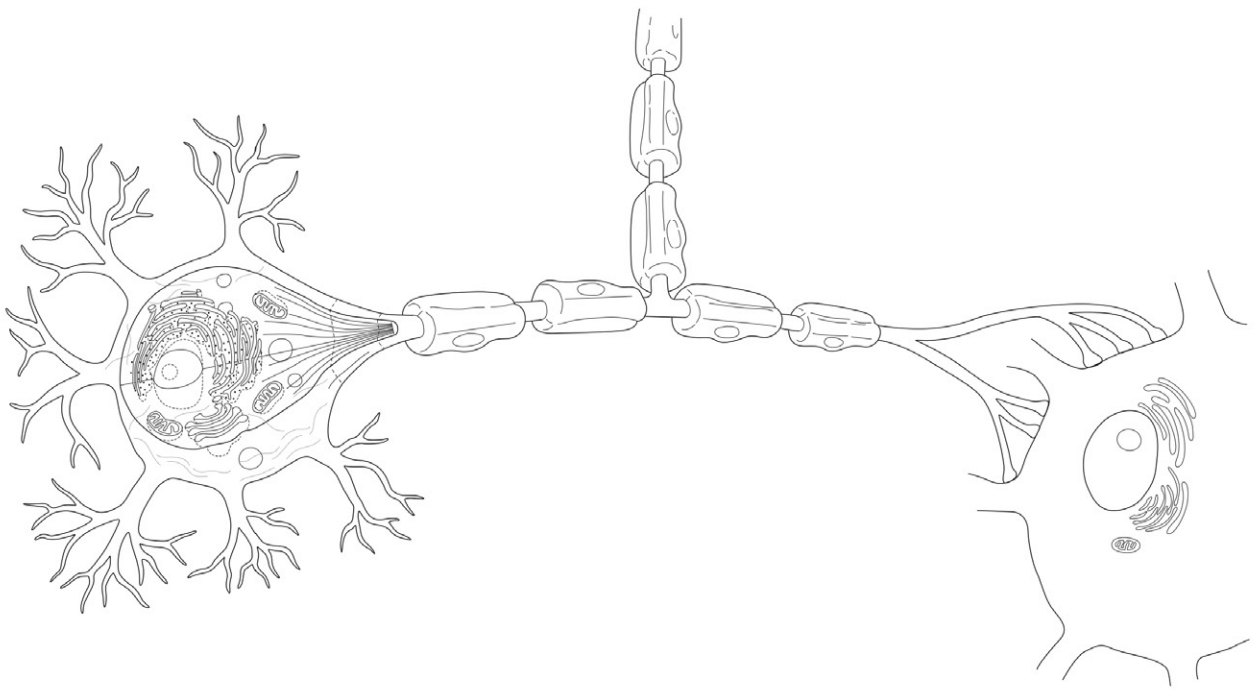

FIGURE **12.1** Multipolar neuron.

SEM of oligodendrocyte.

EXERCISES

We begin our study of the **nervous system** in this unit, and we explore it further over the next three units. The nervous system consists of the *brain*, *spinal cord*, and *peripheral nerves*. The organs of the nervous system are composed of cells called *neurons* that maintain homeostasis in the body by regulating the activity of other cells. They accomplish this by sending nerve impulses, also known as **action potentials**, to their target cells. Neurons are supported by a variety of smaller cells collectively called *neuroglial cells*, and these two cell types, along with a specialized extracellular matrix, make up **nervous tissue**.

In the following exercises we examine the cells and structure of nervous tissue. Then we find out how the structure of neurons relates to their function as we explore nervous system physiology.

Exercise 12-1

Neurons and Neuroglia

MATERIALS

- ❑ Neuron models
- ❑ Modeling clay in four colors
- ❑ Nervous tissue slide
- ❑ Myelin sheath slide
- ❑ Light microscope
- ❑ Colored pencils

There are two types of cells within nervous tissue: neurons and neuroglial cells (Fig. 12.2). **Neurons** (NOOR-ahnz) are large cells that transmit and generate messages in the form of nerve impulses, or **neuronal action potentials**. Although they vary widely in size and structure, most have the following three components: the cell body, one axon, and one or more dendrites (Fig. 12.3).

1. **Cell body.** The **cell body** is the biosynthetic center of the neuron, containing the nucleus and many of the organelles. Its cytoskeleton consists of densely packed intermediate filaments known as **neurofilaments** that compartmentalize the rough endoplasmic reticulum into dark-staining structures called **Nissl bodies**. Near the axon and dendrites, neurofilaments form larger **neurofibrils**, which extend out into these processes. Cell bodies are often found in clusters.

2. **Axon.** A single **axon** exits the cell body at the **axon hillock**. Just distal to the axon hillock is a region called the **initial segment**, also known as the *trigger zone*, which generates signals in the form of action potentials that are transmitted to other neurons, muscle cells, and glands. Action potentials are generated across an axon's plasma membrane, known as the **axolemma** (aks-oh-LEM-uh). The action potential spreads, or *propagates*, down the entire length of the axon. Some axons have branches known as **axon collaterals** that stem off of the main axon at right angles. Both the main axon and the axon collaterals end in multiple terminal branches called **telodendria** (tee-loh-DEN-dree-uh). At the end of each telodendrion is an **axon terminal**, which is sometimes called a synaptic bulb. Recall from Unit 11 that the axon terminal contains synaptic vesicles with neurotransmitters that communicate with the axon's target cell.

3. **Dendrites.** Most neurons have one or more branching processes called **dendrites** (DEN-dryt'z) that receive signals from other neurons. They can transmit these signals to the neuron's cell body, but they are not capable of generating action potentials.

Neurons are classified structurally on the basis of the number of processes extending from

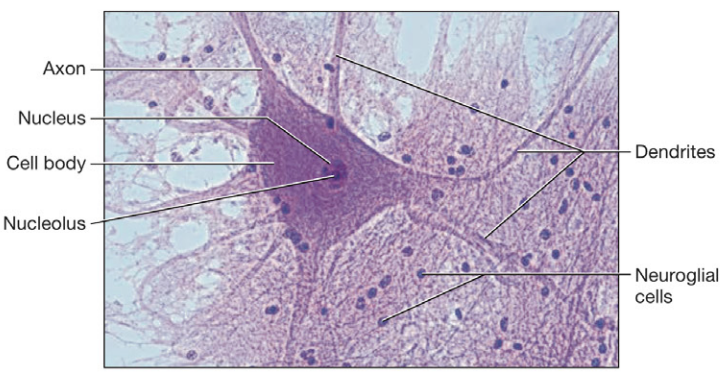

FIGURE **12.2** Nervous tissue, photomicrograph (motor neuron smear).

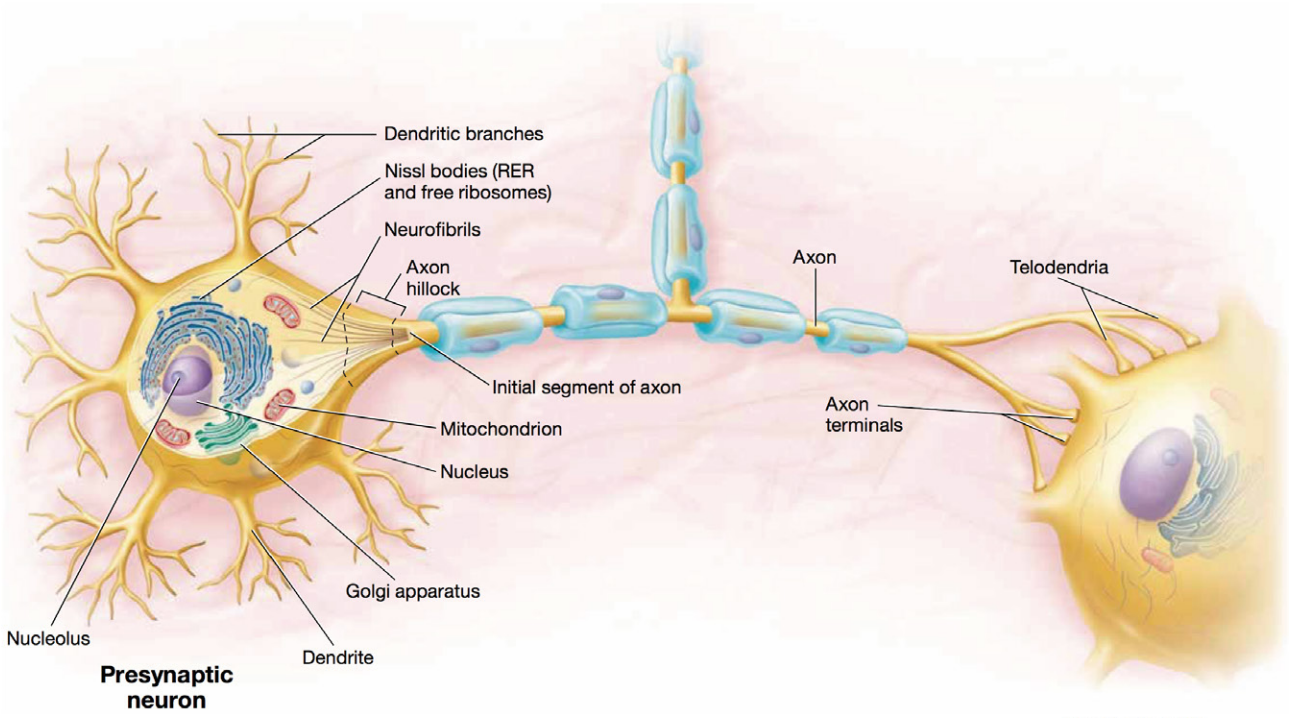

FIGURE **12.3** Multipolar neuron.

the cell body (Fig. 12.4). The most common type of neuron is the large multipolar neuron, which has three or more processes—specifically, one axon and two or more dendrites. Most multipolar neurons resemble highly branched trees and have hundreds to thousands of dendrites.

Both bipolar neurons and pseudounipolar neurons are rarer than multipolar neurons and are associated with the senses. **Bipolar neurons** have one axon and one dendrite and are found in special sense organs such as the olfactory epithelium and the retina of the eye. **Pseudounipolar neurons** are found in the skin and have only one process. A short distance from the cell body, the process branches like a "T" into a **peripheral process**, which brings a stimulus from a sensory receptor to the cell body, and a **central process**, which transmits a signal from the cell body to the spinal cord. Both the central process and the peripheral process can generate action potentials and are therefore axons. Pseudounipolar neurons are sensory neurons that detect stimuli such as fine touch, pressure, and pain.

Neuroglial cells (noor-oh-GLEE-uhl) are much smaller than neurons, and they outnumber neurons about 50 to 1—no small feat considering that the nervous system contains about a trillion neurons. Following are the neuroglial cells of the central nervous system (CNS; brain and spinal cord) and the peripheral nervous system (PNS; cranial and spinal nerves). The neuroglia are shown in Figure 12.5, but note that this figure shows only neuroglial cells of the CNS.

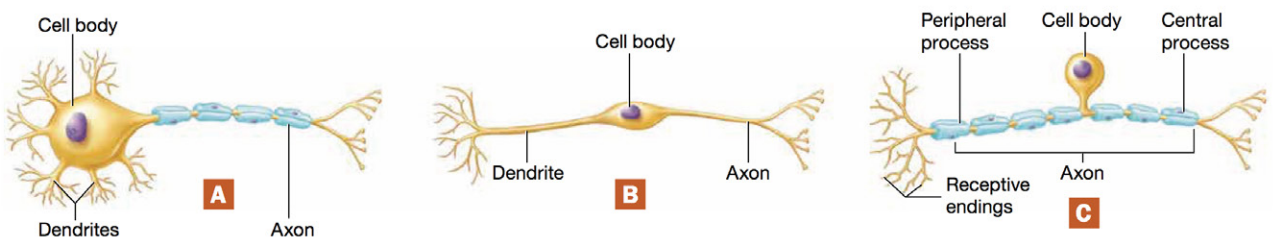

FIGURE **12.4** Types of neurons: (A) multipolar neuron; (B) bipolar neuron; (C) pseudounipolar neuron.

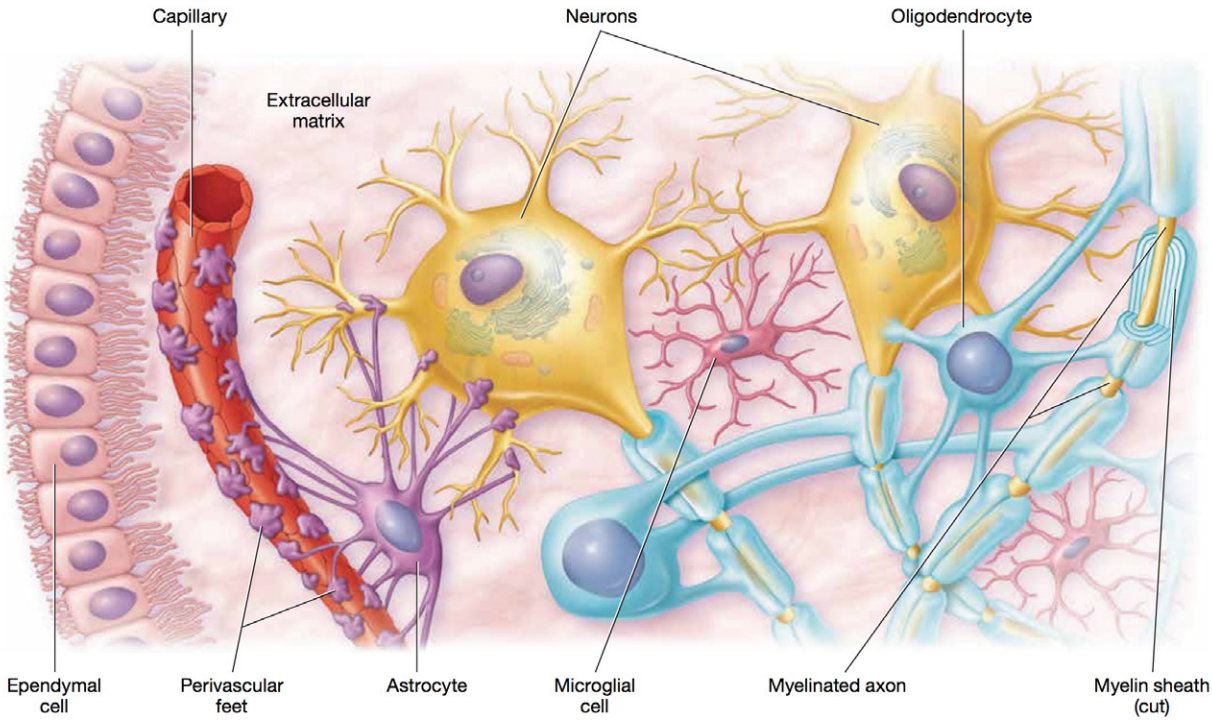

FIGURE **12.5** Neuroglial cells of the CNS.

1. **Astrocytes. Astrocytes** are the most numerous neuroglial cell type in the CNS. These star-shaped cells have many functions, including anchoring neurons and blood vessels in place with processes called **perivascular feet,** and regulating the extracellular environment of the brain. In addition, they facilitate the formation of the **blood-brain barrier,** created by tight junctions in the brain capillaries the blood–brain-barrier prevents many substances in the blood from entering the brain tissue.
2. **Oligodendrocytes. Oligodendrocytes** (oh-lig-oh-DEN-droh-syt'z) have long extensions that wrap around the axons of certain neurons in the CNS to form a structure called the *myelin sheath*. Note that one oligodendrocyte can myelinate segments of several axons.
3. **Microglial cells.** The small **microglial cells** (my-kroh-GLEE-uhl) are very active phagocytes that clean up debris surrounding neurons. Microglia also degrade and ingest damaged or dead neurons.
4. **Ependymal cells.** The ciliated **ependymal cells** (eh-PEN-dih-muhl) line the hollow spaces of the brain and spinal cord. They assist in forming the fluid that bathes the brain and spinal cord, called **cerebrospinal fluid,** and circulate it with their cilia.
5. **Schwann cells. Schwann cells** form the myelin sheath around the axons of certain neurons in the PNS. A Schwann cell can myelinate a segment of only one axon.
6. **Satellite cells. Satellite cells** surround the cell bodies of neurons in the PNS. These cells enclose and support the cell bodies, and regulate the extracellular environment around them.

The **myelin sheath** (MY-lin) is composed of many layers of the plasma membrane of the oligodendrocyte or Schwann cell wrapped around an axon. It performs critical functions within the nervous system, including protecting and insulating the axons and speeding up conduction of action potentials. As you can see in Figure 12.6, Schwann cells and oligodendrocytes myelinate axons differently. Schwann cells, which myelinate a segment of only a single axon, wrap clockwise around the axon (Fig. 12.6A). The outer edge of the Schwann cell, called the **neurilemma** (noor-ih-LEM-uh), contains most of its cytoplasm and the nucleus. Oligodendrocytes, on the other hand, wrap segments of multiple axons in a counterclockwise direction (Fig. 12.6B).

Notice that there are small gaps in the myelin sheath between each oligodendrocyte arm or Schwann cell where the plasma membrane of the axon is exposed. These gaps are called **nodes of Ranvier** (rahn-vee-ay), and the myelin-covered segments between the nodes are **internodes.** You can see these nodes of Ranvier and internodes in Figures 12.6 and 12.7.

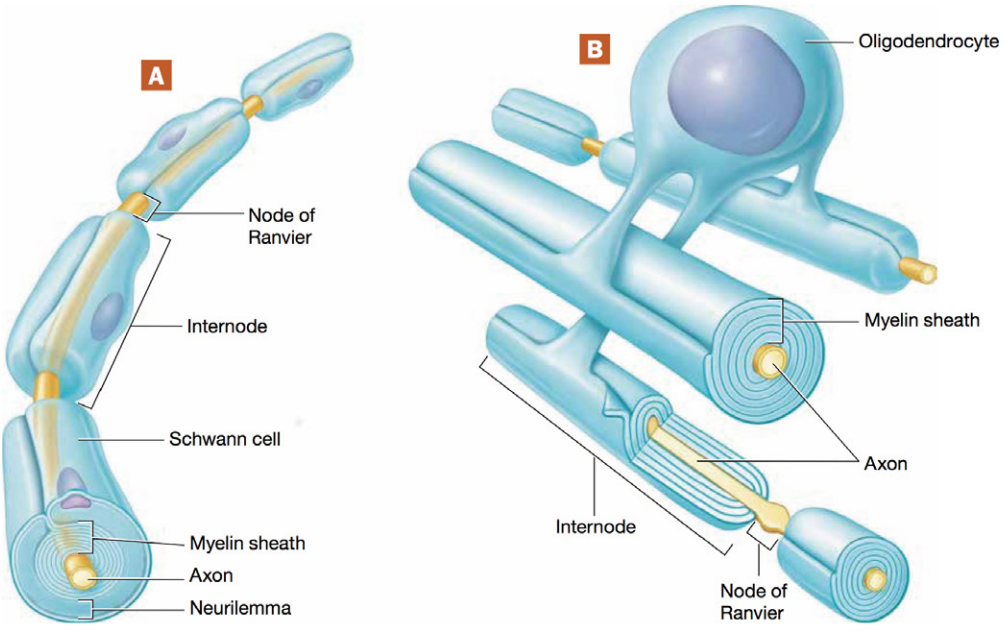

FIGURE **12.6** Myelin sheath: (A) Schwann cells around a PNS axon; (B) an oligodendrocyte around multiple CNS axons.

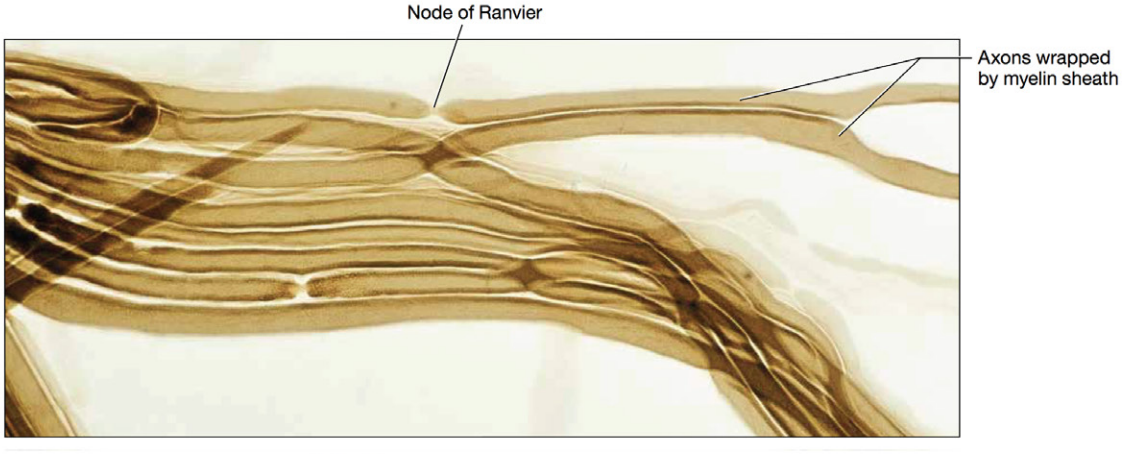

FIGURE **12.7** Myelin sheath, photomicrograph.

Procedure 1 Model Inventory for Nervous Tissue

Identify the following structures of nervous tissue on models and diagrams using your textbook and this unit for reference. As you examine the anatomical models and diagrams, record the name of the model and the structures you were able to identify on the model inventory in Table 12.1. When you have completed the activity, answer Check Your Understanding questions 1 through 4 (p. 331–332).

1. Neuron
   a. Cell body
      (1) Nissl bodies
      (2) Neurofibrils
   b. Axon
      (1) Axon hillock
      (2) Initial segment (trigger zone)
      (3) Axolemma
      (4) Telodendria
   c. Dendrite(s)
2. Multipolar neuron
3. Bipolar neuron
4. Pseudounipolar neuron
5. Neuroglial cells
   a. Astrocytes
   b. Oligodendrocytes
   c. Microglial cells
   d. Ependymal cells
   e. Schwann cells
   f. Satellite cells
6. Other structures
   a. Myelin sheath
   b. Neurilemma
   c. Node of Ranvier
   d. Internode

TABLE 12.1 Model Inventory for Nervous Tissue

Model/Diagram	Structures Identified

Procedure 2 Building a Myelin Sheath

In this exercise you will demonstrate the difference between the methods by which Schwann cells and oligodendrocytes myelinate the axons of neurons in the peripheral nervous system and the central nervous system, respectively.

1. Obtain four colors of modeling clay (blue, green, yellow, and red, if available).
2. Use the following color code to build three central nervous system (CNS) axons, one peripheral nervous system (PNS) axon, one oligodendrocyte, and two Schwann cells:
   a. CNS axons: blue
   b. PNS axon: green
   c. Oligodendrocyte: yellow
   d. Schwann cells: red
3. Build your oligodendrocyte so it reaches out to myelinate the three CNS axons.
4. Build your Schwann cells so they myelinate the single PNS axon, making sure to leave a gap for the node of Ranvier. Be sure to pay attention to the direction in which oligodendrocytes and Schwann cells myelinate their axons (clockwise or counterclockwise).

Procedure 3 Microscopy of Nervous Tissue

Let's now identify some of the structures from the previous procedures on microscope slides. You will examine two tissue sections:

1. **Motor neuron smear.** On this slide you should see many multipolar neurons surrounded by many, much smaller, neuroglial cells (they may look like purple dots; refer to Fig. 12.2, p. 317). As you scan the slide with the low-power objective, find a well-stained neuron, and move the objective lens to high power. Look for Nissl bodies, and try to identify the single axon and the axon hillock. (This may be difficult, so don't get discouraged if all of the processes look similar.)
2. **Myelin sheath.** A longitudinal section of axons treated with a stain specific for the components of myelin (often osmium) is useful for seeing the sheath itself and also the nodes of Ranvier (refer back to Fig. 12.7, p. 320). You will likely need to use the high-power objective to see the nodes.

1. Obtain prepared slides of a motor neuron smear and the myelin sheath.
2. Use your colored pencils to draw what you see, and label your drawing with the following terms.

1. Nervous tissue
   a. Cell body
   b. Axon
   c. Dendrites
   d. Neuroglial cells

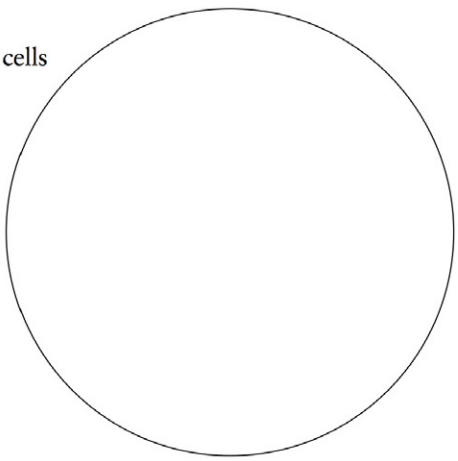

2. Myelin sheath
   a. Axon with myelin sheath
   b. Node of Ranvier
   c. Internode

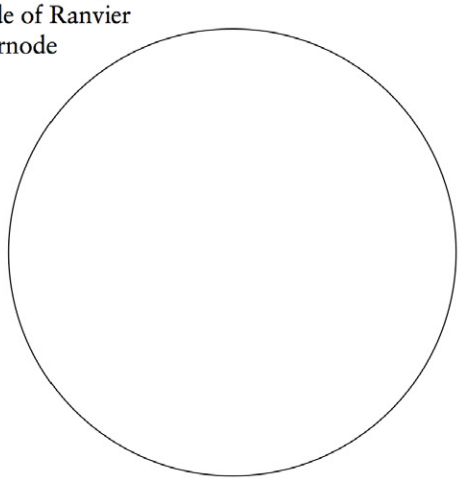

Procedure 4 Time to Draw

In the space below, draw, color, and label one of the neuron models that you examined. In addition, write the function of each structure that you label.

Exercise 12-2

Nervous Tissue Physiology

Neurons communicate with one another and with their target cells at a junction called a **synapse** (SIN-apz). In Unit 11 you learned about a type of synapse called the *neuromuscular junction* (NMJ). The synapse between two neurons is similar to the NMJ and consists of three parts (Fig. 12.8):

1. **Presynaptic neuron.** The neuron that sends the signal is called the **presynaptic neuron.** The axon terminals of the presynaptic neuron contain synaptic vesicles with neurotransmitters.
2. **Synaptic cleft.** As we saw with the NMJ, the two neurons in a neuronal synapse are also separated by a narrow space. This space, called the **synaptic cleft,** is filled with extracellular fluid, enzymes, and other proteins.
3. **Postsynaptic neuron.** The neuron that receives the message is the **postsynaptic neuron.** Its plasma membrane contains **receptors** for neurotransmitters.

When a neurotransmitter binds to receptors on the membrane of the postsynaptic neuron, it can cause one of two effects: (1) it may cause a small **depolarization** in the postsynaptic membrane that makes an action potential more likely, a change called an *excitatory postsynaptic potential* or *EPSP*; or (2) it may cause a small **hyperpolarization** in the postsynaptic membrane that makes an action potential less likely, a change called an *inhibitory postsynaptic potential* or *IPSP*. Both effects are termed **local potentials**.

If a postsynaptic neuron is stimulated to have enough EPSPs by one or more presynaptic neurons, these small depolarizations will **summate,** or add together, and distribute through the neuron's plasma membrane. If they spread to a region of the axon known as the *trigger zone* and reach a value called **threshold**, an action potential is generated.

Once the action potential is generated at the trigger zone, it is **propagated** down the length of the axon to its axon terminals in much the same way current is conducted along a wire. As the action potential reaches the axon terminal, voltage-gated calcium ion channels in the membrane open. The influx of calcium ions into the axon terminal triggers a process that releases neurotransmitters into the synaptic cleft by exocytosis. The neurotransmitters diffuse across the synaptic cleft and bind to receptors on the membrane of the postsynaptic neuron. The effects of these neurotransmitters will depend upon the type of neurotransmitter released and the type of receptor to which it binds, but it will usually be an EPSP or an IPSP.

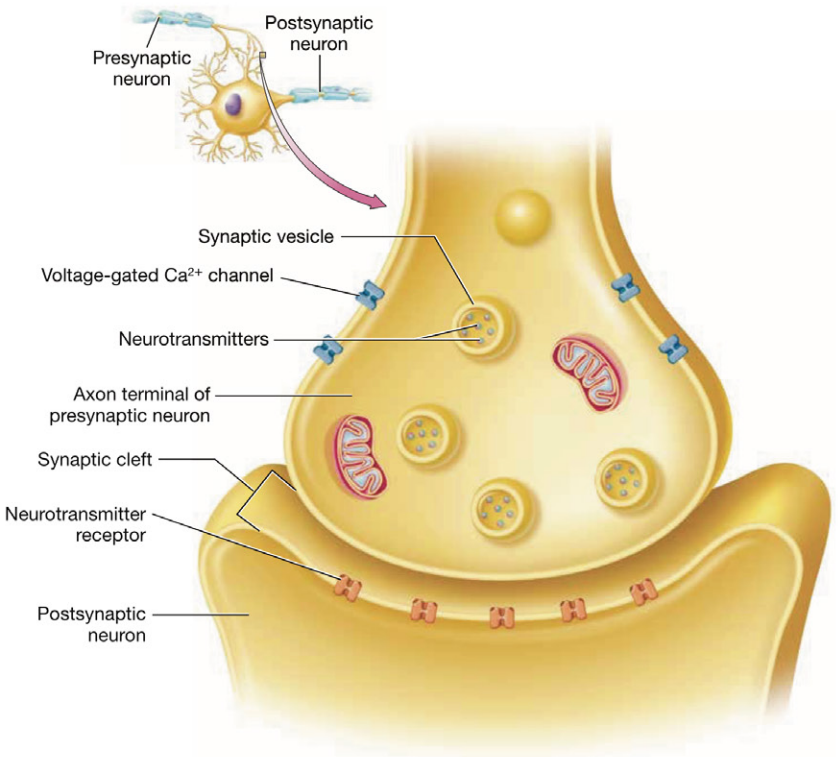

FIGURE **12.8** Structure of a neuronal synapse.

Procedure 1 Model Inventory for Parts of the Synapse

Identify the parts of the synapse on models and diagrams using your textbook and this unit for reference. As you examine the anatomical models and diagrams, record the name of the model and the structures you were able to identify on the model inventory in Table 12.1 (note that this is the model inventory from Exercise 12-1, p. 321).

1. Parts of the synapse
   a. Presynaptic neuron
   b. Axon terminal
   c. Synaptic vesicle
   d. Synaptic cleft
   e. Postsynaptic neuron
   f. Neurotransmitter receptors

Procedure 2 Time to Trace!

Let's now trace the entire series of events through a three-neuron loop, including the steps of synaptic transmission between neurons 1 and 2, the propagation of the action potential down the axon of neuron 2, and the steps of synaptic transmission that occur between neuron 2 and 3. Hints are included to ensure that you stay on the right track as you trace. You may wish to consult your textbook for more details on this process. When you have completed the activity, answer Check Your Understanding questions 5 through 7 (p. 332).

Start: neuronal action potential reaches the axon terminal of neuron 1 → _____ are released from the axon terminal by _____ → _____ diffuse across the _____ _____ and bind to _____ on the postsynaptic membrane of neuron 2, generating an excitatory local potential → if the neuron is stimulated enough times, the excitatory local potentials _____ and spread through the neuron's plasma membrane toward the axon → when the trigger zone is depolarized to _____, an _____ _____ is generated, which _____ down the axon until it reaches the axon terminals → depolarization of the axon terminal triggers the opening of _____ ion channels, and these ions enter the axon terminal → _____ are released from the axon terminal by _____ → _____ diffuse across the _____ _____ and bind to _____ on the postsynaptic membrane of neuron 3, generating an excitatory or inhibitory local potential. **End**

Procedure 3 Diagramming Your Tracing

Take the pathway that you just traced, and turn it into a diagram that contains the three neurons. Your diagram does not have to be a work of art—only a simple schematic representation of each neuron and each process is necessary. You may use the figures in this unit and your text for reference, but it is best to compose and organize your diagram in a way that makes sense to you so you may return to it for study purposes.

Name _____

Section _____ Date _____

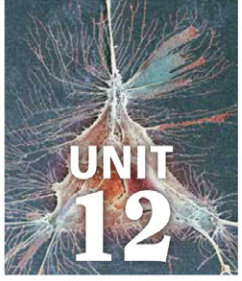

REVIEW

Check Your Recall

1 Label the following structures on Figure 12.9.

- ❑ Axon
- ❑ Axon collateral
- ❑ Axon hillock
- ❑ Cell body
- ❑ Dendrites
- ❑ Neurofibrils
- ❑ Nissl bodies
- ❑ Telodendria

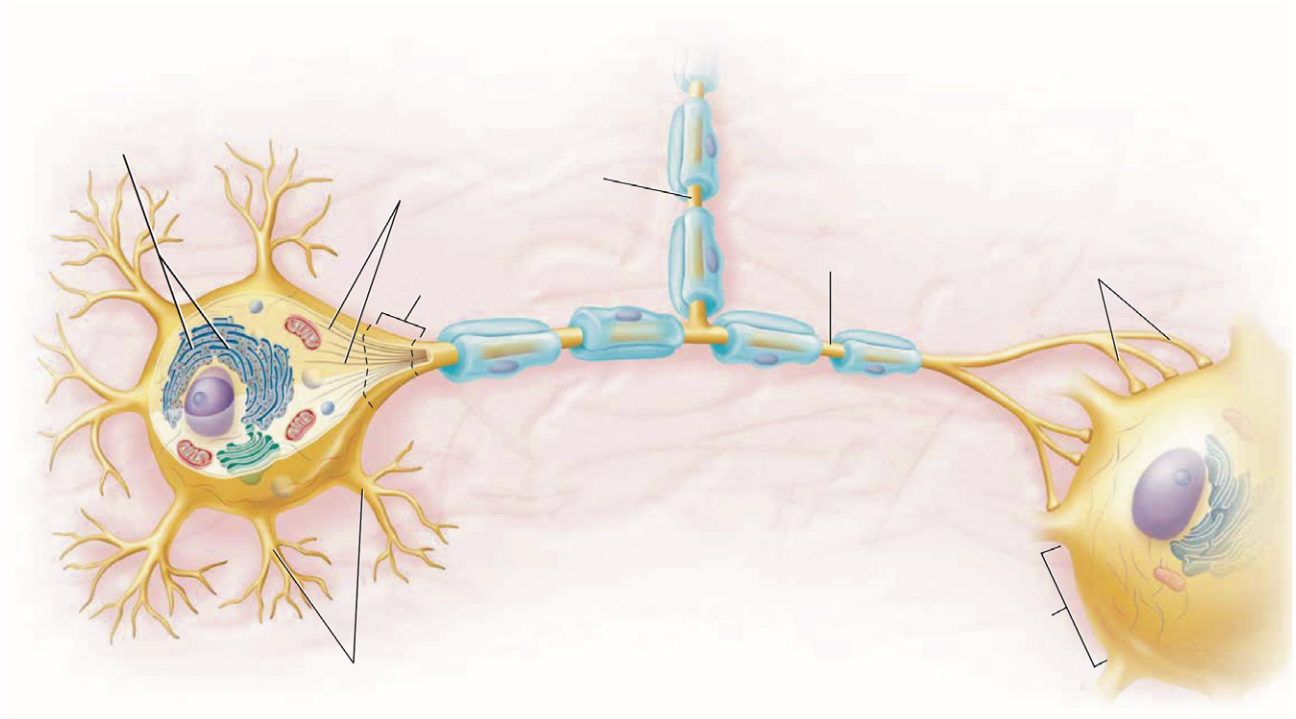

FIGURE **12.9** Neuron.

2 The neuron pictured in Figure 12.9 is a

a. pseudounipolar neuron.
b. bipolar neuron.
c. multipolar neuron.
d. unipolar neuron.

3 The main function of an axon is to

a. generate EPSPs or IPSPs when neurotransmitters bind their membranes.
b. generate and transmit signals in the form of action potentials.
c. function as the biosynthetic center of the neuron.
d. form the myelin sheath.

4 Where are synaptic vesicles located?

a. Axon terminals.
b. Dendrites.
c. Cell body.
d. Both a and b are correct.
e. All of the above.

5 *Matching:* Match the neuroglial cell with its correct function.

_____ Oligodendrocytes
_____ Astrocytes
_____ Microglial cells
_____ Schwann cells
_____ Satellite cells
_____ Ependymal cells

A. Create the myelin sheath in the PNS
B. Ciliated cells in the CNS that form and circulate cerebrospinal fluid
C. Surround the cell bodies of neurons in the PNS
D. Anchor neurons and blood vessels, maintain extracellular environment around neurons, assist in the formation of the blood-brain barrier
E. Phagocytic cells of the CNS
F. Form the myelin sheath in the CNS

6 Label the following structures on Figure 12.10.

- ❑ Internode
- ❑ Myelin
- ❑ Neurilemma
- ❑ Node of Ranvier
- ❑ Oligodendrocyte
- ❑ Schwann cell

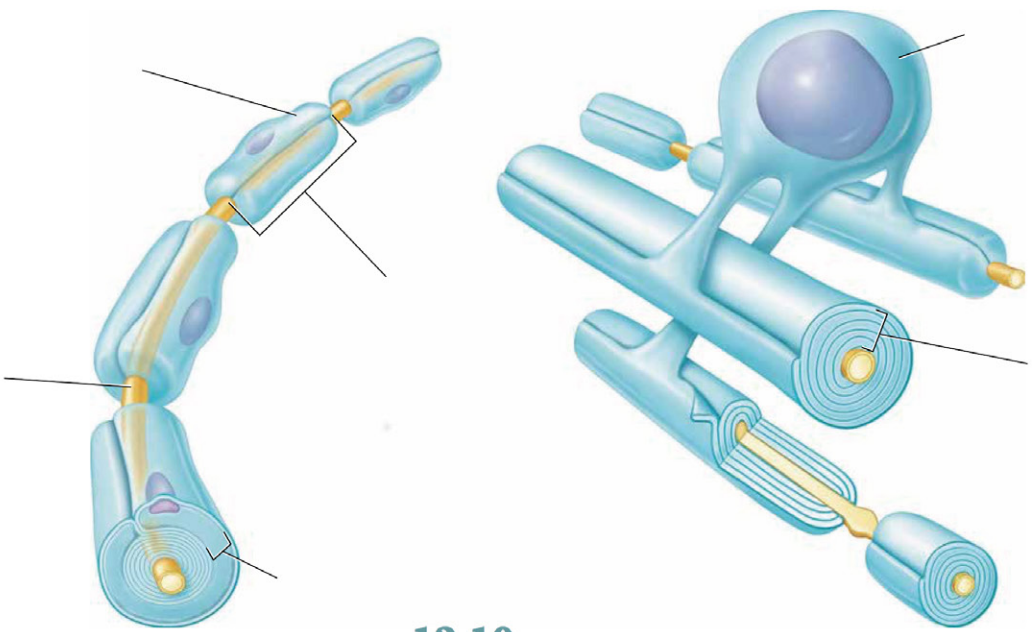

FIGURE **12.10** Myelin sheath.

Name _____

Section _____ Date _____

7 Label the following structures on Figure 12.11.

- ❑ Axon terminal of presynaptic neuron
- ❑ Neurotransmitter receptor
- ❑ Neurotransmitters
- ❑ Postsynaptic neuron
- ❑ Synaptic cleft
- ❑ Synaptic vesicle
- ❑ Voltage-gated Ca^{2+} channel

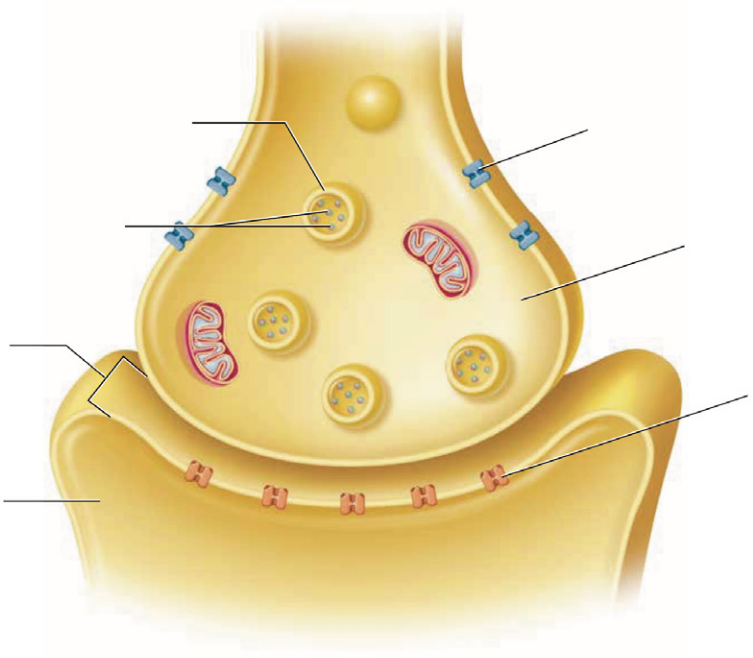

FIGURE **12.11** Structure of a neuronal synapse.

8 An action potential is generated at the

a. trigger zone of the axon.
b. postsynaptic membrane.
c. cell body.
d. axon terminal.

9 What is the difference between an excitatory postsynaptic potential and an inhibitory postsynaptic potential?

10 What triggers exocytosis of synaptic vesicles?

a. Arrival of a local potential at the cell body.
b. Hyperpolarization of the postsynaptic membrane.
c. Neurotransmitters binding to the postsynaptic membrane.
d. The influx of calcium ions into the axon terminal.

Name _____

Section _____ Date _____

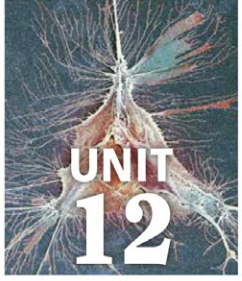

REVIEW

Check Your Understanding

Critical Thinking and Application Questions

1 You are examining a neuronal process and you find that it generates action potentials. Is this an axon or a dendrite? How can you tell?

2 You are examining another neuron, and find that it has two processes, both of which generate action potentials. What is the structural class of this neuron? How did you come to this conclusion?

3 A damaged axon in the PNS may be able to regenerate only if the cell body is intact. Why do you think that the cell body must be intact for regeneration to occur? (***Hint:*** Think about the function of the organelles and other structures located in the cell body.)

4 Multiple sclerosis is a *demyelinating* disease, in which the patient's immune system attacks and destroys the cells that form the myelin sheath in the central nervous system. What types of symptoms would you expect from such a disease? Why? Would Schwann cells or oligodendrocytes be affected? Explain.

5 The bacterium *Clostridium tetani* produces a toxin called *tetanospasmin*, the causative agent of the disease tetanus. The toxin prevents the release of inhibitory neurotransmitters in the CNS and so blocks the resulting IPSPs they would normally generate. What are some of the functions of inhibitory synapses? Considering this, what symptoms would you expect from the disease tetanus, and why? (***Hint:*** Imagine trying to stand up if all of the muscles in your lower limb contracted at the same time.)

6 Certain inhaled anesthetic agents are thought to open Cl^- channels in the membranes of postsynaptic neurons in the brain, an effect that causes IPSPs. Why might this action put a person "to sleep" during anesthesia?

7 Predict what would happen if the calcium ion channels in the axon terminal were blocked. Explain.

UNIT
13

Central Nervous System

Once you have completed this unit, you should be able to:

1. Identify structures of the brain and describe its gross anatomy.
2. Identify structures of the spinal cord and describe its anatomical organization.

Name _____ Section _____ Date _____

PRE-LAB EXERCISES

Complete the following exercises prior to coming to lab, using this lab manual and your textbook for reference.

Pre-Lab Exercise 13-1

Key Terms

You should be familiar with the following terms before coming to lab.

Term	Definition
Structures of the Brain	
Cerebral hemispheres	
Cerebral cortex	
Basal nuclei	
Corpus callosum	
Diencephalon	
Thalamus	
Hypothalamus	
Midbrain	
Pons	
Medulla oblongata	
Cerebellum	
Dura mater	

Name _____ Section _____ Date _____

Arachnoid mater _____

Pia mater _____

Ventricles _____

Dural sinuses _____

Structures of the Spinal Cord

Gray matter horns (anterior, posterior, lateral) _____

Funiculi (anterior, posterior, lateral) _____

Conus medullaris _____

Filum terminale _____

Cauda equina _____

Pre-Lab Exercise 13-2

Brain Anatomy

Label and color the diagrams of the brain in Figures 13.1 through 13.4 with the terms from Exercise 13-1 (p. 339). Use your text and Exercise 13-1 in this unit for reference.

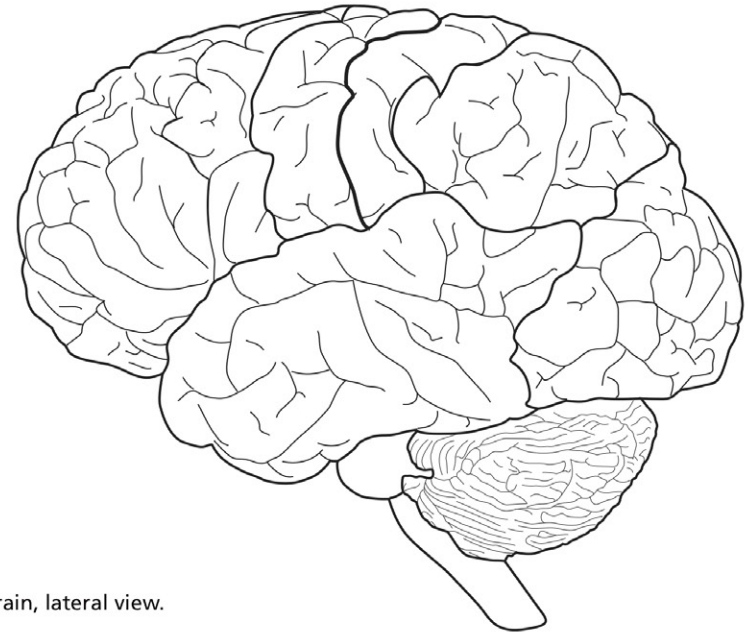

FIGURE **13.1** Brain, lateral view.

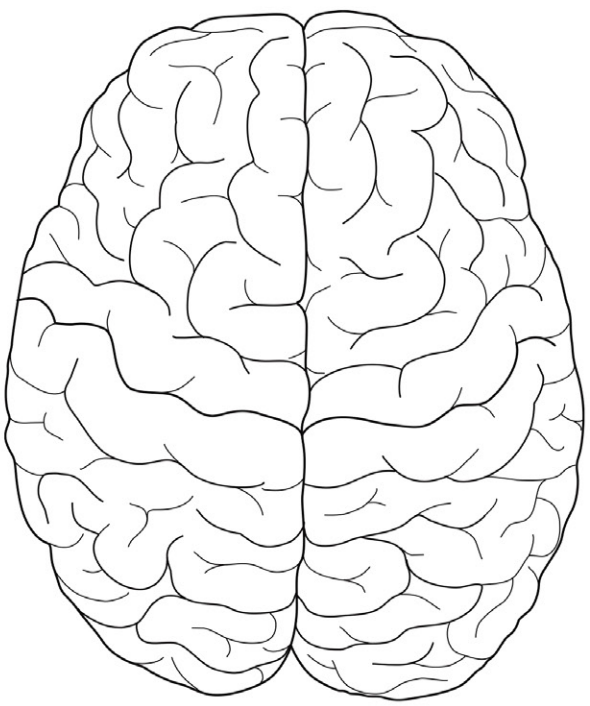

FIGURE **13.2** Brain, superior view.

Name _____ Section _____ Date _____

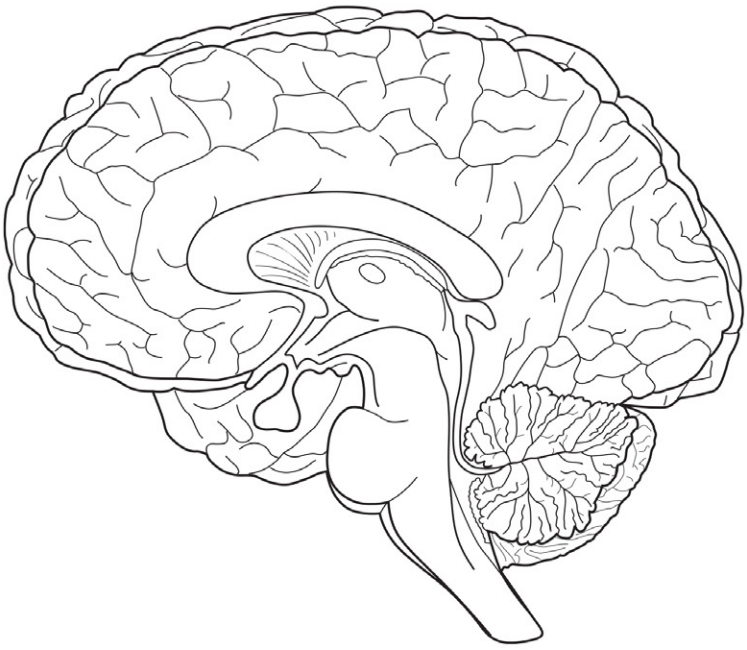

FIGURE **13.3** Brain, midsagittal section.

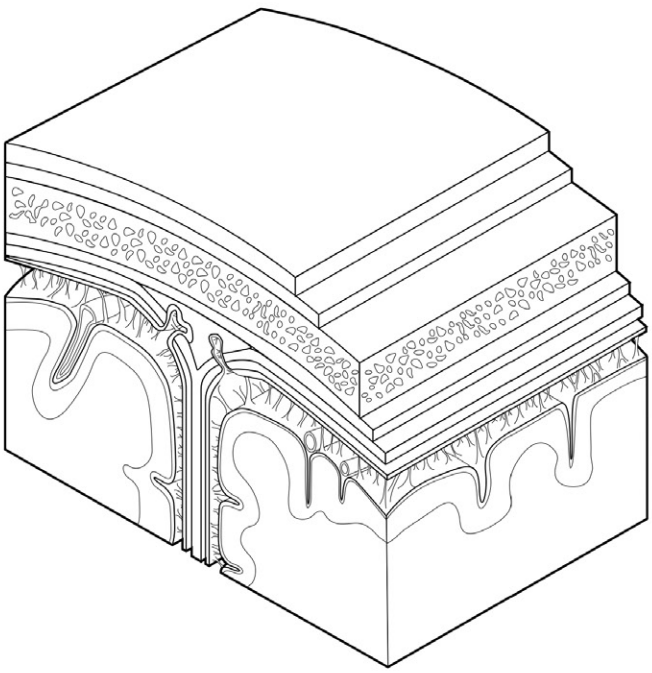

FIGURE **13.4** Brain and meninges, frontal and parasagittal section.

Pre-Lab Exercise 13-3

Spinal Cord Anatomy

Label and color the diagrams of the spinal cord in Figure 13.5 with the terms from Exercise 13-2 (p. 349). Use your text and Exercise 13-2 in this unit for reference.

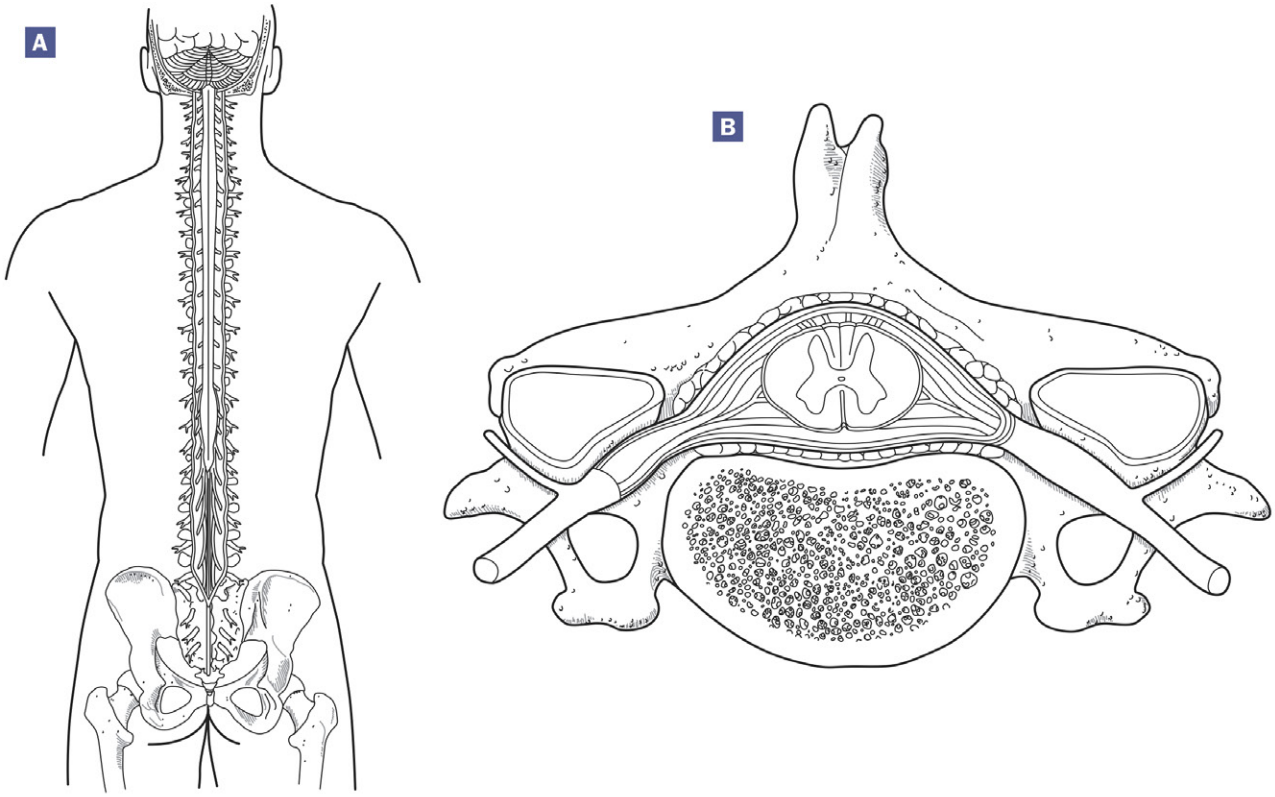

FIGURE **13.5** Spinal cord: (**A**) brain and spinal cord, posterior view; (**B**) spinal cord, transverse section in the vertebral column showing spinal meninges and associated spaces.

Human head, MRI and 3D CT scans.

EXERCISES

Recall from our study of nervous tissue that we divide the nervous system into two structural divisions: the **central nervous system** (**CNS**), which consists of the *brain* and *spinal cord*, and the **peripheral nervous system** (**PNS**), which consists of the *cranial* and *spinal nerves*. We address the structure and function of the CNS in this unit.

The anatomy of the brain and the spinal cord may seem complex, but really it simply consists of a hollow, folded tube with an enlarged end (the brain). Together these two organs monitor and maintain many homeostatic variables, interpret sensation, plan and execute movement, and control our higher brain functions. The anatomy of both organs will be explored in the three exercises in this unit.

Exercise 13-1

Anatomy of the Brain

MATERIALS

- ❑ Brain models: whole and sectioned
- ❑ Ventricle models
- ❑ Brainstem models
- ❑ Dural sinus model
- ❑ Sheep brain
- ❑ Hammer and chisel (if the brain is still in the skull)
- ❑ Dissection equipment and trays
- ❑ Colored pencils

The **brain** is the most complex organ of the nervous system, consisting of a folded, hollow, whitish-gray mass of nervous tissue, connective tissue, and modified epithelium. It is divided into four regions: the *cerebral hemispheres* (collectively called the *cerebrum*), the *diencephalon*, the *cerebellum*, and the *brainstem*. The brain contains hollow spaces called **ventricles** that are filled with a fluid similar to plasma called **cerebrospinal fluid** (seh-ree-broh-SPY-nuhl; **CSF**). As you can see in Figure 13.6, the largest of the ventricles, called the **lateral ventricles**, are located in the right and left cerebral hemispheres. Note in Figure 13.6A that the lateral ventricles resemble rams' horns when viewed from the anterior side. Indeed, the different regions of each lateral ventricle are named *horns*: the *anterior*, *posterior*, and *inferior horns*.

The anterior horns of the two lateral ventricles are connected by a small opening called the *interventricular foramen* (remember from the bone units that "foramen" means "hole"). This foramen leads to the smaller **third ventricle**, which is housed within the diencephalon. The third ventricle is continuous with the **fourth ventricle**, found in the brainstem, via a small canal called the **cerebral aqueduct**. The fourth ventricle is continuous with a canal that runs down the central spinal cord called the **central canal**.

Within each of the four ventricles we find collections of blood vessels known as **choroid plexuses** (KOHR-oyd; see Fig. 13.9). As blood flows through the choroid plexuses, fluid filters out into the ventricles, and at that point is called CSF. The

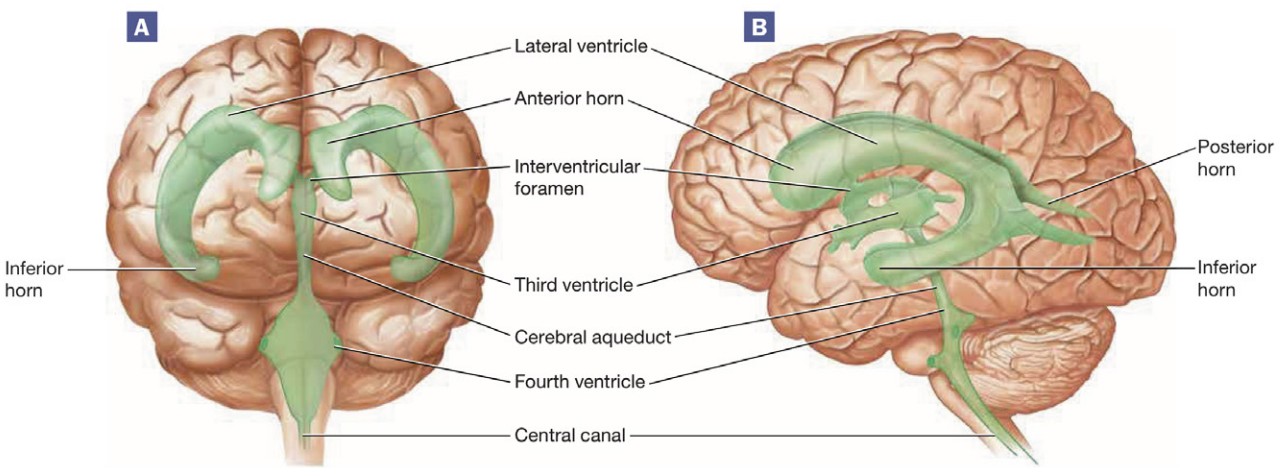

FIGURE **13.6** Ventricles: (**A**) anterior view; (**B**) left lateral view.

largest choroid plexuses are within the lateral ventricles. Recall from Unit 12 that the ventricles are lined by neuroglial cells called ependymal cells, whose cilia beat to circulate CSF. One of the main functions of CSF is to reduce brain weight, as the brain is buoyant in the CSF. Without CSF, your brain literally would crush itself under its own weight.

The **cerebrum** (seh-REE-brum) is the most superior portion of the brain and is responsible for the brain's cognitive functions, including learning and language, conscious interpretation of sensory information, conscious planning of movement, and personality (Fig. 13.7). The two cerebral hemispheres are separated from one another by a deep groove called the **longitudinal fissure**, and they are separated from the cerebellum by the **transverse fissure**. The cerebral surface consists of elevated ridges called **gyri** (JY-ree) and shallow grooves called **sulci** (SUL-kee). The cerebrum consists of five lobes: the **frontal, parietal, temporal, occipital,** and deep **insula** lobes (remember this last one by the mnemonic "the *insula* is *insula*ted"; note the insula is not visible in the figure). Notice that the **lateral sulcus** separates the frontal and temporal lobes and the **central sulcus** separates the frontal and parietal lobes. On either side of the central sulcus are two prominent gyri: the anterior **precentral gyrus,** which houses the primary motor cortex, and the posterior **postcentral gyrus,** which houses the primary somatosensory cortex. A less prominent sulcus, the *parieto-occipital sulcus*, separates the parietal and occipital lobes.

The outer 2 millimeters of the cerebrum is a region known as the **cerebral cortex** (Fig. 13.8). Here we find unmyelinated parts of the cerebral neurons, including cell bodies, dendrites, and unmyelinated axons. As you can see in the figure, the

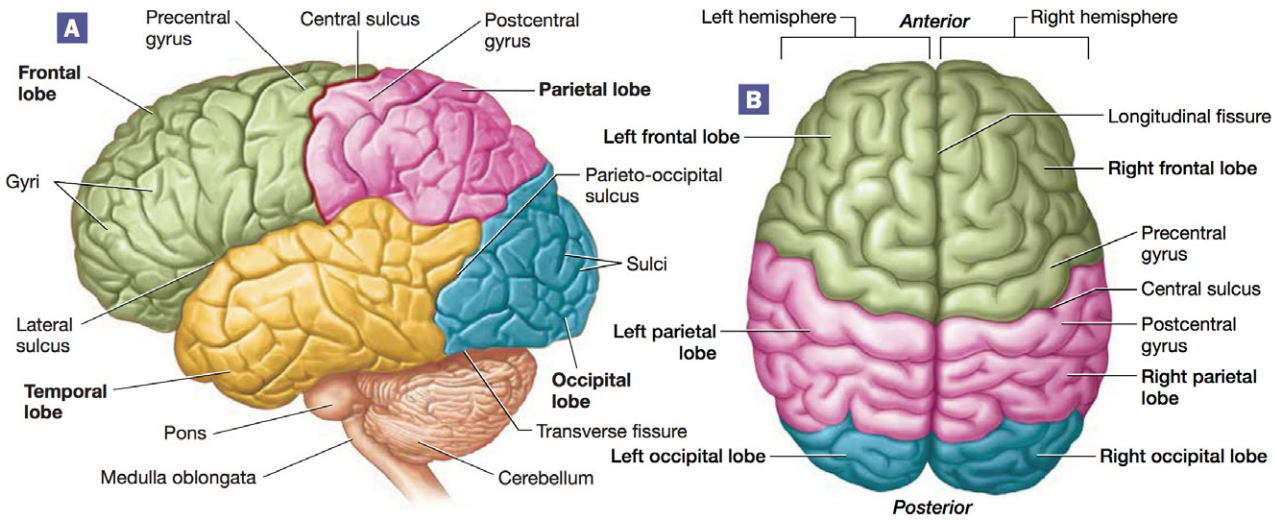

FIGURE **13.7** Brain: (A) lateral view; (B) superior view.

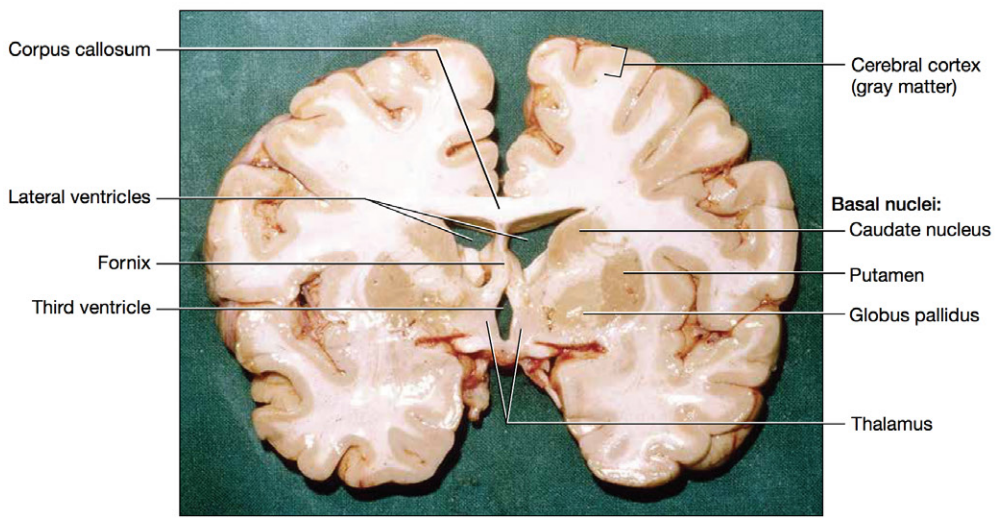

FIGURE **13.8** Frontal section through the brain.

lack of myelin gives the cerebral cortex a gray-brown color, and for this reason it is called **gray matter.** The cell bodies and processes of the cerebral cortex communicate with other parts of the nervous system by bundles of myelinated axons called **white matter.** The largest tract of cerebral white matter is called the **corpus callosum** (KOHR-pus kal-OH-sum), which connects the right and left cerebral hemispheres. Another prominent tract of white matter visible inferior to the corpus callosum is the **fornix.**

Gray matter isn't confined to the cerebral cortex. Clusters of cell bodies called **nuclei** are found throughout the white matter of the cerebrum. An important group of nuclei, the **basal nuclei** (the *caudate nucleus*, *putamen*, and *globus pallidus*), monitors voluntary motor functions. The neurons of these nuclei are connected to other parts of the nervous system by various tracts of cerebral white matter.

Deep to the cerebral hemispheres in the central core of the brain we find the **diencephalon** (dy-en-SEF-ah-lahn), which is composed of three main parts (Fig. 13.9):

1. **Thalamus.** The **thalamus** (THAL-uh-muss), which makes up 80 percent of the diencephalon, is the large, central, egg-shaped mass of gray and white matter. There are two thalamic lobes that are connected by a small band of

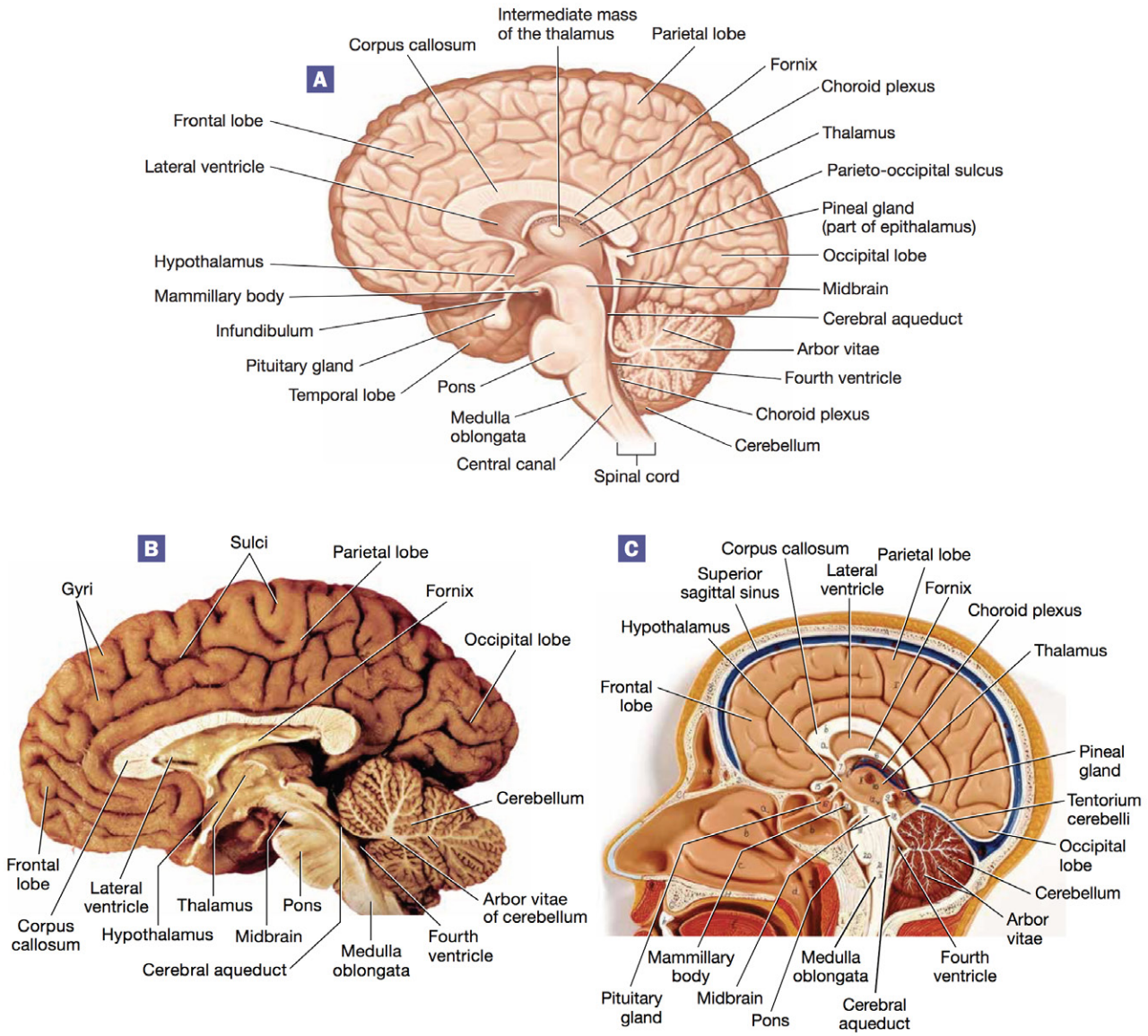

FIGURE **13.9** Midsagittal section of the brain: (A) illustration; (B) photograph; (C) anatomical model.

white matter called the *intermediate mass of the thalamus*. Functionally, the thalamus is a major integration and relay center that edits and sorts information going into the cerebrum. It essentially functions as the "gateway" into the cerebrum.

2. **Hypothalamus.** The **hypothalamus** (hy-poh-THAL-uh-muss) is the anterior and inferior component of the diencephalon. It is a deceptively small structure that contains the nuclei whose neurons help to regulate the endocrine system; monitor the sleep-wake cycle; control thirst, hunger, and body temperature; and monitor the autonomic nervous system (good things do come in small packages, after all). An endocrine organ called the **pituitary gland** (pih-TOO-ih-tehr-ee) is connected to the hypothalamus by a stalk called the **infundibulum** (in-fun-DIB-yoo-lum). On the posteroinferior surface of the hypothalamus is a pair of gray matter clusters called **mammillary bodies**, which play a role in learning and memory.
3. **Epithalamus.** The **epithalamus** is the posterior and superior part of the diencephalon. It contains an endocrine organ called the **pineal gland** (pin-EE-uhl) that secretes the hormone **melatonin** (mel-uh-TOH-nin), which helps to regulate the sleep-wake cycle.

The third major component of the brain is the large posterior **cerebellum** (sehr-eh-BELL-um). It consists of two highly convoluted lobes connected by a piece called the **vermis** (VER-miss). Like the cerebral hemispheres, the outer portion of the cerebellum, known as the **cerebellar cortex**, is gray matter, while the inner region is white matter. The cerebellar white matter is called the **arbor vitae** (AHR-bohr VEE-tay) because of its resemblance to the branches of a tree. The cerebellum coordinates and plans ongoing motor activities and is critical in reducing and preventing motor error with movement.

The final division of the brain, the **brainstem**, influences the automatic functions of the body (Fig. 13.10). The most superior portion of the brainstem is the **midbrain**, which has roles in movement, sensation, and certain reflexes. Posterior to the midbrain are two projections called the **superior and inferior colliculi** (koll-IK-yoo-lye), which relay visual and auditory stimuli to the thalamus, respectively. Inferior to the midbrain we find the rounded **pons**, which bulges anteriorly. Nuclei of the pons are involved in controlling the rhythm for breathing and the sleep cycle. The last segment of the brainstem, the **medulla oblongata** (or simply *medulla*), is continuous inferiorly with the spinal cord. The nuclei in the medulla work with those of the pons to control ventilation and are also involved in regulating heart rate, blood pressure, and certain reflexes such as vomiting.

Note in Figure 13.11 that a set of three membranes, collectively called the **meninges** (meh-NIN-jeez; singular: *meninx*), surrounds the brain. The meninges include the following:

1. **Dura mater.** The outermost meninx is the thick, leathery, double-layered **dura mater** (DOO-rah MAH-tur). The superficial *periosteal layer* is fused to the skull, and the deeper *meningeal layer* is continuous with the dura mater

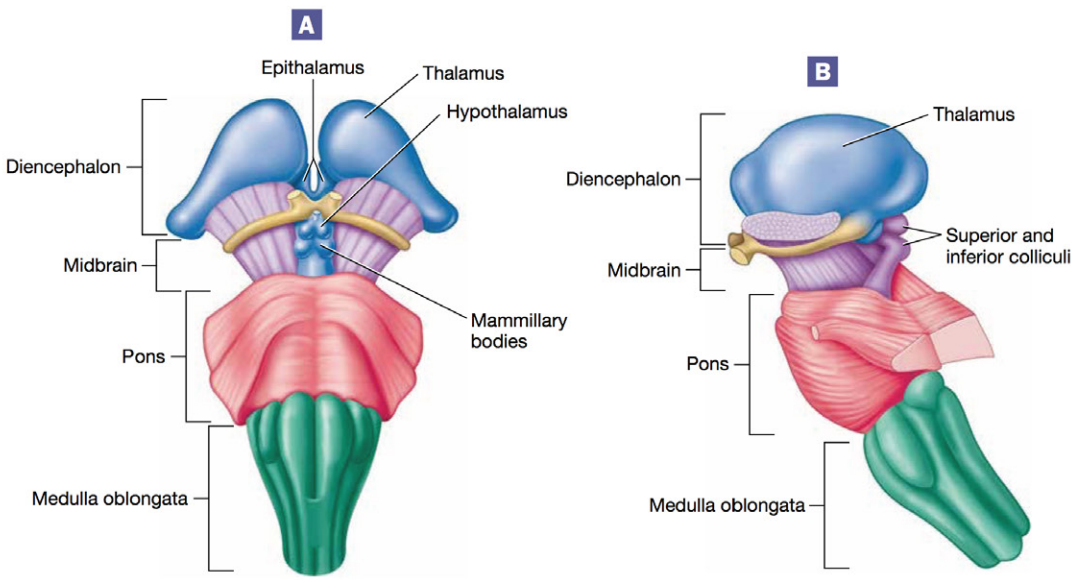

FIGURE **13.10** Diencephalon and brainstem: (**A**) anterior view; (**B**) lateral view.

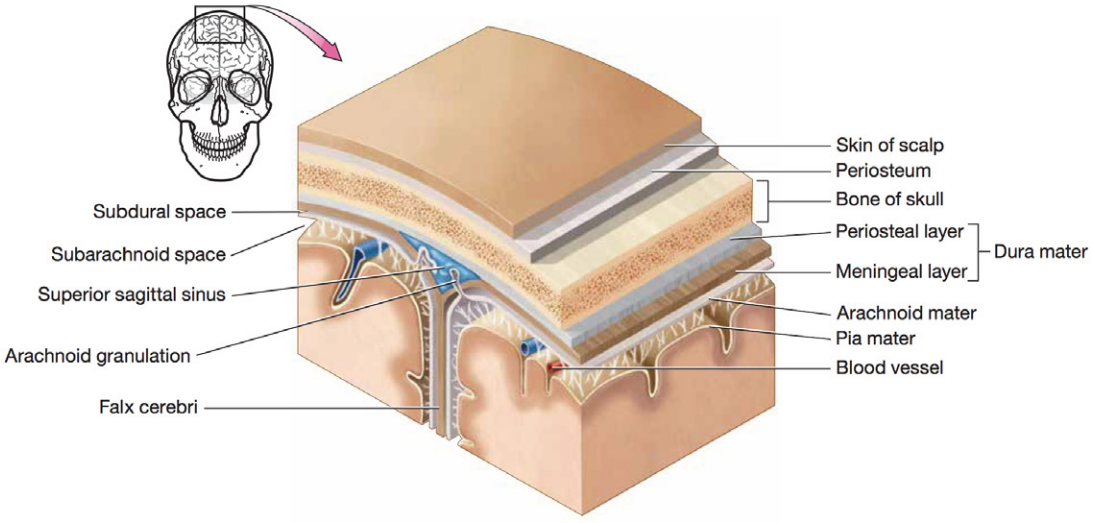

FIGURE **13.11** Brain and meninges, frontal and parasagittal section.

of the spinal cord. The two layers of the dura are fused, but in three regions the meningeal layer separates from the periosteal layer and dives into the brain to form three structures:

a. The **falx cerebri** (FALS seh-REE-bree) resides in the longitudinal fissure and forms a partition between the right and left cerebral hemispheres.

b. The **falx cerebelli** (sehr-eh-BELL-ee) separates the two cerebellar hemispheres.

c. The **tentorium cerebelli** resides in the transverse fissure and separates the cerebrum from the cerebellum (Fig. 13.9C).

At these locations there are spaces between the two dural layers collectively called the **dural sinuses** (see Fig. 18.11, p. 480). All deoxygenated blood from the brain drains into the dural sinuses, which in turn drain into veins exiting the head and neck. You can see the large superior sagittal sinus, which runs along the longitudinal fissure, in Figures 13.11 and 13.12.

2. **Arachnoid mater.** The middle meninx, the **arachnoid mater** (ah-RAK-noyd), is separated from the dura by a potential space called the **subdural space.** Small bundles of the arachnoid mater called the **arachnoid granulations** (or **arachnoid villi**) project into the dural sinuses and allow CSF to reenter the blood. You can see the pattern of CSF circulation from its formation by the choroid plexuses to its return to the blood in Figure 13.12.

3. **Pia mater.** The thinnest, innermost meninx is the **pia mater** (PEE-ah). The pia mater clings to the surface of the cerebral hemispheres and follows the contours of the sulci and gyri. It is richly supplied with blood vessels. There is a space between the pia mater and the arachnoid mater, called the **subarachnoid space,** which is filled with CSF.

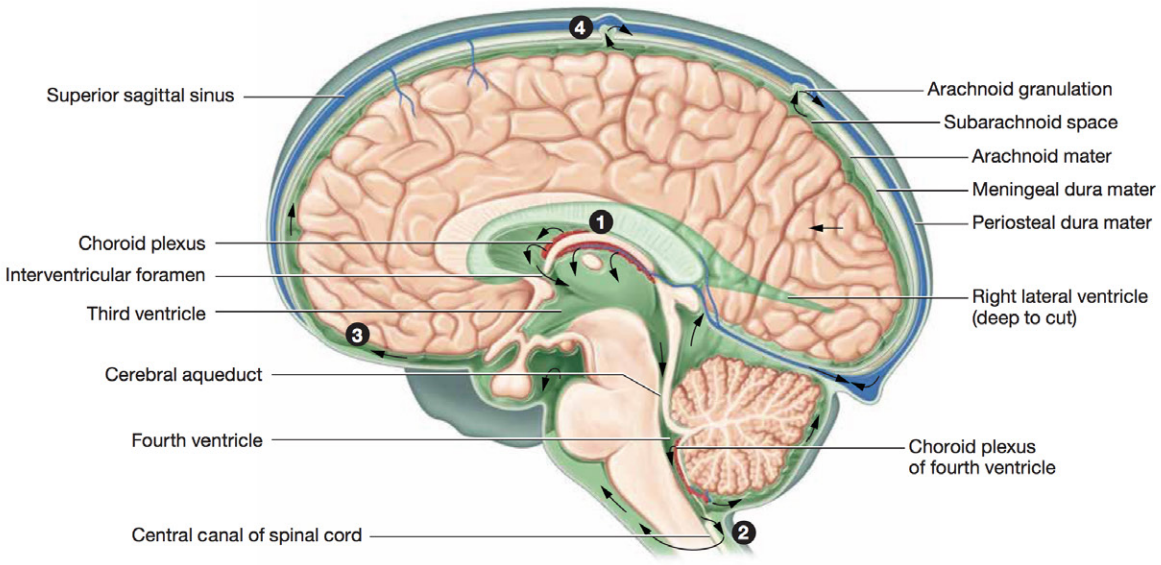

1. CSF is produced by the choroid plexuses of each ventricle.
2. CSF flows through the ventricles and into the subarachnoid space. Some CSF flows through the central canal of the spinal cord.
3. CSF flows through the subarachnoid space.
4. CSF is absorbed into the dural venous sinuses via the arachnoid granulations.

FIGURE **13.12** Circulation of CSF through the brain and spinal cord.

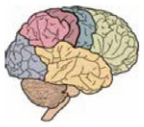

Procedure 1 Model Inventory for the Brain

Identify the following structures of the brain on models and diagrams, using your textbook and this unit for reference. As you examine the anatomical models and diagrams, record the name of the model and the structures you were able to identify on the model inventory in Table 13.1. The brain's structure is fairly complex, and it's best to examine models in as many different planes of section as possible. When you have completed the activity, answer Check Your Understanding questions 1 through 3 (p. 357).

1. Ventricles
   a. Lateral ventricles
   b. Third ventricle
   c. Fourth ventricle
   d. Cerebral aqueduct
   e. Choroid plexuses
2. Cerebrum
   a. Cerebral hemispheres
   b. Fissures
      (1) Longitudinal fissure
      (2) Transverse fissure
   c. Lobes of the cerebrum
      (1) Frontal lobe
      (2) Parietal lobe
      (3) Temporal lobe
      (4) Occipital lobe
      (5) Insula lobe
   d. Sulci
      (1) Lateral sulcus
      (2) Central sulcus
         (a) Precentral gyrus
         (b) Postcentral gyrus
      (3) Parieto-occipital sulcus
   e. Cerebral cortex (gray matter)
   f. Corpus callosum (cerebral white matter)
   g. Fornix
   h. Basal nuclei (these will only be visible on certain sections of the brain)
3. Diencephalon
   a. Thalamus
   b. Hypothalamus
      (1) Pituitary gland
      (2) Infundibulum
      (3) Mammillary bodies
   c. Epithalamus
      (1) Pineal gland
4. Cerebellum
   a. Vermis
   b. Cerebellar cortex
   c. Arbor vitae
5. Brainstem
6. Brain coverings
   a. Dura mater
      (1) Falx cerebri
      (2) Falx cerebelli
      (3) Tentorium cerebelli
      (4) Dural sinuses
      (5) Superior sagittal sinus
   b. Arachnoid mater
      (1) Subdural space
      (2) Arachnoid granulations
   c. Pia mater
      (1) Subarachnoid space

TABLE 13.1 Model Inventory for the Brain

Model/Diagram	Structures Identified

Procedure 2 Brain Dissection

Often structures of the brain and spinal cord are difficult to see on anatomical models. This exercise will allow you to examine these structures more closely by dissecting a preserved sheep brain. You will note that certain structures, such as the frontal lobes of the cerebral hemispheres, are proportionally smaller in the sheep than in the human brain. Note that the process of preservation makes many structures of the brain much tougher than they would be in a fresh specimen.

Safety Note
Goggles and gloves are required!

1. If the brain is still encased in the skull, you have your work cut out for you. The best way to approach extracting it from the skull is to take a hammer and chisel and gently (at least as gently as one can with a hammer and chisel) remove it piece by piece.
2. As you remove the skull, you will note a thick membrane holding the skull in place. This is the dura mater, and it can make removal of the skull somewhat difficult. Ideally, you would like to preserve the dura, but you may end up cutting through it as you remove the brain.
3. Once you have removed most of the skull, gently lift out the brain. (If you're careful, you may be able to get the brain out with the pituitary gland still attached.) You may have to loosen the remaining attachments of the dura with your finger.
4. Once the brain is out, note the thick part of the dura covering the longitudinal fissure. If you cut through this with scissors, you will enter the superior sagittal sinus.
5. Next remove the dura to reveal the thin membrane on top of the brain. This is the arachnoid mater.
6. Remove an area of the arachnoid mater to see the shiny inner membrane—the pia mater—directly touching the surface of the brain. Note that the pia mater follows the convolutions of the gyri and sulci.
7. Examine the surface anatomy of both the superior and the inferior surfaces of the sheep brain (Figs. 13.13 and 13.14).

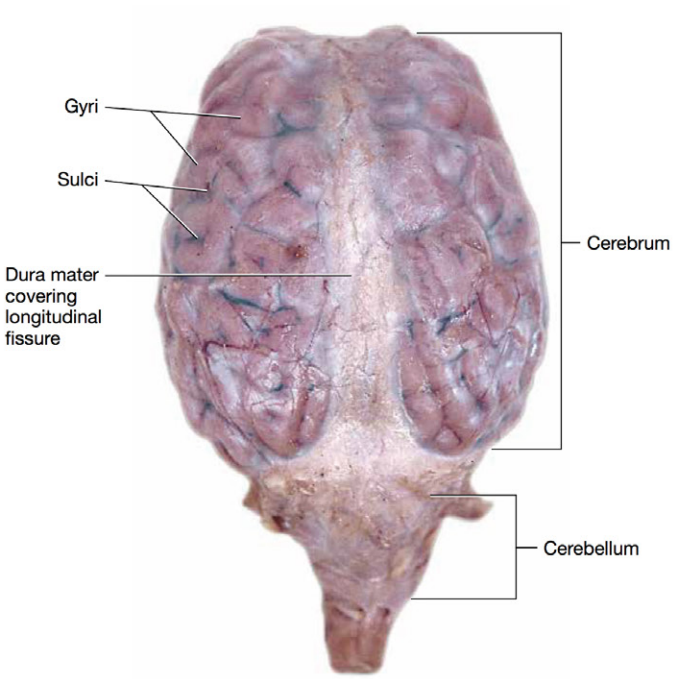

FIGURE 13.13 Superior view of the sheep brain.

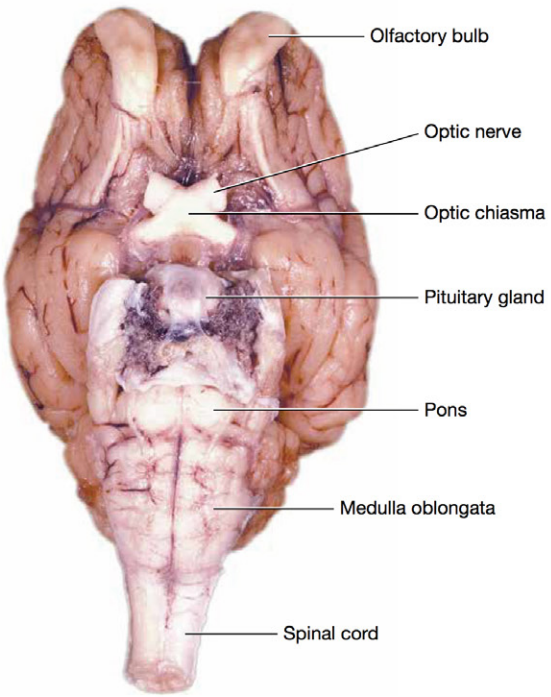

FIGURE 13.14 Inferior view of the sheep brain.

In the space provided, draw what you see on both surfaces, and label your drawing with the following structures:

- ❑ Arachnoid mater
- ❑ Cerebellum
- ❑ Cerebrum
- ❑ Dura mater
- ❑ Gyri
- ❑ Longitudinal fissure
- ❑ Medulla oblongata
- ❑ Pituitary gland
- ❑ Pons
- ❑ Sulci

8 Spread the two cerebral hemispheres, and identify the corpus callosum.

9 Make a cut down the brain's midsagittal plane to separate the two cerebral hemispheres.

10 Examine the brain's internal anatomy (Fig. 13.15), and stick your finger in the lateral ventricle. You will see (or feel) that it is much larger than it appears.

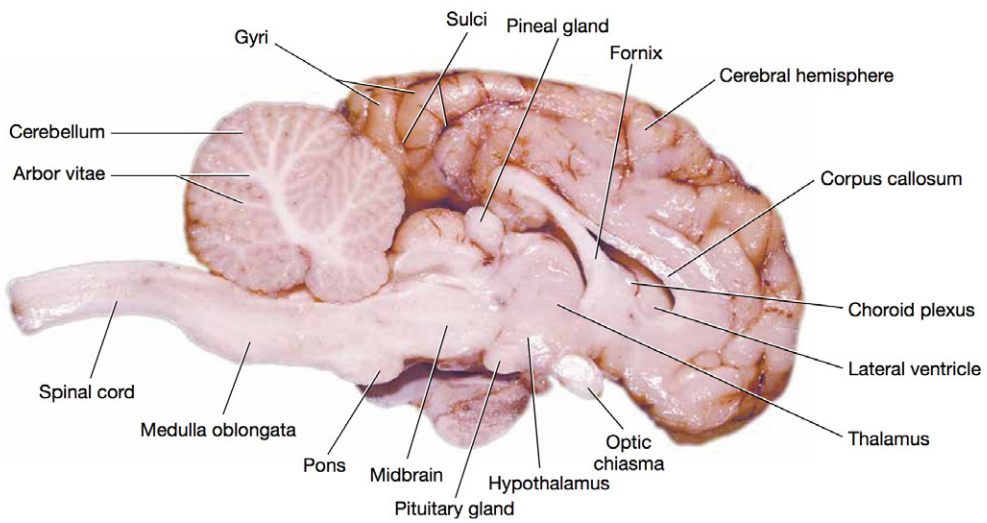

FIGURE **13.15** Lateral view of the sheep brain, midsagittal section.

Draw what you see in the space provided, and label your drawing with the following structures:

- ❑ Arbor vitae
- ❑ Choroid plexus
- ❑ Corpus callosum
- ❑ Fornix
- ❑ Hypothalamus
- ❑ Lateral ventricle
- ❑ Medulla oblongata
- ❑ Midbrain
- ❑ Pineal gland
- ❑ Pons
- ❑ Thalamus

13

11 Section one of the halves of the brain in the frontal plane, approximately along the central sulcus. Note the outer cerebral cortex (the gray matter) and the inner white matter. From this view you also can see the lateral and third ventricles. Again draw what you see in the space provided and label your drawing with the following structures (see Figure 13.8 for reference):

- ❑ Cerebral cortex
- ❑ Cerebral white matter
- ❑ Falx cerebri
- ❑ Lateral ventricle
- ❑ Thalamus
- ❑ Third ventricle

Exercise 13-2

The Spinal Cord

MATERIALS

- ❑ Spinal cord models: whole and sectioned
- ❑ Colored pencils

The medulla oblongata passes through the foramen magnum of the occipital bone and becomes the **spinal cord** (Fig. 13.16). Along its length are two notable bulges, the **cervical** and **lumbar enlargements**. The spinal cord is wider in these areas due to the high number of nerve roots that attach at these locations going to and coming from the upper and lower limbs. Notice in Figure 13.16 that the spinal cord does not extend the entire length of the vertebral column; rather, it ends between the first and second lumbar vertebrae. At this point it tapers to form the end of the spinal cord, called the **conus medullaris** (KOHN-us med-yoo-LEHR-us), which gives off a tuft of nerve roots called the **cauda equina** (KOW-dah eh-KWY-nah; "horse's tail"). The cauda equina fills the remainder of the vertebral column to the sacrum and exits out of the appropriate foramina to become spinal nerves.

Like the brain, the spinal cord is protected by a set of **spinal meninges**, which are continuous with the cranial meninges (Figs. 13.17 and 13.18). The cranial and spinal meninges are similar in name and structure: the dura mater is the outer meninx; the arachnoid mater is the middle meninx, which is separated from the dura by a thin potential space called the subdural space; and the pia mater is the inner meninx, which is separated from the arachnoid mater by the CSF-filled subarachnoid space.

There are a few notable differences between the cranial and spinal meninges. For one, the spinal dura mater consists of only *one* layer rather than two like the cranial dura. This single dural layer does not attach to the vertebral column,

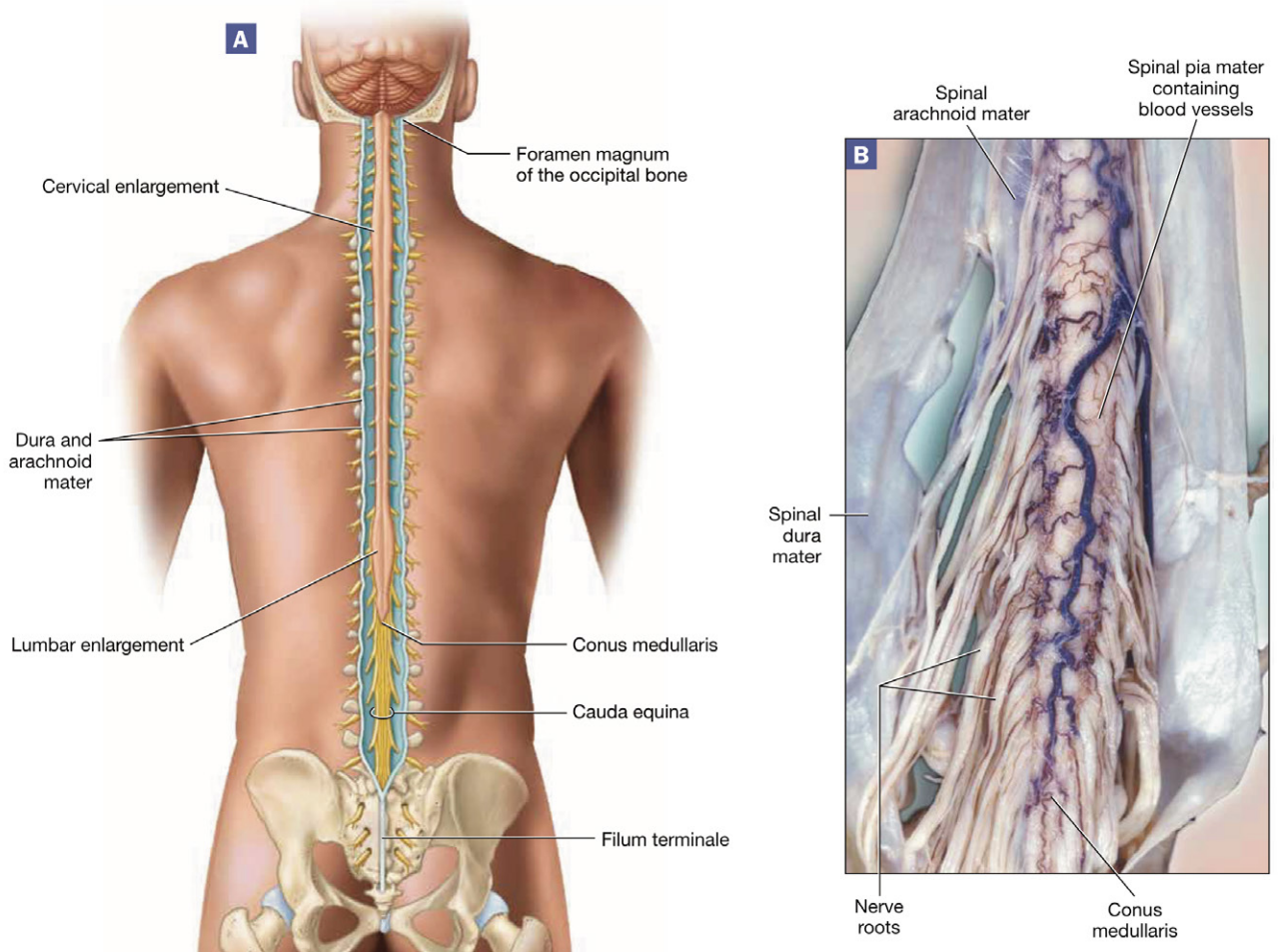

FIGURE **13.16** Spinal cord, posterior view: (**A**) illustration; (**B**) photograph.

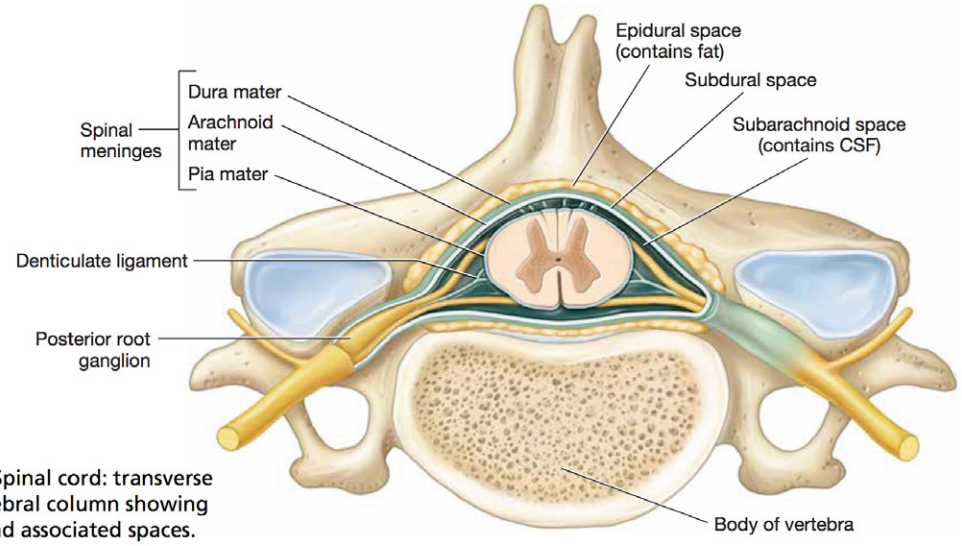

FIGURE **13.17** Spinal cord: transverse section in the vertebral column showing spinal meninges and associated spaces.

which creates a fat-filled space between the spinal dura and the interior vertebral foramen called the **epidural space** (ep-ih-DOO-ruhl). There is no epidural space around the brain because the periosteal layer of the cranial dura is fused to the skull.

Another difference between the cranial and spinal meninges is the presence of small extensions of pia mater in the spinal cord called **denticulate ligaments** (den-TIK-yoo-lit). These tiny ligaments secure the spinal cord to the vertebral column. In addition, the pia mater continues long after the spinal cord ends and forms a long, fibrous extension called the **filum terminale** (FY-lum ter-mee-NAL-ay) that eventually attaches to the coccyx (see Fig. 13.16).

The external surface of the spinal cord features two indentations. Anteriorly, we find the relatively wide **anterior median fissure,** and posteriorly is the much narrower **posterior median sulcus** (Fig. 13.18). Internally, the spinal cord consists of a butterfly-shaped core of gray matter that surrounds the CSF-filled **central canal.** Notice that this arrangement is different from what we saw in the brain, where the gray matter was on the outside and the white matter on the inside. The gray matter is divided into regions, or **horns:**

- The **anterior horns** contain the cell bodies of motor neurons. The axons of the neurons of the anterior horn exit the spinal cord and form the **anterior root,** which eventually becomes part of a spinal nerve.

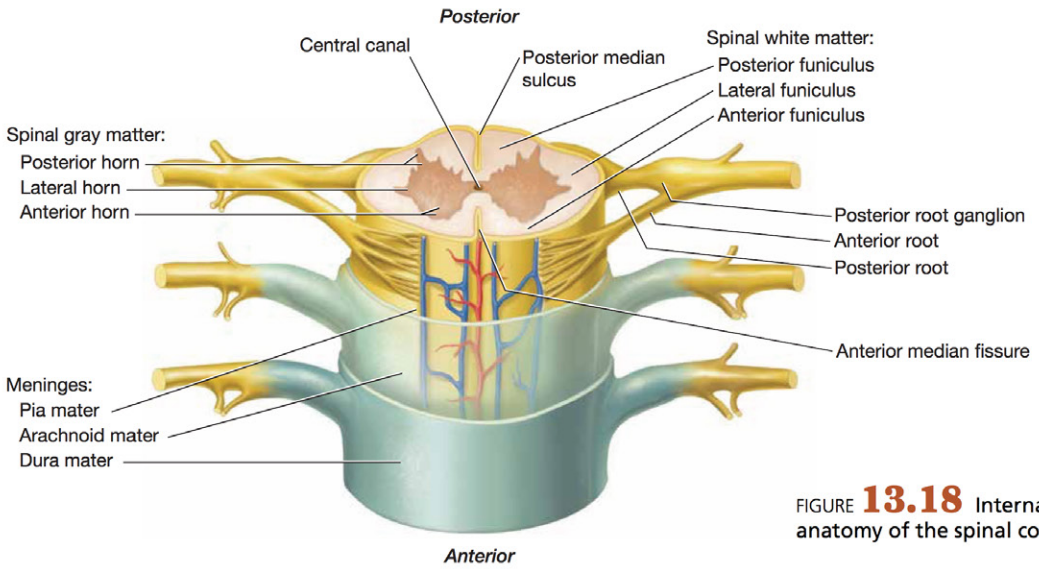

FIGURE **13.18** Internal anatomy of the spinal cord.

- The **posterior horns** contain the cell bodies of sensory neurons. These cell bodies receive input from the axons of pseudounipolar neurons in the PNS that enter the spinal cord via the **posterior root.** The cell bodies of these pseudounipolar neurons are located just lateral to the spinal cord in a swollen knob called the **posterior root ganglion.**
- The **lateral horns** are found in the thoracic and lumbar regions of the spinal cord. They contain the cell bodies of autonomic neurons.

As you can see in Figure 13.18, it is possible to tell the anterior and posterior spinal cord apart by looking at the shapes of the anterior and posterior horns. The anterior horns are broad and flat on the ends, whereas the posterior horns are more tapered, and they extend farther out toward the edge.

Surrounding the spinal gray matter is the spinal white matter, which can be divided into three **funiculi** (fun-IK-yoo-lye; also known as *columns*): the **anterior, posterior,** and **lateral funiculi.** Each funiculus contains myelinated axons grouped into bundles called **tracts.** Tracts contain axons that have the same beginning and end points and the same general function. *Ascending tracts* carry sensory information from sensory neurons to the brain, and *descending tracts* carry motor information from the brain to motor neurons.

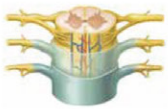

Procedure 1 Model Inventory for the Spinal Cord

Identify the following structures of the spinal cord on models and diagrams, using your textbook and this unit for reference. As you examine the anatomical models and diagrams, record the name of the model and the structures you were able to identify on the model inventory in Table 13.2. When you have completed the activity, answer Check Your Understanding questions 4 through 6 (p. 358).

1. Cervical enlargement
2. Lumbar enlargement
3. Conus medullaris
4. Cauda equina
5. Meninges
   a. Dura mater
      (1) Epidural space
   b. Arachnoid mater
      (1) Subdural space
   c. Pia mater
      (1) Subarachnoid space
      (2) Denticulate ligaments
      (3) Filum terminale
6. Anterior median fissure
7. Posterior median sulcus
8. Central canal
9. Spinal gray matter
   a. Anterior horn
   b. Posterior horn
   c. Lateral horn
10. Spinal nerve roots
    a. Anterior root
    b. Posterior root
       (1) Posterior root ganglion
11. Spinal white matter
    a. Anterior funiculus
    b. Lateral funiculus
    c. Posterior funiculus

TABLE **13.2** Model Inventory for the Spinal Cord

Model/Diagram	Structures Identified

Procedure 2 Time to Draw

In the space below, draw, color, and label one of the transverse sections of the spinal cord models that you examined. In addition, write the function of each structure that you label.

Name _____

Section _____ Date _____

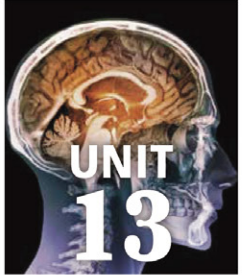

Check Your Recall

REVIEW

1 Label the following parts of the brain in Figures 13.19 and 13.20.

- ❑ Central sulcus
- ❑ Cerebellum
- ❑ Corpus callosum
- ❑ Frontal lobe
- ❑ Hypothalamus
- ❑ Lateral sulcus
- ❑ Medulla oblongata
- ❑ Midbrain
- ❑ Occipital lobe
- ❑ Parietal lobe
- ❑ Pineal gland
- ❑ Pons
- ❑ Postcentral gyrus
- ❑ Precentral gyrus
- ❑ Temporal lobe
- ❑ Thalamus

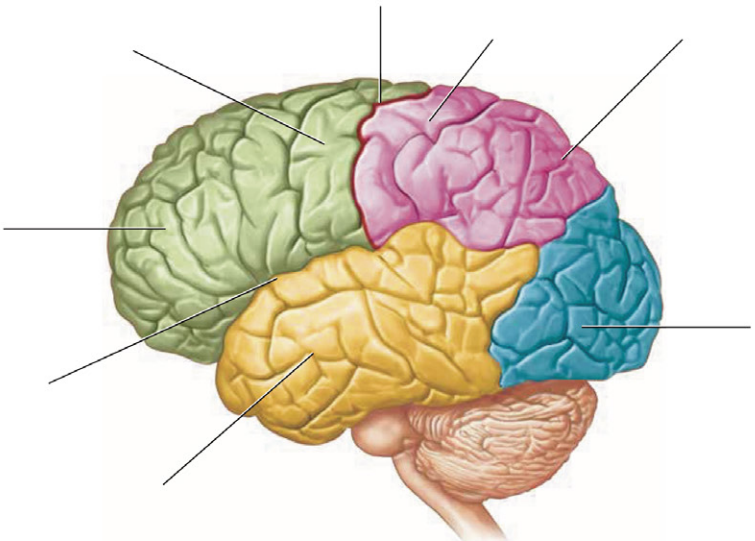

FIGURE **13.19** Brain, lateral view.

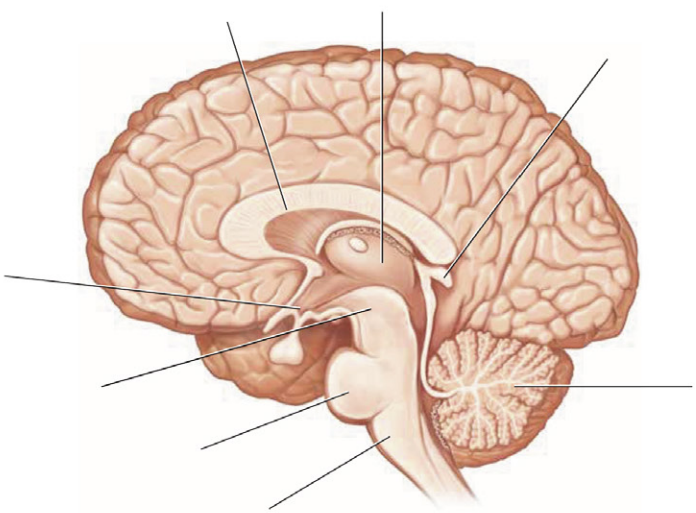

FIGURE **13.20** Brain, midsagittal section.

2 Identify the following structures in Figure 13.21.

- ❑ Central canal
- ❑ Cerebral aqueduct
- ❑ Fourth ventricle
- ❑ Lateral ventricle
- ❑ Third ventricle

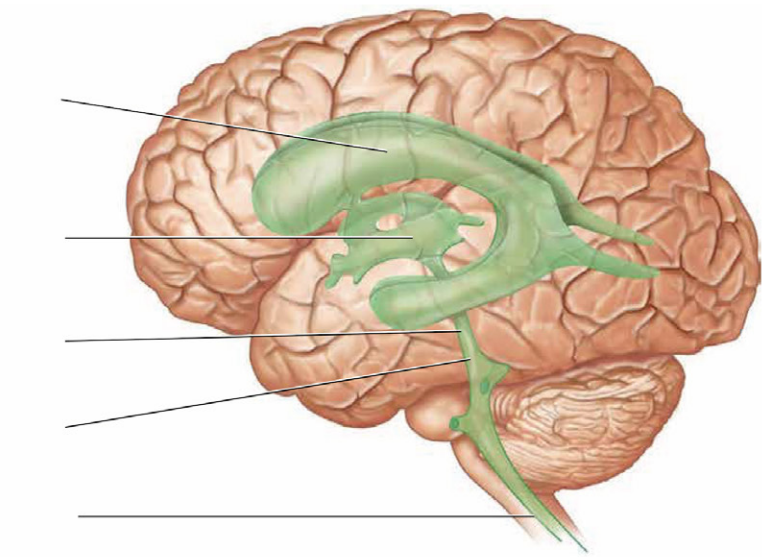

FIGURE **13.21** Brain, left lateral view.

3 What are the four main regions of the brain?

_____

_____

_____

_____

13

4 Gray matter consists of

a. cell bodies, dendrites, and unmyelinated axons.
b. myelinated axons.
c. unmyelinated axons.
d. myelinated cell bodies, dendrites, and axons.

5 *True/False:* Mark the following statements as true (T) or false (F). If the statement is false, correct it to make it a true statement.

_____ The diencephalon consists of the midbrain, pons, and medulla oblongata.

_____ The outer, tough meninx around the brain is the dura mater.

_____ The cerebellum monitors ongoing movement to reduce motor error.

_____ The cerebral cortex is the outer 2 mm of white matter of the cerebrum.

_____ The corpus callosum is a large tract of white matter that connects the right and left cerebral hemispheres.

6 Cerebrospinal fluid is produced by the

a. ventricles of the brain.
b. arachnoid granulations.
c. dural sinuses.
d. choroid plexuses.

Name _____

Section _____ Date _____

7 Label the following parts of the spinal cord in Figure 13.22.

- ❑ Cauda equina
- ❑ Cervical enlargement
- ❑ Conus medullaris
- ❑ Filum terminale
- ❑ Lumbar enlargement

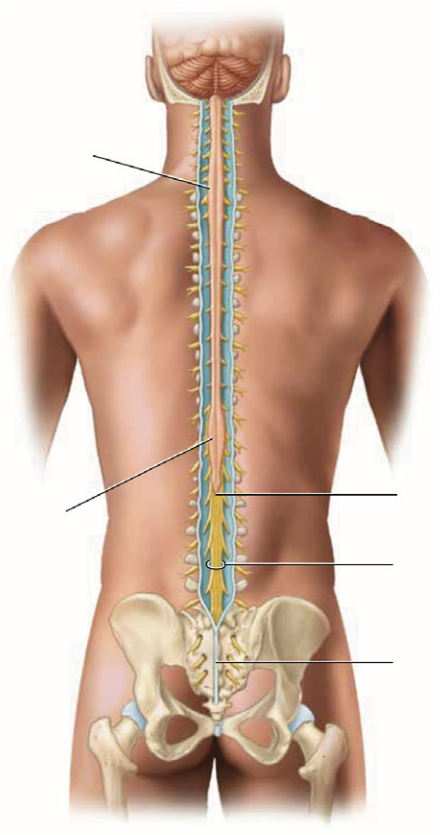

FIGURE **13.22** Spinal cord, posterior view.

8 Label the following parts of the spinal cord in Figure 13.23.

- ❑ Anterior horn
- ❑ Arachnoid mater
- ❑ Central canal
- ❑ Dura mater
- ❑ Epidural space
- ❑ Pia mater
- ❑ Posterior horn
- ❑ Posterior root ganglion
- ❑ Subarachnoid space

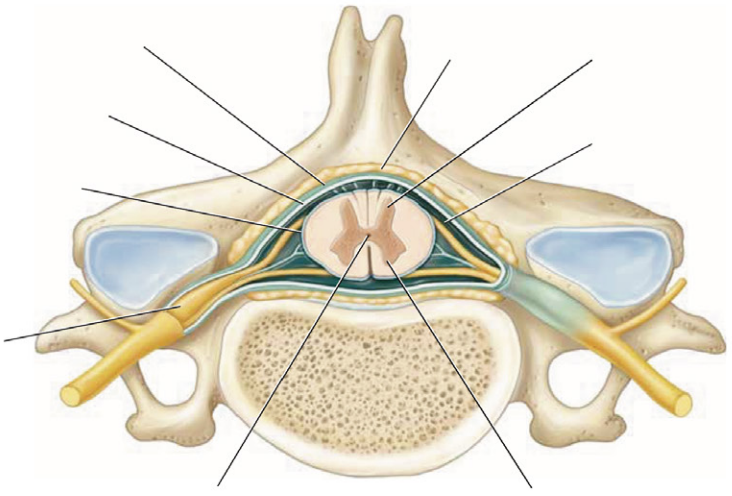

FIGURE **13.23** Spinal cord, transverse section in the vertebral column showing spinal meninges and associated spaces.

9 *Fill in the blanks:* The spinal cord extends from the _____ of the occipital bone to the _____ vertebra. It terminates as the _____ and gives off a bundle of nerve roots called the _____.

10 Which of the following spaces around the spinal cord is filled with cerebrospinal fluid (CSF)?

a. Epidural space.
b. Subdural space.
c. Subarachnoid space.
d. All of the above.

Name _____

Section _____ Date _____

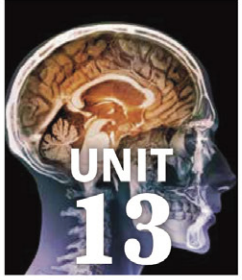

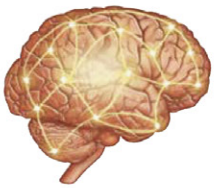

Check Your Understanding

REVIEW

Critical Thinking and Application Questions

1 *Agenesis of the corpus callosum* is a rare birth defect characterized by a lack of development of the corpus callosum. What sort of functional impairment would you expect from such a defect? Explain.

2 Predict the effects of injuries to the following structures:

a Cerebellum

b Pons

c Thalamus

3 Predict what might happen if the choroid plexuses produced excessive CSF, in amounts greater than the dural venous sinuses were able to absorb.

4 A common way to deliver anesthesia for surgery and childbirth is to inject the anesthetic agent into the epidural space (*epidural anesthesia*). Why do you think the anesthetic is injected into the epidural space instead of the subarachnoid space?

5 During a procedure called a *lumbar puncture*, CSF surrounding the meninges is withdrawn with a needle.

a This procedure generally is performed between L3 and L5. Why do you think the fluid is withdrawn here rather than from higher up in the vertebral column? (***Hint:*** Think about the structure and location of the spinal cord.)

b Often, the sampled CSF is tested for bacteria or viruses if a brain infection is suspected. Why would CSF sampled from the spinal cord give you information about the condition of the brain?

c Would you withdraw CSF if the needle were accidentally inserted into the epidural space instead of the subarachnoid space? Why or why not?

6 An individual sustains injuries to only the ascending tracts of the spinal cord. Will this person experience deficits in movement, sensation, both, or neither? Explain.

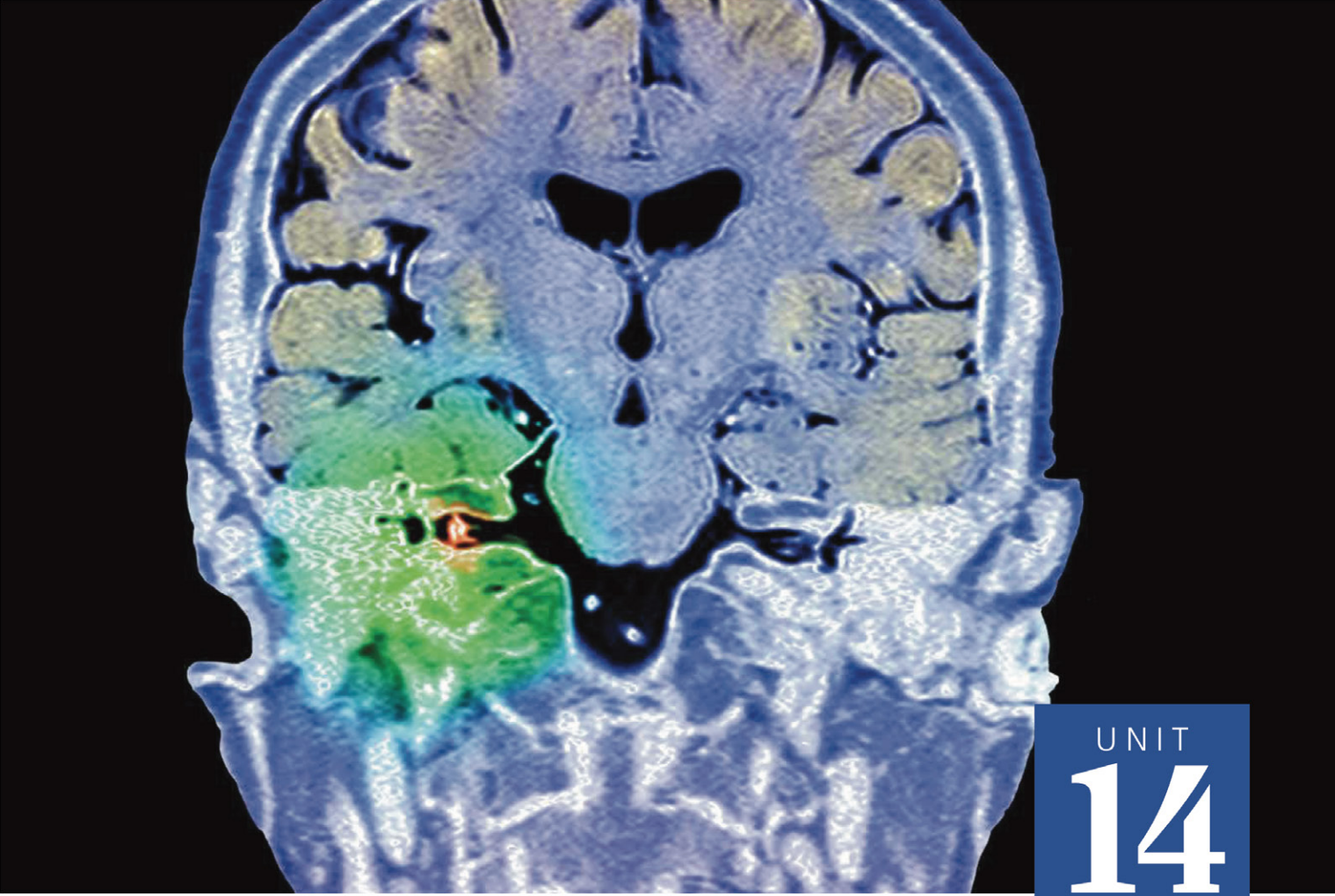

UNIT
14

Peripheral and Autonomic Nervous System

Once you have completed this unit, you should be able to:

1. Identify structures of a peripheral nerve on anatomical models or microscope slides.
2. Identify, describe, and demonstrate functions of cranial nerves.
3. Identify spinal nerves and plexuses on anatomical models.
4. Describe a simple spinal reflex arc, and test the effects of mental concentration on the patellar tendon (knee-jerk) reflex.
5. Describe the effects of the two branches of the autonomic nervous system on the body systems.

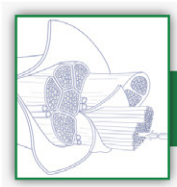

Name _____ Section _____ Date _____

PRE-LAB EXERCISES

Complete the following exercises prior to coming to lab, using this lab manual and your textbook for reference.

Pre-Lab Exercise 14-1



Key Terms

You should be familiar with the following terms before coming to lab. Please note that the individual cranial and spinal nerves are covered in Pre-Lab Exercises 14-3 (p. 363) and 14-5 (p. 365), respectively.

Term	Definition

General Terms

Peripheral nerve _____

Cranial nerve _____

Spinal nerve _____

Nerve plexus _____

Autonomic nervous system _____

Sympathetic nervous system _____

Parasympathetic nervous system _____

Parts of a Peripheral Nerve

Fascicle _____

Axon _____

Epineurium _____

Perineurium _____

Endoneurium _____

_____

Spinal Nerve Plexuses

Cervical plexus _____

_____

Brachial plexus _____

_____

Lumbar plexus _____

_____

Sacral plexus _____

_____

Pre-Lab Exercise 14-2

Peripheral Nerve Anatomy

14

Label and color the peripheral nerve diagram in Figure 14.1 with the terms from Exercise 14-1 (p. 367). Use your text and Exercise 14-1 in this unit for reference.

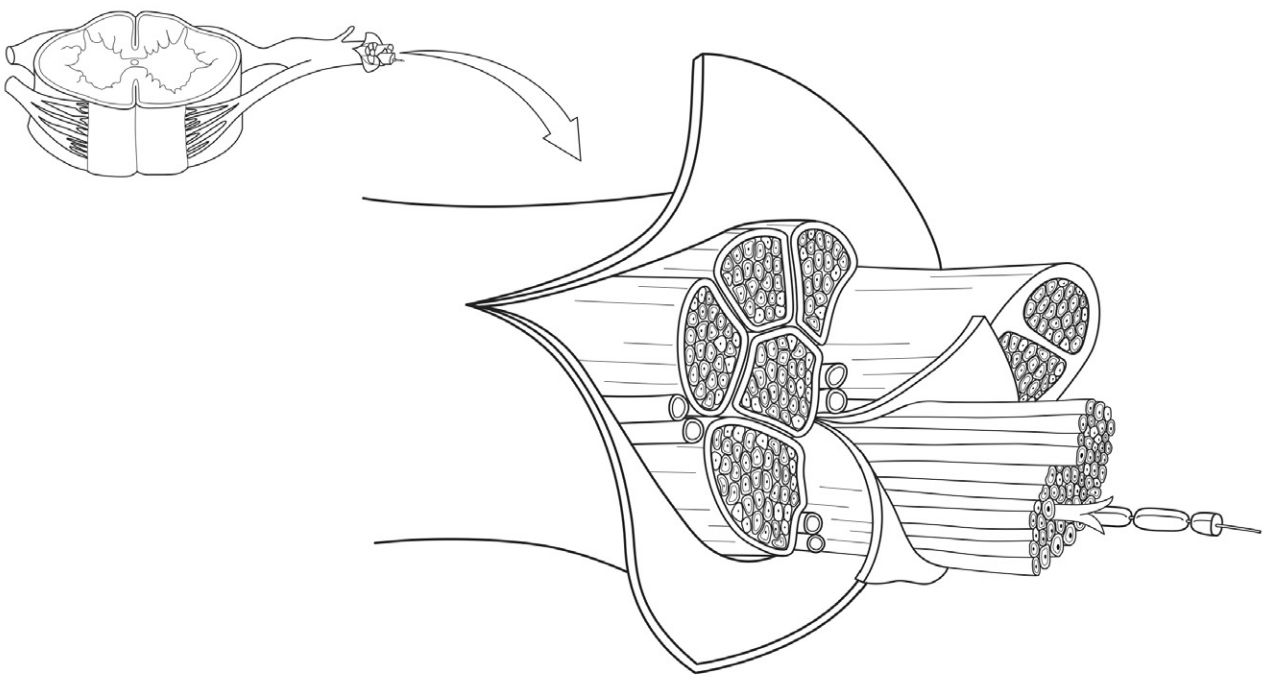

FIGURE **14.1** Anatomy of a peripheral nerve.

Name _____ Section _____ Date _____

Pre-Lab Exercise 14-3



Cranial Nerve Functions

Complete Table 14.1 with the functions of each pair of cranial nerves, and indicate whether the nerve is motor, sensory, or mixed. Use Exercise 14-2 (p. 369) in this unit for reference.

TABLE 14.1 The Cranial Nerves

Cranial Nerve	Functions	Motor, Sensory, or Mixed
CN I: Olfactory nerve		
CN II: Optic nerve		
CN III: Oculomotor nerve		
CN IV: Trochlear nerve		
CN V: Trigeminal nerve		
CN VI: Abducens nerve		
CN VII: Facial nerve		
CN VIII: Vestibulocochlear nerve		
CN IX: Glossopharyngeal nerve		
CN X: Vagus nerve		
CN XI: Accessory nerve		
CN XII: Hypoglossal nerve		

Pre-Lab Exercise 14-4



Spinal Nerve Plexuses and the Anterior Rami of the Spinal Nerves

Label Figure 14.2, which shows the spinal nerve plexuses and the anterior rami of the spinal nerves, with the terms from Exercise 14-3 (p. 375). Use your text and Exercise 14-3 in this unit for reference. Note that this diagram is presented in color to make identification of the nerves easier.

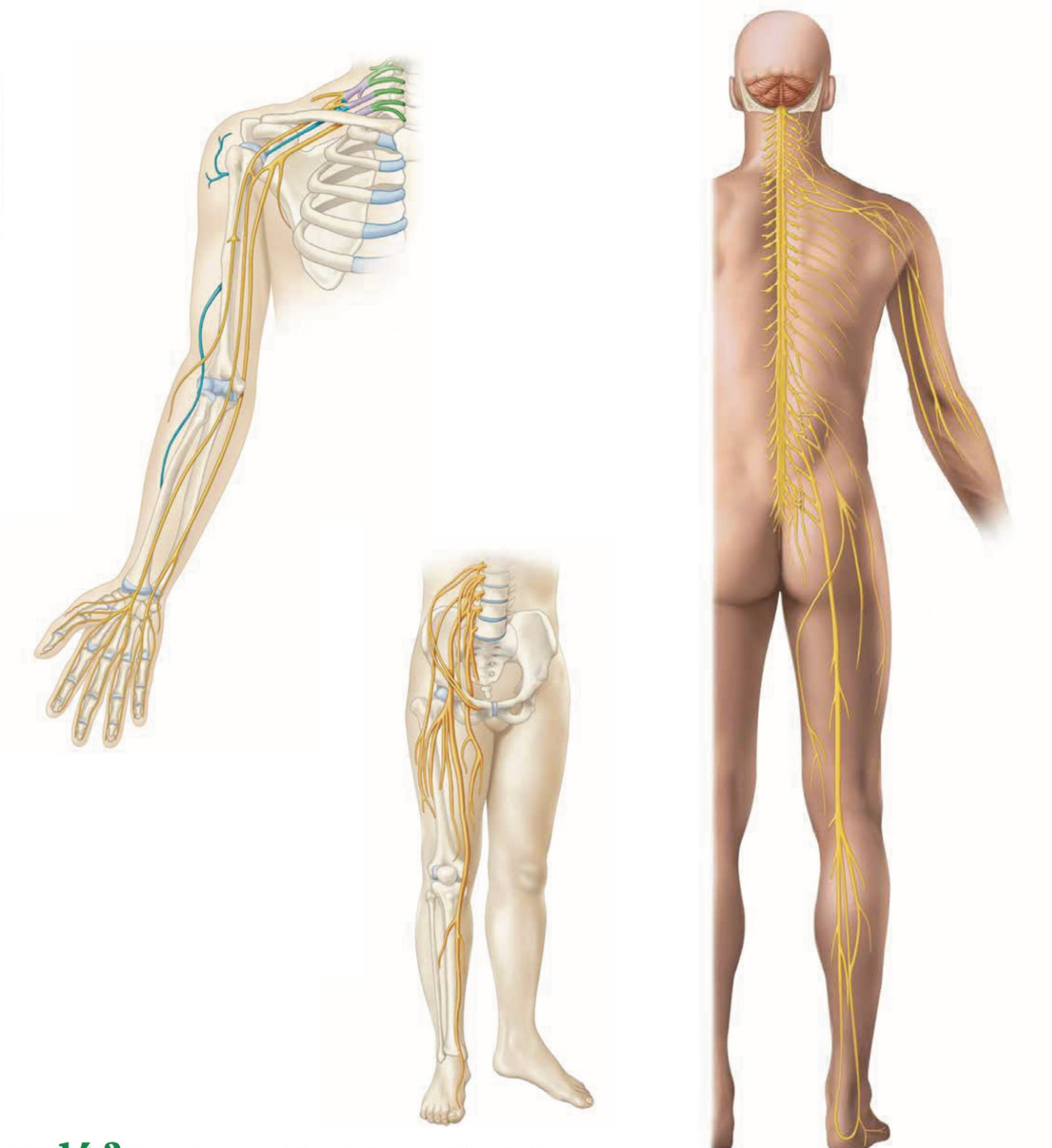

FIGURE **14.2** Nerve plexuses and the anterior rami of the spinal nerves.

Name _____ Section _____ Date _____

Pre-Lab Exercise 14-5



Anterior Rami of the Spinal Nerves: Locations and Functions

The anterior rami of the spinal nerves (with the exception of the intercostal nerves) can be traced to the specific nerve plexus from which they originate. Fill in Table 14.2 with the nerve plexus from which each nerve originates and the functions of each nerve. Use your text and Exercise 14-3 (p. 375) in this unit for reference.

TABLE **14.2** Selected Anterior Rami of the Spinal Nerves

Spinal Nerve	Nerve Plexus	Functions
Phrenic nerve		
Radial nerve		
Ulnar nerve		
Median nerve		
Femoral nerve		
Obturator nerve		
Tibial nerve		
Common fibular nerve		

Pre-Lab Exercise 14-6

Branches of the Autonomic Nervous System

The autonomic nervous system (ANS) has two subdivisions: (a) the sympathetic nervous system (SNS), and (b) the parasympathetic nervous system (PSNS). Fill in Table 14.3 with the general characteristics of each branch of the ANS and the effects of each system on its target organs, using your text and Exercise 14-4 (p. 381) in this unit for reference.

TABLE **14.3** Characteristics of the Sympathetic and Parasympathetic Nervous Systems

Characteristic	SNS	PSNS
Main function		
Location of nerve roots		
Neurotransmitter(s)		
Effects on Target Organs and Physiological Processes		
Heart		
Bronchioles (airway passages of the lungs)		
Blood vessels to abdominal organs and skin		
Blood vessels to skeletal muscle		
Secretion from digestive glands		
Urine formation/ Micturition (urination)		
Pupils of the eye		

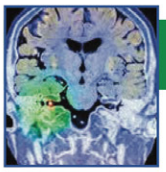

MRI showing an acoustic neuroma, a tumor of the vestibulocochlear nerve (CM VIII).

EXERCISES

In Unit 13 we discussed the central nervous system (CNS), and now we turn to the other division of the nervous system—the **peripheral nervous system** (**PNS**). The organs of the PNS are called **peripheral nerves**, or simply *nerves*. There are two types of nerves classified by location: (1) nerves that bring information to and from the brain and the brainstem, called **cranial nerves**, and (2) nerves that bring information to and from the spinal cord, called **spinal nerves**.

The PNS may be divided broadly into two divisions based upon function: the **motor** or **efferent division**, which innervates muscle cells and glands, and the **sensory** or **afferent division**, which innervates the skin, joints, special sensory organs, and other sensory receptors. The motor and sensory divisions may be further subdivided based upon the structures that are served: (a) the **somatic sensory** and **somatic motor divisions**, which serve skin and skeletal muscles, respectively, and (b) the **visceral sensory** and **visceral motor divisions,** which serve smooth muscle, cardiac muscle, and glands. The visceral motor division controls most of our automatic functions such as heart rate, blood pressure, digestion, and urine production, and is also known as the **autonomic nervous system** (**ANS**).

In the following exercises, we examine the structure and functions of the organs and divisions of the PNS. As you study the PNS, bear in mind that its functions are closely interwoven with the CNS, and the branches of the nervous system cannot function independently of one another.

Exercise 14-1

Peripheral Nerve Anatomy

MATERIALS

- ❑ Peripheral nerve models or charts
- ❑ Peripheral nerve slide
- ❑ Light microscope with three objectives
- ❑ Colored pencils

The organs of the peripheral nervous system are known as **peripheral nerves**, or simply **nerves**. Each nerve consists of myelinated and unmyelinated axons (also known as *nerve fibers*), blood vessels, lymphatic vessels, and connective tissue sheaths (Figs. 14.3A and B). Each individual axon is covered by its axolemma (plasma membrane), superficial to which we find a connective tissue sheath called the **endoneurium** (en-doh-NOOR-ee-um). Axons are grouped into bundles called **fascicles** (FASS-ih-kullz), which are in turn covered with another connective tissue sheath called the **perineurium** (pehr-ih-NOOR-ee-um). Groups of fascicles, blood vessels, and lymphatic vessels are surrounded by the most superficial connective tissue sheath: the **epineurium** (ep-ih-NOOR-ee-um).

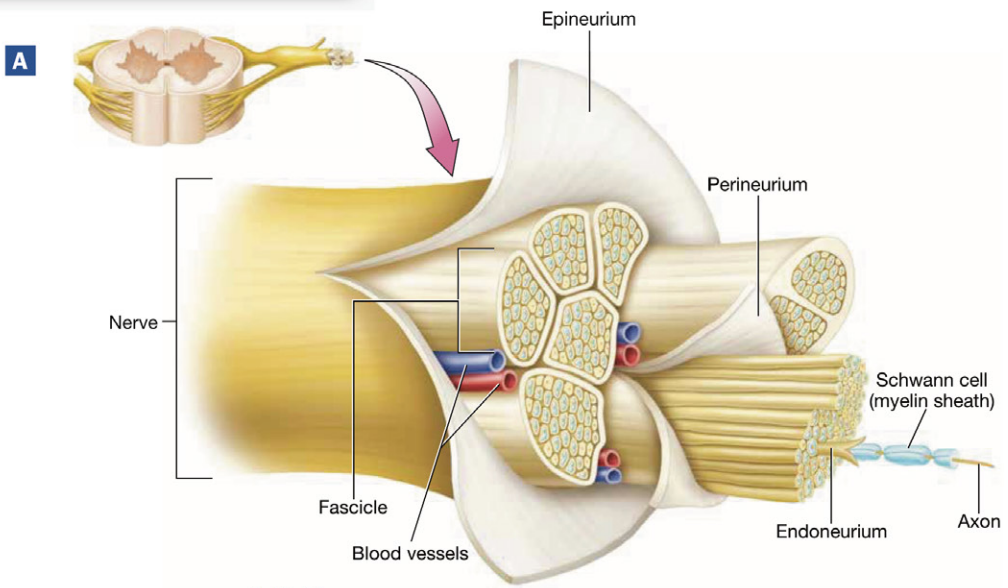

FIGURE **14.3** Anatomy of a peripheral nerve: (**A**) illustration *(continues)*

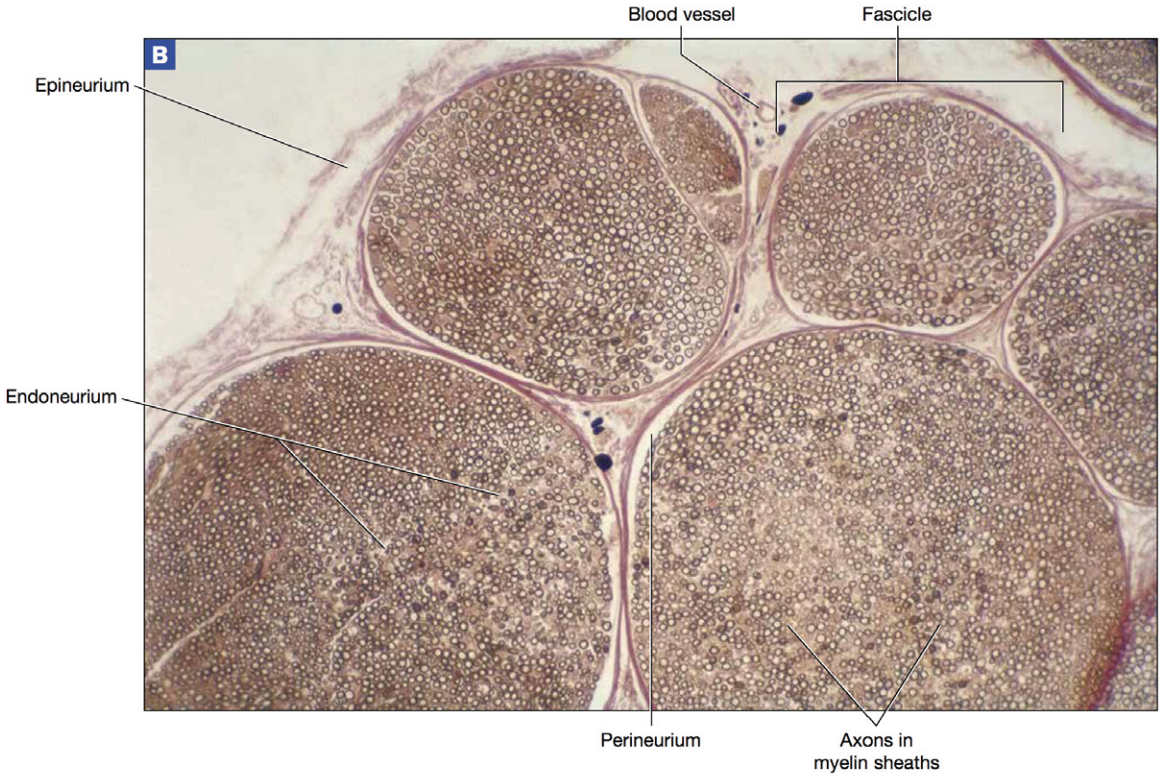

14

FIGURE **14.3** Anatomy of a peripheral nerve *(cont.)*: (**B**) light micrograph.

Procedure 1 Microscopy

Examine a prepared slide of a sectioned peripheral nerve. Start on low power, and then advance to higher powers to see more details. Draw what you see, and label your drawing with the following terms, using Figure 14.3B for reference. When you have finished the procedure, answer Check Your Understanding question 1 (p. 387).

1. Fascicle
2. Axon
3. Blood vessels
4. Nerve sheaths
   a. Epineurium
   b. Perineurium
   c. Endoneurium
   d. Myelin sheath



Exercise 14-2

The Cranial Nerves

MATERIALS

- ❑ Brain models
- ❑ Preserved brain specimens
- ❑ Penlight
- ❑ Snellen vision chart
- ❑ Tuning fork
- ❑ Unknown samples to smell
- ❑ PTC, thiourea, and sodium benzoate tasting papers

The 12 pairs of **cranial nerves** originate from or bring information to the brain (Fig. 14.4). Each nerve is given two names: (1) a sequential Roman numeral in order of its attachment to the brain, and (2) a name that describes the nerve's location or function. For example, cranial nerve III is the third cranial nerve that attaches to the brain. It is also called the oculomotor nerve because one of its functions is to provide motor axons to some of the muscles that move the eyeball.

Most cranial nerves innervate structures of the head and neck. Three cranial nerves are **sensory nerves** whose axons have purely sensory functions, four are **mixed nerves** that contain both sensory and motor axons, and five are **motor nerves** that contain primarily motor axons. Following is an overview of the main functions of each cranial nerve (note that CN = "cranial nerve"):

1. **CN I: Olfactory Nerve.** The **olfactory nerve** is a purely sensory nerve that innervates the olfactory mucosa in the superior nasal cavity, where it provides for the sense of smell.
2. **CN II: Optic Nerve.** The **optic nerve** is also a purely sensory nerve that provides for the sense of vision. Its axons emerge from the retina of the eye and meet at the **optic chiasma** (ky-AZ-mah), where the nerves partially exchange axons before diverging to form the **optic tracts.**
3. **CN III: Oculomotor Nerve.** The **oculomotor nerve** (awk-yoo-loh-MOH-tohr) is a motor cranial nerve. It innervates four of the six extrinsic eye muscles that move the eyeball, the muscle that opens the eyelid, the muscle that constricts the pupil, and the muscle that changes the shape of the lens for near vision, an adjustment called **accommodation.**
4. **CN IV: Trochlear Nerve.** The **trochlear nerve** (TROH-klee-ur) is a small motor nerve that innervates one of the six extrinsic eye muscles that moves the eyeball (the *superior oblique muscle*).
5. **CN V: Trigeminal Nerve.** The **trigeminal nerve** is a large mixed nerve named for the three branches that provide sensory innervation from the face and motor innervation to the muscles of mastication (chewing).

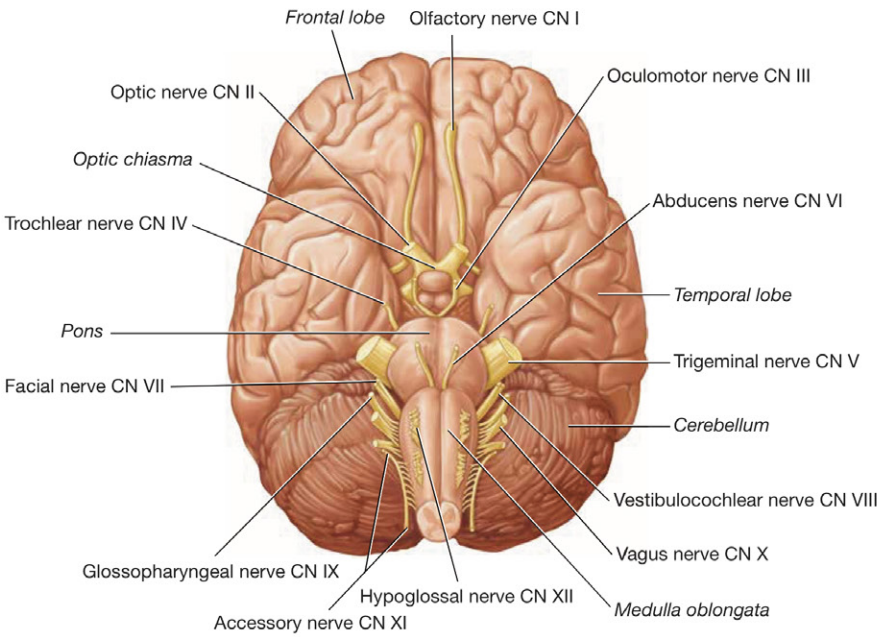

FIGURE **14.4** Inferior view of the brain with the cranial nerves.

6. **CN VI: Abducens Nerve.** The **abducens nerve** (ab-DOO-senz) is a small motor nerve that innervates the final extrinsic eye muscle (the *lateral rectus muscle*).
7. **CN VII: Facial Nerve.** The mixed fibers of the **facial nerve** innervate many structures and provide for the following: motor to the muscles of facial expression; taste from the anterior two-thirds of the tongue; motor to the glands that produce tears (the lacrimal glands), mucus, and saliva; and sensory from part of the face and mouth.
8. **CN VIII: Vestibulocochlear Nerve.** The final sensory nerve, the **vestibulocochlear nerve** (ves-tib-yoo-loh-KOHK-lee-ur), innervates the structures of the inner ear and provides for the senses of hearing and equilibrium.
9. **CN IX: Glossopharyngeal Nerve.** The small mixed **glossopharyngeal nerve** (glah-soh-fehr-IN-jee-uhl) provides motor axons to the muscles of the pharynx (throat) involved in swallowing and sensory fibers from the posterior one-third of the tongue for taste sensation.
10. **CN X: Vagus Nerve.** The mixed **vagus nerve** (VAY-gus) is the only cranial nerve that "wanders" outside of the head and neck ("vagus" means "wanderer"). In the head and the neck it provides some sensory innervation from the skin of the head and the pharynx, motor axons to muscles involved in speech and swallowing, and motor axons to certain salivary glands. Outside the head and the neck it innervates most of the thoracic and abdominal viscera as the main nerve of the parasympathetic nervous system.
11. **CN XI: Accessory Nerve.** The **accessory nerve** is the only cranial nerve that has both a cranial component originating from the brainstem and a spinal component originating from the spinal cord. Its motor axons innervate the muscles that move the head and the neck, such as the trapezius and sternocleidomastoid muscles.
12. **CN XII: Hypoglossal Nerve.** The **hypoglossal nerve** is a small motor nerve that innervates the muscles that move the tongue. Note that the hypoglossal nerve *moves* the tongue but does not provide any taste sensation to the tongue.

14

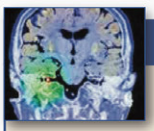

HINTS & TIPS

Remembering the Order of the Cranial Nerves

Many cranial nerve mnemonics have been created over the years to help students remember their correct order. Following is one of my favorite mnemonics, but if this one doesn't stick for you, try making up your own or doing an Internet search for "cranial nerve mnemonics":

Oh (Olfactory)
Once (Optic)
One (Oculomotor)
Takes (Trochlear)
The (Trigeminal)
Anatomy (Abducens)
Final (Facial)
Very (Vestibulocochlear)
Good (Glossopharyngeal)
Vacations (Vagus)
Are (Accessory)
Happening (Hypoglossal)

You also can help yourself remember the olfactory and optic nerves by reminding yourself that you have one nose (CN I, the *olfactory* nerve) and two eyes (CN II, the *optic* nerve).

Procedure 1 Model Inventory for Cranial Nerves I–XII

Identify cranial nerves I–XII and associated structures on anatomical models or preserved specimens of the brain. List the structures you are able to identify in the model inventory in Table 14.4.

1. Olfactory nerves
   a. Olfactory bulbs
2. Optic nerves
   a. Optic chiasma
   b. Optic tract
3. Oculomotor nerves
4. Trochlear nerves
5. Trigeminal nerves
6. Abducens nerves
7. Facial nerves
8. Vestibulocochlear nerves
9. Glossopharyngeal nerves
10. Vagus nerves
11. Accessory nerves
12. Hypoglossal nerves

TABLE 14.4 Model Inventory for the Cranial Nerves

Model/Diagram	Structures Identified

Procedure 2 Testing the Cranial Nerves

A component of every complete physical examination performed by healthcare professionals is the cranial nerve exam. In this exercise you will put on your "doctor hat" and perform the same tests of the cranial nerves done during a physical examination. Pair up with another student, and take turns performing the following tests. For each test, first document your observations (in many cases, this will be "able to perform" or "unable to perform"). Then state which cranial nerve(s) you have checked with each test. Keep in mind that some tests check more than one cranial nerve, some cranial nerves are tested more than once, and each nerve is tested in this exercise at least once. When you have completed the activity, answer Check Your Understanding questions 2 through 4 (p. 387).

1 Have your partner perform the following actions individually (not all at once—your partner may have difficulty smiling and frowning at the same time): smile, frown, raise his or her eyebrows, and puff his or her cheeks.

Observations: _____

CN(s) tested: _____

2 Have your partner open and close the jaw and clench the teeth.

Observations: _____

CN(s) tested: _____

3 Have your partner elevate and depress his or her shoulders and turn his or her head to the right and the left.

Observations: _____

CN(s) tested: _____

4 Draw a large, imaginary "Z" in the air with your finger. Have your partner follow your finger with his or her eyes without moving the head. Repeat the procedure, this time drawing the letter "H" in the air with your finger.

Observations: _____

CN(s) tested: _____

5 Test pupillary response:

- **a** Dim the lights in the room about halfway.
- **b** Place your hand vertically against the bridge of your partner's nose as illustrated in Figure 14.5. This forms a light shield to separate the right and left visual fields.
- **c** Shine the penlight indirectly into the left eye from an angle as illustrated in Figure 14.5. Watch what happens to the pupil in the left eye.
- **d** Move the penlight away, and watch what happens to the left pupil.
- **e** Shine the light into the left eye again, and watch what happens to the pupil in the right eye. Move the penlight away, and watch what happens to the right pupil.
- **f** Repeat this process with the right eye.
- **g** Record your results in Table 14.5.

CN(s) tested: _____

_____

FIGURE **14.5** Method for testing the pupillary response.

TABLE **14.5** Pupillary Response Results

Action	Response of Left Pupil	Response of Right Pupil
Light shined into left eye		
Light removed from left eye		
Light shined into right eye		
Light removed from right eye		

6 Have your partner focus on an object on the far side of the room (e.g., the chalkboard or a chart) for 1 minute. Then have your partner switch focus to an object in your hand (e.g., a pencil). Watch your partner's pupils carefully as the point of focus is changed from far to near.

Observations: _____

_____

CN(s) tested: _____

7 Have your partner swallow and speak with your hand placed on the throat. Feel for symmetrical movement of the larynx (throat).

Observations: _____

CN(s) tested: _____

8 Have your partner protrude his or her tongue. Check for abnormal deviation or movement (e.g., does the tongue move straight forward or does it move to one side?).

Observations: _____

CN(s) tested: _____

9 In order to test vision, have your partner stand 20 feet from a Snellen chart and read the chart, starting with the largest line and stopping with the smallest line that your partner can read clearly. Record the ratio (e.g., 20/30) next to that smallest line.

Observations: _____

CN(s) tested: _____

10 Hold a tuning fork by its handle, and strike the tines with a rubber mallet (or just tap it lightly on the lab table). Touch the stem to the top of your partner's head along the midsagittal line in the manner shown in Figure 14.6. This is called the Weber test. Ask your partner if the vibration is heard better in one ear, or if the sound is heard equally well in both ears.

Observations: _____

_____

CN(s) tested: _____

_____

FIGURE **14.6** Weber test for hearing.

11 Have your partner stand with eyes closed and arms at the sides for several seconds. Evaluate his or her ability to remain balanced.

Observations: _____

_____

CN(s) tested: _____

_____

12 Hold an unknown sample near your partner's nose, and fan the odor toward him or her by waving your hand over the container. Have your partner identify the substance by its scent.

Observations: _____

CN(s) tested: _____

13 Evaluate your partner's ability to taste by having your partner place a piece of PTC paper on his or her tongue (the ability to taste PTC is genetically determined; about half of the population can taste it). If your partner cannot taste the PTC, try the thiourea paper instead (a word of warning—thiourea tastes bad). If your partner cannot taste either of these papers, try the sodium benzoate paper.

Observations: _____

CN(s) tested: _____

14

Exercise 14-3

Spinal Nerves and Reflexes

MATERIALS

- ❑ Model of the spinal nerves
- ❑ Reflex hammer

Each of the 31 pairs of **spinal nerves** forms from the fusion of the anterior and posterior roots of the spinal cord. Recall that the anterior roots carry motor axons emerging from the spinal cord, and the posterior roots carry sensory axons to the spinal cord. Each spinal nerve carries both motor and sensory axons, so all spinal nerves are mixed nerves.

Shortly after the anterior and posterior roots fuse to form the spinal nerve, it splits into three branches: a posterior ramus, an anterior ramus, and a small meningeal branch. The posterior rami serve the skin, joints, and musculature of the posterior trunk. The meningeal branches reenter the vertebral canal to innervate spinal structures. The larger **anterior rami** travel anteriorly to supply the muscles of the upper and lower limbs, the anterior thorax and abdomen, and part of the back. The general distribution of the anterior rami is illustrated in Figures 14.7 and 14.8.

The anterior rami of the thoracic spinal nerves travel between the ribs as 11 separate pairs of **intercostal nerves** that innervate the intercostal muscles, the abdominal muscles, and the skin of the chest and abdomen. The anterior rami of the cervical, lumbar, and sacral nerves combine to form four large **plexuses**, or networks, of nerves: the *cervical*, *brachial*, *lumbar*, and *sacral plexuses*. The major nerves of these plexuses are as follows:

1. **Cervical plexuses.** The **cervical plexuses** consist of the anterior rami of C1–C4 with small contributions from C5. The branches of each cervical plexus serve the skin of the head and the neck and certain neck muscles. The major branch is the **phrenic nerve** (FREN-ik; C3–C5), which serves the diaphragm.
2. **Brachial plexuses.** The complicated-looking **brachial plexuses** consist of the

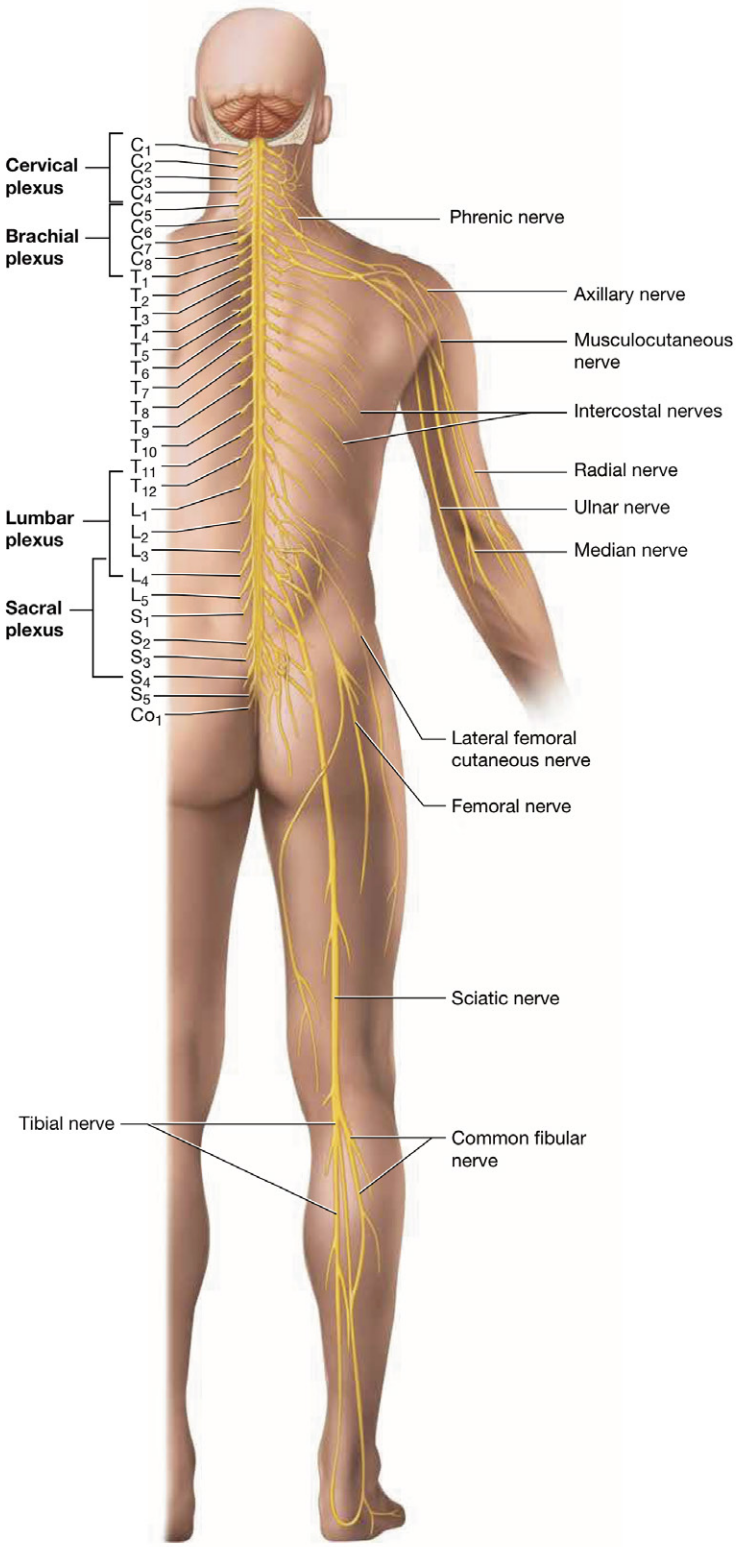

FIGURE **14.7** Nerve plexuses and the anterior rami of the spinal nerves.

anterior rami of C5–T1 (Fig. 14.9). The first structures formed in each brachial plexus are its large **trunks**. Typically, C5 and C6 unite to form the *superior trunk*, C7 forms the *middle trunk*, and C8 and T1 unite to form the *inferior trunk*. Each trunk splits into an anterior division and a posterior division that become the plexus' **cords**. The anterior division of the inferior trunk forms the *medial cord*, which descends in the medial arm. The anterior divisions of the superior and middle trunks unite to form the *lateral cord*, which descends in the lateral arm. The posterior divisions of each trunk unite to form the *posterior cord*, which is located in the posterior arm. Several nerves originate from the brachial plexuses' cords and trunks, including the following:

a. **Axillary nerve.** The **axillary nerve** is a branch of the posterior cord and serves structures near the axilla, including the deltoid and teres minor muscles and the skin around this region.

b. **Musculocutaneous nerve.** The **musculocutaneous nerve** (musk-yoo-loh-kyoo-TAY-nee-us) is the distal continuation of the lateral cord. It is located in the lateral arm and serves the anterior arm muscles that flex the forearm (such as the biceps brachii muscle) and the skin of the lateral forearm.

c. **Radial nerve.** The **radial nerve** is the distal continuation of the posterior cord and is located in the posterior upper limb. It serves the muscles that extend the forearm and hand as well as the skin in the lateral hand.

d. **Ulnar nerve.** The **ulnar nerve**, which you likely know as the "funny bone nerve," is the distal continuation of the medial cord. It begins posteriorly but then crosses over to the anterior side of the forearm as it curves around the medial epicondyle of the humerus. At this point the nerve is superficial and is easily injured when you smack your elbow on something. The ulnar nerve supplies certain muscles in the forearm that flex the hand, most of the intrinsic muscles of the hand, and the skin over the medial hand.

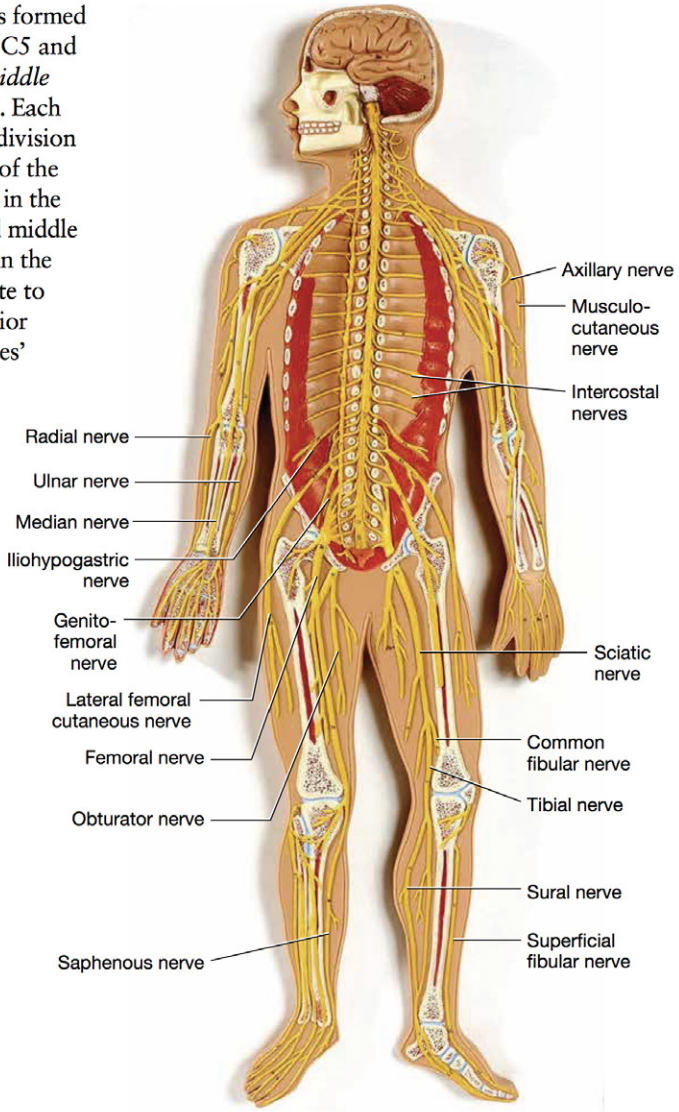

FIGURE **14.8** Anatomical model of the anterior rami of the spinal nerves.

e. **Median nerve.** The **median nerve** results from the fusion of portions of the medial and lateral cords. It is named as such because it travels approximately down the middle of the arm and forearm. It supplies most of the muscles of the forearm that flex the hand, certain intrinsic hand muscles, and the skin over the anterior and lateral hand. As the median nerve enters the wrist, it travels under a band of connective tissue called the *flexor retinaculum*. Occasionally the median nerve becomes trapped and inflamed under the flexor retinaculum, which results in *carpal tunnel syndrome*.

3. **Lumbar plexuses.** Each **lumbar plexus** consists of the anterior rami of L1–L4 with a small contribution from T12 (Fig. 14.10). The branches of the lumbar plexus include the following:

a. **Iliohypogastric and ilioinguinal nerves.** The small **iliohypogastric** (ill-ee-oh-hy-poh-GAS-trik) and **ilioinguinal nerves** (ill-ee-oh-IN-gwin-uhl) both supply motor innervation to the transversus abdominis and internal oblique muscles and sensory to the pelvic area.

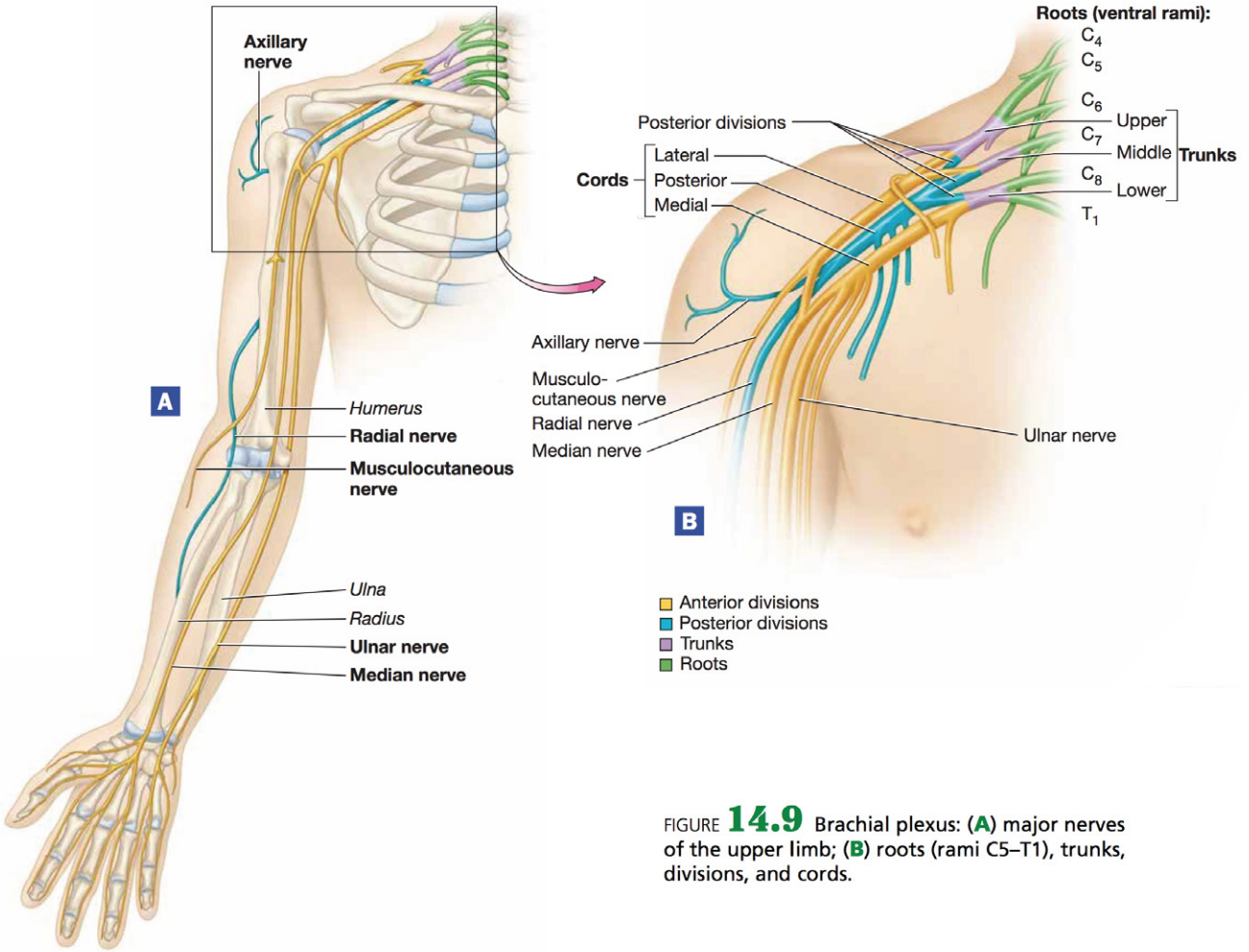

FIGURE **14.9** Brachial plexus: (**A**) major nerves of the upper limb; (**B**) roots (rami C5–T1), trunks, divisions, and cords.

b. **Genitofemoral nerve.** The **genitofemoral nerve** curves around medially to supply the cremaster muscle in males and the skin around the anteromedial thigh and genitals in both sexes.

c. **Femoral nerve.** The largest nerve of this plexus is the **femoral nerve,** which provides motor innervation to most of the anterior thigh muscles that extend the knee and sensory innervation to the skin of the anterior and medial thigh. It gives off a large sensory branch called the **saphenous nerve** (SAF-en-us), which supplies the knee joint, medial leg, and foot.

d. **Lateral femoral cutaneous nerve.** As implied by its name, the **lateral femoral cutaneous nerve** provides mainly sensory innervation to the skin of the anterolateral thigh.

e. **Obturator nerve.** The **obturator nerve** (AHB-too-ray-tur) is located in the medial thigh, where it supplies the medial thigh muscles and the skin of the proximal, medial thigh.

4. **Sacral plexuses.** Each **sacral plexus** forms from anterior rami of L4–S4 (Fig. 14.11). It forms the following nerves:

a. **Superior gluteal nerve.** The first branch of the sacral plexus is the **superior gluteal nerve,** which supplies the gluteus medius, gluteus minimus, and tensor fascia lata muscles.

b. **Inferior gluteal nerve.** The next branch, the **inferior gluteal nerve,** supplies the gluteus maximus muscle.

c. **Pudendal nerve.** A smaller branch of the sacral plexus is the **pudendal nerve** (poo-DEN-duhl), which innervates the muscles of the pelvic floor and anogenital sphincters and provides sensory innervation to the genitalia.

d. **Posterior femoral cutaneous nerve.** The function and location of the **posterior femoral cutaneous nerve** is evident from its name—it is located in the posterior thigh where it provides sensory innervation to the skin.

e. **Sciatic nerve.** The largest nerve of the sacral plexus, and indeed the largest nerve in the body, is the **sciatic nerve** (sy-AEH-tik). The sciatic nerve travels in the posterior thigh, where it splits into two branches: the **tibial nerve** and the **common fibular nerve.** The **tibial nerve** provides motor innervation to the posterior muscles of the thigh, posterior leg, and foot. It gives off a small superficial sensory branch, the **sural nerve,** which

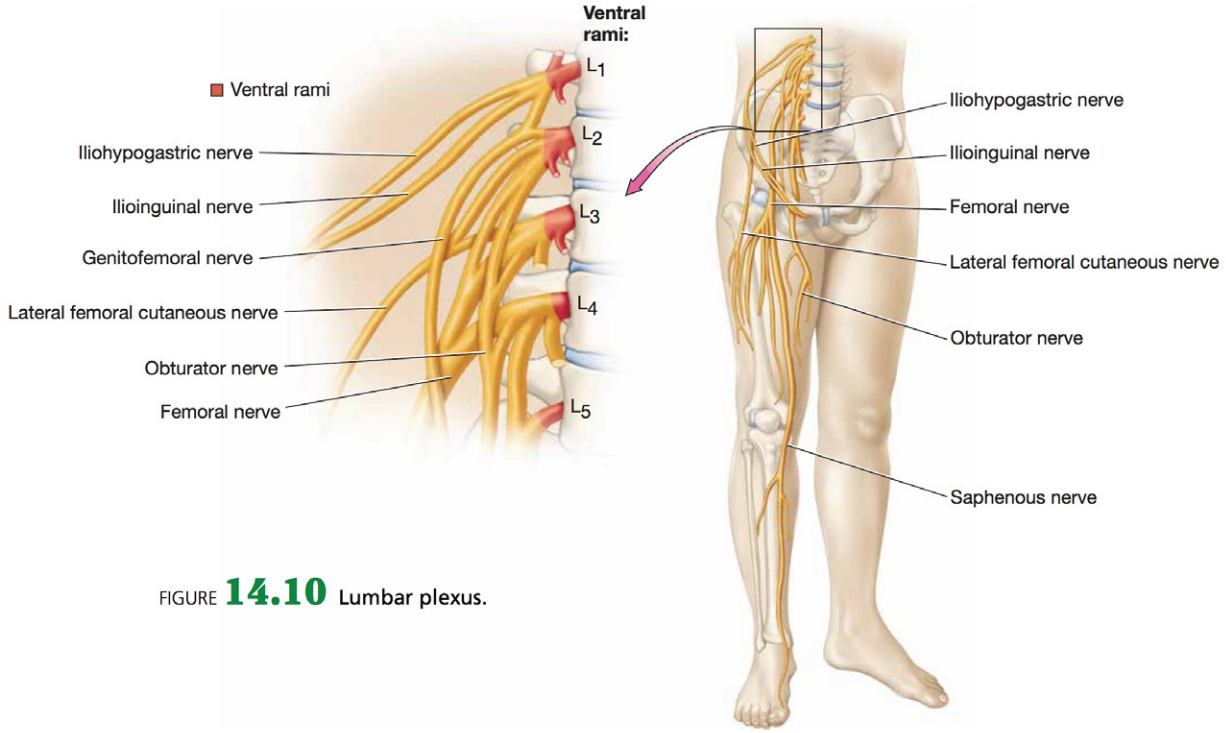

FIGURE **14.10** Lumbar plexus.

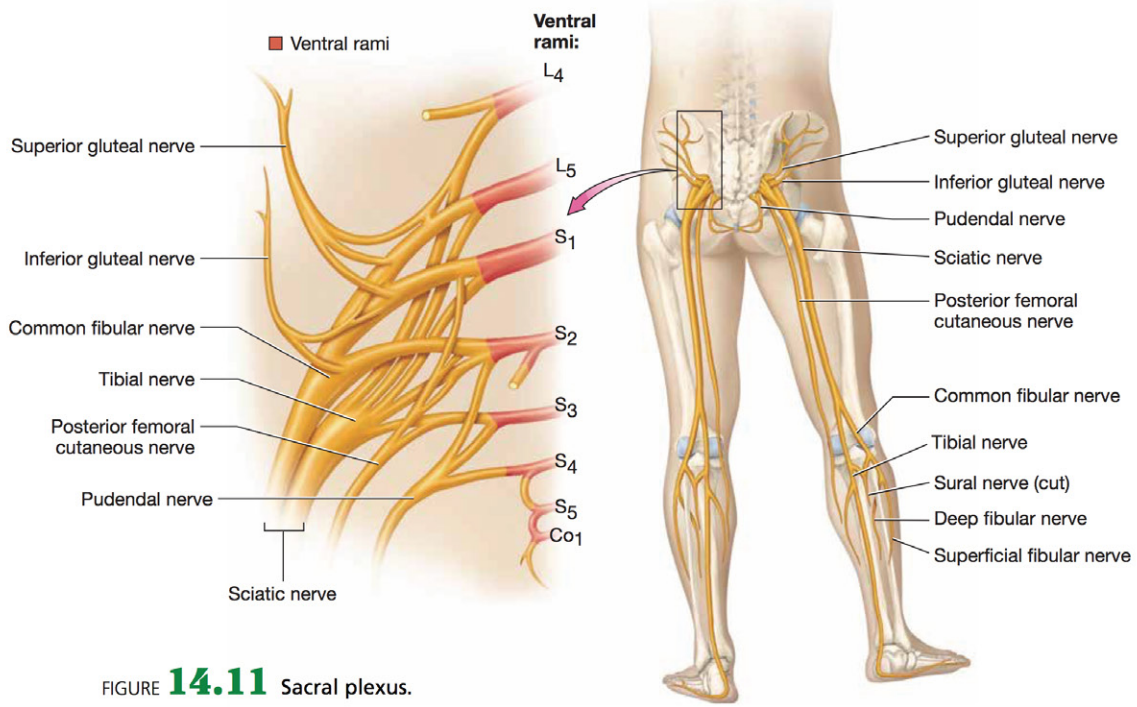

FIGURE **14.11** Sacral plexus.

supplies the skin of the posterior leg and foot. The **common fibular nerve** divides into superficial and deep branches. The superficial branch provides motor innervation to the lateral leg. The deep branch supplies the anterior muscles of the leg that dorsiflex the foot and the intrinsic muscles of the foot. The common fibular nerve also contributes a branch to the sural nerve.

Procedure 1 Model Inventory for Nerves and Nerve Plexuses

Identify the following nerves and nerve plexuses on models and diagrams, using your textbook and this unit for reference. As you examine the anatomical models and diagrams, record the name of the model and the structures you were able to identify on the model inventory in Table 14.6. When you have completed the activity, answer Check Your Understanding questions 5 and 6 (p. 388).

1. Intercostal nerves
2. Cervical plexus
   a. Phrenic nerve
3. Brachial plexus
   a. Axillary nerve
   b. Musculocutaneous nerve
   c. Radial nerve
   d. Ulnar nerve
   e. Median nerve
4. Lumbar plexus
   a. Iliohypogastric nerve
   b. Ilioinguinal nerve
   c. Genitofemoral nerve
   d. Femoral nerve
      (1) Saphenous nerve
   e. Lateral femoral cutaneous nerve
   f. Obturator nerve
5. Sacral plexus
   a. Superior gluteal nerve
   b. Inferior gluteal nerve
   c. Pudendal nerve
   d. Posterior femoral cutaneous nerve
   e. Sciatic nerve
      (1) Tibial nerve
         (a) Sural nerve
      (2) Common fibular nerve

TABLE **14.6** Model Inventory for the Anterior Rami of the Spinal Nerves

Model/Diagram	Structures Identified

Procedure 2 Testing Spinal Reflexes

A **reflex** is an involuntary, predictable motor response to a stimulus. The pathway through which information travels, shown below and in Figure 14.12, is called a **reflex arc:**

sensory receptor detects the stimulus ➔ sensory afferents bring the stimulus to the CNS ➔ the CNS processes and integrates the information ➔ the CNS sends its output via motor efferents to an effector ➔ the effector performs the triggered action

The human body has many different reflex arcs, one of the simplest of which is the **stretch reflex.** Stretch reflexes are important in maintaining posture and equilibrium and are initiated when a muscle is stretched. The stretch is detected by **muscle spindles,** specialized stretch receptors in the muscles, and these stimuli are sent via sensory afferents to the CNS. The CNS then sends impulses down the motor efferents to the muscle, triggering a muscle contraction to counter the stretch.

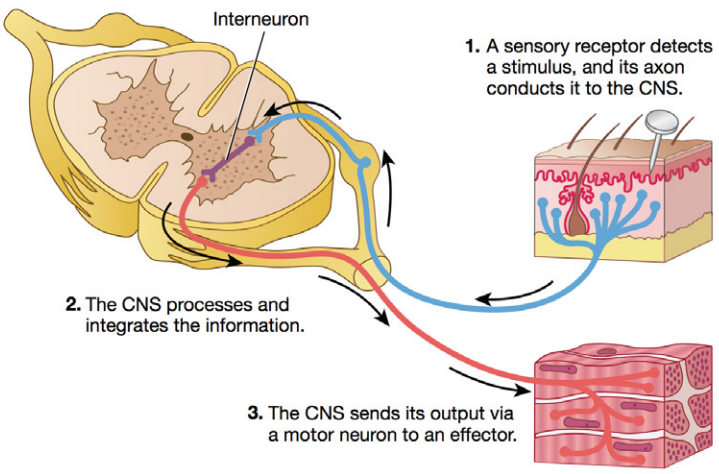

FIGURE **14.12** Reflex arc.

You can demonstrate the stretch reflex easily: Sit down with your knees bent and relaxed, and palpate (feel) the musculature of your posterior thigh. How do the muscles feel (taut or soft)? Now stand up, and bend over to touch your toes. Palpate the muscles of your posterior thigh again. How do they feel? The reason they feel different in this position is that you stretched the hamstring muscles when you bent over to touch your toes. This triggered a stretch reflex that resulted in shortening (or tightening) of those muscles.

Technically, this reflex can be carried out without the help of the cerebral cortex and can be mediated solely by the spinal cord. But does this mean that the cortex plays no role in these reflexes at all? Let's find out, using the simplest example of a stretch reflex—the patellar tendon (knee-jerk) reflex, shown in Figure 14.13.

FIGURE **14.13** Patellar tendon reflex.

1 Have your lab partner sit in a chair with legs dangling freely.

2 Palpate your partner's patellar tendon between the tibial tuberosity and the patella.

3 Tap this area with the flat end of a reflex hammer (sometimes a few taps are necessary to hit the right spot). What is the result?

4 Now give your partner a difficult math problem to work (long division with decimals usually does the trick). As your partner works the problem, tap the tendon again. Is this response different from the original response? If yes, how, and why?

Exercise 14-4

The Autonomic Nervous System

MATERIALS

- ❑ Automated or manual sphygmomanometer
- ❑ Stethoscope

The **autonomic nervous system** (ANS) is the largely involuntary branch of the peripheral nervous system charged with maintaining homeostasis of several different physiological variables in the face of changing conditions. The ANS has two branches—the **sympathetic nervous system** (SNS) and the **parasympathetic nervous system** (PSNS).

The cell bodies of the neurons of the SNS are located in the thoracic and lumbar regions of the spinal cord. Functionally, the SNS is often described in terms of the "fight-or-flight" response, in which the body prepares to respond to an emergency situation (e.g., running from an angry alligator). This gives rise to a useful mnemonic: Your body is *sympathetic* to your emergency situation, so your *sympathetic* nervous system comes to the rescue. Although reaction to an emergency is a primary function of the SNS, it isn't the whole story. The SNS is activated by *any* excitement, emotion, or exercise, even something as simple as standing up. The axons of the SNS release the neurotransmitters **epinephrine**, **norepinephrine**, and **acetylcholine**. These neurotransmitters trigger the following effects in their target tissues:

- Increased rate and force of heart contraction, which increases the blood pressure.
- Constriction of the blood vessels serving the abdominal viscera and the skin, which also increases the blood pressure.
- Dilation of the blood vessels serving the skeletal muscles.
- Dilation of the bronchioles (airway passages in the lungs).
- Decreased secretion from digestive glands.
- Decreased production of urine.
- Increased metabolic rate.
- Increased release of fatty acids and glucose.
- Dilation of the pupils.
- The release of epinephrine from the adrenal medulla.

The cell bodies of the neurons of the PSNS are located in cranial nerve nuclei and in the sacral portion of the spinal cord. Functionally, the PSNS is discussed in terms of its "rest and recovery" role, in which it promotes functions associated with digestion, defecation, and diuresis (urine production). The axons of the PSNS release the neurotransmitter acetylcholine, which has the following effects on its target tissues:

- Decreased heart rate, which decreases blood pressure.
- Dilation of the blood vessels serving the skin and abdominal viscera, which decreases blood pressure. (***Note***: This is *not* a direct effect of the PSNS on the blood vessels. Instead, it is an indirect effect resulting from an inhibition of sympathetic nerves.)
- Mild constriction of the bronchioles.
- Increased activity of smooth muscle of the digestive tract and secretion from digestive glands.
- Increased urine production.
- Storage of fats and glucose.
- Constriction of the pupils.
- Adjustment of the lens for near vision.

Notice that the effects of the SNS and PSNS are exactly opposite. Generally, the PSNS is subordinate to the SNS (digesting that doughnut isn't all that important when you're being chased by an angry alligator); however, neither branch of the ANS is ever completely quiet. The divisions work together constantly to provide the proper balance for any given situation.

Procedure 1 Testing Blood Pressure and Heart Rate Response to Exercise

One of the simplest ways to observe the effects of the SNS is with exercise. In this activity, in order to see the SNS in action, you will be measuring the effects of exercise on a partner's heart rate and blood pressure. When you have completed this activity, answer Check Your Understanding question 7 (p. 388).

1 Have your partner sit quietly for 2 minutes.

2 After 2 minutes, measure resting heart rate by placing two fingers on your partner's radial pulse (on the lateral side of the wrist). Count the number of beats for 1 minute. Record the rate in Table 14.7. Be sure to record the units (beats per minute).

3 Obtain a stethoscope, and listen to your partner's heart. How does the heartbeat sound (quiet, loud, etc.)?

4 Measure your partner's resting blood pressure using a sphygmomanometer (blood pressure cuff) and a stethoscope (instructions for taking blood pressures are found in Unit 19; pp. 513–514). You may also use an automated sphygmomanometer if one is available. Record the blood pressure in Table 14.7. Be sure to record the units (mmHg).

5 Have your partner perform vigorous exercise for several minutes (running up and down stairs or doing jumping jacks works well). Note that even minor exercise will produce changes in blood pressure and pulse, but the changes are more apparent after vigorous exercise (especially for those who are novices at taking blood pressure).

6 Immediately after the vigorous exercise, repeat the heart rate and blood pressure measurements, and record these data in Table 14.7. Then, listen to your partner's heart with a stethoscope. How does the heartbeat sound compared with the sounds you heard at rest?

TABLE **14.7** Results of Exercise and ANS Experiment

Situation	Blood Pressure	Heart Rate
Seated (at rest)		
Immediately after exercise		
After resting for 5 minutes		

7 Have your partner rest while seated for 5 minutes. Repeat the heart rate and blood pressure measurements, record these data in Table 14.7, and again listen to the heartbeat. Does the heart sound different after rest?

8 Interpret your results:

a In which situation(s) did the SNS dominate? How do you know?

b In which situation(s) did the PSNS dominate? How do you know?

Name _____

Section _____ Date _____



REVIEW

Check Your Recall

1 Label the following structures on Figure 14.14.

- ❑ Axon
- ❑ Endoneurium
- ❑ Epineurium
- ❑ Fascicle
- ❑ Myelin sheath
- ❑ Nerve
- ❑ Perineurium

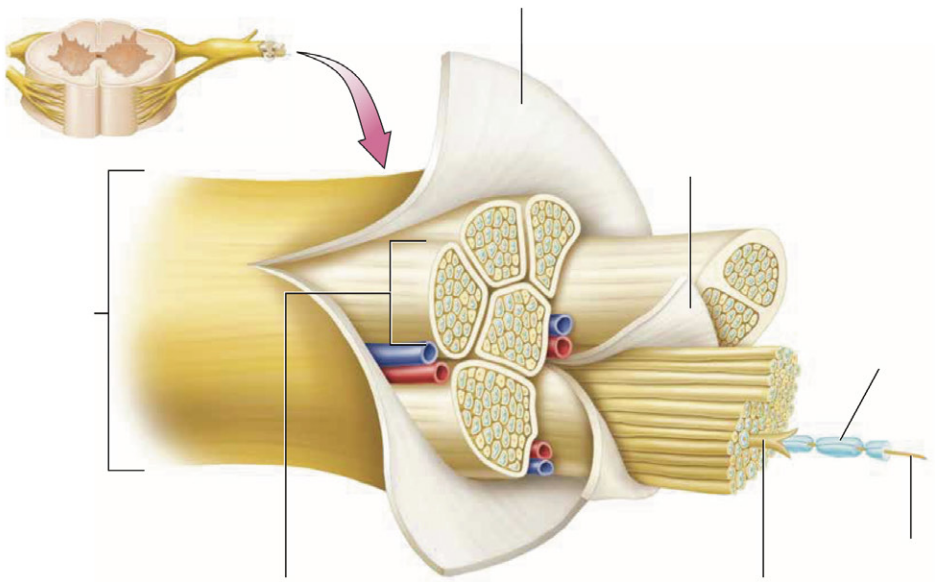

FIGURE **14.14** Anatomy of a peripheral nerve.

2 The structure where the optic nerves meet and partially exchange axons is called the

a. optic tract.
b. optic bulb.
c. oculomotor nerve.
d. optic chiasma.

3 Which of the following cranial nerves is a purely motor nerve?

a. Optic nerve.
b. Glossopharyngeal nerve.
c. Hypoglossal nerve.
d. Facial nerve.

4 *Matching:* Match the cranial nerve with its main functions.

_____ CN I	A. Sensory to the face, motor to the muscles of mastication
_____ CN II	B. Motor to the trapezius and sternocleidomastoid muscles
_____ CN III	C. Hearing and equilibrium
_____ CN IV	D. Olfaction (smell)
_____ CN V	E. Motor to the muscles of swallowing; taste to the posterior one-third of the tongue
_____ CN VI	F. Motor to one-sixth extraocular muscles (superior oblique muscle)
_____ CN VII	G. Motor to the tongue
_____ CN VIII	H. Vision
_____ CN IX	I. Motor to the muscles of facial expression, taste to the anterior two-thirds of the tongue
_____ CN X	J. Motor to four-sixths extraocular muscles, dilates the pupil, opens the eye, changes the shape of the lens
_____ CN XI	K. Motor to the muscles of swallowing and speaking, motor to the thoracic and abdominal viscera
_____ CN XII	L. Motor to one-sixth extraocular muscles (lateral rectus muscle)

5 What are the three branches given off by a spinal nerve, and where do they travel?

6 *Matching:* Match each spinal nerve with the main structures it supplies.

_____ Radial nerve	A. Anterior and lateral leg muscles and skin
_____ Inferior gluteal nerve	B. Medial thigh muscles, skin of the superomedial thigh
_____ Obturator nerve	C. Abdominal muscles, skin of the abdomen
_____ Phrenic nerve	D. Muscles of the forearm that flex the hand, most intrinsic hand muscles, skin on medial hand
_____ Common fibular nerve	E. Muscles on the posterior arm that extend the forearm, muscles of the forearm that extend the hand, skin on lateral hand
_____ Intercostal nerves	F. Diaphragm muscle
_____ Femoral nerve	G. Gluteus maximus muscle
_____ Ulnar nerve	H. Anterior thigh muscles, skin on anterior and medial thigh and leg

7 Number the events of a reflex arc from 1 (first event) through 5 (last event).

_____ CNS sends output via motor neurons to an effector.

_____ Sensory neurons bring the stimulus to the CNS.

_____ The muscle contracts.

_____ CNS processes and integrates the information.

_____ Sensory receptor detects the stimulus.

Name _____

Section _____ Date _____

8 Label the following nerves and plexuses on Figure 14.15.

- ❑ Brachial plexus
- ❑ Cervical plexus
- ❑ Intercostal nerves
- ❑ Lumbar plexus
- ❑ Median nerve
- ❑ Musculocutaneous nerve
- ❑ Radial nerve
- ❑ Sacral plexus
- ❑ Ulnar nerve

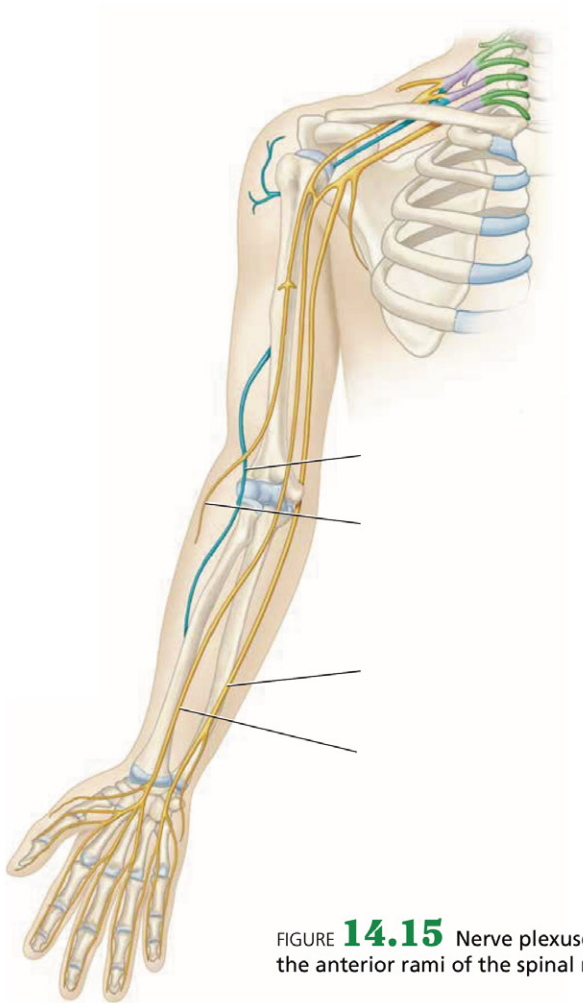

FIGURE **14.15** Nerve plexuses and the anterior rami of the spinal nerves.

9 Label the following nerves on Figure 14.16.

- ❑ Common fibular nerve
- ❑ Femoral nerve
- ❑ Lateral femoral cutaneous nerve
- ❑ Obturator nerve
- ❑ Pudendal nerve
- ❑ Sciatic nerve
- ❑ Superior gluteal nerve
- ❑ Tibial nerve

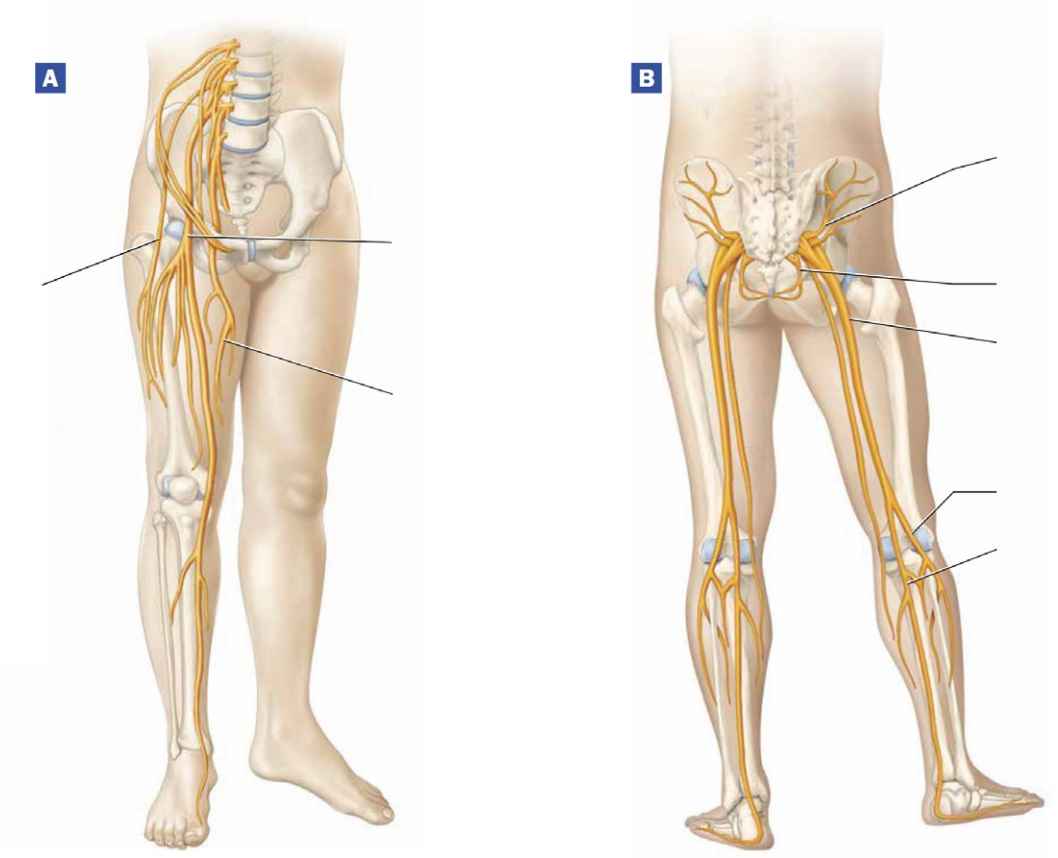

FIGURE **14.16** Nerve plexuses of the lower limb: (**A**) anterior view; (**B**) posterior view.

10 Mark each of the following as an effect of the sympathetic nervous system (SNS) or the parasympathetic nervous system (PSNS):

_____ Increased blood pressure

_____ Constriction of the pupils

_____ Changes the shape of the lens for near vision

_____ Dilation of the bronchioles

_____ Decreased secretion from digestive glands

_____ Storage of fats and glucose

_____ Increased micturition (urination)

_____ Decreased heart rate

_____ Constriction of blood vessels serving skin and abdominal viscera

Name _____

Section _____ Date _____

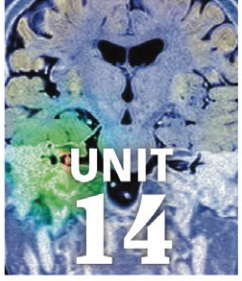

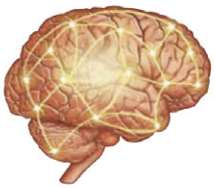

Check Your Understanding

REVIEW

Critical Thinking and Application Questions

1 Sometimes the terms "neuron" and "nerve" are mistakenly used interchangeably. Explain the difference between the two structures.

2 Damage to which cranial nerve(s) might produce the following results?

a Inability to move the tongue _____

b Inability to see _____

c Inability to masticate (chew food) _____

d Inability to swallow _____

3 Dave was playing a hockey game when he was hit in the face by a puck. He suffered a broken nose during the injury and now finds that his sense of smell has diminished. What is likely causing this?

4 Your patient, Mr. Pratchett, is unable to open his eyelid. On examination, you find that his pupil is dilated, and he is unable to move his affected eye in any direction except laterally and downward, indicating that only his lateral rectus and superior oblique extrinsic eye muscles are functioning. Based on this information, which cranial nerve do you think is involved in Mr. Pratchett's condition? Explain your reasoning.

5 Damage to which spinal nerve(s) might produce the following physical findings?

a Inability to extend the forearm and hand _____

b Inability to breathe _____

c Inability to feel the skin over the anterolateral thigh _____

d Inability to dorsiflex the foot _____

6 Marta is an editor and she spends a great deal of time typing on her computer. She begins to feel numbness and tingling in her anterior and lateral hands and weakness in the muscles of her forearm that flex her hand. What nerve is likely involved in her problem, and what do you think has happened? Explain her symptoms.

_____

_____

_____

_____

_____

7 The herbal supplement bitter orange, also known as *synephrine*, mimics the effects of the neurotransmitters of the SNS on the heart and blood vessels serving the abdominal viscera and skin. What effect do you think this would have on blood pressure? Considering this, do you think this drug should be given to people with hypertension (high blood pressure)?

_____

_____

_____

_____

_____

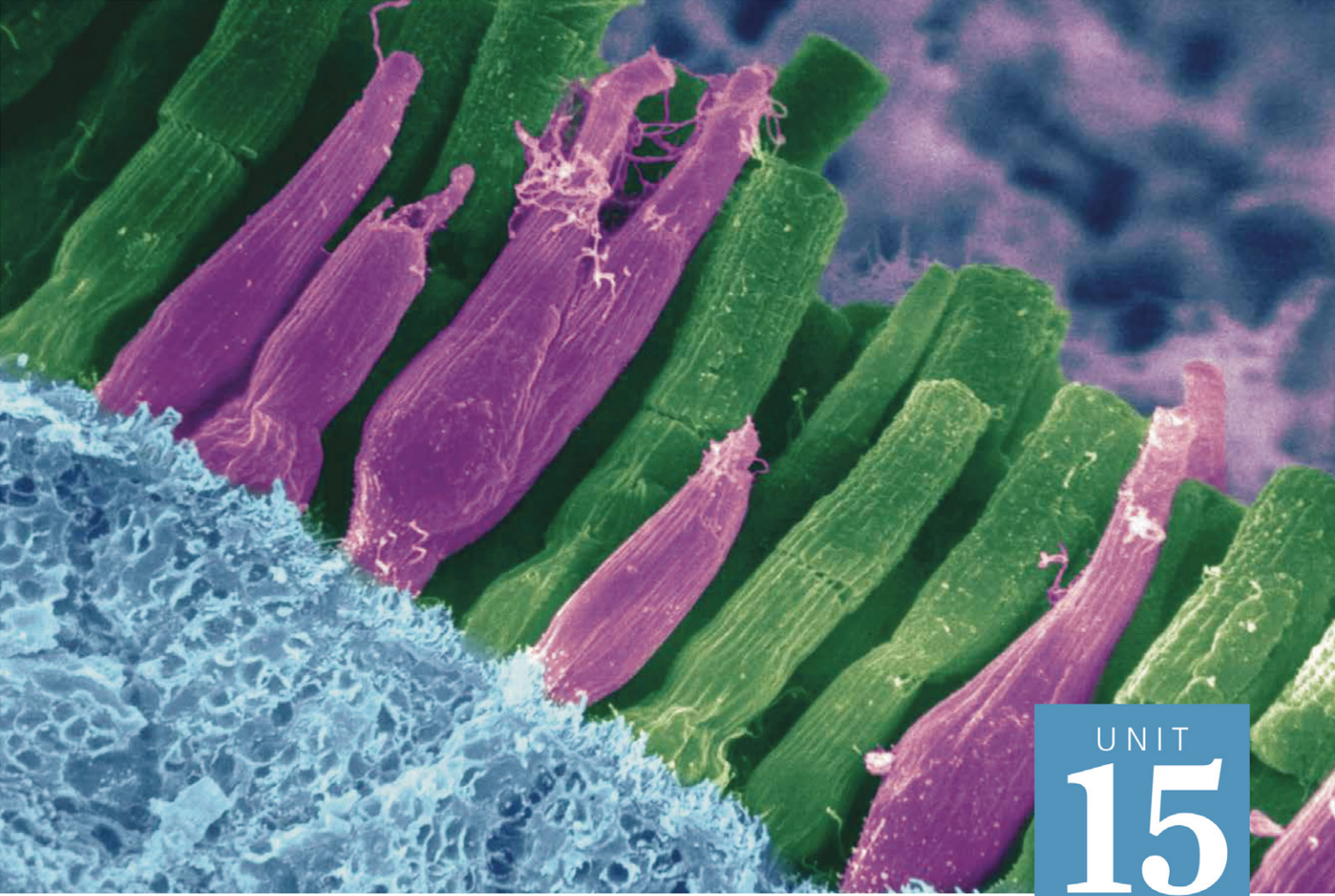

UNIT
15

General and Special Senses

Once you have completed this unit, you should be able to:

1. Identify structures of the eye.
2. Describe the extrinsic eye muscles that move the eyeball.
3. Compare the functions of the rods and cones.
4. Identify structures of the ear.
5. Perform tests of hearing and equilibrium.
6. Identify structures of the olfactory and taste senses.
7. Determine the relative concentration of cutaneous sensory receptors in different regions of the body.

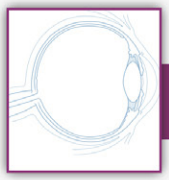

Name _____ Section _____ Date _____

PRE-LAB EXERCISES

Complete the following exercises prior to coming to lab, using this lab manual and your textbook for reference.

Pre-Lab Exercise 15-1

Key Terms

You should be familiar with the following terms before coming to lab.

Term	Definition

Structures of the Eye

Conjunctiva _____

Lacrimal gland _____

Sclera _____

Cornea _____

15

Iris _____

Pupil _____

Lens _____

Ciliary body _____

Choroid _____

Retina _____

Rods _____

Cones _____

Name _____ Section _____ Date _____

Structures of the Ear

Auricle _____

External auditory canal _____

Tympanic membrane _____

Auditory ossicles _____

Pharyngotympanic tube _____

Vestibule _____

Semicircular canals _____

Cochlea _____

Structures of Taste and Smell

Chemosenses _____

Olfactory epithelium _____

Tongue papillae _____

Pre-Lab Exercise 15-2

Anatomy of the Eye

Label and color the structures of the eye in Figures 15.1 and 15.2 with the terms from Exercise 15-1 (p. 395). Use your text and Exercise 15-1 in this unit for reference.

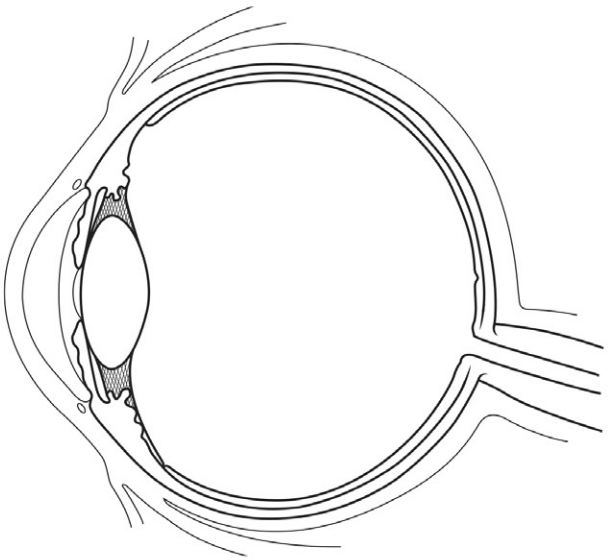

FIGURE **15.1** Eyeball, sagittal section.

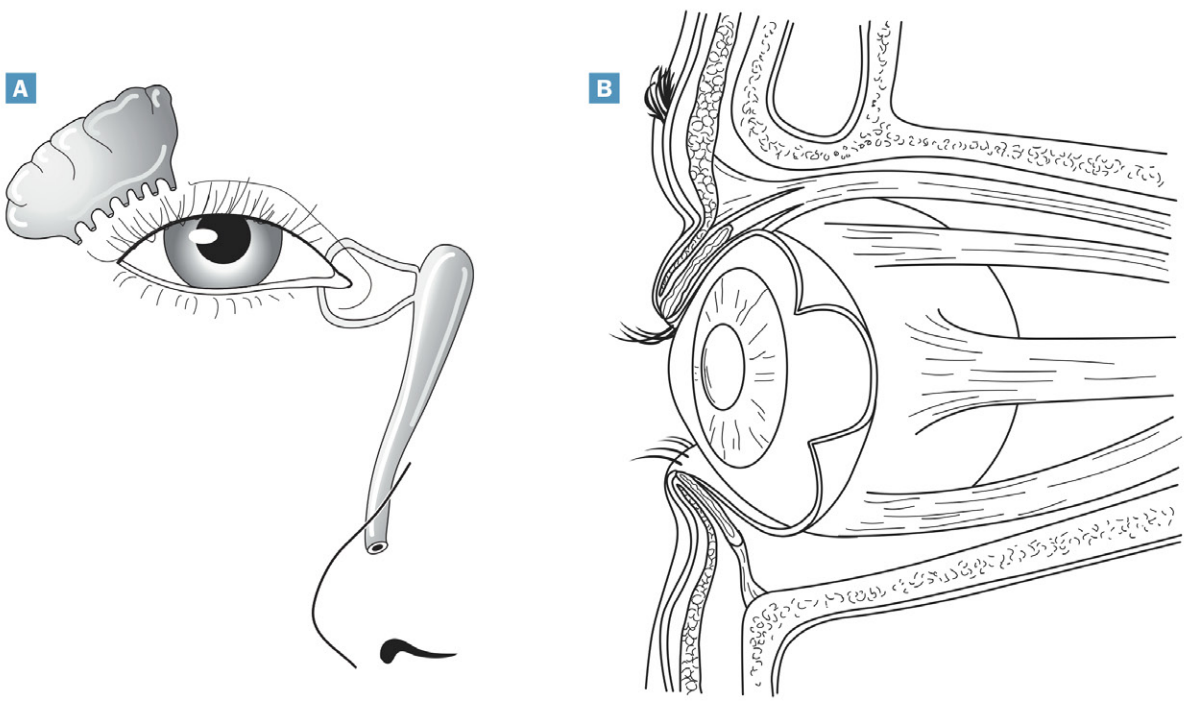

FIGURE **15.2** External structures of the eye: (**A**) anterior view; (**B**) lateral view.

Name _____ Section _____ Date _____

Pre-Lab Exercise 15-3

Extrinsic Eye Muscles

The six muscles that move the eyeball are called **extrinsic eye muscles**. First, label and color the extrinsic eye muscles illustrated in Figure 15.3, using Exercises 15-1 (p. 395) and 14-2 (p. 369) for reference. Then, fill in Table 15.1 with the location, action, and cranial nerve innervation for each of the extrinsic eye muscles.

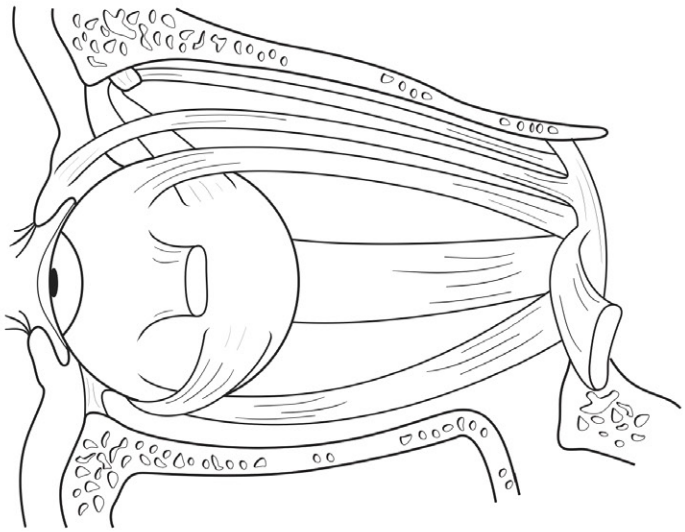

FIGURE **15.3** Extrinsic eye muscles.

TABLE **15.1** The Extrinsic Eye Muscles

Muscle	Location	Action	Cranial Nerve Innervation
Superior rectus muscle			
Inferior rectus muscle			
Medial rectus muscle			
Lateral rectus muscle			
Superior oblique muscle			
Inferior oblique muscle			

Pre-Lab Exercise 15-4

Anatomy of the Ear

Label and color the structures of the ear in Figure 15.4 with the terms from Exercise 15-2 (p. 403).

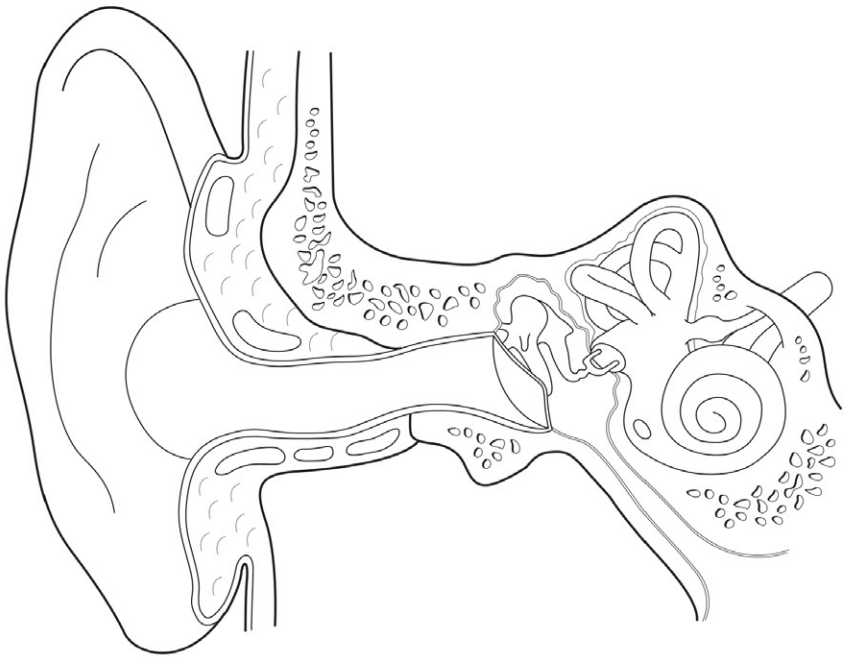

FIGURE **15.4** Ear.

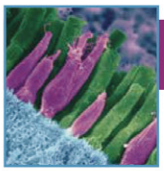

Colorized SEM of rods and cones in the retina.

EXERCISES

Sensation is broadly defined as the detection of changes in the internal and external environments. Sensation may be conscious or subconscious, depending on the destination of the sensory information. For example, certain blood vessels have receptors that detect blood pressure. These stimuli are transmitted to the brainstem, which makes changes as necessary to ensure that blood pressure adjusts to meet the body's needs. This information never makes it to the cerebral cortex, so you are not consciously aware of it. However, information eventually taken to the cerebral cortex for integration and interpretation (e.g., the taste of your food or the level of light in a room) is something of which you are consciously aware. This is called **perception**, and it is the focus of this unit.

The following exercises ask you to examine the anatomy and physiology of the **special senses**: vision, hearing and equilibrium, taste, and smell. You also will examine the **general senses** in this unit, which include the senses of touch, pain, and temperature.

Exercise 15-1

Anatomy of the Eye and Vision

MATERIALS

- ❑ Eye models
- ❑ Preserved eyeballs
- ❑ Dissection equipment
- ❑ Dissection trays
- ❑ Snellen vision chart
- ❑ Dark green or blue paper
- ❑ Ruler

The eye is a complex organ consisting of two main components: external structures such as the eyelids and the eyeball itself. Many of the external structures of the eye protect the delicate eyeball, and others move the eyeball.

Anteriorly, the eye is covered by the eyelids, or **palpebrae** (pal-PEE-bree; Fig. 15.5A). The palpebrae meet medially and laterally at the **medial** and **lateral canti** (or *commissures*), respectively. There are several structures in and around the palpebrae that contain sebaceous or mucous glands to lubricate the palpebrae and anterior surface of the eyeball. One such structure is the **lacrimal caruncle** (LAK-rih-muhl kar-UN-kuhl), which is located at the medial canthus.

One of the most prominent external structures of the eye is the **lacrimal apparatus**, which produces and drains tears. The lacrimal apparatus consists of the **lacrimal gland**, located in the superolateral orbit, and the ducts that drain the tears it produces. As you can see in Figure 15.5A, tears drain into small **lacrimal canals** near the medial

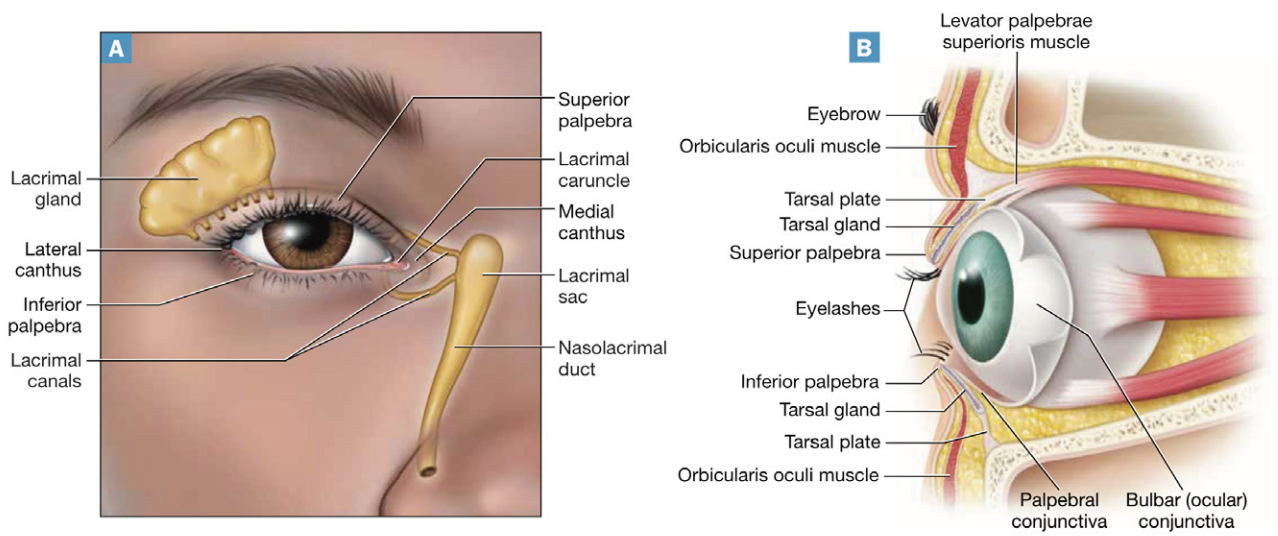

FIGURE **15.5** External structures of the eye: (**A**) anterior view; (**B**) lateral view.

canthus, which then drain into the **lacrimal sac**, which is found in a depression in the lacrimal bone. From here, tears travel through the **nasolacrimal duct**, and finally empty into the nasal cavity just inferior to the inferior nasal concha (which is why your nose runs when you cry).

Other accessory structures associated with the palpebrae are shown in Figure 15.5B. As you can see, each palpebra has a stiff **tarsal plate** composed of dense connective tissue, which is associated with a sebaceous gland known as a **tarsal gland.** In addition, the internal surfaces of the palpebrae are lined with a thin mucous membrane called the **palpebral conjunctiva** (kon-junk-TY-vah). Where this mucous membrane contacts the eyeball, it curls around and becomes the **bulbar conjunctiva,** which lines much of the eyeball's superficial surface. Finally, two muscles that open and close the eye insert into and around the palpebrae: the *levator palpebrae superioris muscle* and the *orbicularis oculi muscle.*

The other major external structures of the eye are the **extrinsic eye muscles,** which move the eyeball. As you learned in Unit 11, there are six extrinsic eye muscles (Fig. 15.6), including the

1. **lateral rectus muscle,** which moves the eyeball laterally;
2. **medial rectus muscle,** which moves the eyeball medially;
3. **superior rectus muscle,** which moves the eyeball superiorly;
4. **inferior rectus muscle,** which moves the eyeball inferiorly;
5. **superior oblique muscle,** which moves the eyeball inferiorly and laterally, and
6. **inferior oblique muscle,** which moves the eyeball superiorly and laterally.

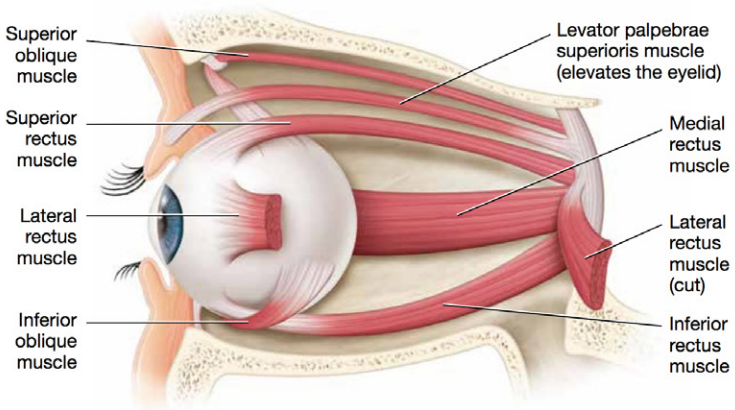

FIGURE **15.6** Extrinsic eye muscles.

15

The **eyeball** itself is a hollow organ that is divided into two main portions: the anterior cavity and the posterior cavity. The boundary for the cavities is a crystalline structure known as the **lens,** which is one of the structures in the eye that refracts (bends) light coming into the eye to focus it. The **anterior cavity** is anterior to the lens and is filled with a watery fluid called **aqueous humor.** Aqueous humor is produced relatively constantly and drained by a structure called the **scleral venous sinus.** The **posterior cavity** is posterior to the lens and contains a thicker fluid called **vitreous humor** (VIT-ree-us). Unlike aqueous humor, vitreous humor is present at birth and remains relatively unchanged throughout life. Both fluids help to refract light coming into the eye.

The eyeball has three distinct tissue layers, or tunics (Fig. 15.7):

1. **Fibrous tunic.** This outermost layer of the eyeball is the **fibrous tunic,** which consists mostly of dense irregular collagenous connective tissue. It is avascular (lacks a blood supply) and consists of two parts:
   a. **Sclera.** The **sclera** (SKLEHR-ah) is the white part of the eyeball, and makes up the posterior five-sixths of the fibrous tunic. It is white because of numerous collagen fibers that contribute to its thickness and toughness (in the same way a joint capsule or a ligament is tough and white).
   b. **Cornea.** The clear **cornea** (KOHR-nee-ah) makes up the anterior one-sixth of the fibrous tunic. It is the fourth refractory medium of the eyeball.
2. **Vascular tunic.** Also called the **uvea** (YOO-vee-uh), the **vascular tunic** carries most of the blood supply to the tissues of the eye. It is composed of three main parts:
   a. **Choroid.** The highly vascular **choroid** (KOHR-oyd) makes up the posterior part of the vascular tunic. The choroid is brown in color to prevent light scattering in the eye.
   b. **Ciliary body.** The **ciliary body** (SILL-ee-ehr-ee) is located at the anterior aspect of the vascular tunic. It is made chiefly of the **ciliary muscle,** smooth muscle fibers that control the shape of the lens. The muscle attaches to the lens via small **suspensory ligaments.** The ciliary body also produces aqueous humor.
   c. **Iris.** The pigmented **iris** is the most anterior portion of the vascular tunic. It consists of muscle fibers arranged around an opening called the **pupil.** As the fibers contract, the pupil either constricts or dilates. The iris also

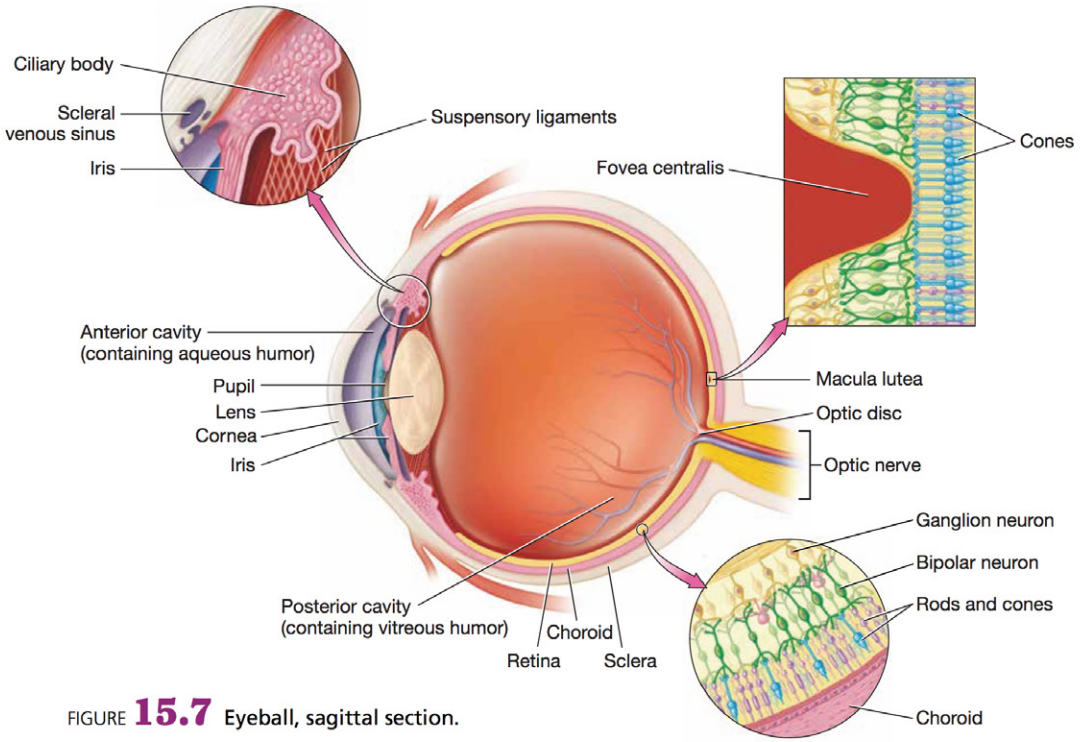

FIGURE **15.7** Eyeball, sagittal section.

divides the anterior cavity into two smaller subdivisions: the *anterior segment*, which is anterior to the iris, and the *posterior segment*, which is posterior to the iris.

3. **Sensory tunic.** The **sensory tunic** consists of the retina and the optic nerve. The **retina** (RET-in-ah) is a thin, delicate structure that contains three layers of neurons: **photoreceptors** called rods and cones that detect light; **bipolar neurons** that receive input from photoreceptors; and **ganglion cells** whose axons converge to form the **optic nerve**, or cranial nerve II. Recall from Unit 14 that the optic nerves exit from the posterior orbit, then partially exchange axons at the X-shaped *optic chiasma* before diverging into the two *optic tracts* (see Fig. 14.4, p. 369). The input is eventually delivered to the visual cortex in the occipital lobe of the brain.
   a. **Rods.** The photoreceptors known as **rods** are scattered throughout the retina and are responsible for vision in dim light and for peripheral vision. They can produce vision in black and white only.
   b. **Cones.** The second type of photoreceptors, **cones**, are concentrated at the posterior portion of the retina. They are found in highest numbers in an area called the **macula lutea** (MAK-yoo-lah LOO-tee-ah). At the center of the macula lutea is the **fovea centralis** (FOH-vee-uh sin-TRAL-iss), which contains only cones. Cones are responsible for color and high-acuity (sharp) vision in bright light.

Note that there are no rods or cones at the posteriormost aspect of the eyeball where the optic nerve leaves the eyeball. This location is called the **optic disc**. It is also known as the *blind spot* because its lack of photoreceptors means that this region can produce no images.

Notice in Figure 15.7 that light has to pass through four refractive media before it hits the retina: the cornea, the aqueous humor, the lens, and the vitreous humor. Of these four, the cornea and the lens have the greatest refractive power. The cornea by itself accounts for about two-thirds of the eye's refractive power, and indeed the cornea alone provides most of the necessary refraction when viewing distant objects.

When viewing nearer objects, however, additional "fine-tuning" refraction is needed by the lens. This is accomplished with the help of the ciliary muscle—when its smooth muscle fibers contract, the ciliary body moves closer to the lens and removes tension on the suspensory ligaments. This causes the lens to become rounder, an adjustment called *accommodation* that allows the lens to provide the additional refraction necessary to focus light on the retina. When the eye switches to a distant object again, the ciliary muscle relaxes, which moves the ciliary body farther away from the lens and puts tension on the suspensory ligaments. This flattens the lens and allows the cornea to again become the primary refractive medium.

Procedure 1 Model Inventory for the Eye

Identify the following structures of the eye and the eyeball on models and diagrams using your textbook and this unit for reference. As you examine the anatomical models and diagrams, record the name of the model and the structures you were able to identify on the model inventory in Table 15.2. When you have finished the activity, answer Check Your Understanding question 1 (p. 417).

Accessory Structures

1. Palpebrae
2. Medial and lateral canthi
3. Lacrimal caruncle
4. Lacrimal apparatus
   a. Lacrimal gland
   b. Lacrimal canals
   c. Lacrimal sac
   d. Nasolacrimal duct
5. Tarsal plate
6. Tarsal gland
7. Palpebral conjunctiva
8. Bulbar conjunctiva
9. Extrinsic eye muscles
   a. Lateral rectus m.
   b. Medial rectu m.
   c. Superior rectus m.
   d. Inferior rectus m.
   e. Superior oblique m.
   f. Inferior oblique m.

Eyeball

1. Lens
2. Anterior cavity
   a. Aqueous humor
   b. Scleral venous sinus
3. Posterior cavity
   a. Vitreous humor
4. Fibrous tunic
   a. Sclera
   b. Cornea
5. Vascular tunic (uvea)
   a. Choroid
   b. Ciliary body
      (1) Ciliary muscle
      (2) Suspensory ligaments
   c. Iris
      (1) Pupil
6. Sensory tunic
   a. Retina
   b. Optic nerve (cranial nerve II)
   c. Macula lutea
   d. Fovea centralis
   e. Optic disc

TABLE **15.2** Model Inventory for the Eye

Model/Diagram	Structures Identified

Procedure 2 Eyeball Dissection

In this exercise you will examine the structures of the eyeball on a fresh or preserved eyeball. Eyeball dissection isn't as gross as it sounds—I promise!

Safety Note
Goggles and gloves are required!

1 Examine the external anatomy of the eyeball (Fig. 15.8), and record the structures you can identify.

2 Use scissors to remove the adipose tissue surrounding the eyeball. Identify the optic nerve.

3 Hold the eyeball at its anterior and posterior poles, and use a sharp scalpel or scissors to make an incision in the frontal plane. Watch out, as aqueous humor and vitreous humor are likely to spill everywhere.

4 Complete the incision, and separate the anterior and posterior portions of the eyeball (Fig. 15.9). Take care to preserve the fragile retina—the thin, delicate yellow-tinted inner layer.

5 List the structures you can identify in the anterior half of the eyeball (Fig. 15.10):

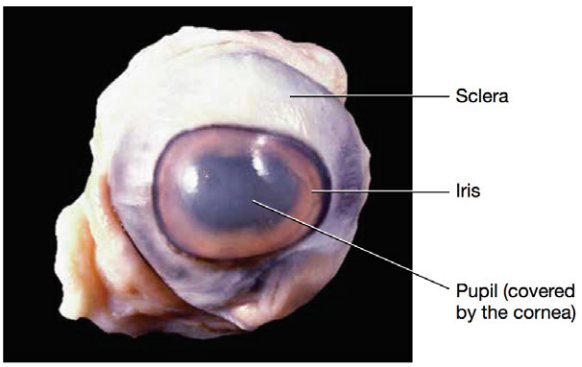

FIGURE **15.8** Anterior view of an eyeball.

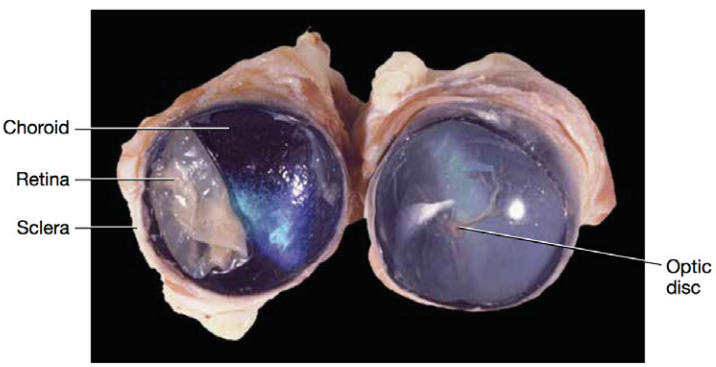

FIGURE **15.9** Frontal section of an eyeball showing the tunics.

6 List the structures you can identify in the posterior half of the eyeball:

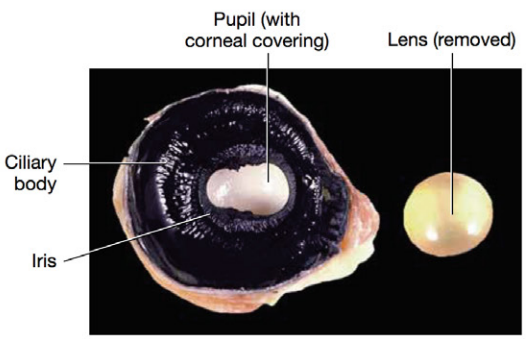

FIGURE **15.10** Posterior view of the anterior portion of the eyeball and lens.

Procedure 3 Comparing the Distribution of Rods and Cones

We discussed earlier the unequal distribution of the photoreceptors in the retina. In this exercise you will see (no pun intended) firsthand the differences in vision produced by the rods and the vision produced by the cones. After you have completed the activity, answer Check Your Understanding question 2 (p. 417).

1. On a small sheet of paper, write the phrase "Anatomy is fun" in your regular-size print.
2. Hold this piece of paper about 25 cm (10 inches) directly in front of your lab partner's eyes, and have your lab partner read the phrase.

   Can your partner read the phrase clearly? _____

   Which photoreceptors are producing the image? _____
3. Now write a second phrase on the paper, and don't tell your partner what the phrase says. Hold the paper about 10 inches from your partner's peripheral vision field. Have them continue to stare forward and attempt to read what you have written.

   Can your partner read the phrase clearly? _____

   Which photoreceptors are producing the image? _____
4. For the next test, dim the lights in the room. Have your partner stand 20 feet in front of a Snellen eye chart and read down the chart, stopping with the smallest line read accurately. (You should stand next to the chart to verify your partner has read the correct letters.) The numbers next to the line indicate your partner's vision relative to someone with perfect vision, a measurement known as **visual acuity**. For example, a person with 20/40 vision can see at 20 feet what someone with perfect vision could see at 40 feet. Record your partner's ratio (e.g., 20/40).

   Visual acuity: _____
5. With the lights still dimmed and your partner standing in the same place, hold a piece of dark green or dark blue paper over the Snellen chart. Ask your partner to identify the color of the paper you are holding. Record your partner's response.

   Paper color: _____
6. Repeat the above processes with the lights illuminated. Record your partner's visual acuity and paper color response.

   Visual acuity: _____

   Paper color: _____
7. In which scenario were visual acuity and color vision better? Explain your findings.

_____

_____

_____

_____

_____

Procedure 4 Testing the Extrinsic Eye Muscles

In this procedure, you will determine which extrinsic eye muscles are responsible for moving the eyeballs in each direction.

1. Trace a line in the air about 1 foot in front of your partner's eyes, moving from your partner's left to right. Have your partner follow your finger without moving the head. Which extrinsic eye muscles produce the movements you see for each eye?

   Right eye _____ Left eye _____

2. Now trace a diagonal line, starting at the upper right corner and moving to the lower left corner. Have your partner follow your finger again. Which extrinsic eye muscles produce the movements you see for each eye?

   Right eye _____ Left eye _____

3. Again have your partner follow your finger, but trace a horizontal line from left to right. Which extrinsic eye muscles produce the movements you see for each eye?

   Right eye _____ Left eye _____

4. Finally, trace another diagonal, this time from your partner's lower right to the upper left, and have your partner follow along (you should have traced out an hourglass shape overall). Which extrinsic eye muscles produce the movements you see for each eye?

   Right eye _____ Left eye _____

Procedure 5 Finding the Blind Spot

Recall that the location where the optic nerve exits the eyeball lacks photoreceptors and so leaves a "blind spot"—a place that can produce no images. You can find the blind spot with the simple diagram shown in Figure 15.11.

1. Close your left eye, and hold Figure 15.11 about 56 cm (18 inches) in front of your right eye so that the "+" is directly in line with your right eye.
2. Slowly move Figure 15.11 toward your right eye while staring at the "+" until the large dot disappears. When it disappears, it is in your blind spot.
3. Have your lab partner measure with a ruler the distance from the page to your eye.

   Distance in centimeters: _____

4. Repeat the process for your left eye.

   Distance in centimeters: _____

FIGURE **15.11** Blind spot test.

Procedure 6 Testing for Astigmatism

The condition called **astigmatism** is characterized by irregularities in the surfaces in the cornea and/or the lens. These irregularities decrease visual acuity because these structures are unable to focus light precisely on the retina. You can test for astigmatism by using a chart like the one shown in Figure 15.12. When you have finished the procedure, answer Check Your Understanding question 3 (p. 417).

1. Hold Figure 15.12 a comfortable reading distance from your eyes, about 35 cm (14 inches).
2. Cover one eye, and stare at the center of Figure 15.12. All lines should appear equally distinct and black. If any of the lines appear blurry or gray, astigmatism may be present.
3. Cover the other eye and repeat the process.
4. Was astigmatism present in either eye?

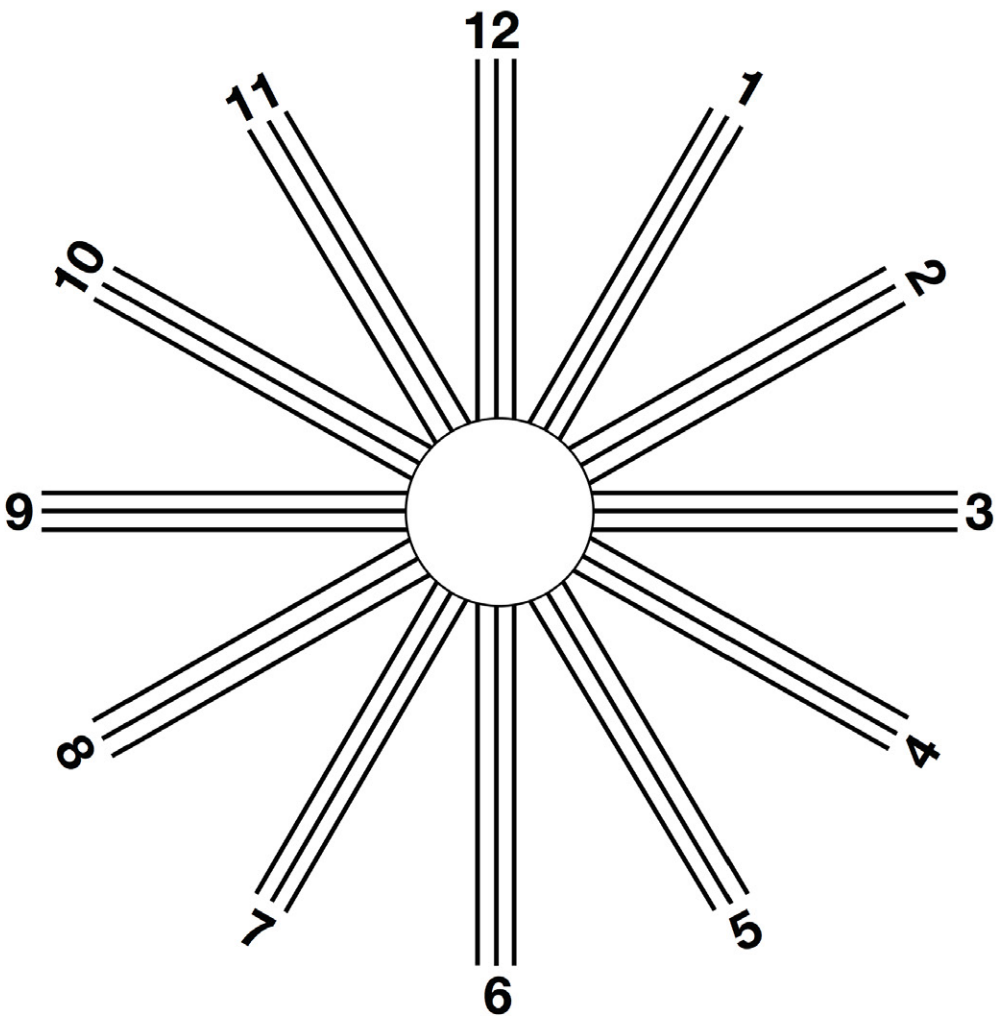

FIGURE **15.12** Astigmatism test chart.

Exercise 15-2

Anatomy of the Ear, Hearing, and Equilibrium

MATERIALS

- ❑ Ear models
- ❑ Tuning fork (500–1,000 Hz)
- ❑ Whiteboard markers

The ear contains structures both for hearing and equilibrium. It is divided into three regions: the outer, middle, and inner ear (Fig. 15.13).

1. **Outer ear.** The **outer ear** begins with the **auricle** (OHR-ih-kuhl), or *pinna*, a shell-shaped structure composed primarily of elastic cartilage that surrounds the opening to the **external auditory canal.** The external auditory canal extends about 2.5 cm into the temporal bone, where it ends in the **tympanic membrane,** a thin sheet of epithelium and connective tissue that separates the outer ear from the middle ear.
2. **Middle ear.** The **middle ear** is a small air-filled cavity within the temporal bone that houses tiny bones called the **auditory ossicles** (AW-sih-kullz)—the **malleus** (MAL-ee-us; hammer), **incus** (ING-kus; anvil), and **stapes** (STAY-peez; stirrup). The ossicles transmit vibrations from the tympanic membrane to the inner ear through a structure called the **oval window,** to which the stapes is attached. An additional structure in the middle ear is the **pharyngotympanic tube** (fah-ring-oh-tim-PAN-ik; also called the auditory tube), which connects the middle ear to the pharynx (throat) and equalizes pressure in the middle ear.
3. **Inner ear.** The **inner ear** contains the sense organs for hearing and equilibrium. It consists of cavities collectively called the **bony labyrinth** filled with a fluid called **perilymph** (PEHR-ee-limf). Within the perilymph is a series of membranes, called the **membranous labyrinth,** that contain a thicker fluid called **endolymph** (EN-doh-limf; Fig. 15.14). The bony labyrinth has three regions:
   a. **Vestibule.** The **vestibule** is an egg-shaped bony cavity that houses two structures responsible for equilibrium—the **saccule** (SAK-yool) and the **utricle** (YOO-trih-kuhl). Both structures transmit impulses down the vestibular portion of the vestibulocochlear nerve. The saccule and the utricle are responsible for a type of equilibrium called *static equilibrium*. This refers to maintaining balance when the body is not moving—hence the word "static"—but the head is tilted.
   b. **Semicircular canals.** Situated at right angles to one another, the **semicircular canals** house the **semicircular ducts** and the **ampullae,** which work together with the organs of the vestibule to maintain equilibrium. Their orientation allows them to be responsible for a type of equilibrium called *rotational equilibrium*. This refers to the ability to maintain balance when the body or head is moving. Like the saccule and utricle, the semicircular ducts and the ampulla transmit impulses down the vestibular portion of the vestibulocochlear nerve.
   c. **Cochlea.** The **cochlea** (KOHK-lee-ah) is a spiral bony canal that contains a part of the membranous labyrinth called the **cochlear duct.** Within the cochlear duct is a structure known as the **spiral organ** (or the **organ of**

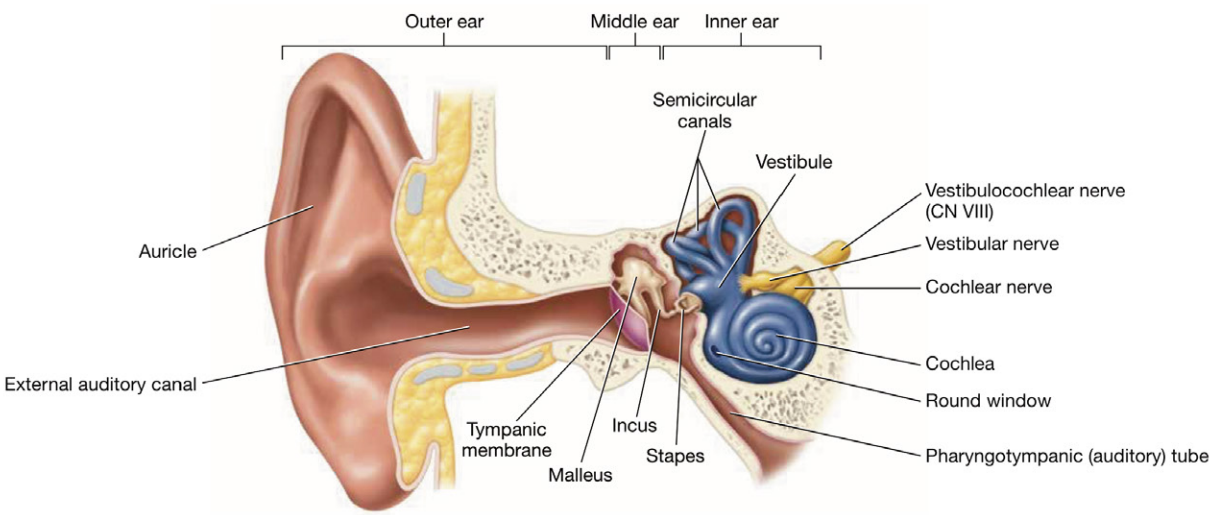

FIGURE **15.13** Anatomy of the ear.

Corti) whose specialized **hair cells** depolarize in response to sound wave vibrations. The depolarized hair cells transmit sound impulses to the cochlear portion of the vestibulocochlear nerve. The cochlea has a hole in its lateral wall called the **round window,** which plays a role in allowing the perilymph in the cochlea to vibrate.

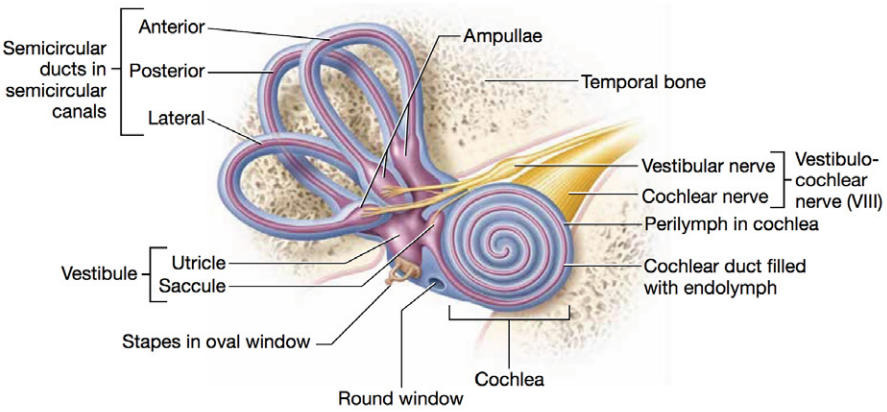

FIGURE **15.14** Membranous labyrinth of the inner ear.

Procedure 1 Model Inventory for the Ear

Identify the following structures of the ear on models and diagrams, using your textbook and this unit for reference. As you examine the anatomical models and diagrams, record the name of the model and the structures you were able to identify on the model inventory in Table 15.3. After you have completed the activity, answer Check Your Understanding question 4 (p. 417).

1. Outer ear
   a. Auricle (pinna)
   b. External auditory canal
2. Middle ear
   a. Tympanic membrane
   b. Ossicles
      (1) Malleus
      (2) Incus
      (3) Stapes
   c. Oval window
   d. Pharyngotympanic (auditory) tube
3. Inner ear
   a. Vestibule
      (1) Saccule
      (2) Utricle
   b. Semicircular canals
      (1) Semicircular duct
      (2) Ampullae
   c. Cochlea
      (1) Cochlear duct
      (2) Round window
   d. Vestibulocochlear nerve (cranial nerve VIII)
      (1) Vestibular nerve
      (2) Cochlear nerve

TABLE **15.3** Model Inventory for the Ear

Model/Diagram	Structures Identified

Hearing Acuity

There are two possible types of hearing loss:

1. **Conductive hearing loss** results from interference of sound conduction through the outer and/or middle ear.
2. **Sensorineural hearing loss** results from damage to the inner ear or the vestibulocochlear nerve.

Two clinical tests can help a healthcare professional determine if hearing loss is conductive or sensorineural: the Weber test and the Rinne (rinn-ay) test. Both tests use tuning forks that vibrate at specific frequencies when struck. The tuning forks are placed either directly on the bones of the skull to evaluate bone conduction—the ability to hear the vibrations transmitted through the bone—or in front of the ear, to evaluate air conduction—the ability to hear the vibrations transmitted through the air. After you have completed both tests, answer Check Your Understanding questions 5 and 6 (p. 418).

Procedure 2 Weber Test

1 Obtain a tuning fork with a frequency of 500 to 1,000 Hz (cycles per second).

2 Hold the tuning fork by the base, and strike it lightly with a mallet, or tap it on the edge of the table. The fork should begin ringing softly. If it is ringing too loudly, grasp the tines to stop it from ringing, and try again.

3 Place the base of the vibrating tuning fork on the midline of your partner's head, as shown in Figure 15.15.

4 Ask your partner if the sound is heard better in one ear or if the sound is heard equally in both ears. If the sound is heard better in one ear, this is called lateralization.

Was the sound lateralized? If yes, to which ear? _____

5 To illustrate what it would sound like if the sound were lateralized, have your partner place a finger in one ear. Repeat the test.

a In which ear was the sound heard better? _____

b If a patient has conduction deafness, in which ear do you think the sound will be heard most clearly (the deaf ear or the good ear)?

_____

Why? (If you are confused, think about your results when one ear was plugged.)

_____

_____

_____

_____

c If a patient has sensorineural deafness, in which ear do you think the sound will be best heard?

_____

FIGURE **15.15** Weber test.

Procedure 3 Rinne Test

1. Strike the tuning fork lightly to start it ringing, as shown in Figure 15.16.
2. Place the base of the tuning fork on your partner's mastoid process.
3. Time the interval during which your partner can hear the sound by having your partner tell you when the ringing stops.

   Time interval in seconds: _____
4. Once your partner cannot hear the ringing, quickly move the still-vibrating tuning fork 1 to 2 cm lateral to the external auditory canal (the fork should not be touching your partner at this point).
5. Time the interval from the point when you moved the tuning fork in front of the external auditory canal to when your partner can no longer hear the sound.

   Time interval in seconds: _____

   Which situation tested bone conduction? _____

   Which situation tested air conduction? _____
6. Typically, the air-conducted sound is heard twice as long as the bone-conducted sound. For example, if the bone-conducted sound was heard for 15 seconds, the air-conducted sound should be heard for 30 seconds.

   Were your results normal? _____

   What type of deafness is present if the bone-conducted sound is heard longer than the air-conducted sound?

   _____

15

FIGURE **15.16** Rinne test.

Equilibrium

A common and simple test of equilibrium is the **Romberg test**, in which the person is asked to stand still, first with the eyes open and then with the eyes closed. Under normal conditions, the vestibular apparatus should be able to maintain equilibrium in the absence of visual input. If the vestibular apparatus is impaired, however, the brain relies on visual cues to maintain balance.

Procedure 4 Romberg Test

1. Have your partner stand erect with the feet together and the arms at the sides in front of a whiteboard.
2. Use a whiteboard marker to draw lines on the board on either side of your partner's torso. These lines are for your reference in the next part.
3. Have your partner stand in front of the whiteboard for 1 minute, staring forward with his or her eyes open. Use the lines on either side of the torso to note how much your partner sways while standing. Below, record the amount of side-to-side swaying (i.e., minimal or significant):

4. Now have your partner stand in the same position for 1 minute with his or her eyes closed. Again note the amount of side-to-side swaying, using the marker lines for reference.

   Was the amount of swaying more or less with the eyes closed?

   Why do you think this is so?

   What do you predict would be the result for a person with an impaired vestibular apparatus? Explain.

Exercise 15-3

Olfactory and Taste Senses

MATERIALS

- ❑ Head and neck models
- ❑ Tongue model

Both olfaction and taste are sometimes referred to as the **chemosenses,** because they both rely on chemoreceptors to relay information about the environment to the brain. The chemoreceptors of the olfactory sense are located in a small patch in the roof of the nasal cavity called the **olfactory epithelium** (Fig. 15.17). The olfactory epithelium contains bipolar neurons called **olfactory receptor cells.** Their axons, which are collectively called **cranial nerve I** or the **olfactory nerve**, penetrate the holes in the cribriform plate to synapse on the **olfactory bulb,** which then sends the impulses down the axons of the **olfactory tract** to the olfactory cortex.

Taste receptors are located on **taste buds** housed on projections from the tongue called **papillae** (Fig. 15.18). Of the four types of papillae—**filiform, fungiform, foliate,** and **circumvallate**—all but filiform papillae house taste buds. **Fungiform papillae** are scattered over the surface of the tongue, whereas the large **circumvallate papillae** are located at the posterior aspect of the tongue, arranged in a V shape. **Foliate papillae** contain taste buds primarily during childhood; they are located on the lateral aspects of the tongue.

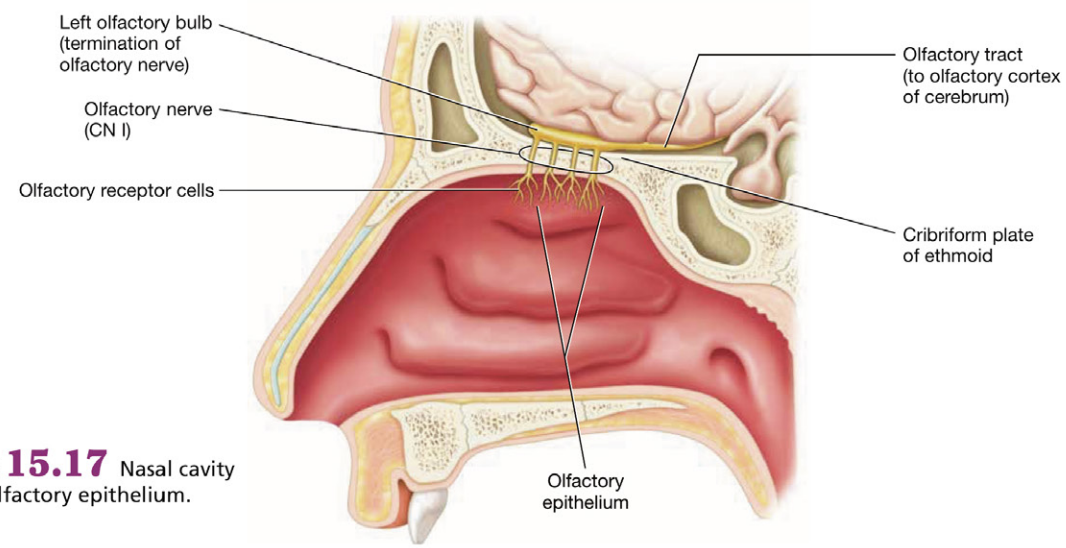

FIGURE **15.17** Nasal cavity and olfactory epithelium.

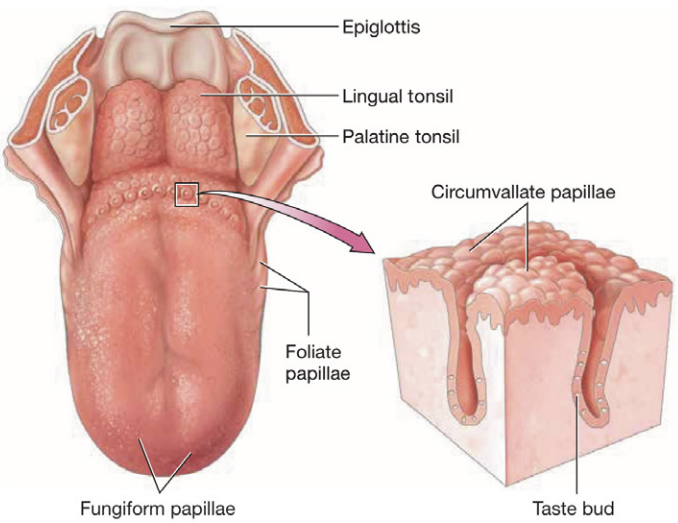

FIGURE **15.18** Surface of the tongue.

Procedure 1 Model Inventory for Olfaction and Taste

Identify the following structures of the olfactory and taste senses on anatomical models and charts. As you examine the anatomical models and diagrams, record the name of the model and the structures you were able to identify on the model inventory in Table 15.4. After you have completed the activity, answer Check Your Understanding question 7 (p. 418).

Olfaction

1. Nasal cavity
   a. Cribriform plate
2. Olfactory epithelium
   a. Olfactory receptor cells
3. Olfactory nerve (cranial nerve I)
4. Olfactory bulbs
5. Olfactory tract

Taste

1. Taste buds
2. Papillae
   a. Fungiform papillae
   b. Circumvallate papillae
   c. Foliate papillae

TABLE 15.4 Model Inventory for Olfaction and Taste

Model/Diagram	Structures Identified

Exercise 15-4

The General Senses: Cutaneous Sensation

MATERIALS

- ❑ Water-soluble marking pens (two colors)
- ❑ Ruler
- ❑ 2 wooden applicator sticks (or toothpicks)
- ❑ Alcohol swabs

Sensory receptors in the skin respond to different stimuli, including temperature, touch, and pain. These receptors are not distributed throughout the skin equally, but instead are concentrated in certain regions of the body. The following experiments will allow you to determine the relative distribution of the receptors for touch in the skin by performing two tests: the error of localization and two-point discrimination. After you complete the activities, answer Check Your Understanding question 8 (p. 418).

Error of Localization

Every region of the skin corresponds to an area of the primary somatosensory cortex of the cerebrum. Some regions are better represented than others and are therefore capable of localizing stimuli with greater precision than are less well-represented areas. The **error of localization** (also called tactile localization) tests the ability to determine the location of the skin touched and demonstrates how well-represented each region of the skin is in the cerebral cortex.

Procedure 1 Testing Error of Localization

1. Have your partner sit with his or her eyes closed.
2. Use a water-soluble marking pen to place a mark on your partner's anterior forearm.
3. Using a different color of marker, have your partner, still with eyes closed, place a mark as close as possible to where he or she believes the original spot is located.
4. Use a ruler to measure the distance between the two points in millimeters. This is your error of localization.
5. Repeat this procedure for each of the following locations:
   a. Anterior thigh.
   b. Face.
   c. Palm of hand.
   d. Fingertip.
6. Record your data in Table 15.5.

TABLE **15.5** Error of Localization

Location	Error of Localization (mm)
Anterior forearm	
Anterior thigh	
Face	
Palm of hand	
Fingertip	

Two-Point Discrimination

The **two-point discrimination test** assesses the ability to perceive the number of stimuli ("points") placed on the skin. Areas that have a higher density of touch receptors are better able to distinguish between multiple stimuli than those with fewer touch receptors.

Procedure 2 Testing Two-Point Discrimination

1. Have your partner close his or her eyes.
2. Place the ends of two wooden applicator sticks close together (they should be nearly touching) on your partner's skin on the anterior forearm. Ask how many points your partner can discriminate—one or two.
3. If your partner can sense only one point, move the sticks farther apart. Repeat this procedure until your partner can distinguish two separate points touching the skin.
4. Use a ruler to measure the distance between the two sticks in millimeters. This is your two-point discrimination.
5. Repeat this procedure for each of the following locations:
   a. Anterior thigh.
   b. Face (around the lips and/or eyes).
   c. Vertebral region.
   d. Fingertip.
6. Record your data in Table 15.6.

TABLE **15.6** Two-Point Discrimination

Location	Two-Point Discrimination (mm)
Anterior forearm	
Anterior thigh	
Face	
Vertebral region	
Fingertip	

7. What results did you expect for each test? Explain.

8 Did your observations agree with your expectations? Interpret your results.

15

Name _____

Section _____ Date _____

UNIT 15 REVIEW

Check Your Recall

1 Label the following parts of the eyeball on Figure 15.19.

- ❑ Choroid
- ❑ Ciliary body
- ❑ Conjunctiva
- ❑ Cornea
- ❑ Inferior palpebra
- ❑ Iris
- ❑ Lateral rectus muscle
- ❑ Lens
- ❑ Optic nerve
- ❑ Posterior cavity
- ❑ Pupil
- ❑ Retina
- ❑ Sclera
- ❑ Superior rectus muscle
- ❑ Tarsal gland

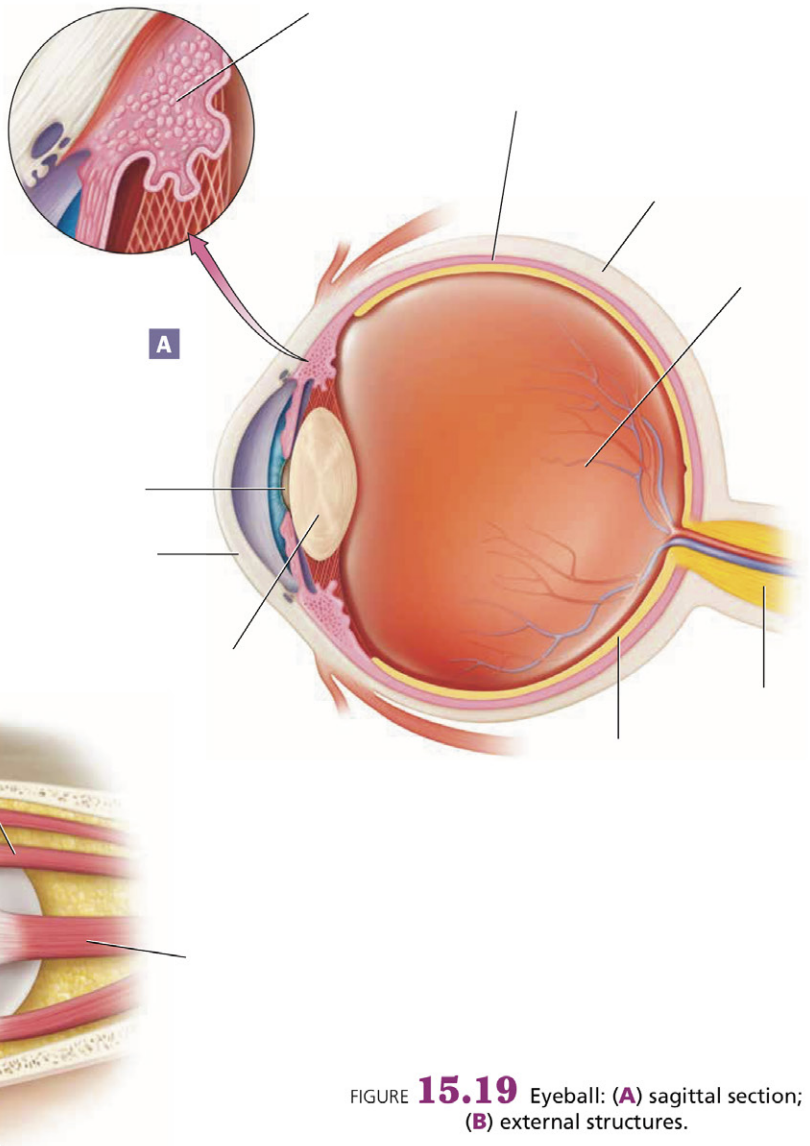

FIGURE **15.19** Eyeball: (**A**) sagittal section; (**B**) external structures.

2 *Fill in the blanks:* The fluid in the anterior cavity is known as _____, whereas the fluid in the posterior cavity is known as _____.

3 The rods are responsible for _____, whereas the cones are responsible for _____.

a. peripheral and dim light vision; high-acuity color vision
b. high-acuity color vision; peripheral and dim light vision
c. peripheral and color vision; high-acuity and dim light vision
d. high-acuity and dim light vision; peripheral and color vision

4 The pharyngotympanic tube connects the _____ to the _____.

a. middle ear; inner ear
b. external auditory canal; middle ear
c. inner ear; pharynx
d. middle ear; pharynx

5 *Fill in the blanks:* The structures of the cochlea are responsible for _____, whereas the structures of the saccule and utricle are responsible for _____ equilibrium, and semicircular ducts and ampulla are responsible for _____ equilibrium.

6 *True/False:* Mark the following statements as true (T) or false (F). If the statement is false, correct it so it is a true statement.

_____ a. Sensorineural hearing loss results from damage to the inner ear or the vestibulocochlear nerve.

_____ b. The auditory ossicles transmit vibrations through the round window.

_____ c. Astigmatism refers to irregularities in the surface of the retina.

_____ d. The six extrinsic eye muscles move the eyeball.

_____ e. Smell and taste are considered visceral senses.

_____ f. Accommodation is the adjustment of the lens necessary for near vision.

7 The axons of the olfactory nerve synapse are located on the

a. olfactory bulb.
b. olfactory epithelium.
c. cranial nerve I.
d. olfactory tract.

Name _____

Section _____ Date _____

8 Label the following parts of the ear on Figure 15.20.

- ❑ Auricle
- ❑ Cochlea
- ❑ Cochlear duct
- ❑ External auditory canal
- ❑ Incus
- ❑ Malleus
- ❑ Pharyngotympanic tube
- ❑ Round window
- ❑ Saccule
- ❑ Semicircular canals
- ❑ Stapes
- ❑ Tympanic membrane
- ❑ Utricle
- ❑ Vestibule
- ❑ Vestibulocochlear nerve

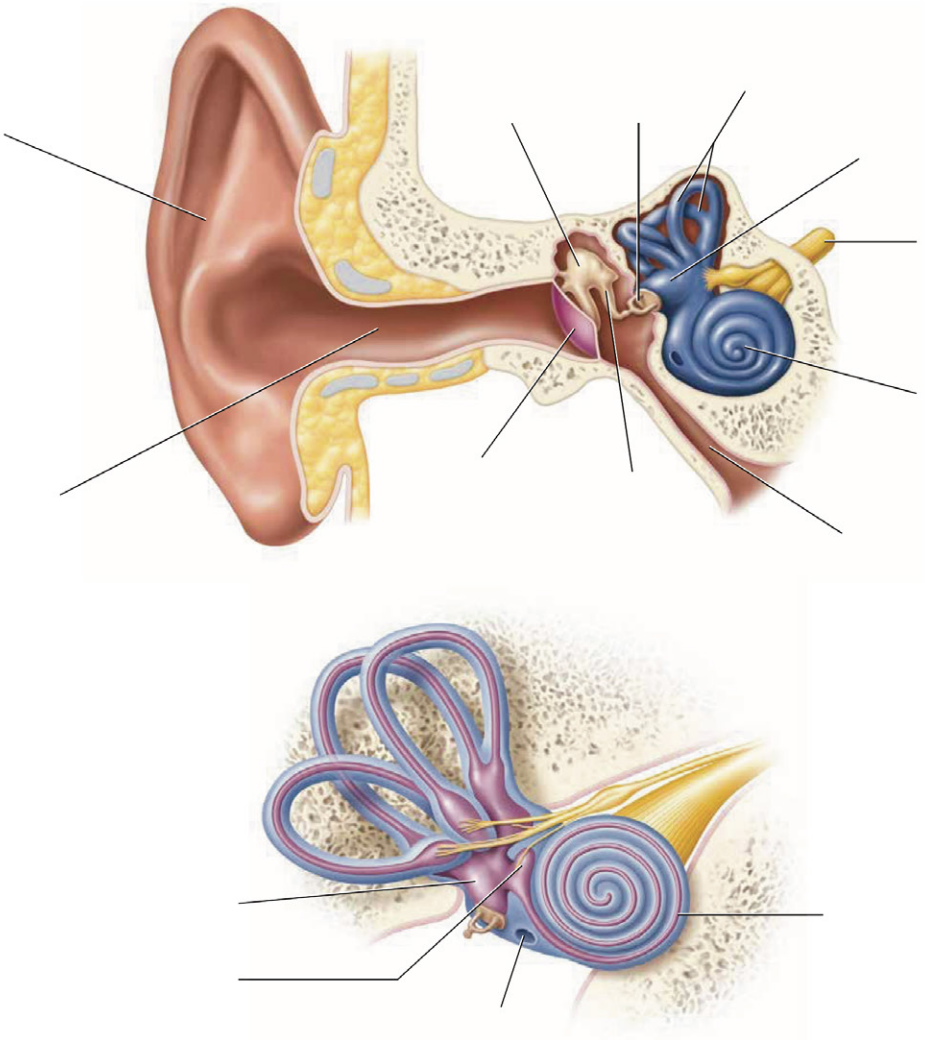

FIGURE **15.20** Anatomy of the ear.

9 Which of the following types of papillae of the tongue does not house taste buds?

a. Fungiform papillae.
b. Filiform papillae.
c. Circumvallate papillae.
d. Foliate papillae.

10 You would expect the error of localization and the two-point discrimination threshold to be highest on the

a. back.
b. lip.
c. fingertip.
d. palm.

Name _____

Section _____ Date _____

REVIEW

Check Your Understanding

Critical Thinking and Application Questions

1 A person who visits the eye doctor is often given eye drops containing the drug *atropine* to dilate the pupils. A side effect of this drug is paralysis of the ciliary muscle, an effect called *cycloplegia*. Will a person with cycloplegia have difficulty with near vision or distance vision? Explain.

2 The disease *macular degeneration* is characterized by a gradual loss of vision as a result of degeneration of the macula lutea. Considering the type of cells located in the macula lutea, which type of vision do you think a sufferer of macular degeneration would lose? Why?

3 LASIK, or *laser-assisted in situ keratomileusis*, is a surgical procedure on the eye that millions of people have undergone to improve visual acuity. It involves the use of a laser is to reshape the cornea in individuals suffering from astigmatism, near-sightedness (myopia), or far-sightedness (hyperopia). How could changing the shape of the cornea affect one's visual acuity?

4 Explain why infectious *otitis media* (inflammation of the middle ear) may result in a simultaneous pharyngitis (inflammation of the throat).

5 A standard hearing aid functions by amplifying the sound conducted through the external auditory canal. Explain why this type of hearing aid is effective for conductive hearing loss, but not sensorineural hearing loss.

6 The most common cause of hearing loss is exposure to loud noise such as music, which can permanently damage the hair cells of the cochlea. Would you expect this to result in conductive or in sensorineural hearing loss? What results would you expect from the Rinne and Weber tests in an individual with noise-induced hearing loss?

7 Your patient is in a car accident and several days later complains of a loss of smell. An X-ray reveals a fracture of the cribriform plate. What structures specifically have been damaged? How has this interfered with your patient's sense of smell?

8 Kevin presents to your office after a mountain biking accident last weekend during which he fell on his left elbow. He says that since the accident, his forearm alternates between periods of numbness and feeling "like he has hit his funny bone." You test the two-point discrimination on Kevin's left fifth digit and find that it is 6 mm. On his right fifth digit, however, it is less than 1 mm. You also find that his forearm muscles that flex his hand on the left side are very weak, as are most of the intrinsic muscles of his left hand. What has likely happened? How does this explain the results of the two-point discrimination test? (***Hint:*** You may want to refer to Unit 14, pp. 359–388, for help.)

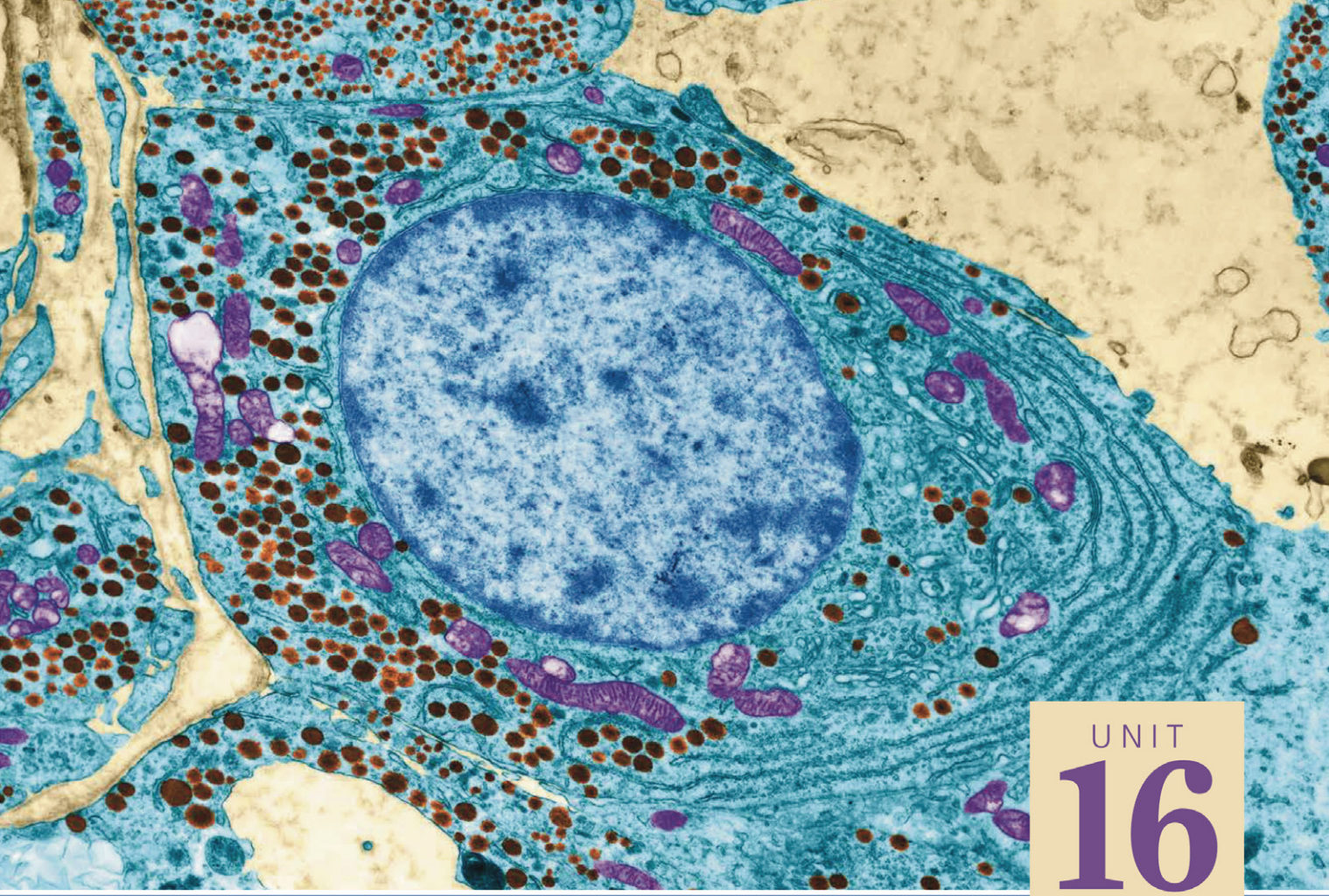

UNIT
16

Endocrine System

Once you have completed this unit, you should be able to:

1. Identify endocrine organs and structures.
2. Identify microscopic structures of endocrine organs.
3. Trace the functions, stimulus for secretion, and target tissues of various hormones.
4. Describe the negative feedback mechanisms that control hormone secretion.
5. Apply principles of the endocrine system to clinical cases.

Name _____ Section _____ Date _____

PRE-LAB EXERCISES

Complete the following exercises prior to coming to lab, using this lab manual and your textbook for reference.

Pre-Lab Exercise 16-1



Key Terms

You should be familiar with the following terms before coming to lab. Please note that key hormones are covered in Pre-Lab Exercise 16-3 (p. 423).

Term	Definition

General Terms

Endocrine organ (gland) _____

Hormone _____

Target tissue _____

Negative feedback _____

16

Endocrine Organs

Hypothalamus _____

Anterior pituitary _____

Posterior pituitary _____

Thyroid gland _____

Parathyroid glands _____

Pineal gland _____

Thymus _____

Name _____ Section _____ Date _____

Pancreas _____

Adrenal cortex _____

Adrenal medulla _____

Ovaries _____

Testes _____

Pre-Lab Exercise 16-2

Endocrine System Anatomy

Label and color the structures of the endocrine system in Figure 16.1 with the terms from Exercise 16-1 (p. 425). Use your text and Exercise 16-1 in this unit for reference.

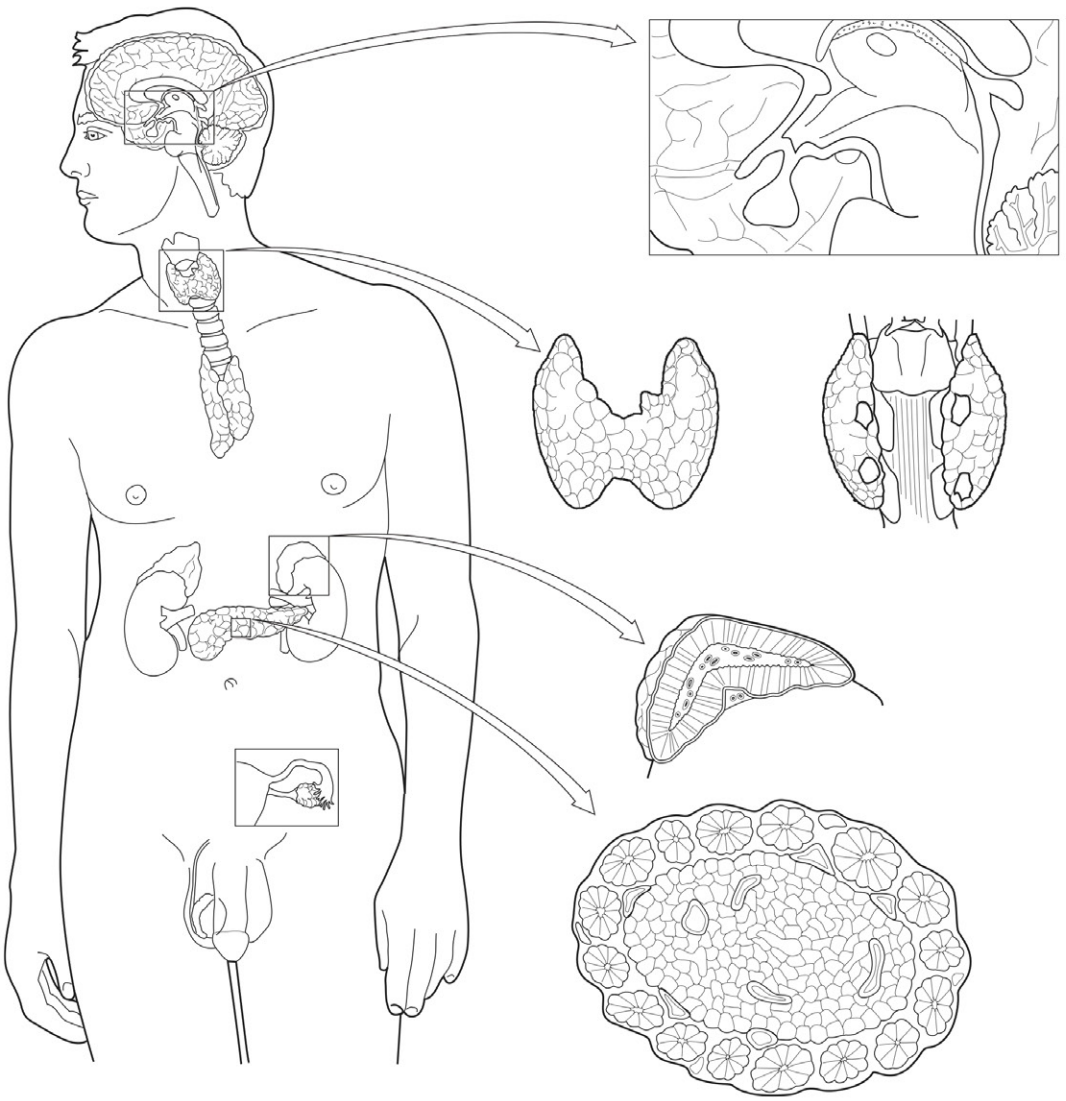

FIGURE **16.1** Organs and tissues of the endocrine system.

Name _____ Section _____ Date _____

Pre-Lab Exercise 16-3

Hormones: Target Tissues and Effects

Fill in Table 16.1 with the organ that secretes each hormone, the hormone's target tissue, and its main effects.

TABLE **16.1** Properties of Hormones

Hormone	Organ That Secretes the Hormone	Target Tissue(s)	Main Effects
Antidiuretic hormone			
Oxytocin			
Thyroid-stimulating hormone			
Adrenocorticotropic hormone			
Growth hormone			
Prolactin			
Melatonin			
Thyroxine and triiodothyronine (T4 and T3)			

(continues)

TABLE **16.1** Properties of Hormones *(cont.)*

Hormone	Organ That Secretes the Hormone	Target Tissue(s)	Main Effects
Calcitonin			
Thymosin and thymopoietin			
Parathyroid hormone			
Cortisol			
Aldosterone			
Epinephrine and norepinephrine			
Insulin			
Glucagon			

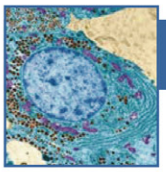

Color-enhanced TEM of a hormone-secreting pituitary gland cell.

EXERCISES

The **endocrine system** is a diverse group of ductless glands that plays a major role in maintaining the homeostasis of multiple physiological variables. The group works closely with the other system that maintains the homeostasis of multiple physiological variables—the nervous system. Although these two systems both work toward the same goal, you will notice that the methods by which they do so differ. The nervous system functions via action potentials (nerve impulses) and releases **neurotransmitters** that directly affect target cells. The effects are nearly immediate, but they are very short in duration. In contrast, the endocrine system brings about its effects via the secretion of **hormones**—chemicals released into the bloodstream that typically act on distant targets. The effects of hormones are not immediate, but they are longer-lasting than those of the nervous system.

In general, hormones regulate the processes of other cells, including inducing the production of enzymes or other hormones, changing the metabolic rate of a cell, and altering permeability of the plasma membrane. You might think of hormones as the "middle managers" of the body, because they communicate the messages from their "bosses" (the endocrine glands) and tell the "workers" (other cells) what to do. Some endocrine glands (e.g., the thyroid and anterior pituitary glands) secrete hormones as their primary function. Others, however, secrete hormones as a secondary function, examples of which are the heart (atrial natriuretic peptide), adipose tissue (leptin), the kidneys (erythropoietin), and the stomach (gastrin).

This unit introduces you to the anatomy, histology, and physiology of the endocrine organs and hormones. To close out this unit, you will play "endocrine detective" and solve three "endocrine mysteries."

Exercise 16-1

Endocrine System Anatomy

MATERIALS

- ❑ Endocrine system models
- ❑ Human torso models
- ❑ Head and neck models
- ❑ Fetal models

The 10 organs in the body that have hormone secretion as a primary function are the hypothalamus, the pituitary gland, the pineal gland, the thyroid gland, the parathyroid glands, the thymus, the adrenal gland, the pancreas, and the ovaries or testes (Fig. 16.2). Let's take a closer look at each of these organs (note that we discuss the ovaries and testes only briefly here; they are discussed further in Unit 27).

1. **Hypothalamus and Pituitary Gland.** The **hypothalamus**, the inferior part of the diencephalon, is known as a **neuroendocrine organ**. It can be likened to the endocrine system's chief executive officer (CEO). It has a close working relationship with the **pituitary gland** (pih-TOO-ih-tehr-ee), to which it is attached by a stalk called the **infundibulum** (in-fun-DIB-yoo-lum). Notice in Figure 16.3 that the pituitary gland is actually two separate structures: The **anterior pituitary gland**, or **adenohypophysis** (ad-in-oh-hy-PAWF-ih-sis), is composed of glandular epithelium and secretes a variety of hormones that affect other tissues in the body. The **posterior pituitary**, or **neurohypophysis** (noor-oh-hy-PAWF-ih-sis), is actually composed of nervous tissue rather than glandular tissue.

   The hypothalamus produces two types of hormones. The first, called **inhibiting** and **releasing hormones** respectively, are those that inhibit and stimulate secretion from the anterior pituitary gland. In response to hypothalamic-releasing hormones, the anterior pituitary gland secretes hormones that stimulate other endocrine and exocrine glands in the body. In Figure 16.3A, you can see how the hypothalamus communicates with the anterior pituitary gland via a specialized set of blood vessels collectively called the **hypothalamic-hypophyseal portal system** (hy-PAW-fih-see-uhl). The releasing and inhibiting hormones are synthesized by hypothalamic neurons and enter capillaries in the hypothalamus, after which they travel through small veins in the infundibulum. They then enter a second capillary bed in the anterior pituitary, where they exit the blood and interact with anterior pituitary cells to influence their functions.

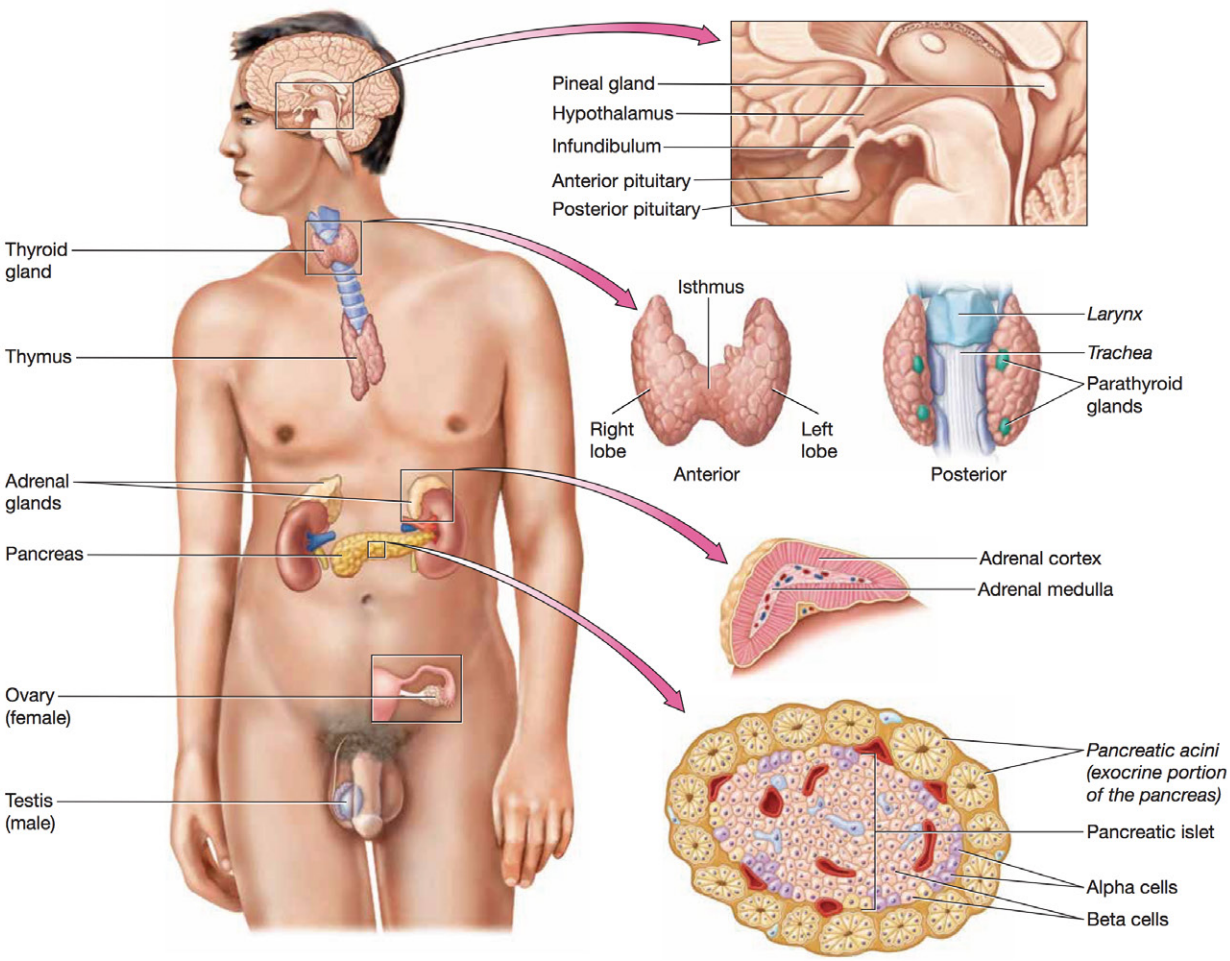

FIGURE **16.2** Organs and tissues of the endocrine system.

In addition to inhibiting and releasing hormones, the hypothalamus makes the hormone **oxytocin** (awks-ee-TOH-sin), which triggers uterine contraction and milk ejection from the mammary gland. It also produces **antidiuretic hormone** (an-tee-dy-yoo-RET-ik; **ADH**), which causes water retention from the kidneys. These hormones are produced by hypothalamic neurons that extend the length of the infundibulum down into the posterior pituitary, where they are stored (Fig. 16.3B).

a. The **anterior pituitary gland** mostly produces hormones known as *tropic hormones*, or those that influence the functions of other glands. Examples include **thyroid-stimulating hormone** (**TSH**), which stimulates growth of and secretion from the thyroid; **prolactin**, which stimulates milk production from mammary glands; **adrenocorticotropic hormone** (ah-dree-noh-kohr-tih-koh-TROH-pik; **ACTH**), which stimulates secretion from the adrenal cortex; and two reproductive hormones, **luteinizing hormone** (LOO-tee-in-aye-zing) and **follicle-stimulating hormone**, which affect primarily the testes and ovaries. An exception is **growth hormone** (**GH**), which increases the rate of cell division and protein synthesis in all tissues and has both tropic and nontropic effects.

b. The posterior pituitary doesn't produce any hormones at all and functions merely as a place to store the oxytocin and ADH produced by the hypothalamus.

2. **Pineal gland**. Recall from Unit 13 (p. 333) that the tiny **pineal gland** (pin-EE-uhl) is located in the posterior and superior diencephalon. This neuroendocrine organ secretes the hormone **melatonin** (mel-uh-TOH-nin) in response to decreased light levels and acts on the reticular formation of the brainstem to trigger sleep.

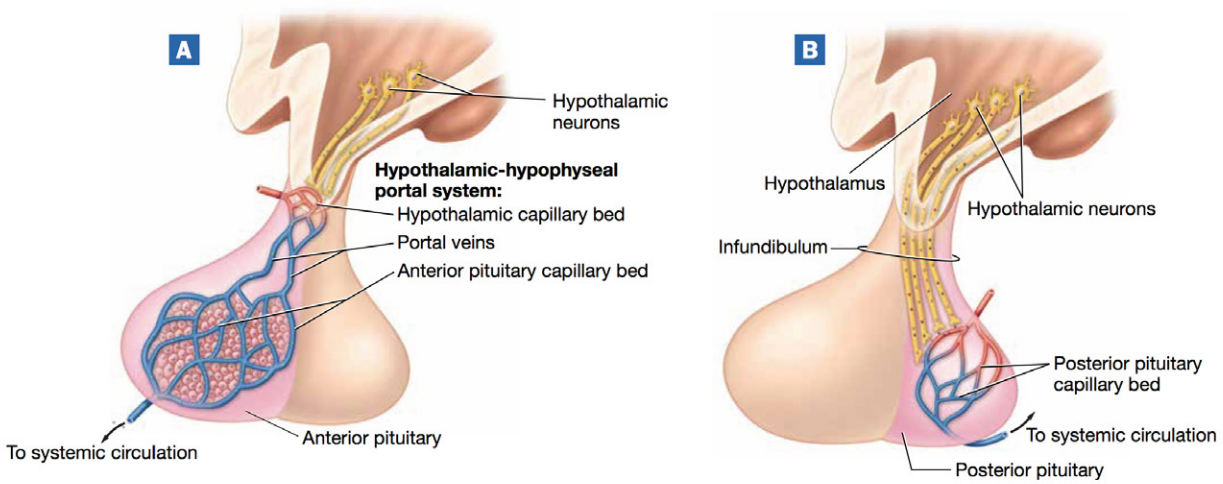

FIGURE **16.3** Hypothalamus and pituitary gland: (**A**) hypothalamus and anterior pituitary; (**B**) hypothalamus and posterior pituitary.

3. **Thyroid gland.** The **thyroid gland** is located in the anterior and inferior neck superficial to the larynx. It consists of right and left lobes connected by a thin band of tissue called the **isthmus.** Microscopically, it is composed of hollow spheres called **thyroid follicles** (Fig. 16.4). The cells that line the thyroid follicles are simple cuboidal cells called **follicle cells,** and they surround a gelatinous, iodine-rich substance called **colloid** (KAWL-oyd). The follicle cells respond to TSH from the anterior pituitary by secreting a chemical into the colloid that reacts with iodine to produce two different hormones: **thyroxine** or **T4,** which has four iodine molecules, and **triiodothyronine** (try-aye-oh-doh-THY-roh-neen) or **T3,** which has three iodine molecules. T3 is the most active of the two hormones and acts on essentially all cells in the body to increase the metabolic rate, increase protein synthesis, and regulate the heart rate and blood pressure, among other things. About 10 times as much T4 is produced as T3, and the body converts T4 to T3 when the T3 level in the blood drops.

Between the follicles we find another cell type called the **parafollicular cells.** These cells produce the hormone **calcitonin** (kal-sih-TOH-nin), a hormone that plays a role in calcium ion homeostasis. Calcitonin is secreted when calcium ion levels in the blood rise, and it triggers osteoblast activity and bone deposition.

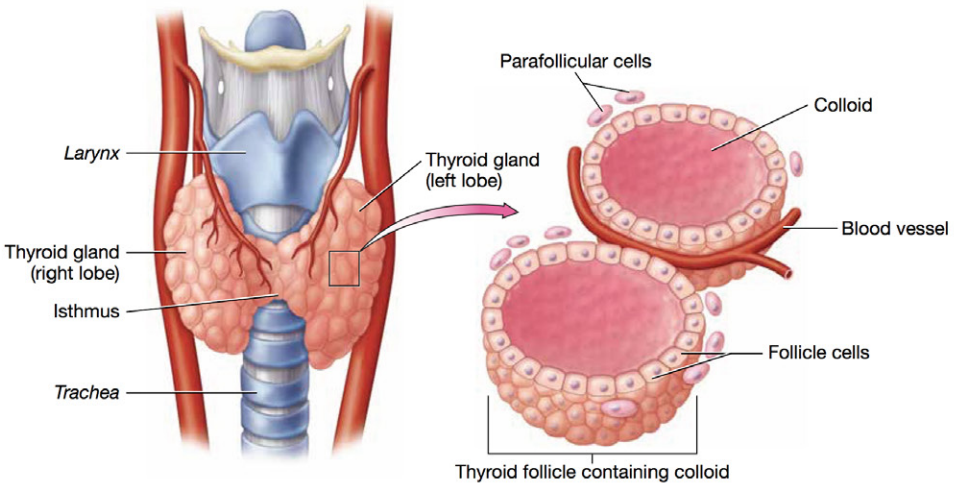

FIGURE **16.4** Thyroid gland and thyroid follicles.

4. **Parathyroid glands.** Refer back to Figure 16.2 where you can see the small **parathyroid glands** on the posterior thyroid gland. They secrete the hormone **parathyroid hormone** (**PTH**), which is the main hormone in the body that maintains calcium ion homeostasis. PTH is secreted in response to a decreased level of calcium ions in the blood. It triggers osteoclast activity and resorption of bone tissue, increased calcium ion absorption from the intestines, and increased calcium ion reabsorption from the kidneys. Hormones such as PTH and calcitonin that have opposite actions are called **antagonists.**

5. **Thymus.** The **thymus** sits in the superior mediastinum. It is large and active in infancy and early childhood, during which time it secretes the hormones **thymosin** and **thymopoietin** (thy-moh-poh-EE-tin). Both of these hormones stimulate the development of T lymphocytes within the thymus. In adults most of the thymic tissue is gradually replaced by fat and other connective tissue.

6. **Adrenal gland.** As the name implies, the **adrenal glands** (uh-DREE-nuhl) sit atop the superior pole of each kidney (*ad-* = next to; *renal* = kidney). Like the pituitary gland, the adrenal gland is actually composed of two separate structures, the adrenal cortex and the adrenal medulla, which are surrounded by a connective tissue capsule (Fig. 16.5).

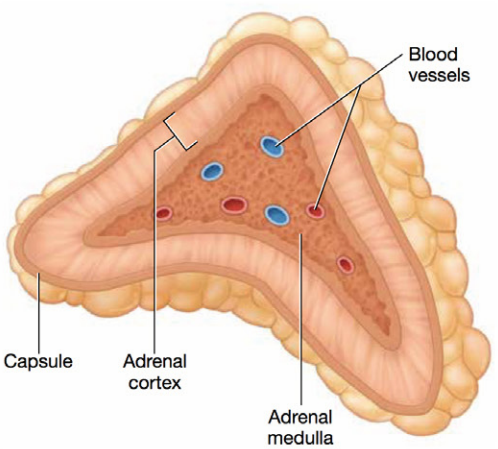

FIGURE **16.5** Adrenal gland.

   a. **Adrenal cortex.** The superficial region of the adrenal gland consists of glandular tissue called the **adrenal cortex,** which secretes **steroid hormones** in response to stimulation by ACTH and other factors. The outermost zone of the adrenal cortex, the **zona glomerulosa** (glom-ehr-yoo-LOH-sah), secretes steroids called **mineralocorticoids** (min-er-al-oh-KORT-ih-koydz). These steroids, such as **aldosterone** (al-DAHS-tur-ohn), regulate fluid, electrolyte, and acid-base homeostasis. The middle zone of the adrenal cortex, the **zona fasciculata** (fah-SIK-yoo-lah-tah), secretes steroids called **glucocorticoids** (gloo-koh-KORT-ih-koydz) such as **cortisol.** Glucocorticoids regulate the stress response, blood glucose, fluid homeostasis, and inflammation. The innermost zone, the **zona reticularis,** secretes glucocorticoids and steroids called **gonadocorticoids** (goh-nad-oh-KORT-ih-koydz) that affect the gonads and other tissues.

   b. **Adrenal medulla.** The deep region of the adrenal gland, called the **adrenal medulla** (meh-DOOL-uh), consists of modified postsynaptic sympathetic neurons that secrete *catecholamines*—**epinephrine** and **norepinephrine**—into the blood in response to sympathetic stimulation. The adrenal catecholamines have the same effects on target cells as the norepinephrine and epinephrine released by sympathetic neurons: dilation of bronchioles; increase in the rate and force of contraction of the heart; constriction of blood vessels serving the skin and abdominal viscera; dilation of the pupil; and more (see Unit 14). Secretion of adrenal catecholamines prolongs the sympathetic response, as the effects of neuronal catecholamines are terminated after only a few seconds. In addition, these hormones are able act on target cells that are not innervated by sympathetic neurons.

7. **Pancreas.** The **pancreas** (PAYN-kree-us) has both endocrine and exocrine functions. Its exocrine functions are carried out by groups of cells called *pancreatic acini*, which release their products into ducts. Embedded within the pancreatic acini are small, round "islands" called **pancreatic islets** (Fig. 16.6) that carry out the pancreas' endocrine functions. The cells within the pancreatic islets secrete the hormones **insulin** and **glucagon** (GLOO-kah-gawn), which play a major role in regulating

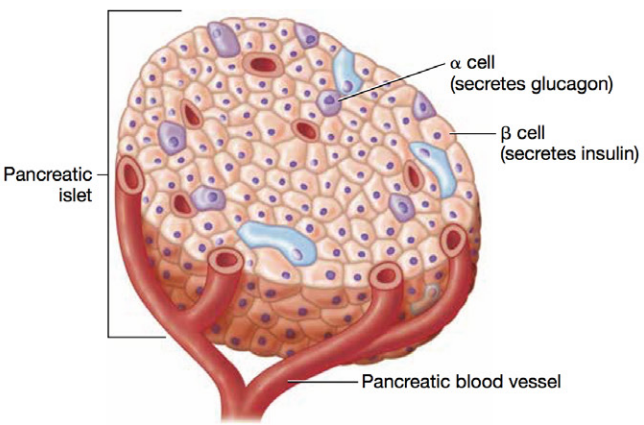

FIGURE **16.6** Pancreatic islet.

blood glucose levels. **Insulin**, which is produced by cells called **beta** (β) **cells**, triggers the uptake of glucose by cells, which decreases the concentration of glucose in the blood. The hormone **glucagon**, which is produced by **alpha** (α) **cells**, is insulin's antagonist—it triggers the release of stored glucose from the liver and the production of new glucose, which increases the concentration of glucose in the blood.

8. **Testes.** The **testes** are the male reproductive organs that produce sperm cells, the male gametes. Cells within the testes called **interstitial cells** produce a steroid hormone called **testosterone**. This hormone promotes the production of sperm cells and the development of male secondary sex characteristics such as a deeper voice, greater bone and muscle mass, and facial hair.
9. **Ovaries.** The **ovaries** are the female reproductive organs that produce ooctyes, the female gametes. The ovaries produce steroid hormones called **estrogens** and **progesterone**. Estrogens play a role in the development of oocytes, female secondary sex characteristics such as breasts and subcutaneous fat stores, and a variety of other processes. Progesterone has a number of effects that prepare the body for pregnancy.

Let's now examine these structures on models and charts. Note that human torso models are typically a good place to start when studying the endocrine system, because most of the organs are easy to find. The one exception is the thymus; many torsos and models choose not to show this structure because it is fairly inactive in adults. Fetal models, however, typically show well-developed thymus glands.

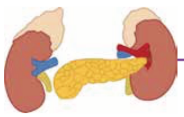

Procedure 1 Model Inventory of the Endocrine System

Identify the following structures of the endocrine system on models and diagrams, using your textbook and this unit for reference. As you examine the anatomical models and diagrams, record the name of the model and the structures you were able to identify on the model inventory in Table 16.2. After you have completed this activity, answer Check Your Understanding questions 1 through 5 (pp. 443–444).

Endocrine Glands

1. Hypothalamus
   a. Infundibulum
2. Pituitary gland
   a. Anterior pituitary
   b. Posterior pituitary
3. Pineal gland
4. Thyroid gland
   a. Right and left lobes
   b. Isthmus
5. Parathyroid glands
6. Thymus gland
7. Adrenal glands
   a. Adrenal cortex
   b. Adrenal medulla
8. Pancreas
   a. Pancreatic islets
9. Testes
10. Ovaries

TABLE **16.2** Model Inventory for the Endocrine System

Model/Diagram	Structures Identified

Exercise 16-2

Endocrine Organ Histology

MATERIALS

- ❑ Thyroid gland slide
- ❑ Adrenal gland slide
- ❑ Pancreas slide
- ❑ Light microscope
- ❑ Colored pencils

In this exercise we examine the histology of three endocrine organs: the thyroid gland, the adrenal gland, and the pancreas. (We examine the ovary and testis in the reproductive system unit.) Following are keys to identification of each tissue:

1. **Thyroid gland.** Thyroid follicles are perhaps one of the easiest structures to identify (Fig. 16.7). Look for a ring of simple cuboidal epithelium surrounding the reddish-brown, acellular colloid. Notice that between the follicles, you can see large parafollicular cells.

2. **Adrenal gland.** The zones of the adrenal cortex each appear differently and so are fairly easy to tell apart on a slide. As you can see in Figure 16.8, the cells in the thin outer zona glomerulosa are arranged in clusters, whereas the cells in the thick middle zona fasciculata are stacked on top of one another and resemble columns. Finally, the cells of the thin inner zona reticularis stain more darkly and are tightly packed. The innermost adrenal medulla is distinguished from the zones of the cortex by its numerous, loosely arranged blood vessels. If you find that you're having a hard time discerning the adrenal medulla from the zona glomerulosa (i.e., you don't know if you're looking at the top or the bottom of the slide), look for the adrenal gland capsule, which you can see in the figure. It is the most superficial layer of the adrenal gland, and so is the "top" of the slide.

   The regions of the adrenal gland are best viewed on low or medium power. Switch to high power to get more detail of the individual cells.

3. **Pancreas.** As you read earlier, there are two main groups of cells in the pancreas: (1) the endocrine pancreatic islets, and (2) the exocrine acinar cells and the cells that line the pancreatic ducts. Most of the pancreas is composed of acinar cells and ductal cells; however, note the small "islands" of tissue in Figure 16.9. These islands are, of course, the insulin- and glucagon-secreting pancreatic islets. Typically, the islets are lighter in color than the surrounding acinar cells. On high power, the differences between the two tissues are easily seen: The acinar cells are slightly cuboidal and are arranged around a duct, whereas the islet cells have no distinctive arrangement (there also may be larger, stain-free spaces between the islet cells).

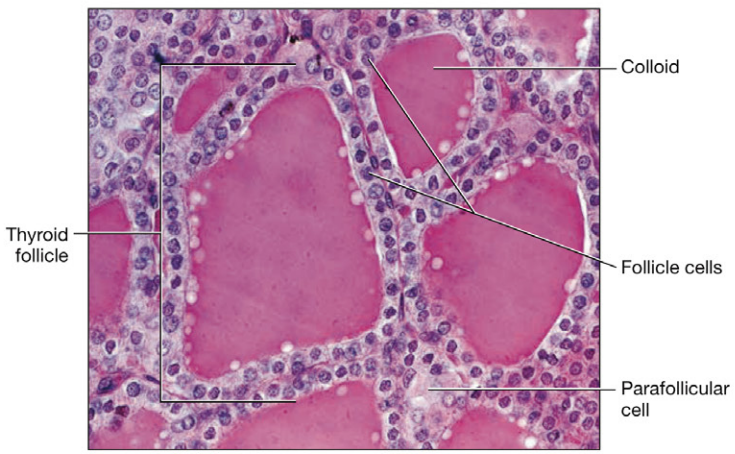

FIGURE **16.7** Thyroid gland, photomicrograph.

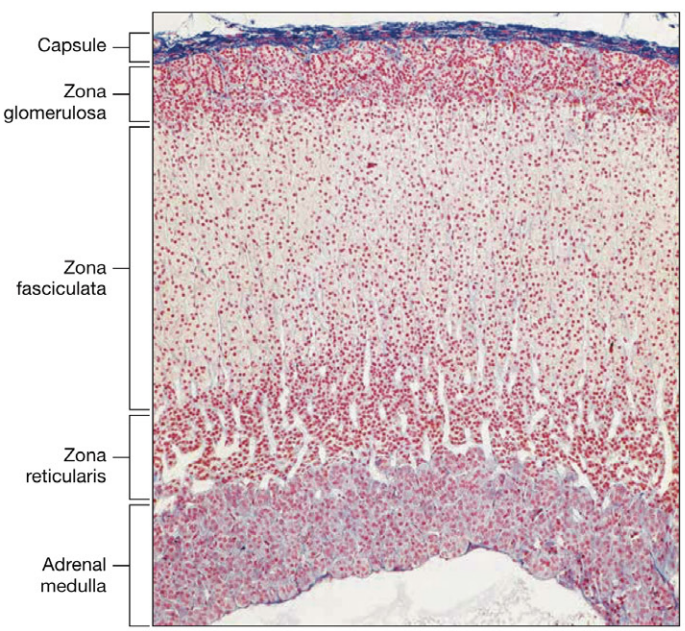

FIGURE **16.8** Zones of the adrenal gland, photomicrograph.

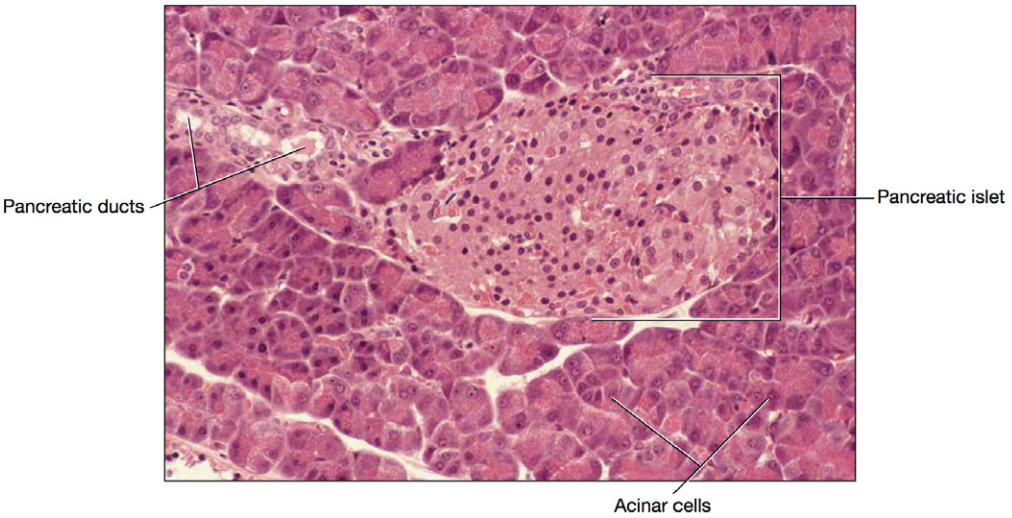

FIGURE **16.9** Pancreas, photomicrograph.

Procedure 1 Microscopy

Obtain prepared slides of the thyroid gland, the adrenal gland, and the pancreas. Place each slide on the stage of the microscope, and scan it on low power. Advance to higher power to see the cells and associated structures in greater detail. Use your colored pencils to draw what you see in the field of view, and label your drawing with the terms as indicated.

1 Thyroid

1. Follicle cells
2. Colloid
3. Parafollicular cells



2 Adrenal gland

1. Zones of the adrenal cortex:
   a. Zona glomerulosa
   b. Zona fasciculata
   c. Zona reticularis
2. Adrenal medulla



3 Pancreas

1. Pancreatic acini (exocrine portion)
2. Pancreatic islets (endocrine portion)



Exercise 16-3

Time to Trace! Negative Feedback Loops

Earlier in this unit we pointed out that each hormone has its own stimulus for secretion. The stimulus for secretion is generally a disturbance in the homeostasis of a particular physiologic variable such as blood pressure, the concentration of glucose in the blood, or body temperature. The hormone's response is to act on distant target cells to cause changes that restore the variable to its normal range. When homeostasis is restored, the activity of the glands and concentration of the hormone declines. This type of response is called a **negative feedback loop**.

In this exercise you will be tracing a hormone's negative feedback loop from the initial homeostatic disturbance, through the hormone's effects on its target cells to restore homeostasis, and finally the decline of the concentration of the hormone in the blood. Following is an example:

Start: the concentration of glucose in the blood falls ➜ the pancreas releases glucagon ➜ the level of the hormone glucagon in the blood rises ➜ the hormone glucagon causes glycogenolysis by the liver ➜ the concentration of glucose in the blood rises ➜ the level of the hormone glucagon in the blood decreases ➜ **End**

Now it's your turn! After you have completed the activity, answer Check Your Understanding question 6 (p. 444).

1 **Start:** the concentration of the blood increases (i.e., there is *inadequate water* in the blood) ➜ the hypothalamus releases the hormone _____ and stores it in the _____ ➜ the stored hormone _____ is released and so its level in the blood rises ➜ the hormone _____ causes _____ ➜ the concentration of the blood _____ ➜ the level of the hormone _____ in the blood _____ ➜ **End**

2 **Start:** the concentration of glucose in the blood increases ➜ the pancreas releases the hormone _____ ➜ the level of the hormone _____ in the blood rises ➜ the hormone _____ causes _____ ➜ blood glucose levels _____ ➜ the level of the hormone _____ in the blood _____ ➜ **End**

3 **Start:** the concentration of calcium ions in the blood decreases ➜ the parathyroid glands release the hormone _____ ➜ the level of the hormone _____ in the blood rises ➜ the hormone _____ causes _____ ➜ the concentration of calcium ions in the blood _____ ➜ the level of the hormone _____ in the blood _____ ➜ **End**

4 **Start:** the concentration of potassium and hydrogen ions in the blood increases ➜ the adrenal cortex releases the hormone _____ ➜ the level of the hormone _____ in the blood rises ➜ the hormone _____ causes _____ ➜ the concentration of potassium and hydrogen ions in the blood _____ ➜ the level of the hormone _____ in the blood _____ ➜ **End**

5 **Start:** the body is exposed to a stressor ➜ the hypothalamus releases *corticotropin-releasing hormone* ➜ CRH stimulates the release of the hormone _____ from the anterior pituitary gland ➜ the hormone _____ stimulates the release of the hormone _____ from the adrenal cortex ➜ the level of the hormone _____ in the blood rises ➜ the hormone _____ causes _____ ➜ the body adapts to the stressor ➜ the level of the hormone _____ in the blood _____ ➜ **End**

Exercise 16-4

Endocrine "Mystery Cases"

In this exercise you will be playing the role of "endocrine detective" to solve endocrine disease mysteries. In each case you will have a victim who has suddenly fallen ill with a mysterious malady. You will be presented a set of "witnesses," each of whom will give you a clue as to the nature of the illness. Other clues will come from samples you send off to the lab for analysis. You will solve the mystery by providing the victim a diagnosis. You may wish to use your textbook for assistance with these cases. When you have completed the cases, answer Check Your Understanding question 7 (p. 444).

Case 1: The Cold Colonel

You are called upon to visit the ailing Col. Lemon. Before you see him, you speak with three witnesses who were with him when he fell ill.

Witness statements:

- *Ms. Magenta*: "Col. Lemon has been hot-blooded for as long as I've known him. But I noticed that he couldn't seem to keep warm. He kept complaining about being cold. . ."
- *Mr. Olive*: "Just between you and me, I've noticed that the old chap has put on quite a bit of weight lately."
- *Professor Purple*: "The colonel and I used to go on major expeditions together. Now he just doesn't seem to have the energy to do much of anything."

What are your initial thoughts about the witnesses' statements? Does one hormone come to mind that may be the cause? Explain.

You see the colonel and collect some blood to send off to the lab. The analysis comes back as follows:

T3 (triiodothyronine): 0.03 ng/dl (normal: 0.2–0.5 ng/dl)

T4 (thyroxine): 1.1 µg/dl (normal: 4–7 µg/dl)

TSH (thyroid-stimulating hormone): 86 mU/l (normal: 0.3–4.0 mU/l)

Analyze the results. Why do you think the T3 and T4 are low and the TSH is elevated?

Based upon the witness statements and the laboratory analysis, what is your final diagnosis? Explain Col. Lemon's symptoms.

Case 2: The Bloated Mrs. Blanc

Your next call is to the home of Mrs. Blanc. As before, you have three witnesses to interview.

Witness statements:

- *Ms. Magenta*: "Between you and me, she's really let herself go. She has fat deposits in all of these strange places, like around her face and trunk, and a weird hump on her back. If you ask me, some exercise may do her some good!"
- *Col. Lemon*: "Not that I want to talk about such things, but she's seemed bloated, a bit swollen, lately. She even told me that her blood pressure has gone up!"
- *Ms. Feather*: "The poor dear. She's been sick so much lately with all kinds of infections. Personally, I think her immune system needs boosting. But my herbal teas don't seem to help."

What are your initial thoughts, based upon the witnesses' statements? Does one hormone come to mind that could produce these effects?

Your next step is to speak with Mrs. Blanc. During the interview you notice a bottle of pills on her nightstand. You log the pills as evidence and send them off to the lab for analysis. The lab report shows the pills to be the medication *prednisone*, which you know to be a glucocorticoid similar to the hormone cortisol. Is this finding significant? Why or why not?

Based upon the witness statements and the laboratory analysis, what is your final diagnosis? Explain your reasoning.

Case 3: The Parched Professor

Your last call is to the aid of Professor Purple. Three witnesses are present from whom to take statements.

Witness statements:

- *Mr. Olive*: "I swear that I saw him drink a full glass of water every half an hour today. He kept saying how thirsty he was!"
- *Mrs. Blanc*: "He must be going to the . . . well, you know, the little boys' room, two or three times every hour!"
- *Ms. Feather*: "He's been saying lately that his mouth is dry and that he feels weak. Personally, I think he's just not following a healthy diet. He should be drinking some of my herbal teas!"

Based upon the witnesses' statements, what are your initial thoughts? Does one hormone come to mind that could produce these effects? Explain.

You interview Professor Purple and collect blood and urine specimens to be sent off to the lab for analysis. The lab reports that the urine osmolality is 150 mOsm/kg, which means the urine is overly dilute (too *much* water in the urine). The blood osmolality is 300 mOsm/kg, meaning the blood is overly concentrated (too *little* water in the blood). The lab also reports that his blood glucose is completely *normal*. What is the significance of these clues?

Based upon the witness statements and the laboratory analysis, what is your final diagnosis? (***Hint:*** Think of the hormone that is supposed to trigger water retention from the kidneys. Is there a disease where this hormone is deficient?) Explain Prof. Purple's symptoms.

Name _____

Section _____ Date _____

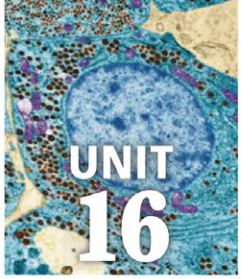

Check Your Recall

REVIEW

1 Label Figure 16.10 with the terms below.

- ❑ Adrenal gland
- ❑ Anterior pituitary
- ❑ Hypothalamus
- ❑ Ovary
- ❑ Pancreas
- ❑ Pancreatic islet
- ❑ Parathyroid glands
- ❑ Posterior pituitary
- ❑ Testis
- ❑ Thyroid gland

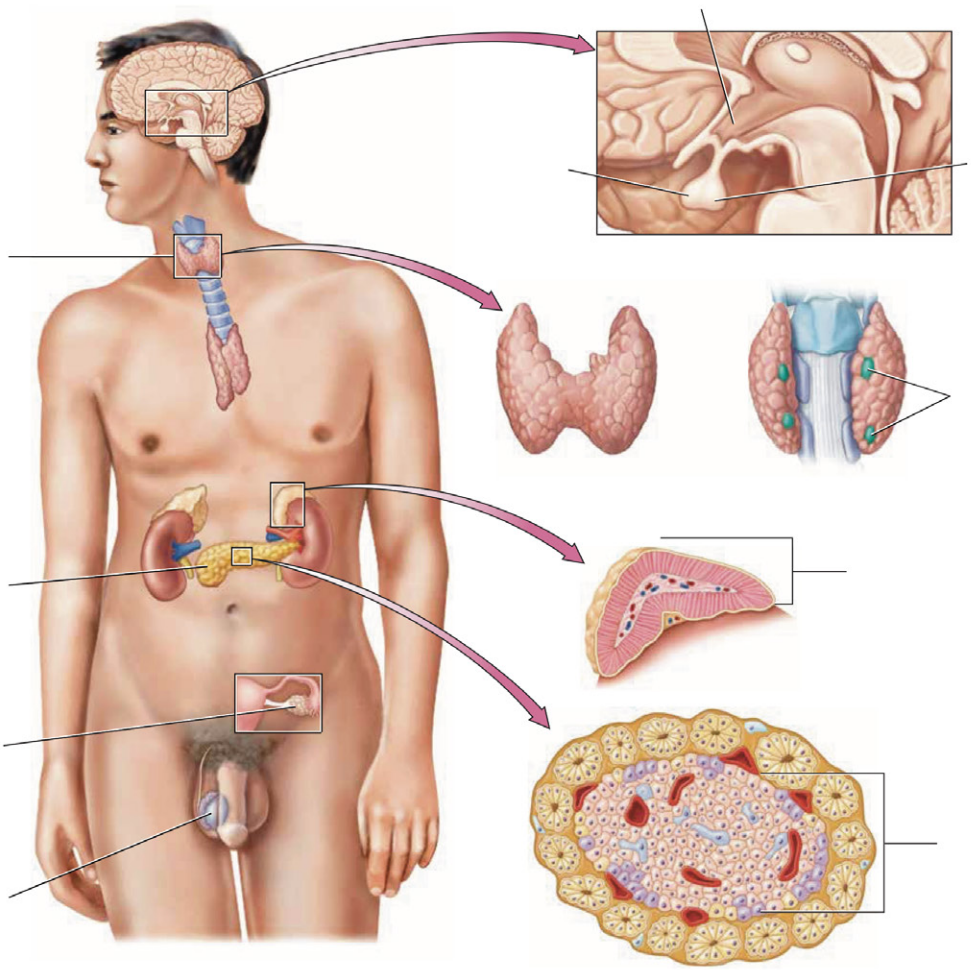

FIGURE **16.10** Endocrine system.

2 A hormone is best described as a

a. chemical released into the extracellular fluid that affects neighboring cells.
b. chemical released by a neuron directly onto a target cell.
c. chemical released into the bloodstream that typically acts on distant targets.
d. All of the above describe hormones.

3 The hypothalamus communicates with the _____ via the hypothalamic-hypophyseal portal system.

a. pineal gland
b. anterior pituitary gland
c. posterior pituitary gland
d. parathyroid gland

4 *True/False:* Mark the following statements as true (T) or false (F). If the statement is false, correct it to make it a true statement.

_____ a. Insulin triggers actions that raise the concentration of glucose in the blood.

_____ b. Interstitial cells within the testes produce testosterone.

_____ c. Aldosterone is the adrenal hormone responsible for the stress response.

_____ d. Parathyroid hormone triggers actions that lower the concentration of calcium ions in the blood.

_____ e. The posterior pituitary produces no hormones of its own.

5 Label Figure 16.11 with the terms below.

16

- ❑ Colloid
- ❑ Follicle cells
- ❑ Thyroid follicle
- ❑ Isthmus
- ❑ Parafollicular cells

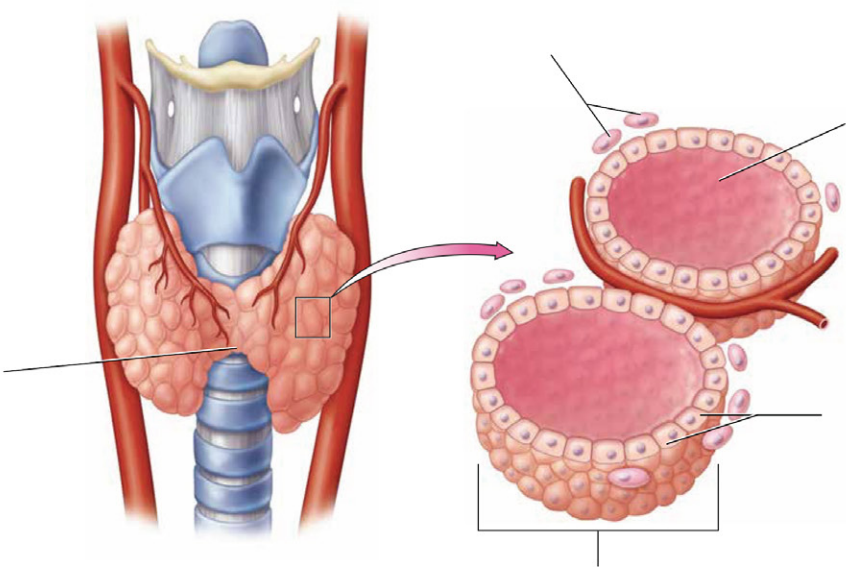

FIGURE **16.11** Thyroid gland.

Name _____

Section _____ Date _____

6 Label Figure 16.12 with the terms below.

- ❑ Zona glomerulosa
- ❑ Adrenal medulla
- ❑ Adrenal capsule
- ❑ Zona reticularis
- ❑ Zona fasciculata
- ❑ Adrenal cortex

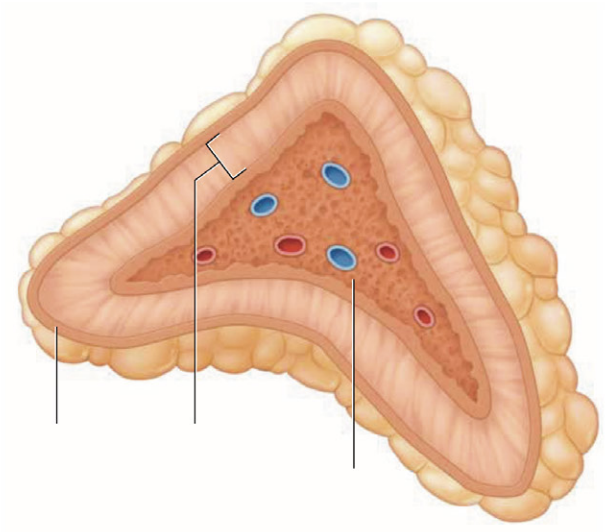

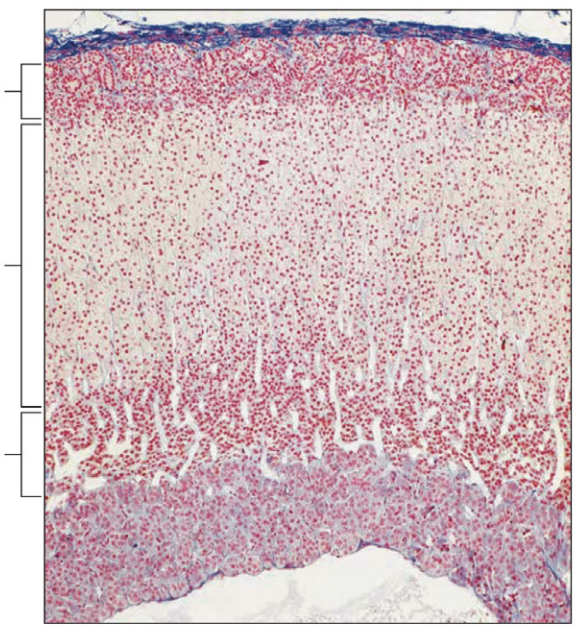

FIGURE **16.12** Adrenal gland.

7 Which of the following sets of hormones are antagonists?

a. Insulin and glucagon.
b. Calcitonin and cortisol.
c. Epinephrine and norepinephrine.
d. Growth hormone and thyroxine.

8 *Matching:* Match the following endocrine organs with the hormone(s) each secretes.

_____ Pineal gland
_____ Thyroid gland
_____ Pancreas
_____ Thymus
_____ Hypothalamus
_____ Adrenal cortex
_____ Anterior pituitary
_____ Adrenal medulla

A. Antidiuretic hormone and oxytocin
B. Insulin and glucagon
C. Aldosterone and cortisol
D. Epinephrine and norepinephrine
E. Thyroxine, triiodothyronine, and calcitonin
F. Thyroid-stimulating hormone, growth hormone
G. Melatonin
H. Thymosin and thymopoietin

9 Which of the following is true regarding endocrine organ histology?

a. The thyroid gland consists of rings of stratified cuboidal follicle cells surrounding colloid.
b. The pancreas has an exocrine portion consisting of pancreatic islets and an endocrine portion consisting of acinar cells.
c. The adrenal cortex has three zones of cells that secrete steroid hormones.
d. The adrenal medulla is modified nervous tissue of the parasympathetic nervous system.

10 In a negative feedback loop, you would expect secretion from an endocrine gland to _____ after homeostasis has been restored.

a. decrease
b. increase
c. remain the same

Name _____

Section _____ Date _____

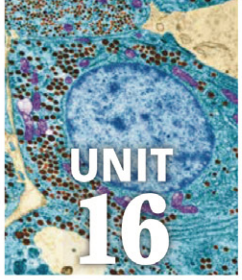

REVIEW

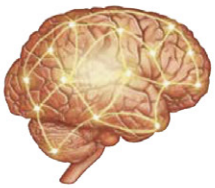

Check Your Understanding

Critical Thinking and Application Questions

1 How does the way in which the hypothalamus communicates with the anterior and posterior pituitary glands differ? How does this reflect the functional differences of the anterior and posterior pituitary glands?

2 Tumors of the parathyroid gland often result in secretion of excess parathyroid hormone. Considering the function of this hormone, predict the effects of such a tumor. How would the effects change if the tumor secreted calcitonin instead?

3 A *pheochromocytoma* (fee-uh-kroh-muh-sy-TOH-muh) is a tumor of the adrenal medulla that secretes epinephrine and norepinephrine. Predict the symptoms that you might see from this condition.

4 The disease *diabetes mellitus* is due to either destruction of the cells that produce insulin or a decrease in sensitivity of target cells to circulating insulin. How would this affect the level of glucose in the blood? Why?

5 A type of tumor in the pancreas called a *glucagonoma* produces and releases excess glucagon into the blood. How would this affect the level of glucose in the blood? Would the overall effect on blood glucose differ from that of type I diabetes mellitus? Why or why not?

6 In the condition hyperthyroidism, patients have elevated levels of both T3 and T4 due to a malfunction of the immune system that causes the thyroid gland to overproduce thyroid hormones. Do you think the negative feedback loops would lead to high levels of TSH or low levels of TSH? Explain.

7 In case 3 of Exercise 16-4 (p. 437), we saw that Professor Purple had insufficient antidiuretic hormone (ADH). However, the opposite condition can also occur in which excess ADH is present, called *syndrome of inappropriate ADH secretion*. Predict the symptoms of this condition.

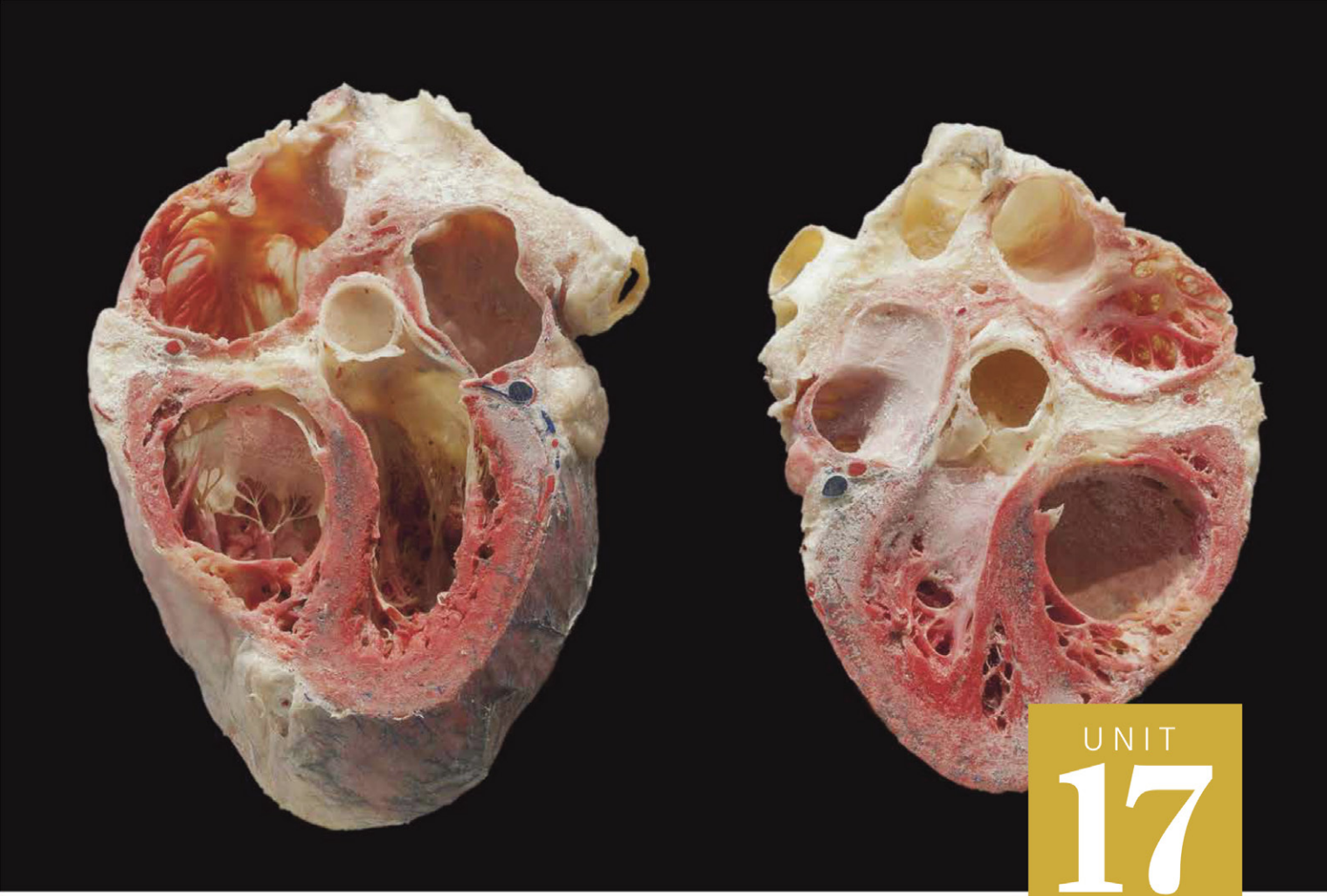

UNIT
17

Cardiovascular System—Part I: The Heart

Once you have completed this unit, you should be able to:

1. Identify structures of the heart.
2. Trace the pathway of blood flow through the heart and lungs.
3. Describe the histology of cardiac muscle tissue.

Name _____ Section _____ Date _____

PRE-LAB EXERCISES

Complete the following exercises prior to coming to lab, using this lab manual and your textbook for reference.

Pre-Lab Exercise 17-1



Key Terms

You should be familiar with the following terms before coming to lab.

Term	Definition

Layers of the Heart Wall

Fibrous pericardium _____

Serous parietal pericardium _____

Serous visceral pericardium _____

Pericardial cavity _____

Myocardium _____

Endocardium _____

Structures of the Heart

Atria (right and left) _____

Ventricles (right and left) _____

Tricuspid valve _____

Mitral (bicuspid) valve _____

Pulmonary valve _____

Aortic valve _____

Name _____ Section _____ Date _____

Chordae tendineae _____

Papillary muscles _____

Great Vessels

Superior vena cava _____

Inferior vena cava _____

Pulmonary trunk _____

Pulmonary veins _____

Aorta _____

Pre-Lab Exercise 17-2

Anatomy of the Thoracic Cavity

Label and color the structures of the thoracic cavity in Figure 17.1 with the terms from Exercise 17-1 (p. 451). Use your text and Exercise 17-1 in this unit for reference.

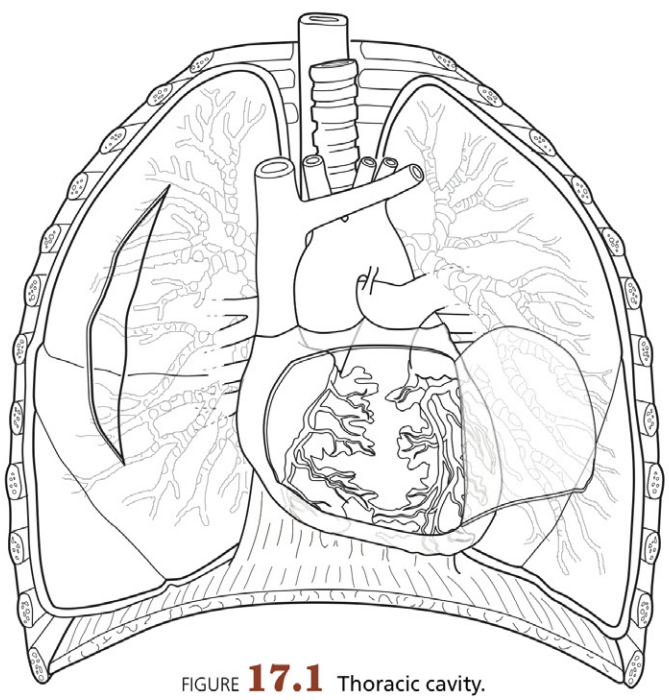

FIGURE 17.1 Thoracic cavity.

Pre-Lab Exercise 17-3

Anatomy of the Heart

Label and color the three views of the heart in Figure 17.2 with the terms from Exercise 17-1 (p. 451). Use your text and Exercise 17-1 in this unit for reference.

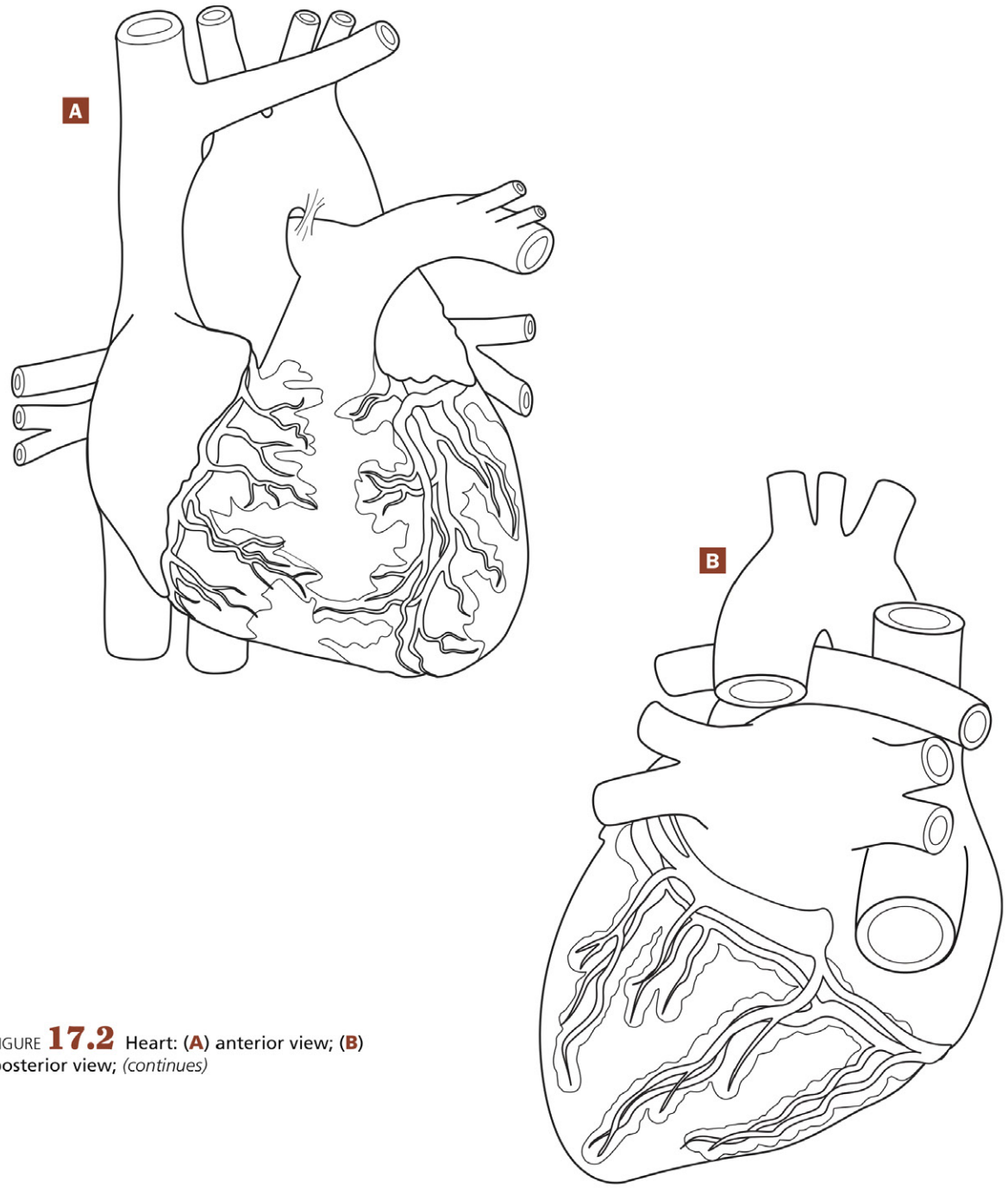

FIGURE **17.2** Heart: (**A**) anterior view; (**B**) posterior view; *(continues)*

Name _____ Section _____ Date _____

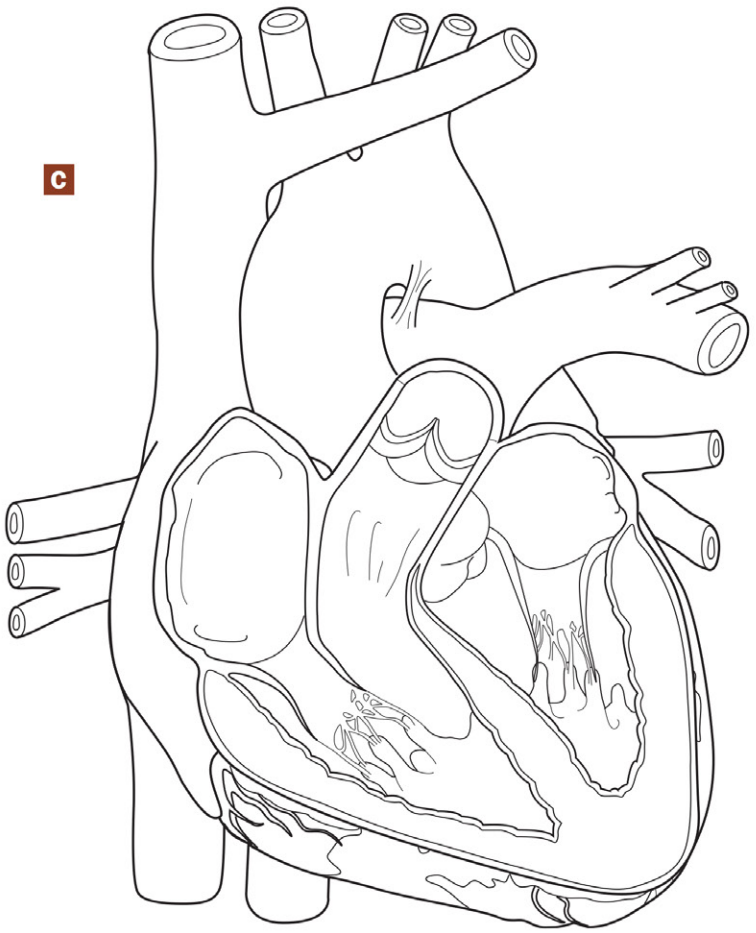

FIGURE **17.2** Heart *(cont.)*: (C) frontal section.

Pre-Lab Exercise 17-4

Pathway of Blood Flow through the Heart

Answer the following questions about the pathway of blood flow through the heart. Use your textbook and Exercise 17-1 (p. 451) in this unit for reference.

1. Regarding veins:
   a. Where do veins carry blood? _____
   b. Is this blood generally oxygenated or deoxygenated? _____
   c. Does this rule have any exceptions? If yes, where? _____
2. Regarding arteries:
   a. Where do arteries carry blood? _____
   b. Is this blood generally oxygenated or deoxygenated? _____
   c. Does this rule have any exceptions? If yes, where? _____
3. Where does each atrium pump blood when it contracts?
   a. Right atrium: _____
   b. Left atrium: _____
4. Where does each ventricle pump blood when it contracts?
   a. Right ventricle: _____
   b. Left ventricle: _____

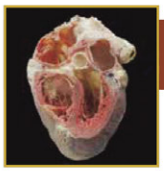

Plastinated and sectioned human heart.

EXERCISES

The **cardiovascular system** transports oxygen, nutrients, wastes, other solutes, and cells throughout the body. In this unit we begin our exploration of the cardiovascular system with the pump that drives it—the heart. The heart is a remarkable organ, tirelessly beating more than 100,000 times per day to pump more than 8,000 liters of blood around the body. In this unit we examine the anatomy of this remarkable organ, including the blood flow through the heart and the histology of cardiac muscle.

Exercise 17-1

Anatomy of the Heart

MATERIALS

- ❑ Heart models
- ❑ Preserved heart
- ❑ Dissection equipment
- ❑ Dissection tray
- ❑ Water-soluble marking pens or colored pencils
- ❑ Laminated outline of the heart and lungs
- ❑ Colored pencils

The heart is located in the *mediastinum* and is on average about the size of a fist (Fig. 17.3A). Its **apex** is its pointy inferior tip, and its **base** is its flattened posterior side (Fig. 17.3B). The heart is composed of four chambers—the small, superior *right* and *left atria* and the larger, inferior *right* and *left ventricles*. The chambers are separated visually by grooves on the heart's surface: The **atrioventricular sulcus** (ay-tree-oh-ven-TRIK-yoo-lur) is between the atria and ventricles, and the **interventricular sulcus** is between the two ventricles.

As you can see in Figure 17.4, the heart is surrounded by a double-layered membrane called the **pericardium** (pehr-ee-KAR-dee-um). The outermost layer of the pericardium, called the **fibrous pericardium**, anchors the heart to surrounding structures. It is made of dense irregular collagenous connective tissue that is not very distensible, which helps to prevent the heart from overfilling. The inner layer, called the **serous pericardium**, is itself composed of two layers. The outer portion, called the **parietal pericardium**, is functionally fused to the fibrous pericardium. Notice that at the edges of the heart, the parietal pericardium folds over on itself to attach to the heart muscle and form the inner layer of the serous membrane called the **visceral pericardium**, also known as the *epicardium*. Between the parietal and visceral layers we find a thin layer of serous fluid that occupies a narrow potential space called the **pericardial cavity**. The fluid within the pericardial cavity helps the heart to beat without friction.

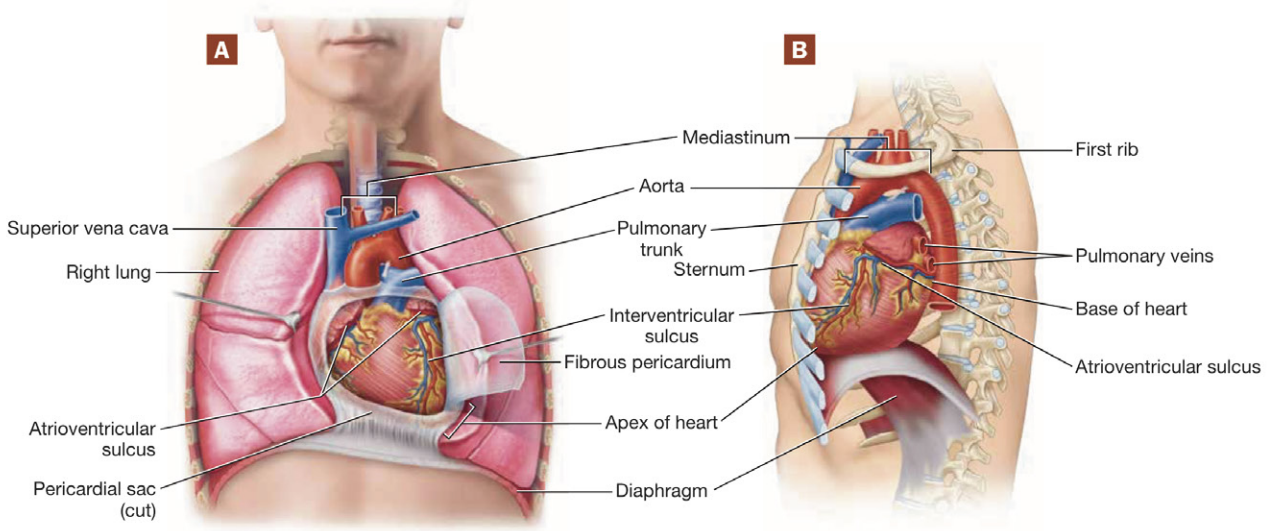

FIGURE **17.3** Thoracic cavity: (**A**) anterior view; (**B**) left lateral view.

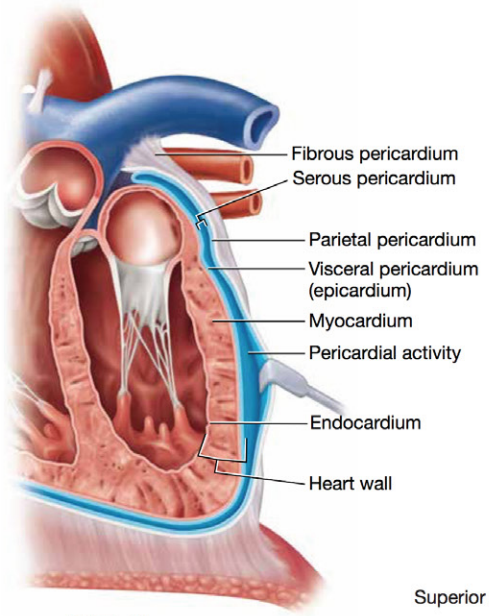

FIGURE **17.4** Layers of the heart wall.

The heart itself is an organ that consists of three tissue layers:

1. **Epicardium.** The **epicardium** (ep-ih-KAR-dee-um) or visceral pericardium is considered the outermost layer of the heart wall. It consists of a layer of simple squamous epithelial tissue and loose connective tissue.
2. **Myocardium.** The middle **myocardium** (my-oh-KAR-dee-um) is the actual muscle of the heart. It consists of cardiac muscle tissue and its fibrous skeleton.
3. **Endocardium.** The innermost **endocardium** is a type of simple squamous epithelium called *endothelium*. It is continuous with the endothelium lining all blood vessels in the body.

Let's look now at the external anatomy of the heart, shown in Figure 17.5. As you can see in the figure, the atria receive blood from

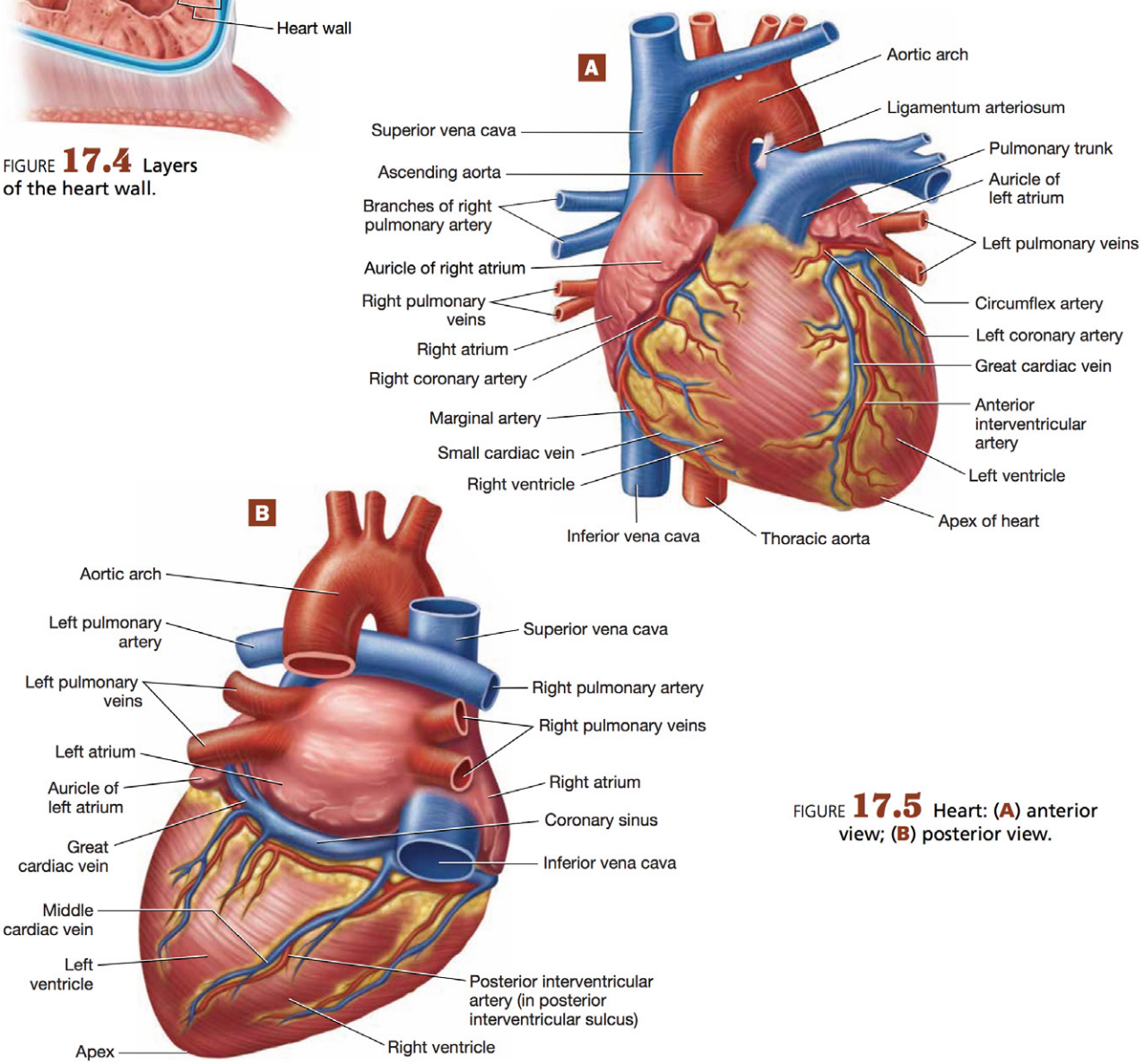

FIGURE **17.5** Heart: (**A**) anterior view; (**B**) posterior view.

veins, which are vessels bringing blood to the heart. The ventricles eject blood into *arteries*, which carry blood away from the heart. The vessels entering and exiting the heart are the largest in the body and so are called **great vessels.** There are four sets of great vessels including the following:

1. **Superior and inferior venae cavae.** The **superior vena cava** (VEE-nah KAY-vah) is a large vein that drains deoxygenated blood from structures located, in general, above the diaphragm, while the **inferior vena cava** drains structures located, in general, below the diaphragm. Both empty into the right atrium. These veins drain a group of blood vessels collectively called the **systemic circuit**, in which oxygen and nutrients are delivered to cells by *systemic arteries* and deoxygenated blood is returned to the heart by *systemic veins*.
2. **Pulmonary trunk.** The **pulmonary trunk** is a large artery that exits from the right ventricle. Shortly after it forms, it splits into **right** and **left pulmonary arteries**, which deliver deoxygenated blood to the lungs through a series of vessels collectively called the **pulmonary circuit**. Within the pulmonary circuit, gases are exchanged, and the blood becomes oxygenated.
3. **Pulmonary veins.** The **pulmonary veins** are the portion of the pulmonary circuit that brings oxygenated blood back to the heart. There are generally four pulmonary veins, and they empty into the left atrium.
4. **Aorta.** The large **aorta** (ay-OHR-tah) is the first and largest artery of the systemic circuit. It stems from the left ventricle, after which it branches repeatedly to deliver oxygenated blood to the body's cells.

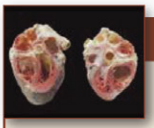

HINTS & TIPS

Red or Blue?

On anatomical models, vessels that carry oxygenated blood are red, whereas those that carry deoxygenated blood are blue. Systemic arteries carry oxygenated blood to the body's cells and so are red on anatomical models. Systemic veins, on the other hand, carry deoxygenated blood back to the right atrium and so are blue. But be sure to remember that the reverse is true in the pulmonary circuit: The pulmonary arteries carry deoxygenated blood to the lungs and the pulmonary veins carry oxygenated blood to the heart. So, in the pulmonary circuit, the arteries are blue and the veins are red. (Do be aware, though, that sometimes on anatomical models the pulmonary trunk and arteries are painted more of a purple color to differentiate them from systemic veins.)

The other set of blood vessels visible on the external surface of the heart are the vessels collectively called the **coronary circulation** (KOHR-oh-nehr-ee). The **coronary arteries** branch off the base of the aorta and bring oxygenated blood to the cells of the myocardium. The myocardium is drained by a set of **cardiac veins**. The first coronary artery, the **right coronary artery**, travels along the right side of the atrioventricular sulcus. It branches into the **right marginal artery**, which serves the lateral part of the right atrium and right ventricle, and the **posterior interventricular artery**, which serves the posterior heart.

The other coronary artery is the **left coronary artery**, which branches shortly after it forms into the **anterior interventricular artery** (also known as the **left anterior descending artery**), which travels along the interventricular sulcus to supply the anterior heart. Its second branch is the **circumflex artery** (SIR-kum-flex), which travels in the left side of the atrioventricular sulcus to supply the left atrium and posterior left ventricle. When a coronary artery is blocked, the reduced blood flow to the myocardium causes a situation known as *myocardial ischemia*. Severe blockage may result in hypoxic injury and death to the tissue, a condition termed **myocardial infarction** (commonly called a heart attack).

The anatomy of the cardiac veins often varies from person to person, but the following three main veins generally are present: (1) the **small cardiac vein**, which drains the right inferolateral heart; (2) the **middle cardiac vein**, which drains the posterior heart; and (3) the **great cardiac vein**, which drains most of the left side of the heart. All three veins drain into the large **coronary sinus** located on the posterior right atrium. The coronary sinus drains into the right atrium.

On a dissection of the heart, as shown in Figure 17.6, we can see that the atria and ventricles are divided by muscular walls called *septa*. In between the atria is a thin wall called the **interatrial septum** (in-ter-AY-tree-uhl). This wall has a small dent in it called the **fossa ovalis** (FAWS-ah oh-VAL-is), which is a remnant of a hole, called the *foramen ovale*, that was present during fetal life. The much thicker **interventricular septum** separates the two ventricles.

Let's look now more closely at the heart's four chambers.

1. **Right atrium.** The **right atrium** (AY-tree-um) is the superior right chamber. It receives deoxygenated blood from the body's main veins—the superior vena cava, the inferior vena cava, and the coronary sinus—the openings for which we find on the right atrium's posterior side. Externally, it has a large pouch called the **right auricle** (OHR-ih-kuhl) that allows the right atrium to expand and fill with more blood. Internally, the anterior surface of the right atrium is rough due to muscular ridges called **pectinate muscles** (PEK-tin-et).

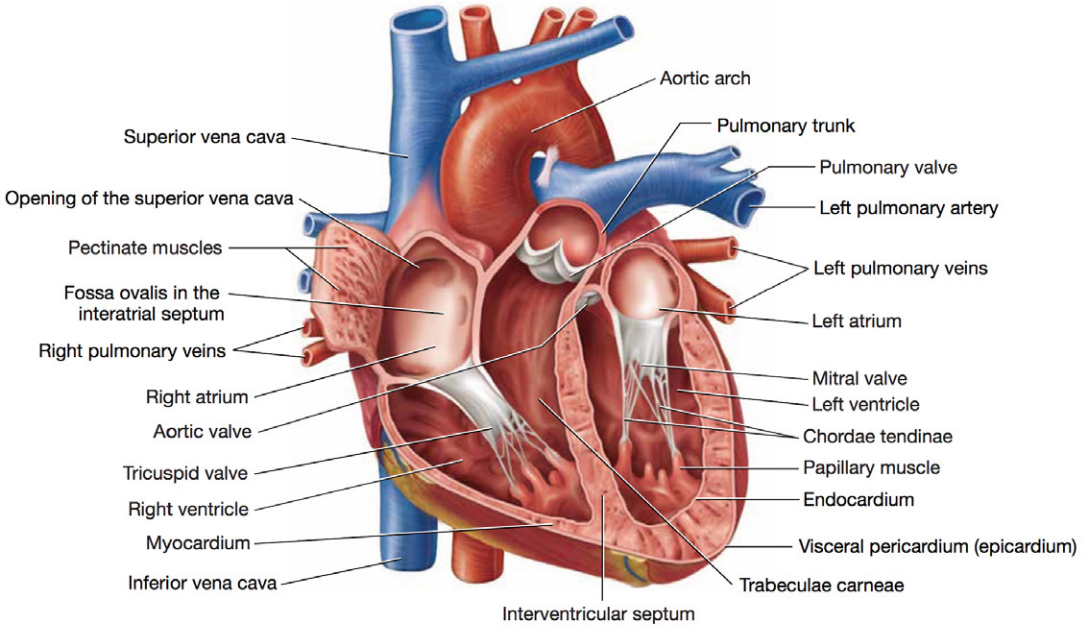

FIGURE **17.6** Frontal dissection of the heart.

2. **Right ventricle.** The **right ventricle** is a wide, crescent-shaped, thin-walled chamber inferior to the right atrium, from which it receives deoxygenated blood. It ejects blood into a vessel called the **pulmonary trunk.** Internally, its surface contains ridge-like protrusions of cardiac muscle called **trabeculae carneae** (trah-BEK-yoo-lee kar-NEE-ee).
3. **Left atrium.** The superior left chamber is the **left atrium.** It receives oxygenated blood returning from the pulmonary circuit via four **pulmonary veins.** Externally, it has a **left auricle,** although it is much smaller than the right auricle. Internally, its surface is mostly smooth and it lacks pectinate muscles.
4. **Left ventricle.** The **left ventricle** is a thick, long, circular chamber that receives oxygenated blood from the left atrium and pumps it into the **aorta.** Notice in the figure that the left ventricle is considerably thicker than the right ventricle. This reflects the fact that the pressure is much higher in the systemic circuit than it is in the pulmonary circuit. The higher pressure requires the left ventricle to pump harder, and so it has greater muscle mass and is thicker. Like the right ventricle, trabeculae carneae line the left ventricle's internal surface.

To ensure that blood in the heart flows only in a single direction, we have structures called **valves** (Figs. 17.6 and 17.7). There are two types of valves in the heart. First are the valves between the atria and ventricles, which are called **atrioventricular**

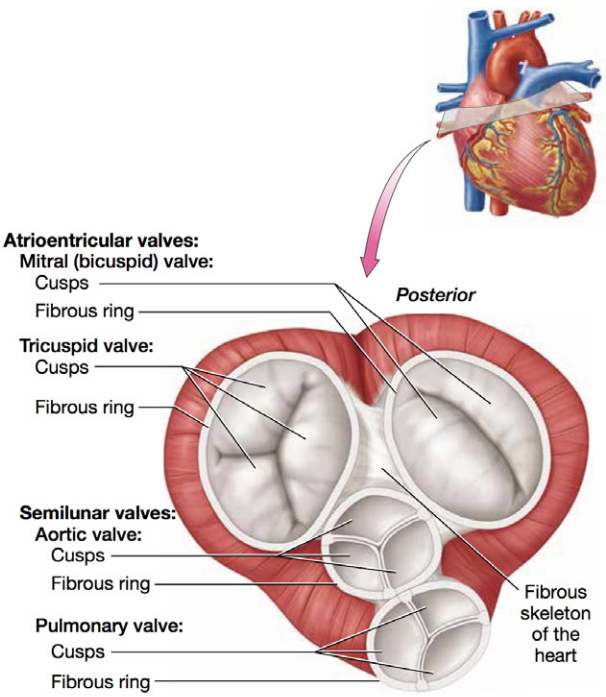

FIGURE **17.7** Transverse section of the heart showing all four valves.

valves. The three-cusped **tricuspid valve** is between the right atrium and right ventricle, and the two-cusped **mitral** (MY-trul) or **bicuspid valve** is between the left atrium and left ventricle. Each cusp of the atrioventricular valves is attached to collagenous "strings" called **chordae tendineae** (KOHR-dee tin-din-EE-ee), which are themselves attached to muscles within the ventricular wall called **papillary muscles.** When the ventricles contract, the papillary muscles pull the chordae tendineae taut, which puts tension on the cusps and prevents them from everting into the atria, a condition called *prolapse*.

Second are the valves between the ventricles and their arteries, which are called **semilunar valves**. The **pulmonary valve** sits between the right ventricle and the pulmonary trunk, and the **aortic valve** sits between the left ventricle and the aorta. Note that there are no chordae tendineae or papillary muscles attached to the semilunar valves.

Procedure 1 Model Inventory for the Heart

Identify the following structures of the heart on models and diagrams, using your textbook and this unit for reference. As you examine the anatomical models and diagrams, record the name of the model and the structures you were able to identify on the model inventory in Table 17.1. When you have completed the activity, answer Check Your Understanding questions 1 through 3 (pp. 467–468).

1. General structures
   a. Mediastinum
   b. Apex of the heart
   c. Base of the heart
   d. Atrioventricular sulcus
   e. Interventricular sulcus
   f. Pericardium
      (1) Fibrous pericardium
      (2) Serous pericardium
         (a) Parietal pericardium
         (b) Visceral pericardium (epicardium)
         (c) Pericardial cavity
   g. Myocardium
   h. Endocardium
2. Great vessels
   a. Superior vena cava
   b. Inferior vena cava
   c. Pulmonary trunk
   d. Right and left pulmonary arteries
   e. Pulmonary veins
   f. Aorta
3. Coronary arteries
   a. Right coronary artery
   b. Right marginal artery
   c. Posterior interventricular artery
   d. Left coronary artery
   e. Anterior interventricular artery
   f. Circumflex artery
4. Cardiac veins
   a. Small cardiac vein
   b. Middle cardiac vein
   c. Great cardiac vein
   d. Coronary sinus
5. Interatrial septum
   a. Fossa ovalis
6. Interventricular septum
7. Right atrium
   a. Opening of the superior vena cava
   b. Opening of the inferior vena cava
   c. Opening of the coronary sinus
   d. Right auricle
   e. Pectinate muscles
8. Right ventricle
   a. Trabeculae carneae
9. Left atrium
   a. Left auricle
   b. Openings of the pulmonary veins
10. Left ventricle
    a. Trabeculae carneae
11. Atrioventricular valves
    a. Tricuspid valve
    b. Mitral valve
    c. Chordae tendineae
    d. Papillary muscles
12. Semilunar valves
    a. Pulmonary valve
    b. Aortic valve

TABLE **17.1** Model Inventory for the Heart

Model/Diagram	Structures Identified

Procedure 2 Time to Draw

In the space below, draw, color, and label one of the heart models that you examined. Draw both the anterior view and the frontal dissection. In addition, write the function of each structure that you label.

Procedure 3 Heart Dissection

You will now examine a preserved heart or a fresh heart, likely from a sheep or a cow. Follow the procedure below to find the structures you just studied on models. When you have completed the dissection, answer Check Your Understanding question 4 (p. 468).

Safety Note

Safety glasses and gloves are required!

1 Orient yourself by first determining the superior aspect and the inferior aspect of the heart. The superior aspect of the heart is the broad end, and the inferior aspect (apex) is the pointy tip. Now orient yourself to the anterior and posterior sides. The easiest way to do this is to locate the pulmonary trunk—the vessel directly in the middle of the anterior side. Find the side from which the pulmonary trunk originates, and you will be on the anterior side, which you can see in Figure 17.8. Structures to locate at this time are the following:

a. Parietal pericardium (may not be attached).
b. Visceral pericardium (shiny layer over the surface of the heart).
c. Aorta.
d. Pulmonary trunk.
e. Superior vena cava.
f. Inferior vena cava.
g. Pulmonary veins.
h. Ventricles.
i. Atria.

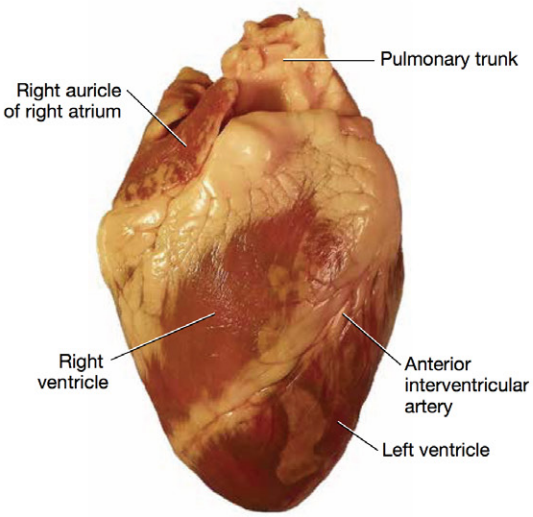

FIGURE **17.8** Anterior view of a sheep heart.

Finding the coronary vessels tends to be difficult because the superficial surface of the heart is covered with adipose tissue. To see the coronary vessels, carefully dissect the adipose tissue.

2 Locate the superior vena cava. Insert scissors or a scalpel into the superior vena cava and cut down into the right atrium. Before moving on to step 3, note the structure of the tricuspid valve, and draw it in the space provided. How many flaps do you see? What is the function of this valve?

3 Once the right atrium is exposed, continue the cut down into the right ventricle, which is shown in Figure 17.9. Structures to locate at this time include the following:

a. Tricuspid valve.
b. Chordae tendineae.
c. Papillary muscles.
d. Myocardium.
e. Endocardium (shiny layer on the inside of the heart).

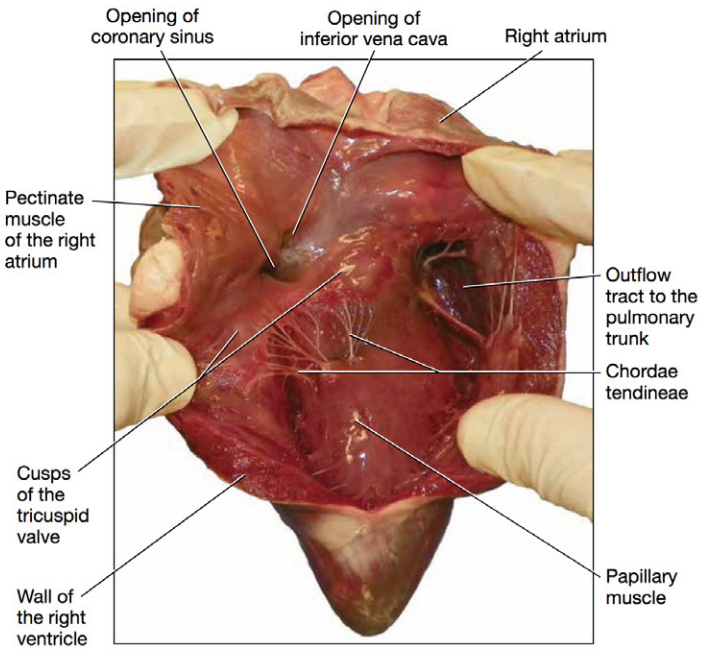

FIGURE **17.9** Right ventricle of a sheep heart.

4 Insert the scissors into the pulmonary trunk. Note the structure of the pulmonary valve, and draw it in the space provided. How does it differ structurally from the tricuspid valve? What is the function of this valve?

5 Insert the scissors into a pulmonary vein. Cut down into the left atrium. Note the structure of the mitral valve, and draw it in the space provided. What is the function of this valve? How does its structure differ from that of the pulmonary and tricuspid valves?

6 Continue the cut into the left ventricle. Note the thickness of the left ventricle, as shown in Figure 17.10. How does it compare with the thickness of the right ventricle? Why is there a difference?

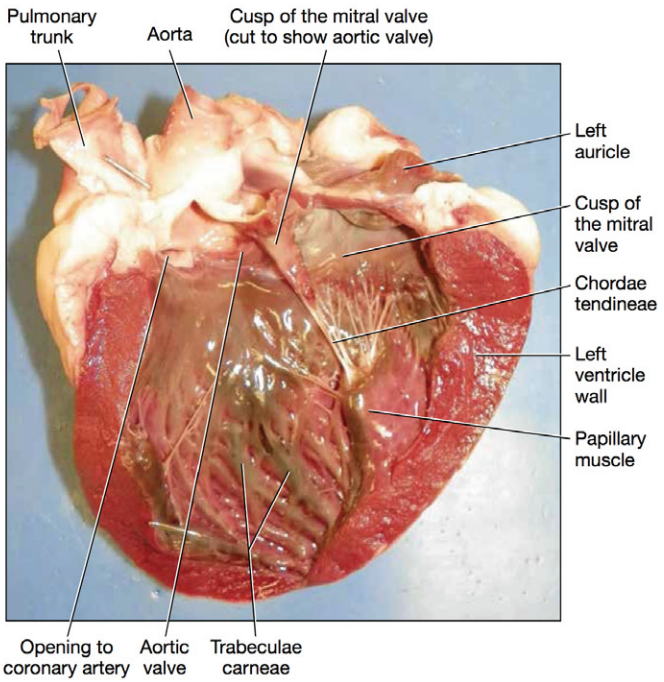

FIGURE **17.10** Left ventricle of a sheep heart.

7 Insert the scissors into the aorta. Extend the cut until you can see the aortic valve. Draw the aortic valve in the space provided. Is it structurally more similar to the pulmonary valve or the mitral valve? What is the function of this valve?

8 Your instructor may wish you to identify other structures on the heart. List any additional structures in the space provided.

Procedure 4 Tracing Blood through the Heart

Now that you've learned the parts of the heart, put the pieces together and trace the pattern of blood as it flows through the heart and lungs. First, write out the entire pathway, beginning with the main systemic veins that drain into the heart and ending with the main systemic artery into which the heart pumps. Don't forget to include the valves in your tracing. Then, use water-soluble markers and a laminated outline of the heart to draw the pathway of blood as it flows through the heart and pulmonary circulation. Use a blue marker to indicate areas that contain deoxygenated blood and a red marker to indicate areas that contain oxygenated blood. If no laminated outline is available, use Figure 17.11. When you have completed the activity, answer Check Your Understanding question 5 (p. 468).

Start: Inferior/Superior venae cavae →

17

→ **End:** Aorta

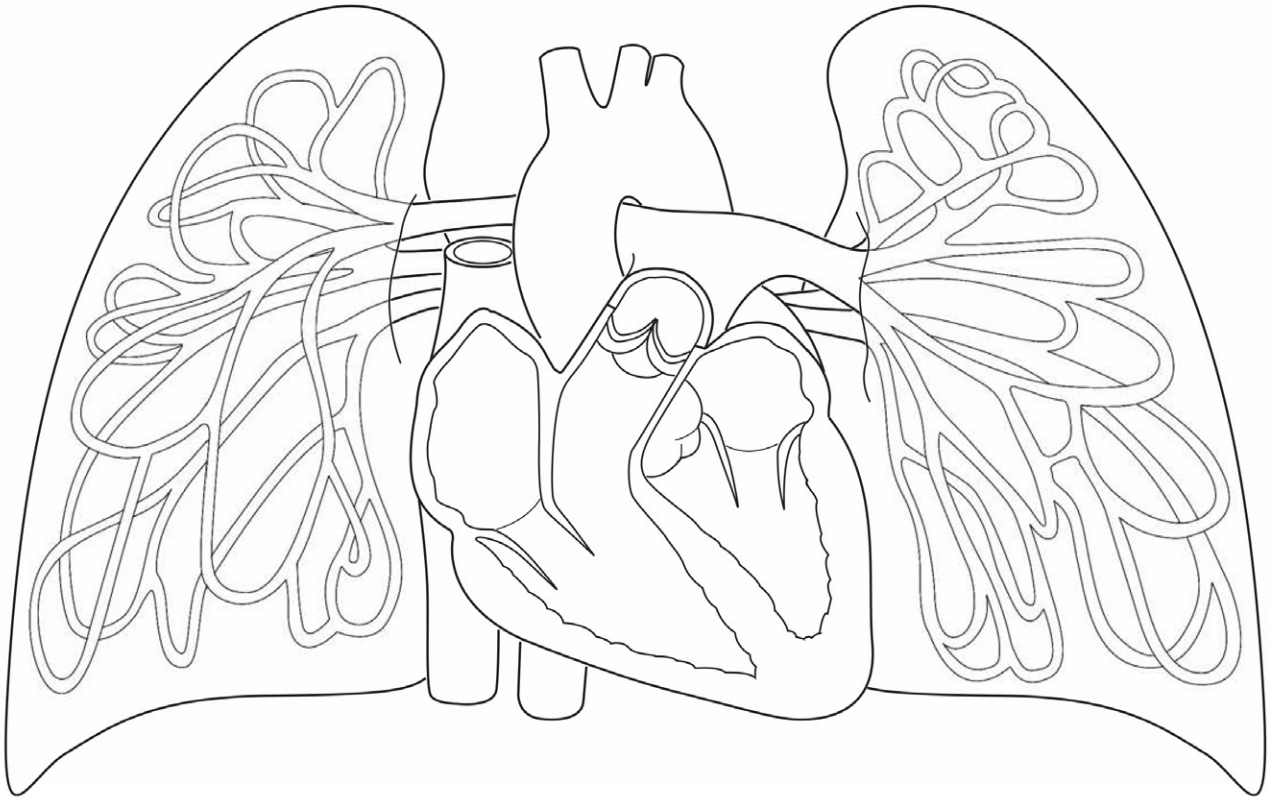

FIGURE **17.11** Heart, lungs, and pulmonary circulation.

Exercise 17-2

Cardiac Muscle Histology

MATERIALS

- ❑ Cardiac muscle tissue slide
- ❑ Light microscope
- ❑ Colored pencils

Recall from Unit 5 (p. 121) that cardiac muscle tissue is striated like skeletal muscle tissue but otherwise is quite different (Fig. 17.12). Following are some important structural differences:

- Cells of cardiac muscle, known as **cardiac myocytes**, are shorter, wider, and branched, whereas skeletal muscle fibers are long, thin, and unbranched.
- Cardiac muscle cells typically are uninucleate, although some have multiple nuclei. The nucleus is generally located near the center of the cell.
- These cells contain specialized adaptations called **intercalated discs** (in-TUR-kuh-layt-ed) that appear as dark lines parallel to the striations. These discs contain desmosomes and gap junctions that hold adjacent cardiac cells tightly together to allow the cells to communicate chemically and electrically. This adaptation is important to the heart's function: For a heart contraction to occur, all of the cells of the atria must contract simultaneously as a unit, and then all of the cells of the ventricles must contract simultaneously as a unit. Contrast this with skeletal muscles, in which the number of muscle fibers that contract is proportional to the strength of the contraction.

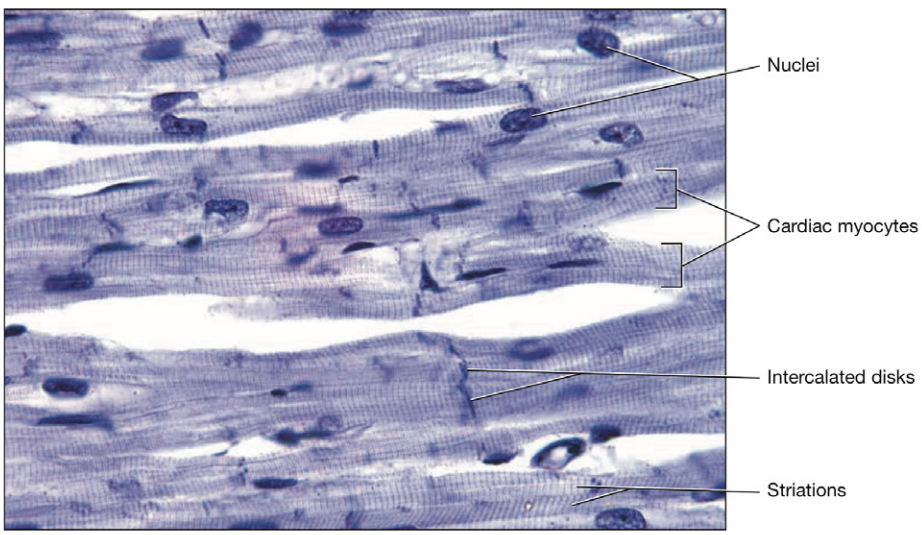

FIGURE **17.12** Cardiac muscle tissue, photomicrograph.

Procedure 1 Microscopy of Cardiac Muscle Tissue

Examine a prepared slide of cardiac muscle tissue on high power. Use colored pencils to draw what you see and label the listed structures. When you have completed the activity, answer Check Your Understanding question 6 (p. 468).

1. Cardiac myocyte
2. Intercalated discs
3. Striations
4. Nucleus



Name _____

Section _____ Date _____

Check Your Recall

REVIEW

1 Label the following parts of the heart on Figure 17.13.

- ❑ Anterior interventricular artery
- ❑ Aorta
- ❑ Circumflex artery
- ❑ Inferior vena cava
- ❑ Pulmonary trunk
- ❑ Pulmonary veins
- ❑ Right coronary artery
- ❑ Superior vena cava

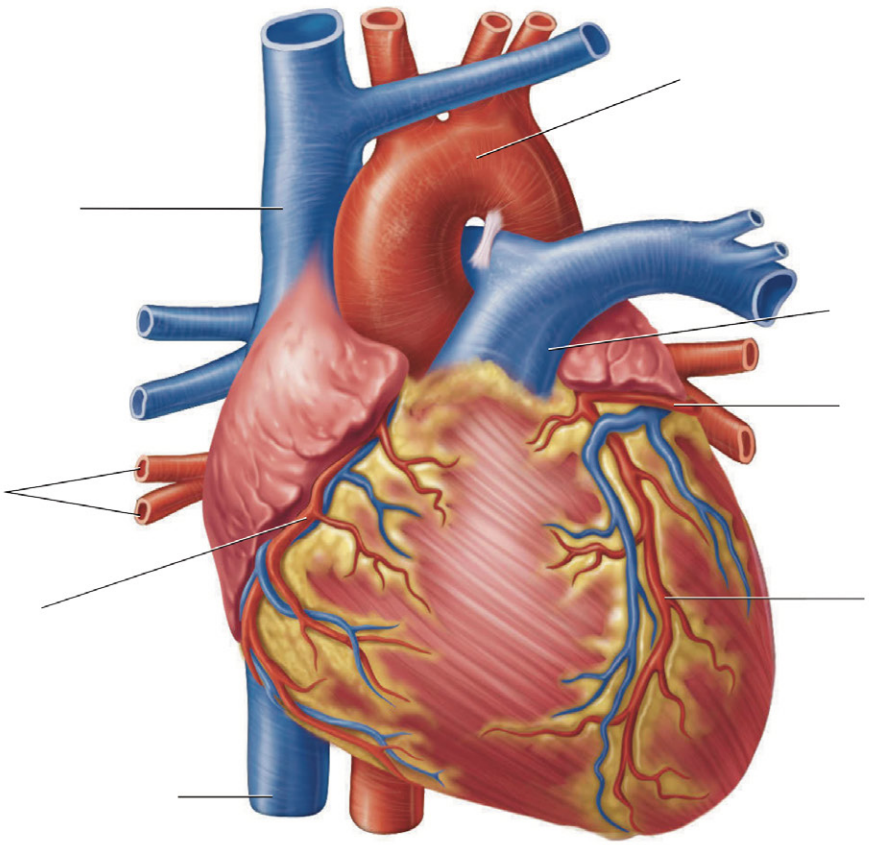

FIGURE **17.13** Heart, anterior view.

2 Label the following parts of the heart on Figure 17.14.

- ❑ Chordae tendineae
- ❑ Interventricular septum
- ❑ Left atrium
- ❑ Left ventricle
- ❑ Papillary muscle
- ❑ Right atrium
- ❑ Right ventricle

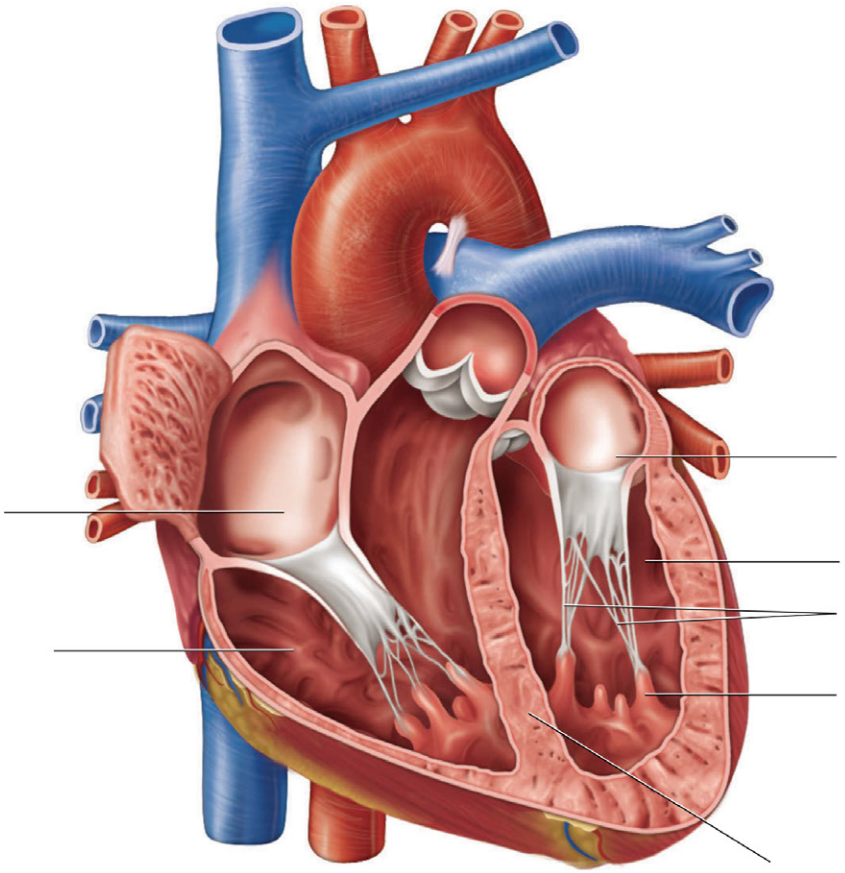

FIGURE **17.14** Frontal dissection of the heart.

Name _____

Section _____ Date _____

3 Label the following parts of the heart on Figure 17.15.

- ❑ Aortic valve
- ❑ Mitral valve
- ❑ Pulmonary valve
- ❑ Tricuspid valve

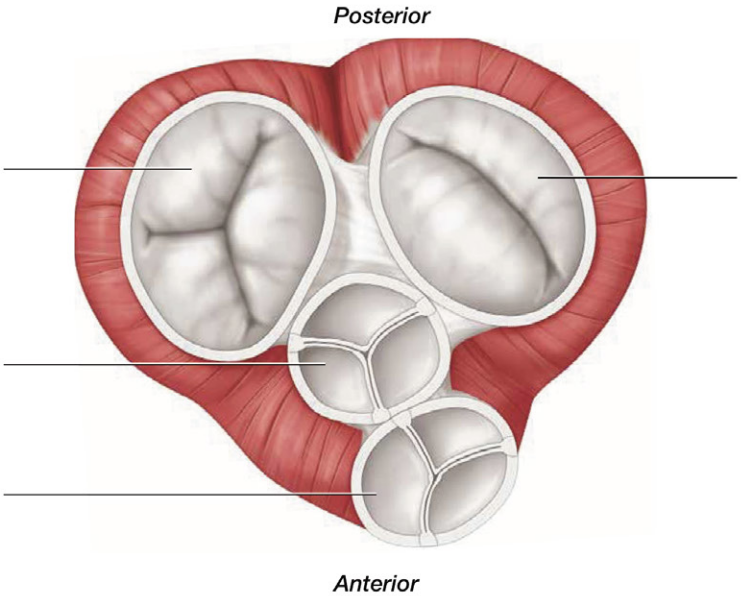

FIGURE **17.15** Transverse section of the heart showing all four valves.

4 *Matching:* Match the following terms with the correct definition.

_____ Myocardium
_____ Parietal pericardium
_____ Tricuspid valve
_____ Aortic valve
_____ Papillary muscles
_____ Pulmonary veins
_____ Mitral valve
_____ Visceral pericardium
_____ Pulmonary trunk
_____ Chordae tendineae

A. Located between the left ventricle and the aorta
B. Located between the left atrium and left ventricle
C. Inner layer of the serous pericardium
D. Bring(s) oxygenated blood to the left atrium from the lungs
E. Layer of the heart composed of cardiac muscle tissue
F. Bring(s) deoxygenated blood to the lungs
G. Located between the right atrium and the right ventricle
H. Fingerlike muscular projections from the ventricles
I. Outer layer of the serous pericardium
J. Fibrous cord(s) that attach(es) to valves

5 The arteries of the systemic circuit carry _____ blood, and the arteries of the pulmonary circuit carry _____ blood.

a. oxygenated; deoxygenated
b. oxygenated; oxygenated
c. deoxygenated; deoxygenated
d. deoxygenated; oxygenated

6 The tricuspid and mitral valves are known as the

a. chordae tendineae.
b. semilunar valves.
c. coronary valves.
d. atrioventricular (AV) valves.

7 The function of the papillary muscles is to

a. pull open the semilunar valves.
b. pull the chordae tendineae taut.
c. pull open the atrioventricular valves.
d. pull the semilunar valves closed.

8 *Fill in the blanks:* The two main branches of the left coronary artery are the _____ and the _____.

9 The main vein that drains the coronary circulation is the

a. superior vena cava.
b. pulmonary vein.
c. small cardiac vein.
d. coronary sinus.

10 *Fill in the blanks:* Cardiac muscle cells are also known as _____. Adjacent cells are joined together by _____, which allow the heart to _____.

Name _____

Section _____ Date _____

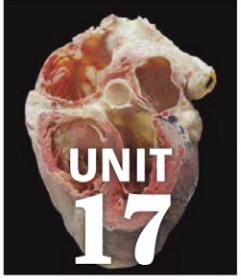

REVIEW

Check Your Understanding

Critical Thinking and Application Questions

1 When the pericardium fills with blood, it produces a condition called cardiac tamponade, which can be rapidly lethal. Why do you think this condition is so dangerous? (***Hint:*** Consider the structure of the fibrous pericardium.)

2 A condition known as *pulmonary hypertension* is characterized by high blood pressure in the pulmonary circuit. Which chamber of the heart would this condition most directly affect, and why?

3 Ms. F. visited her physician for a routine physical. During the exam, she explained that over the last two weeks, she had been feeling much more tired than normal and occasionally felt short of breath. Knowing that women usually present with atypical symptoms of a heart attack, her physician ran some diagnostic tests and found that Ms. F. was indeed having a heart attack.

a Imaging studies showed that Ms. F. had blockages in both her right marginal artery and her anterior interventricular artery. What parts of the heart would be affected by these blockages?

b Ms. F.'s heart attack damaged one of her papillary muscles. What is the normal function of a papillary muscle? Predict the consequences of a malfunctioning papillary muscle.

4 In the heart dissection you performed, you noted the muscular walls of the ventricles. The walls of the atria, however, were much thinner. Why do you think the ventricular walls are so much thicker than the atrial walls?

5 The condition known as *ventricular septal defect* is characterized by the presence of a hole in the interventricular septum. How would this condition affect the normal pattern of blood flow? What effect would this have on the oxygenation of the blood?

6 While in the hospital recovering from her heart attack Ms. F. developed a condition known as *atrial fibrillation*, in which the myocytes of the atria depolarize and contract individually. How are the cells of the heart supposed to contract? (***Hint:*** Think about the functions of the intercalated discs.) Why would it impair the functions of the heart as a whole to have cardiac myocytes contracting individually?

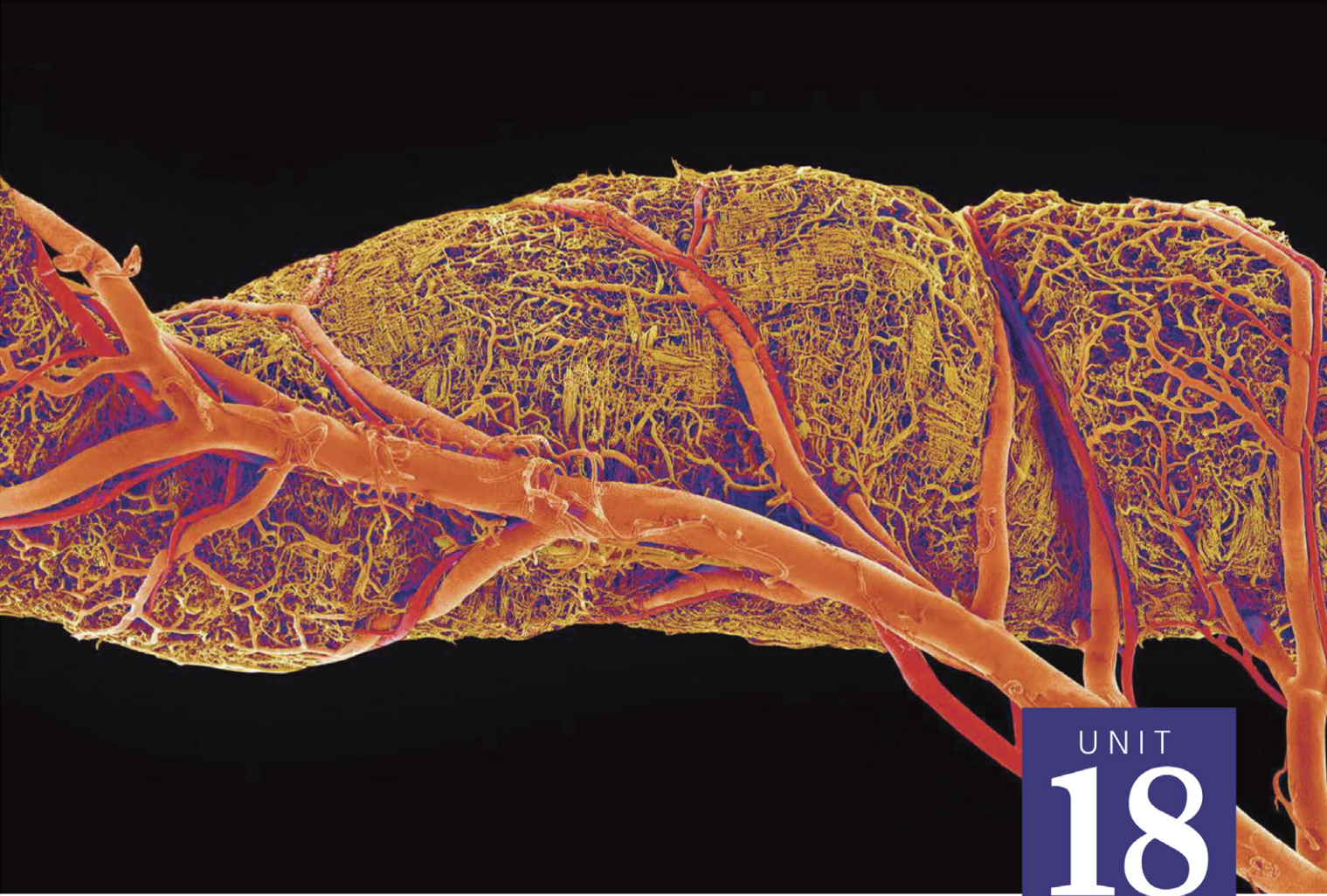

UNIT
18

Cardiovascular System—Part II: Blood Vessel Anatomy

Once you have completed this unit, you should be able to:

1. Identify selected arteries and veins.
2. Describe the organs and regions supplied and drained by each artery and vein.
3. Describe the unique blood flow patterns through the brain and the hepatic portal system.
4. Trace the pathway of blood flow through various arterial and venous circuits.
5. Describe the histological differences between arteries and veins.
6. Palpate common pulse points and identify common locations for blood draws.

Name _____ Section _____ Date _____

PRE-LAB EXERCISES

Complete the following exercises prior to coming to lab, using this lab manual and your textbook for reference.



Pre-Lab Exercise 18-1

Arterial Anatomy

Label the arterial diagrams in Figure 18.1A–D with the terms from Exercise 18-1 (p. 473). Use your text and Exercise 18-1 in this unit for reference. Note that these diagrams are presented in color to facilitate identification of the vessels.

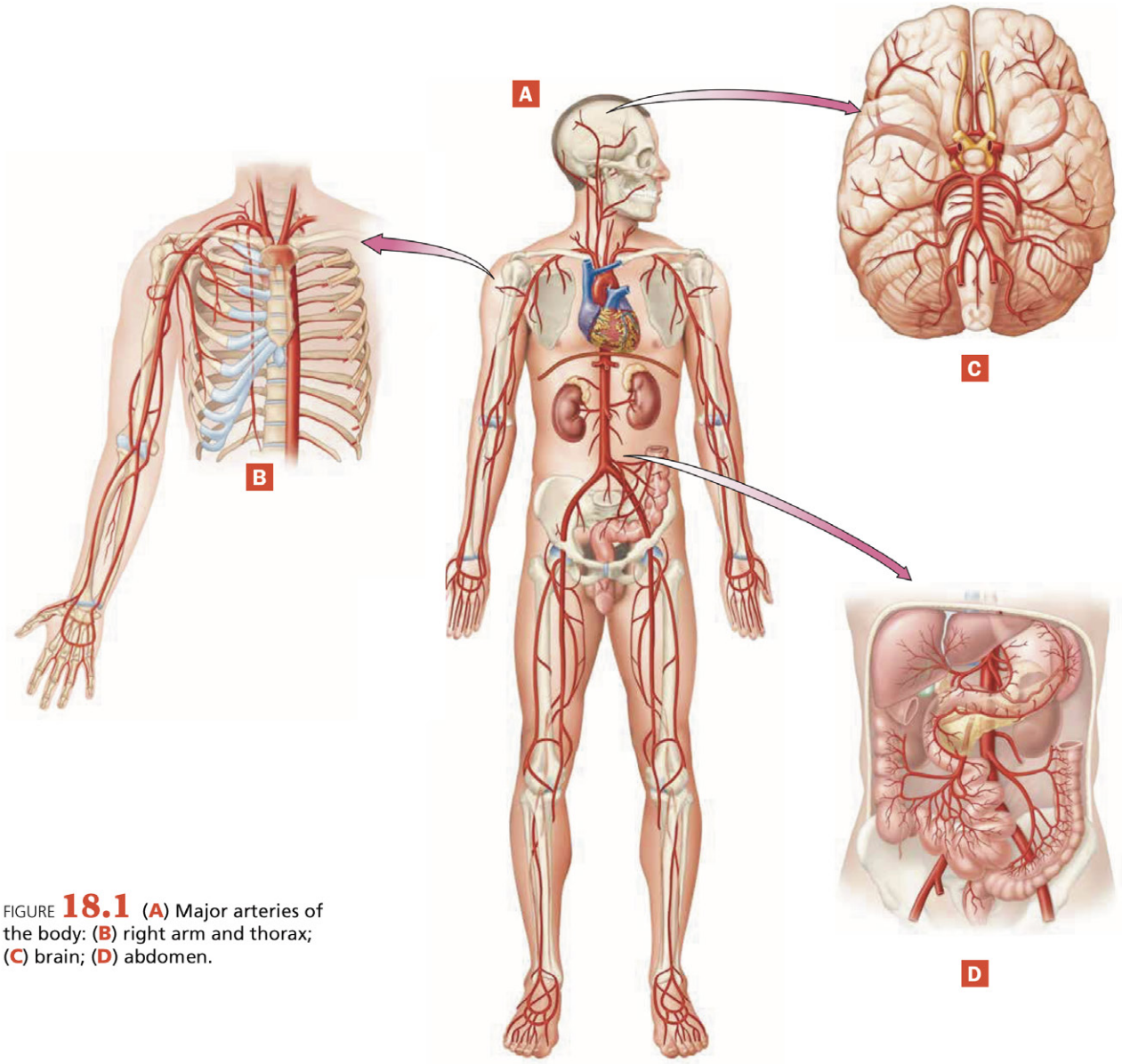

FIGURE 18.1 (A) Major arteries of the body: (B) right arm and thorax; (C) brain; (D) abdomen.

Pre-Lab Exercise 18-2



Venous Anatomy

Label the venous diagrams in Figure 18.2A–D with the terms from Exercise 18-2 (p. 478). Use your text and Exercise 18-2 in this unit for reference. Note that these diagrams are presented in color to facilitate identification of the vessels.

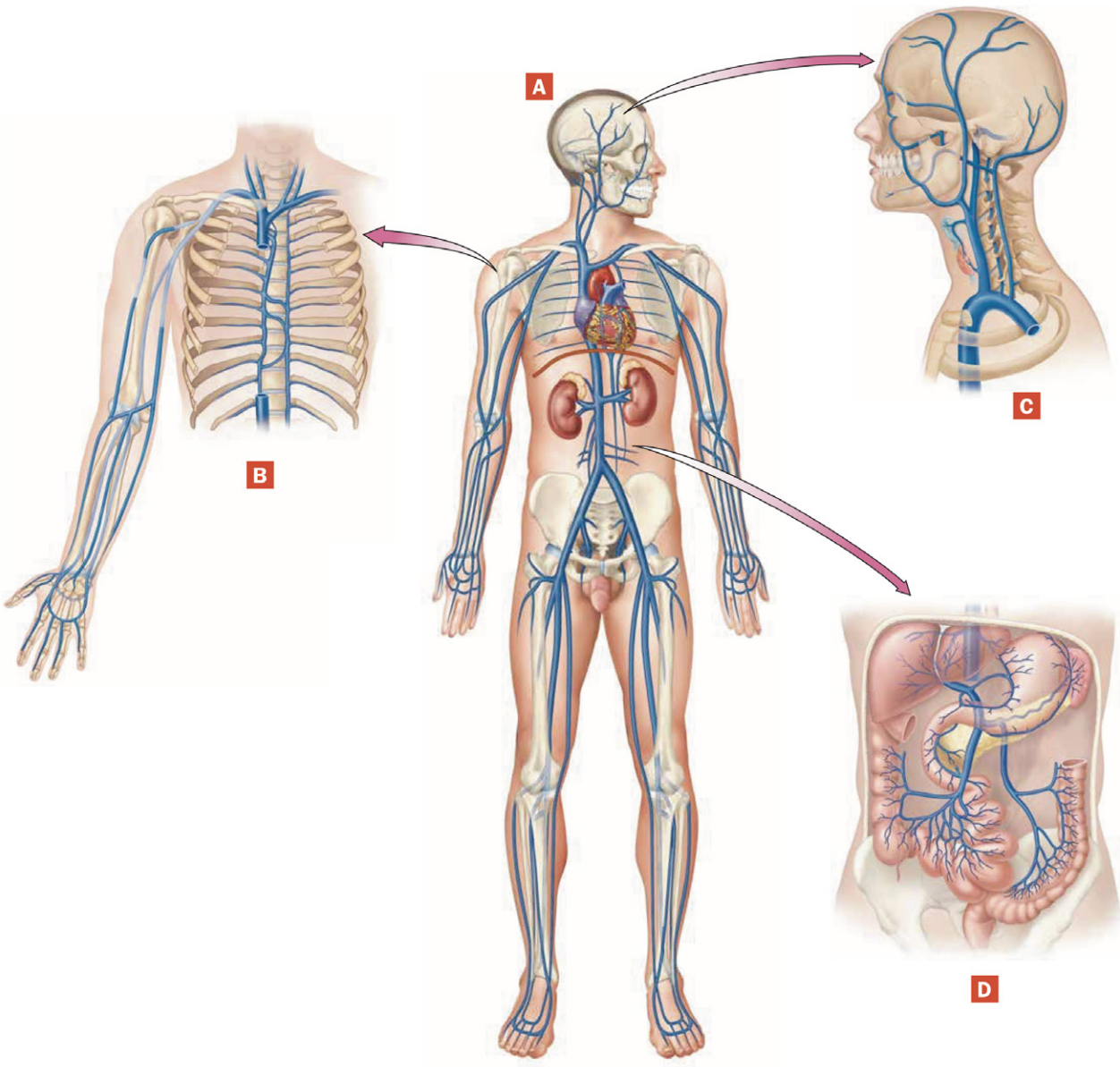

18

FIGURE 18.2 (A) Major veins of the body: (B) right arm and thorax; (C) head and neck; (D) abdomen and hepatic portal system.

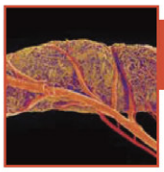

Colored SEM of blood vessels in the duodenum region of the small intestine.

EXERCISES

Blood vessels are a closed system of passages that transport blood around the body. The heart pumps blood away from the heart through a series of **arteries**. Arteries branch as they pass through organs and tissues to form progressively smaller vessels until they branch into tiny **capillary beds**, where gas, nutrient, and waste exchange take place. The blood is drained from the capillaries via a series of **veins** that return the blood to the heart.

The three major circuits of blood flow in the body are the following:

1. **Systemic.** The **systemic circuit** consists of a series of arteries that deliver oxygenated blood to capillary beds within the body's tissues, and a set of veins that return deoxygenated blood back to the heart.
2. **Coronary.** The **coronary circuit** is similar to the systemic circuit except its arteries, capillary beds, and veins supply and drain only the heart.
3. **Pulmonary.** The **pulmonary circuit** features a set of arteries that deliver deoxygenated blood to the capillary beds of the lungs, and a set of veins that return oxygenated blood to the heart.

In this unit we will address primarily the systemic circuit, as the coronary and pulmonary circuits were discussed in Unit 17. In the upcoming exercises, you will identify the systemic circuit's major blood vessels, trace various pathways of blood flow through the body, and examine the histology of the blood vessel wall. In the final exercise, you will perform some clinical examinations of blood vessels.

Exercise 18-1

Major Arteries of the Body

MATERIALS

- ❑ Blood vessel models:
  - human torsos
  - brain
  - head and neck
  - abdomen
  - upper limb
  - lower limb

The systemic arterial circuit begins with the largest artery in the body, the **aorta.** An overview of the systemic arterial circuit is shown in Figure 18.3. The aorta originates from the left ventricle as the **ascending aorta,** which ascends until it curves around to form the **aortic arch.** There are three major branches off the aortic arch: the *brachiocephalic trunk*, the *left common carotid artery*, and the *left subclavian artery*. The **brachiocephalic trunk** (bray-kee-oh-seh-FAL-ik) is a small trunk that veers to the right. Shortly after passing deep to the clavicle, it splits into the right common carotid and right subclavian arteries.

The arterial supply of the head and neck comes primarily from the **right** and **left common carotid arteries** (kuh-RAWT-id; Fig. 18.4). Notice that the right and left common carotid arteries have different origins—the right side branches from the brachiocephalic trunk, and the left side from the aortic arch. In the neck, these arteries branch into the internal and external carotid arteries. The **external carotid artery** gives off many branches that supply the structures of the head, neck, and face. One of its terminal branches is the large **superficial temporal artery**, which crosses the temporal bone to supply the scalp.

The **internal carotid arteries** pass through the carotid canals to enter the cranial cavity, where they give off branches called the **anterior** and **middle cerebral arteries** that supply the brain. Notice in Figure 18.5 that the two anterior cerebral arteries are connected by a small **anterior communicating artery**. Also supplying the brain are the **vertebral arteries**, which branch from the subclavian arteries. The vertebral arteries then pass through the vertebral foramina of the cervical vertebrae and enter the cranial cavity through the foramen magnum. At the brainstem, the two vertebral arteries fuse to become the single **basilar artery** (BAY-zih-lur), splitting again near the pituitary gland into the **posterior cerebral arteries**. These vessels give off small **posterior communicating arteries,** connecting the circulation of the basilar artery with that of the internal carotid arteries. As you can see in Figure 18.5, these vessels form a continuous structure known as the **cerebral arterial circle**. The connection provides alternate routes of circulation to the brain if one of the arteries supplying the brain becomes blocked.

The arterial supply to the upper limb begins with the right and left **subclavian arteries** (sub-KLAY-vee-in; Fig. 18.6). The subclavian artery becomes the **axillary artery** near the axilla. In the arm, the axillary artery becomes the **brachial artery**

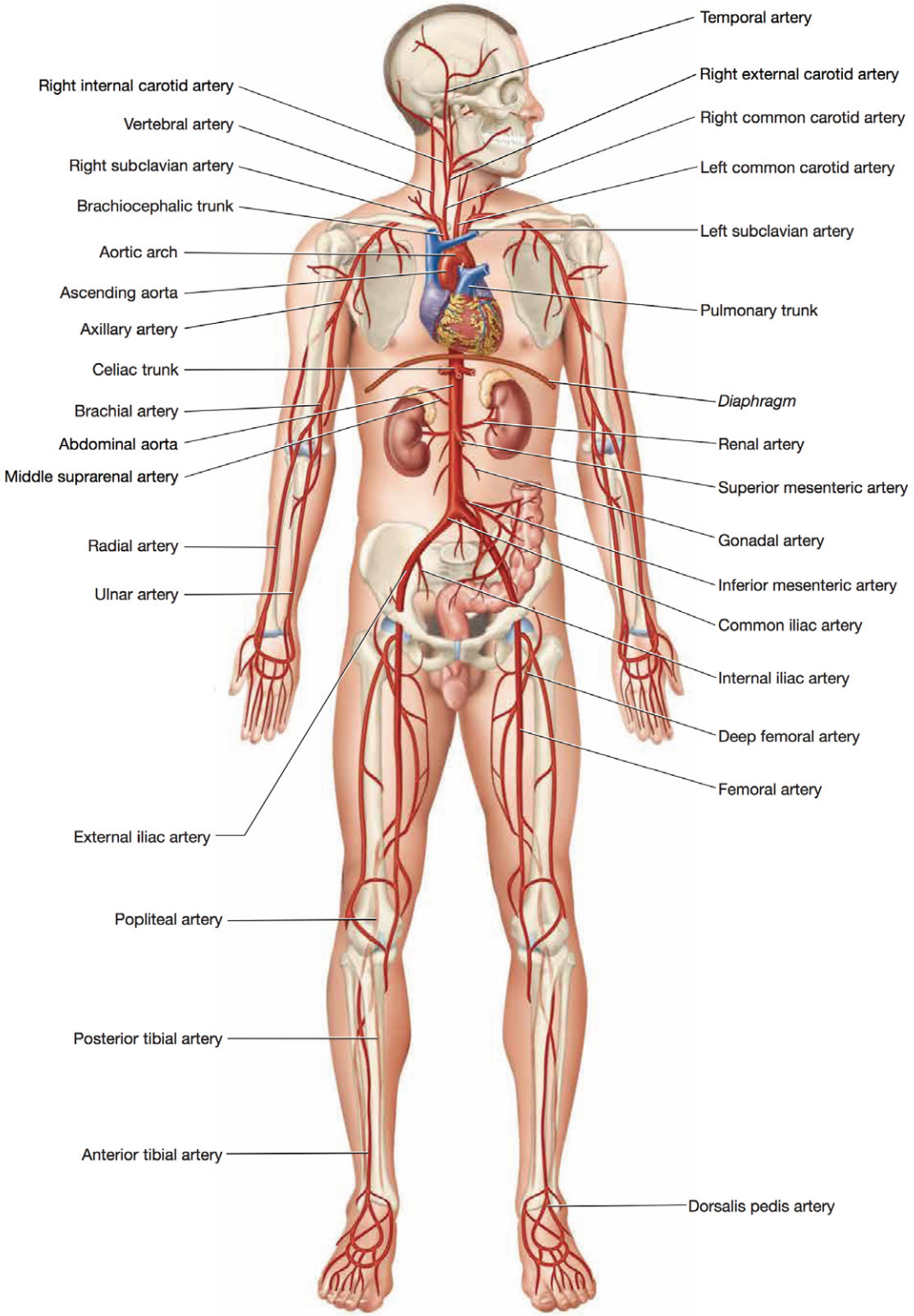

FIGURE **18.3** Major arteries of the body.

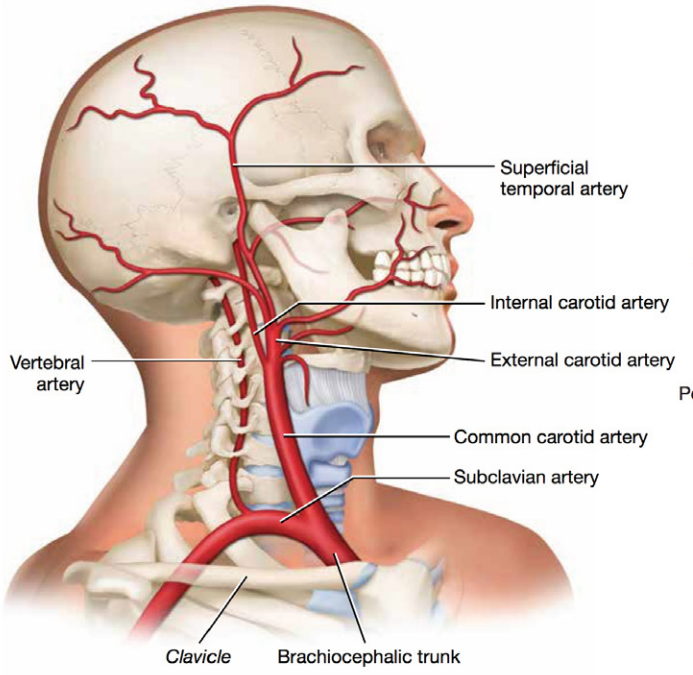

FIGURE **18.4** Arteries of the head and neck.

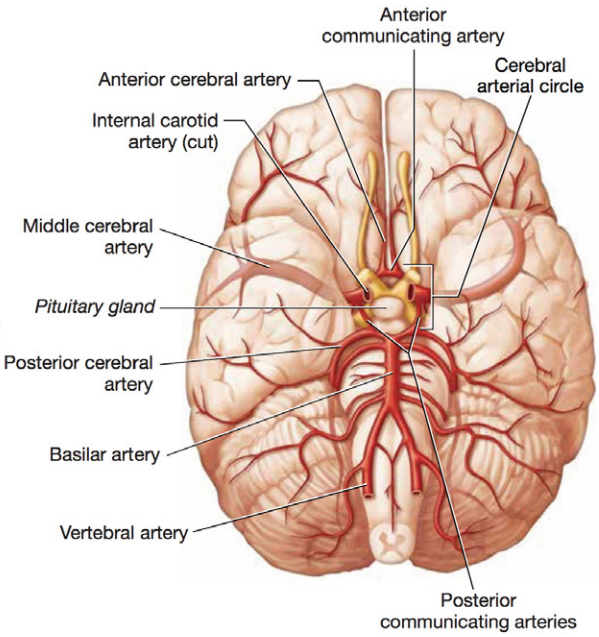

FIGURE **18.5** Arteries of the brain, inferior view.

(BRAY-kee-uhl), which splits into the **radial artery** and the **ulnar artery** just distal to the antecubital fossa. As you would expect, these arteries travel alongside the bones for which they are named—the radial artery is lateral and the ulnar artery is medial.

Near the left superior sternal border, the aortic arch curves inferiorly to become the **thoracic aorta**. The thoracic aorta descends through the thoracic cavity posterior to the heart, giving off *posterior intercostal arteries*, after which it passes through the diaphragm to become the **abdominal aorta**. The six major branches of the abdominal aorta, shown in Figure 18.7, include the following:

1. **Celiac trunk.** The short, stubby **celiac trunk** (SEE-lee-ak) is the first branch off the abdominal aorta. It splits almost immediately into the **common hepatic artery**, which supplies the

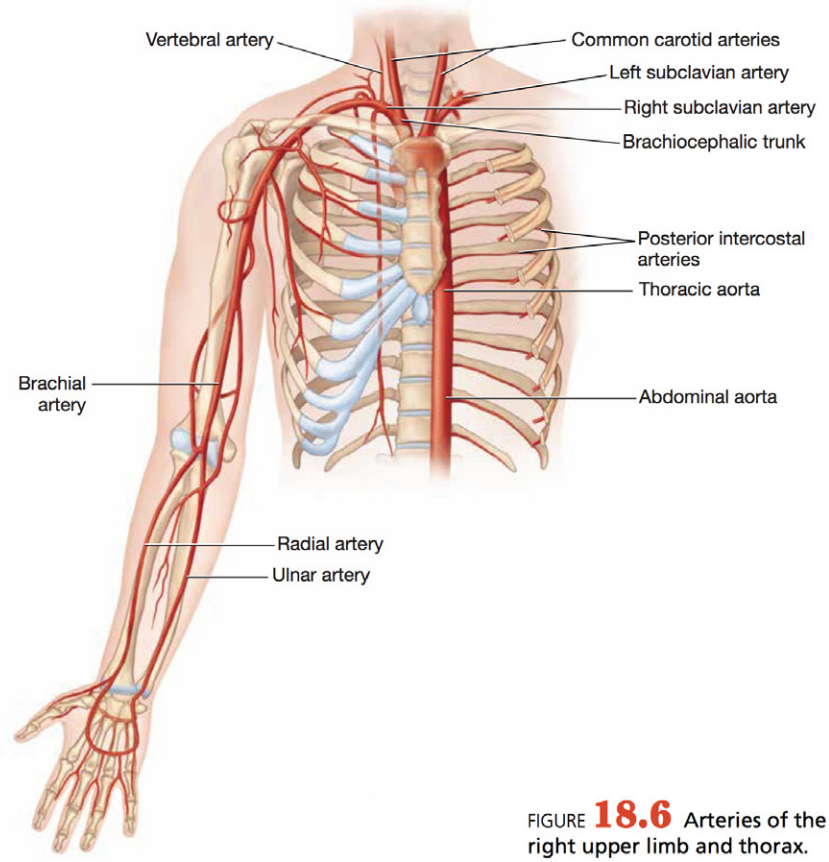

FIGURE **18.6** Arteries of the right upper limb and thorax.

liver, stomach, pancreas, and duodenum (part of the small intestine); the **splenic artery** (SPLEN-ik), which supplies the spleen, stomach, and pancreas; and the **left gastric artery**, which supplies the stomach.

2. **Middle suprarenal arteries.** Just inferior to the celiac trunk are the small **middle suprarenal arteries,** which supply the adrenal glands that are located on top of the kidneys. They are seen more clearly in Figure 18.3.
3. **Renal arteries.** Inferior to the celiac trunk we find the two **renal arteries** (REE-nuhl), which serve the kidneys. Note that the kidneys are posterior to the other abdominal organs in Figure 18.7 and so the renal arteries are slightly obscured by other organs and vessels. They are also seen more clearly in Figure 18.3.
4. **Superior mesenteric artery.** In the same vicinity of the renal arteries is another branch called the **superior mesenteric artery** (mez-en-TEHR-ik). As its name implies, it travels through the membranes of the intestines (called the *mesentery*) and supplies the small and much of the large intestine.
5. **Gonadal arteries.** Inferior to the superior mesenteric arteries we find a small pair of arteries that serve the reproductive organs, or *gonads*, and so are called the **gonadal arteries.**
6. **Inferior mesenteric artery.** The last large branch off the abdominal aorta is the **inferior mesenteric artery,** which supplies the remainder of the large intestine.

The abdominal aorta terminates by bifurcating into two **common iliac arteries** (ILL-ee-ak), which themselves bifurcate into an internal iliac artery and an external iliac artery (Figs. 18.7 and 18.8). The **internal iliac artery** supplies structures of the pelvis, and the **external iliac artery** passes deep to the inguinal ligament to enter the anterior thigh, where it becomes the **femoral artery.** In the proximal thigh, the femoral artery gives off the *deep femoral artery*, which travels posteriorly to supply the hip joint, femur, and other structures in the thigh. The femoral artery remains anterior until about midway down the thigh when it also passes posteriorly to become the **popliteal artery** (pahp-lih-TEE-uhl; named for the popliteal fossa, or the posterior knee). Just distal to the popliteal fossa, the popliteal artery divides into its two main branches: the **anterior tibial artery**, which continues in the anterior foot as the **dorsalis pedis artery** (dohr-SAL-iss PEE-diss), and the **posterior tibial artery,** which curls underneath the medial malleolus and continues to the plantar surface of the foot.

Many of the models in your lab likely show both arteries and veins. For this reason, we have included a few photos of anatomical models with arteries and veins to help guide you as you do your model inventories. These photos are in Figures 18.16–18.18 on pp. 484–485 (after we discuss veins).

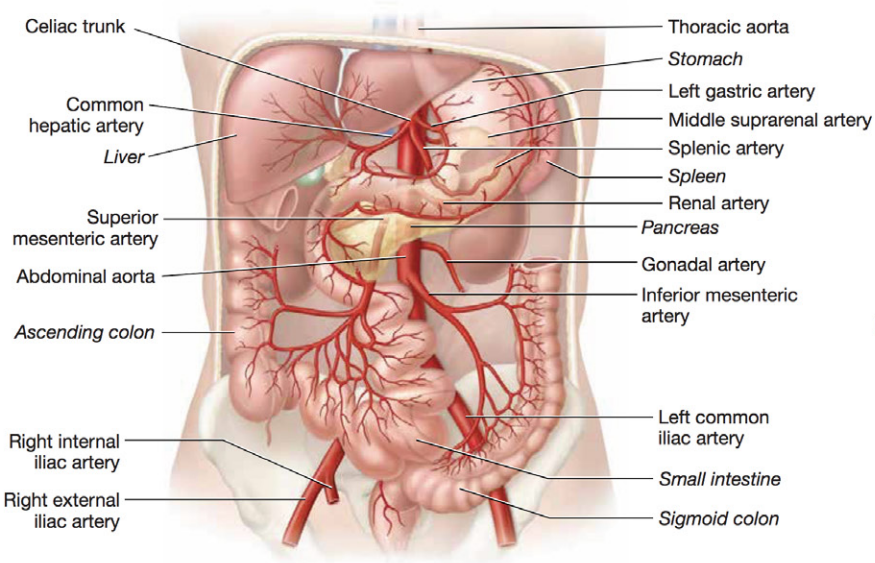

FIGURE **18.7** Arteries of the abdomen.

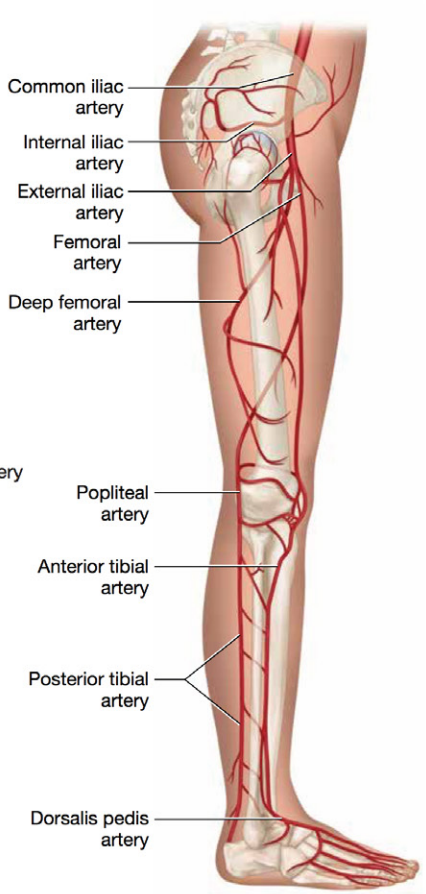

FIGURE **18.8** Arteries of the right lower limb, lateral view.

Procedure 1 Model Inventory for Arteries

Identify the following arteries on models and diagrams, using your textbook and this unit for reference. As you examine the anatomical models and diagrams, record the name of the model and the structures you were able to identify on the model inventory in Table 18.1. When you have completed the activity, answer Check Your Understanding questions 1 and 2 (p. 503).

Arteries of the Trunk

1. Aorta
   a. Ascending aorta
   b. Aortic arch
   c. Thoracic aorta
   d. Abdominal aorta
2. Brachiocephalic trunk
3. Subclavian artery
4. Celiac trunk
   a. Common hepatic artery
   b. Splenic artery
   c. Left gastric artery
5. Middle suprarenal arteries
6. Renal arteries
7. Superior mesenteric artery
8. Gonadal arteries
9. Inferior mesenteric artery
10. Common iliac artery
    a. Internal iliac artery
    b. External iliac artery

Arteries of the Head and Neck

1. Common carotid arteries
   a. Right common carotid artery
   b. Left common carotid artery
2. External carotid artery
   a. Superficial temporal artery
3. Internal carotid artery
   a. Anterior cerebral artery
   b. Middle cerebral artery
4. Vertebral artery
5. Basilar artery
   a. Posterior cerebral artery
6. Cerebral arterial circle
   a. Anterior communicating artery
   b. Posterior communicating arteries

Arteries of the Upper Limbs

1. Axillary artery
2. Brachial artery
3. Radial artery
4. Ulnar artery

Arteries of the Lower Limbs

1. Femoral artery
2. Popliteal artery
   a. Anterior tibial artery
      (1) Dorsalis pedis artery
   b. Posterior tibial artery

TABLE 18.1 Model Inventory for Arteries

Model/Diagram	Structures Identified

Exercise 18-2

Major Veins of the Body

MATERIALS

- ❑ Blood vessel models:
  - human torsos
  - brain
  - head and neck
  - abdomen
  - upper limb
  - lower limb
  - dural sinuses

Arteries of the systemic circuit deliver oxygenated, nutrient-rich blood to capillary beds, and here gases, nutrients, and wastes are exchanged. The deoxygenated, carbon dioxide-rich blood is then drained from the capillary beds by a series of veins. The two largest veins in the body are the **superior vena cava**, which drains most structures superior to the diaphragm, and the **inferior vena cava**, which drains most structures inferior to the diaphragm. An overview of the major veins of the body is shown in Figure 18.9.

The head and the neck are drained primarily by the internal and external jugular veins, with a small contribution from the **vertebral vein** in the posterior neck (Fig. 18.10). The much smaller and more lateral **external jugular vein** (JUG-yoo-lur) drains the face and the scalp, and the larger **internal jugular vein**, which travels in a sheath with the common carotid artery, drains the brain. Note, however, that venous blood from the brain does not simply drain into one vein and exit the head. Instead, blood from brain capillaries drains into cerebral veins, and then into spaces between the two layers of the dura mater called the **dural sinuses** (Fig. 18.11). As you can see in the figure, two of the sinuses, the **superior** and **inferior sagittal sinuses**, are located within the falx cerebri. Blood from the inferior sagittal sinus drains posteriorly into the **straight sinus**, and then joins with the blood from the superior sagittal sinus by draining into the **transverse sinuses**. From here, blood drains into the **sigmoid sinuses**, which also receive blood from the anterior **cavernous sinus**. At this point blood drains into the internal jugular vein.

Blood from the deep structures of the upper limb is drained by the **radial** and **ulnar veins**, both of which parallel the bones for which they are named (Fig. 18.12). These two veins merge in the arm to form the **brachial vein** near the antecubital fossa. The superficial structures of the upper limb are drained by three veins: the lateral **cephalic vein**, the middle **median antebrachial vein**, and the medial **basilic vein**. Notice in the figure that the cephalic vein and the basilic vein are united in the antecubital fossa by the **median cubital vein** (KYOO-bit-uhl). This is a frequent site for drawing blood with a syringe. Around the axilla, the basilic vein joins the brachial vein to form the **axillary vein**. Near the clavicle, the axillary vein becomes the **subclavian vein**, which drains into the **brachiocephalic vein,** and finally into the superior vena cava.

Also shown in Figure 18.12 is the venous drainage system of the posterior thoracic and abdominal walls, which drains into a set of veins called the **azygos system** (ay-ZY-gus). This system consists of three veins: the **azygos vein**, the **hemiazygos vein**, and the **accessory hemiazygos vein**. The vessels on the left side of the thorax, such as the *posterior intercostal veins*, drain into either the hemiazygos or accessory hemiazygos veins, which then drain into the azygos vein. Vessels on the right side of the thorax drain into the azygos vein. Blood in the azygos vein then drains directly into the superior vena cava.

Veins draining blood from the organs of the abdomen are named largely in parallel with the arteries that serve the organs: The **renal veins** drain the kidneys, the **gonadal veins** drain the gonads, the **suprarenal veins** drain the adrenal glands (Fig. 18.13), the **splenic vein** drains the spleen, the **gastric veins** drain the stomach, the **superior mesenteric vein** drains the small intestine and much of the large intestine, and the **inferior mesenteric vein** drains the remainder of the large intestine. Although the renal veins and gonadal veins empty into the inferior vena cava, the blood from the latter four veins does not drain into the inferior vena cava directly. Instead, note in Figure 18.14 that each vein drains into a common vein called the **hepatic portal vein**. Here, nutrient-rich blood passes through the sinusoids of the liver, where it is processed and detoxified. In this way, everything we ingest (except lipids, which we discuss in Unit 24) must travel through the liver before entering the systemic circulation. After the blood has filtered through the hepatic portal system, it exits via **hepatic veins** and drains into the inferior vena cava.

The deep structures of the leg are drained by the **anterior** and **posterior tibial veins**, which unite in the popliteal fossa to form the **popliteal vein** (Figs. 18.9 and 18.15). A superficial vein called the **small saphenous vein** (SAF-en-us) also drains into the popliteal vein. In the distal thigh, the popliteal vein becomes the **femoral vein**. The largest superficial vein of the lower limb is the **great saphenous vein**, which drains the medial leg and thigh and empties into the femoral vein in the proximal thigh.

The femoral vein becomes the **external iliac vein** after it passes deep to the inguinal ligament. In the pelvis, the external iliac vein merges with the **internal iliac vein**, which drains pelvic structures, forming the **common iliac vein**. The two common iliac veins unite to form the inferior vena cava near the superior part of the pelvis.

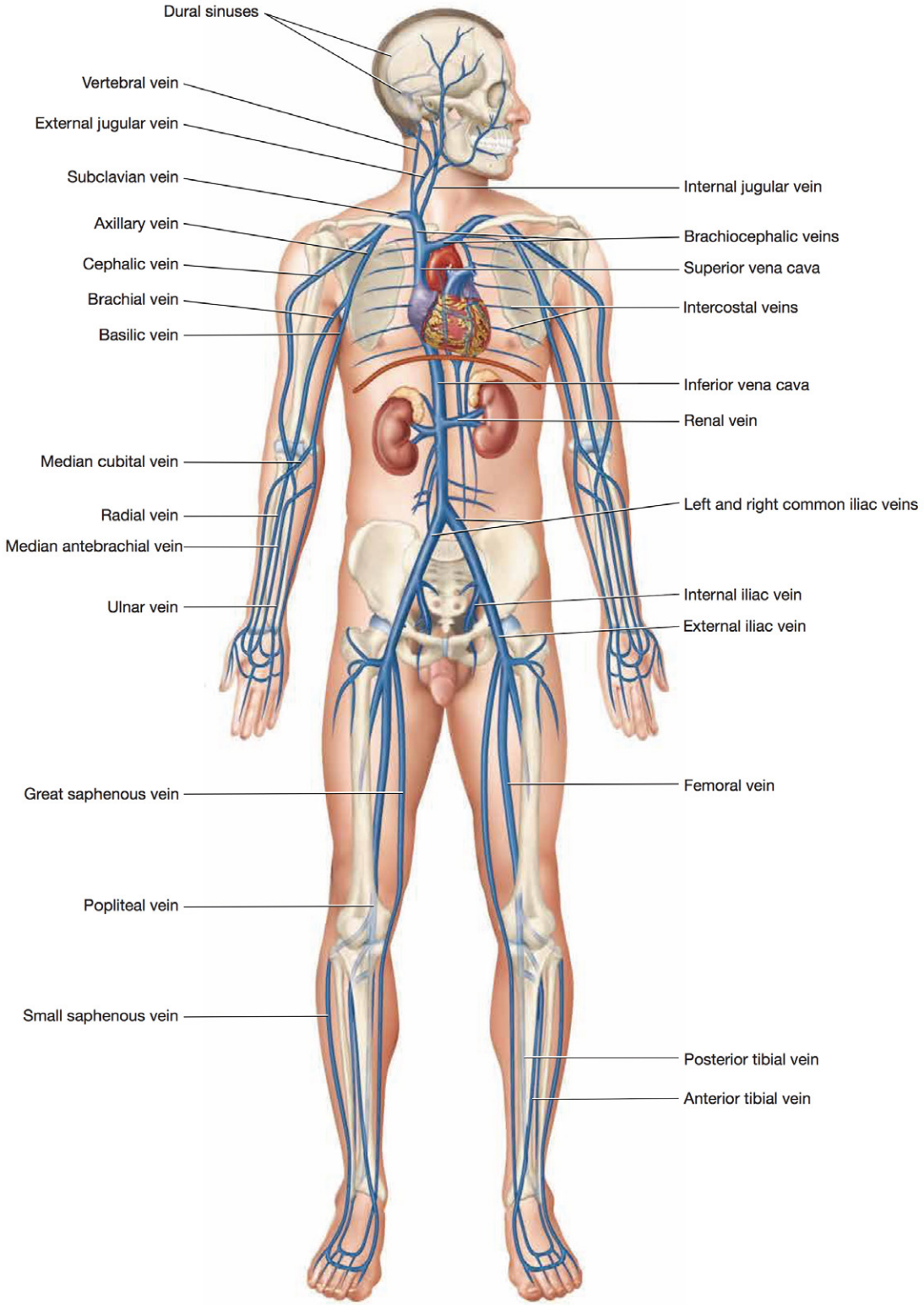

FIGURE **18.9** Major veins of the body.

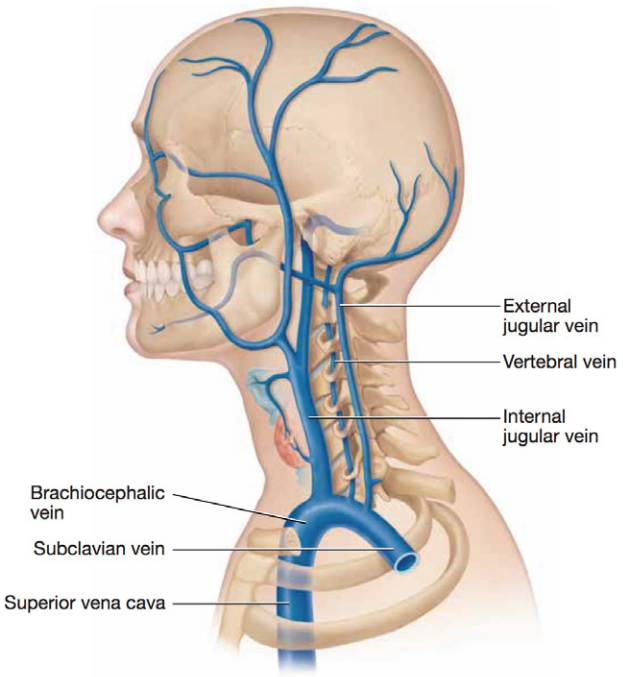

FIGURE **18.10** Superficial veins of the head and neck.

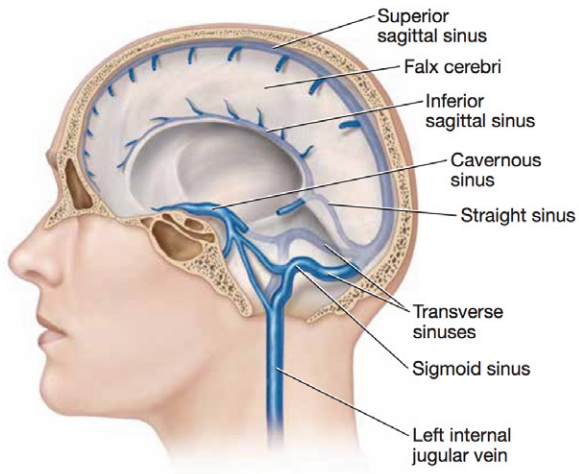

FIGURE **18.11** Veins draining dural sinuses of brain.

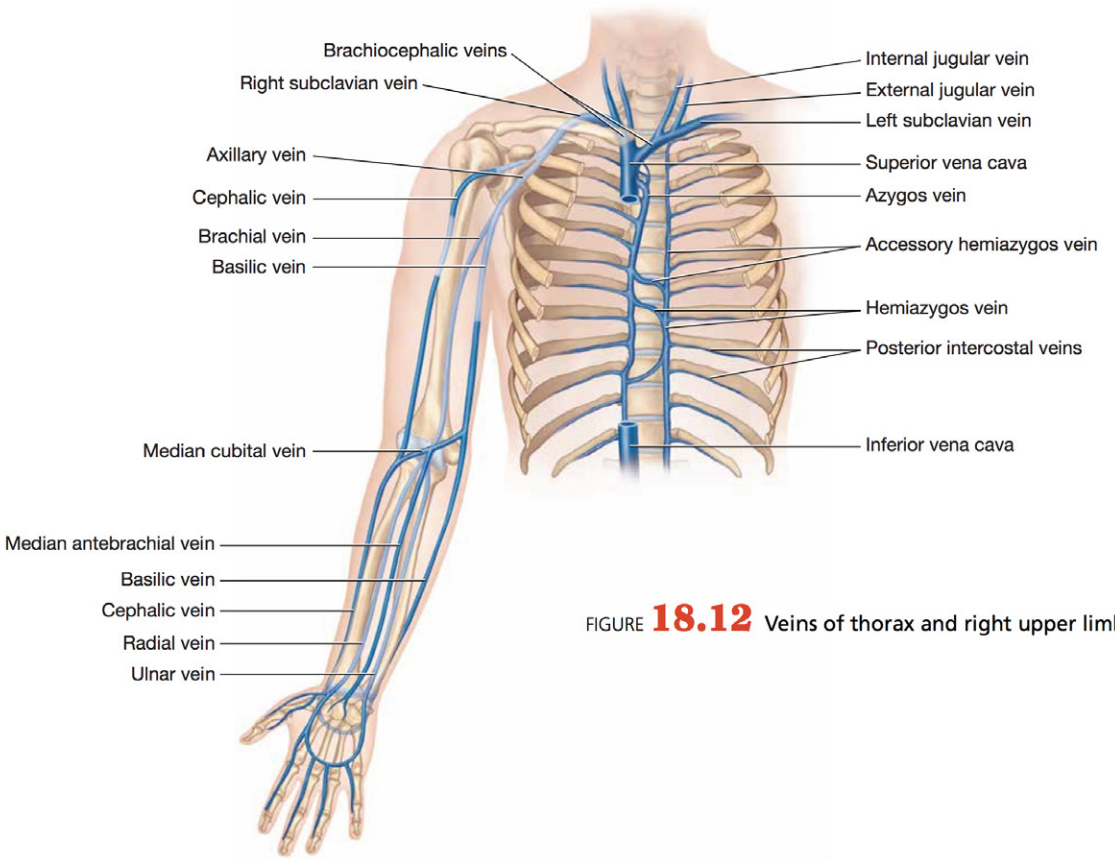

FIGURE **18.12** Veins of thorax and right upper limb.

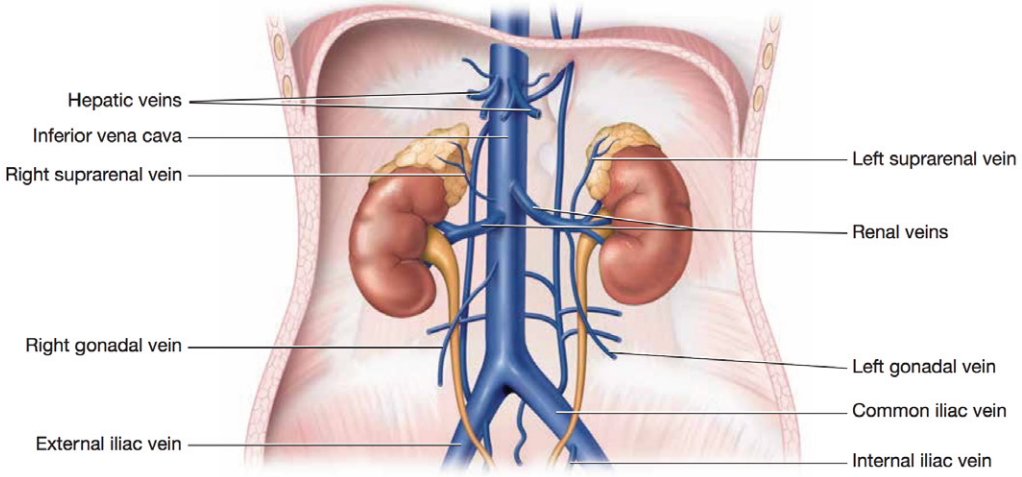

FIGURE **18.13** Veins draining the abdominal area (excluding the hepatic portal system).

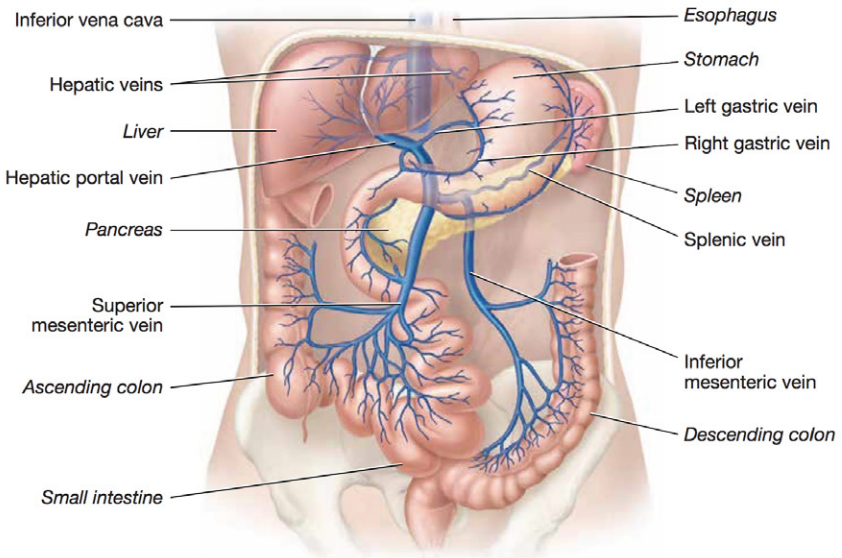

FIGURE **18.14** Veins of the abdomen and the hepatic portal system.

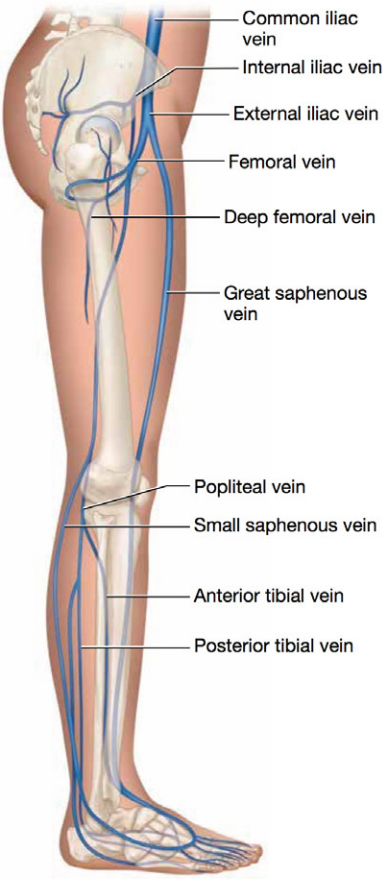

FIGURE **18.15** Veins of the lower limb, lateral view.

Procedure 1 Model Inventory for Veins

Identify the following veins on models and diagrams, using your textbook and this unit for reference. As you examine the anatomical models and diagrams, record the name of the model and the structures you were able to identify on the model inventory in Table 18.2. Figures 18.16–18.18 are photos of anatomical models that show both arteries and veins; you may use these to help guide your work as you do your model inventory. When you have completed the activity, answer Check Your Understanding question 3 (p. 503).

Veins of the Trunk

1. Superior vena cava
2. Inferior vena cava
3. Azygos system
   a. Azygos vein
   b. Hemiazygos vein
   c. Accessory hemiazygos vein
4. Renal vein
5. Gonadal veins
6. Suprarenal vein
7. Splenic vein
8. Gastric veins
9. Superior mesenteric vein
10. Inferior mesenteric vein
11. Hepatic portal vein
12. Hepatic veins

Veins of the Head and Neck

1. Vertebral vein
2. External jugular vein
3. Internal jugular vein
4. Dural sinuses
   a. Superior sagittal sinus
   b. Inferior sagittal sinus
   c. Straight sinus
   d. Transverse sinus
   e. Sigmoid sinus
   f. Cavernous sinus

Veins of the Upper Limbs

1. Radial vein
2. Ulnar vein
3. Brachial vein
4. Cephalic vein
5. Median antebrachial vein
6. Basilic vein
7. Median cubital vein
8. Axillary vein
9. Subclavian vein
10. Brachiocephalic vein

Veins of the Lower Limbs and Pelvis

1. Anterior tibial vein
2. Posterior tibial vein
3. Popliteal vein
4. Small saphenous vein
5. Great saphenous vein
6. Femoral vein
7. External iliac vein
8. Internal iliac vein
9. Common iliac vein

TABLE **18.2** Model Inventory for Veins

Model/Diagram	Structures Identified

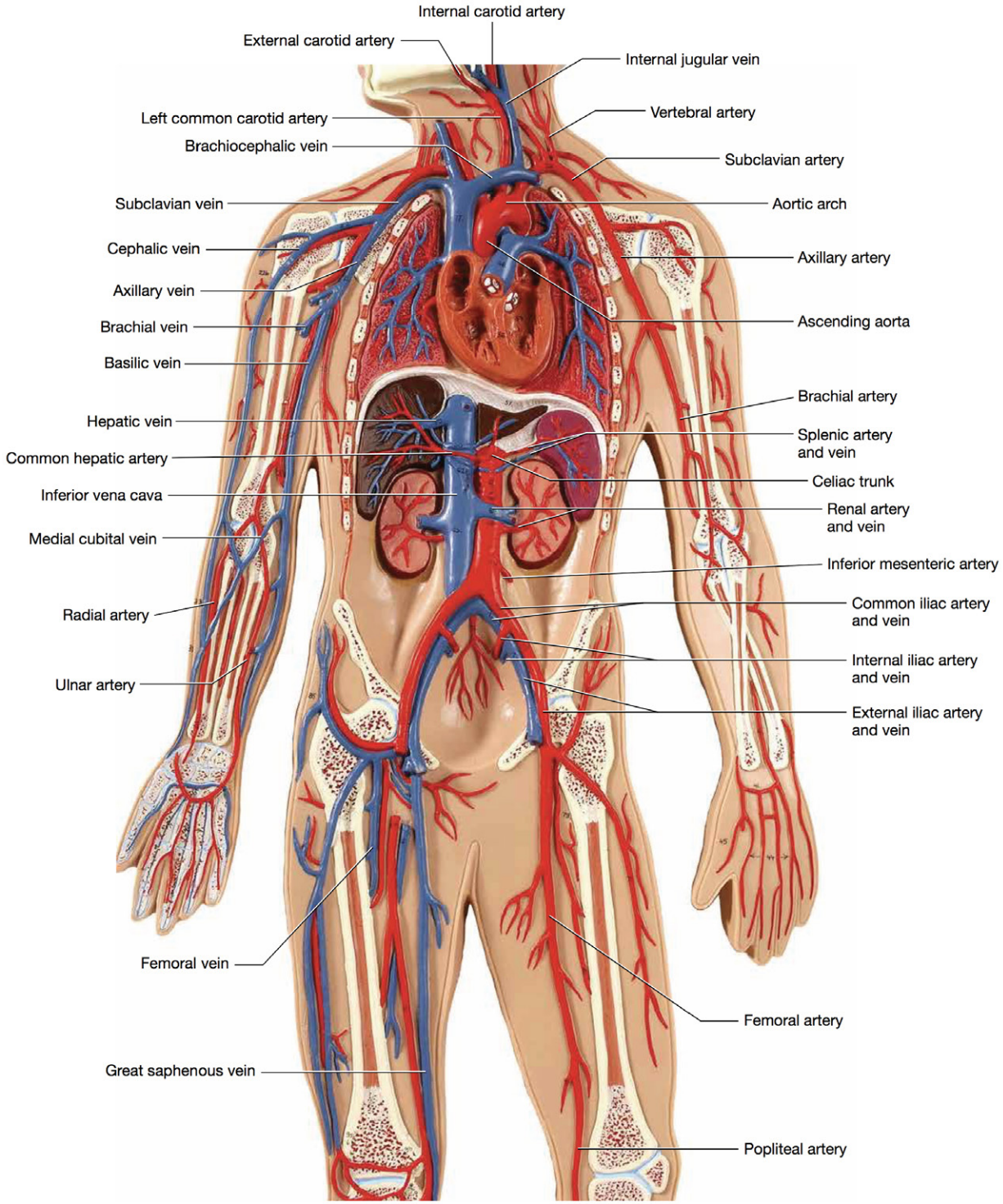

FIGURE **18.16** Arteries and veins of the body, model photo.

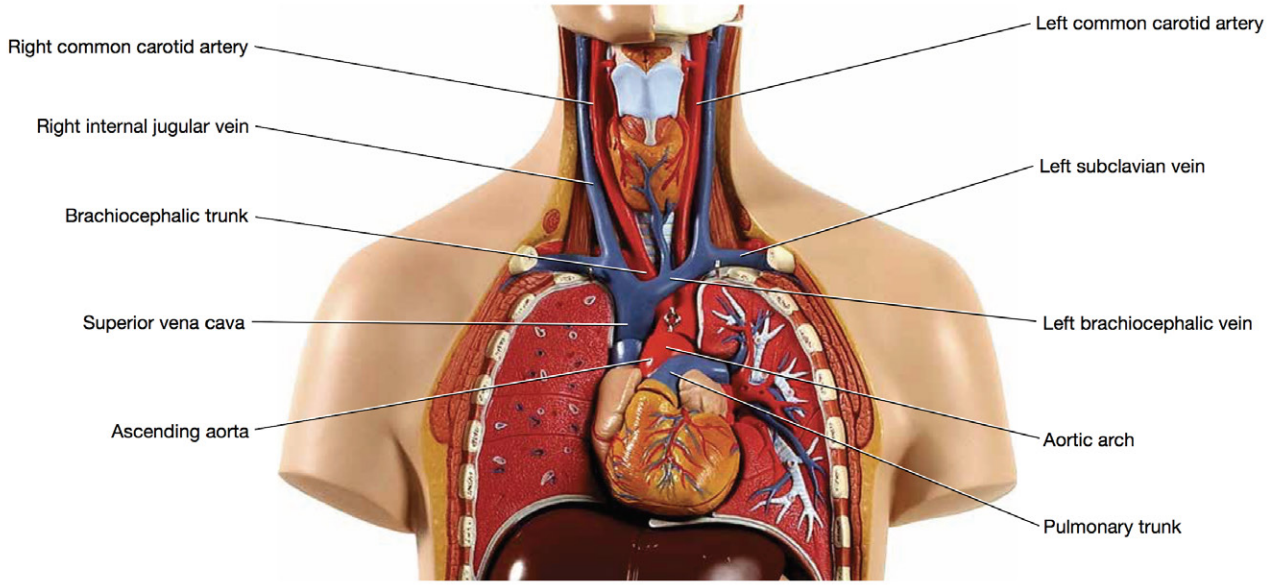

FIGURE **18.17** Arteries and veins of the neck and thorax, model photo.

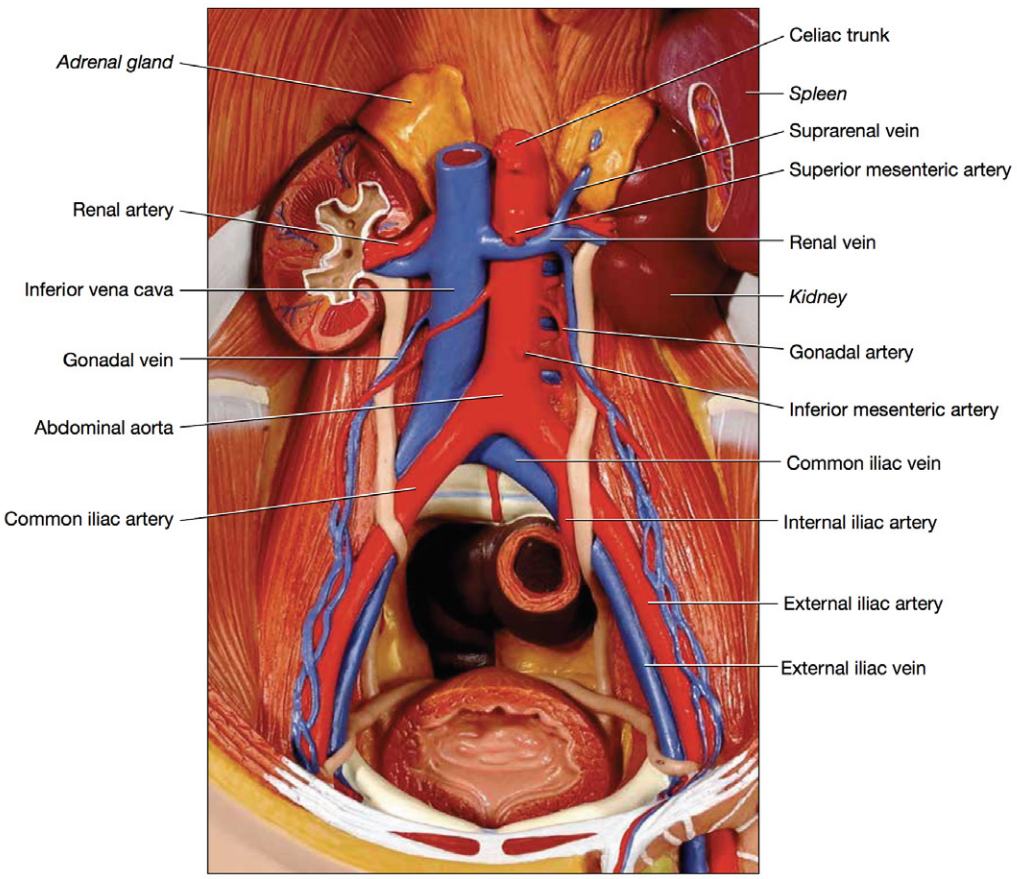

FIGURE **18.18** Arteries and veins of the posterior abdominal wall, model photo.

Exercise 18-3

Time to Trace!

MATERIALS

- ❑ Laminated outline of the human body
- ❑ Water-soluble marking pen

In this exercise you will trace the blood flow through various circuits in the body. As you trace, keep the following hints in mind:

- Don't forget about the hepatic portal system. Remember that most venous blood coming from the abdominal organs has to go through the hepatic portal vein and the hepatic portal system before it can enter the general circulation.
- Don't forget that the venous blood in the brain drains first into the dural sinuses, then into the internal jugular vein.
- If you start in a vein, you have to go through the venous system, through the right heart, through the pulmonary circuit, and then through the left heart before you can get back to the arterial system.
- If you start in an artery, you have to go through the arterial system and then through a *capillary bed* before you can get to the venous system. You can't go backward through the arterial system—that's cheating.
- If you start in an artery and end in an artery, you likely will have to go through the arterial circuit, through a capillary bed, through the venous circuit, back to the heart and lungs, and *then* reenter the arterial circuit.

Following is an example in which we have started in the right popliteal vein and ended in the left internal carotid artery:

Start: right popliteal vein ➜ right femoral vein ➜ right external iliac vein ➜ right common iliac vein ➜ inferior vena cava ➜ right atrium ➜ tricuspid valve ➜ right ventricle ➜ pulmonary valve ➜ pulmonary trunk ➜ pulmonary artery ➜ pulmonary capillaries ➜ pulmonary veins ➜ left atrium ➜ mitral valve ➜ left ventricle ➜ aortic valve ➜ ascending aorta ➜ aortic arch ➜ left common carotid artery ➜ left internal carotid artery ➜ **End**

Wasn't that easy?

Procedure 1 Tracing Blood Flow Patterns

Trace the path of blood flow through the following circuits, using the example on page 486 for reference. It is helpful to draw the pathway out on a laminated outline of the human body, and label each vessel as you trace. If a laminated outline is not available, use Figures 18.19–18.22 instead. When you have completed your tracings, answer Check Your Understanding question 4 (p. 504).

1 **Start:** Right renal vein

End: Right radial artery

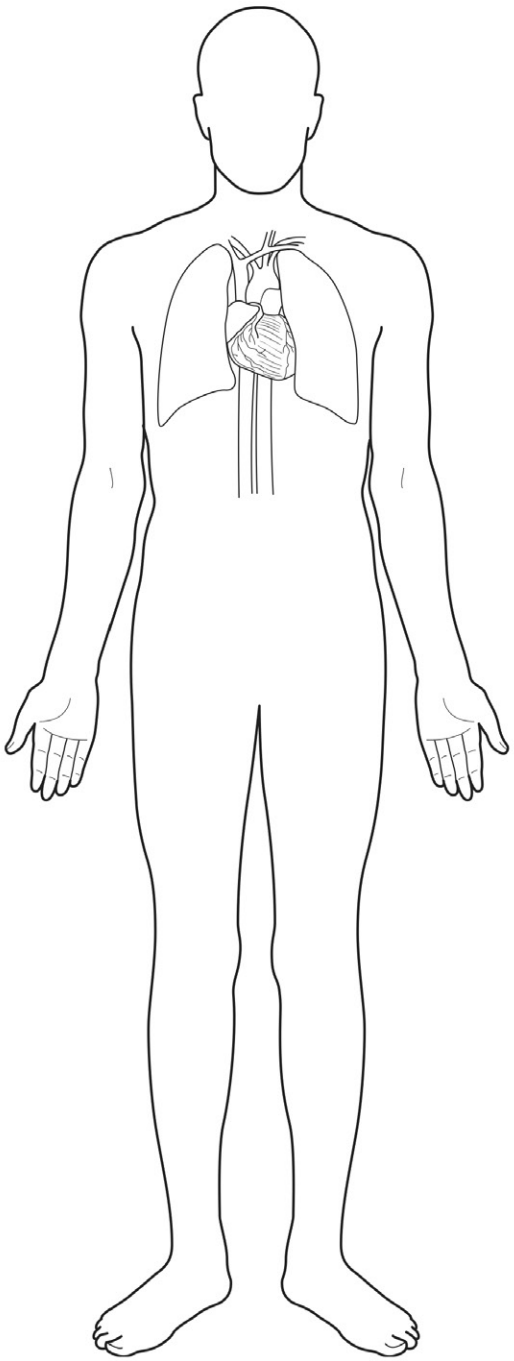

FIGURE **18.19** Outline of the human body.

2 **Start:** Middle cerebral artery

End: Left brachial artery

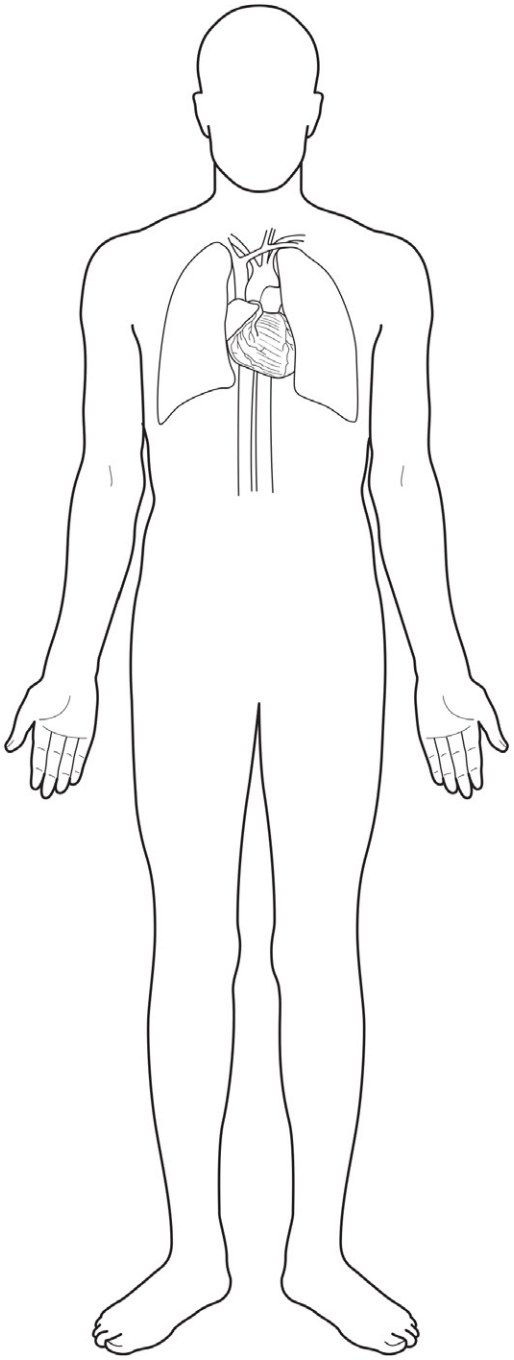

FIGURE **18.20** Outline of the human body.

3 **Start:** Superior mesenteric vein

End: Right dorsalis pedis artery

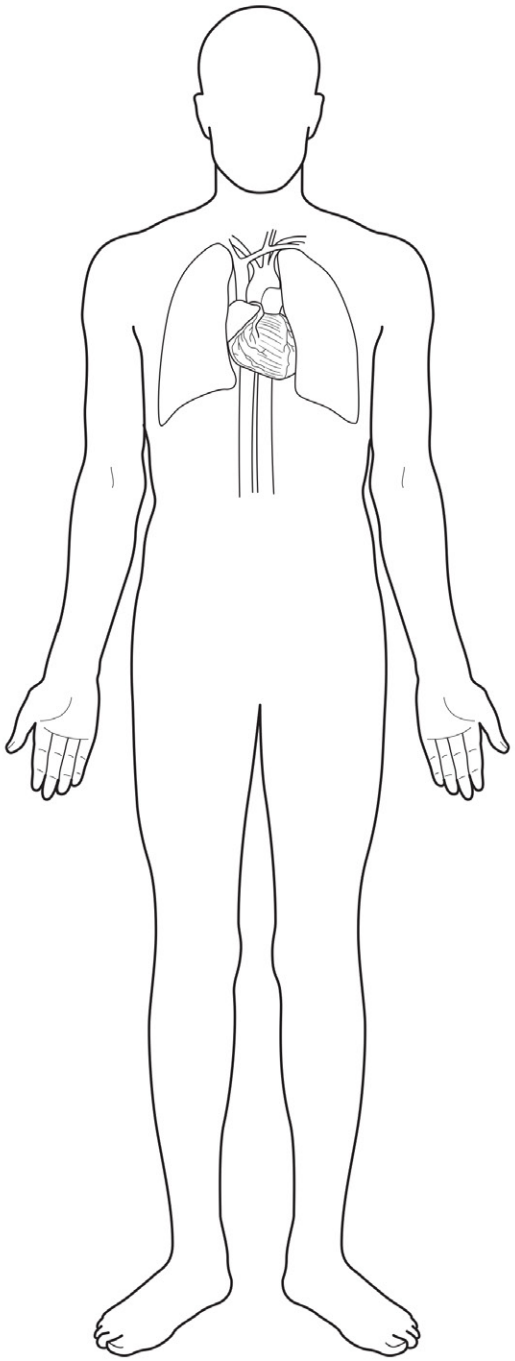

FIGURE **18.21** Outline of the human body.

4 **Start:** Left cephalic vein

End: Right internal carotid artery

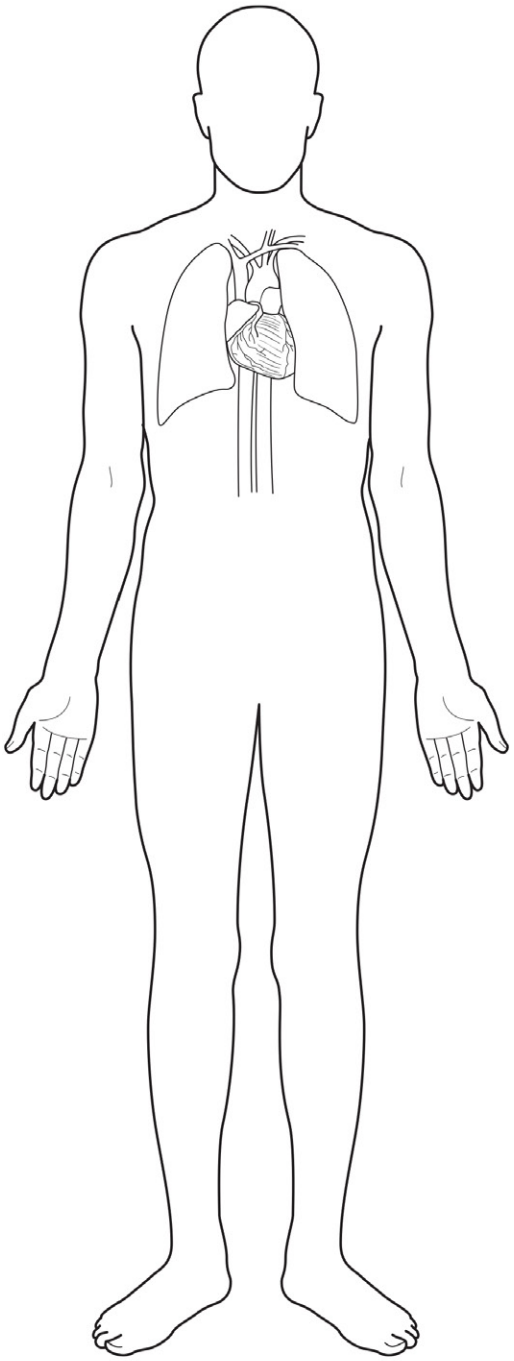

FIGURE **18.22** Outline of the human body.

Exercise 18-4

Histology of the Blood Vessel Wall

MATERIALS

- ❑ Blood vessel slide
- ❑ Light microscope
- ❑ Colored pencils

Three distinct tissue layers make up the walls of arteries and veins. The three layers, shown in Figure 18.23, are as follows:

1. **Tunica interna.** The innermost lining of the blood vessel is called the **tunica interna.** It consists of a specialized type of simple squamous epithelium called **endothelium.** It rests on top of a thin layer of extracellular matrix called the *basal lamina*.
2. **Tunica media.** The middle layer of the blood vessel wall is called the **tunica media,** and it consists of smooth muscle tissue and elastic fibers. The smooth muscle, innervated by the sympathetic nervous system, controls the diameter of the vessel and plays an important role in regulating tissue perfusion and blood pressure. The elastic fibers allow the vessel to expand with changing pressure and return to its original diameter.
3. **Tunica externa.** The outermost layer of the blood vessel wall is the **tunica externa** (or **tunica adventitia**), which consists of dense irregular collagenous connective tissue with abundant collagen fibers. The collagen fibers reinforce the blood vessel wall and prevent it from rupturing when the pressure in the vessel increases.

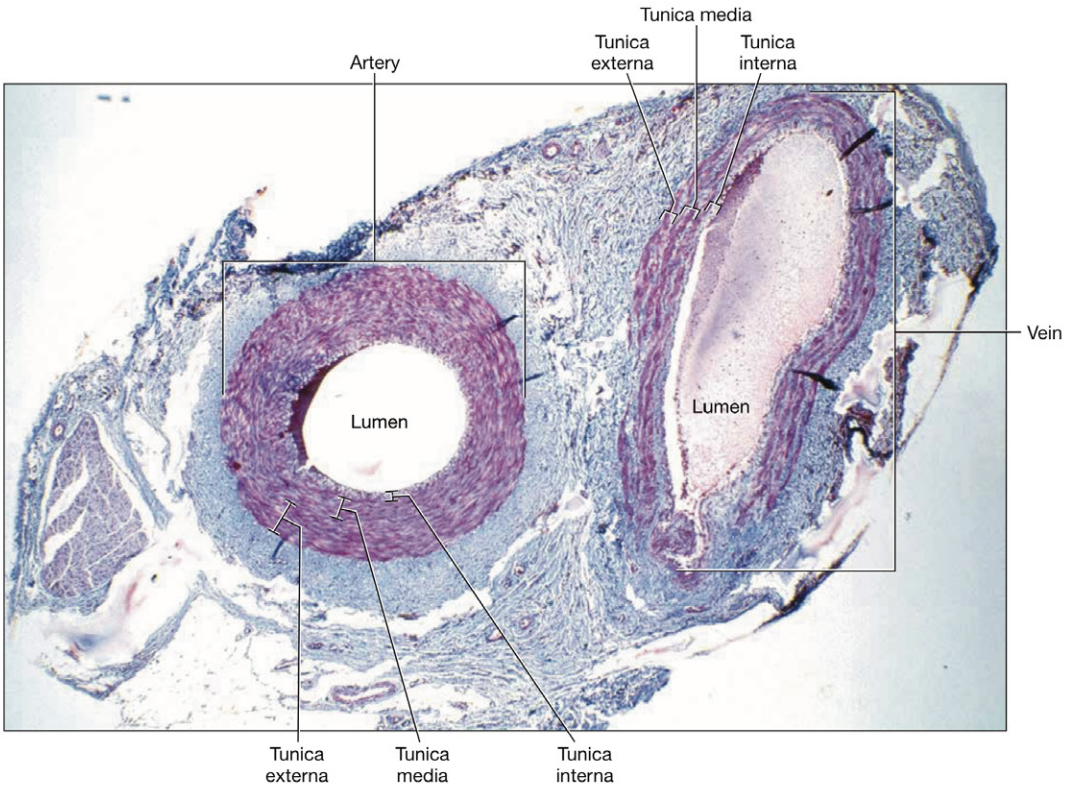

FIGURE **18.23** Photomicrograph, artery and veins.

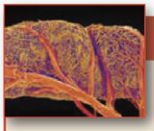

HINTS & TIPS

Like any other organ, the structure of each type of blood vessel follows its function. For this reason, the characteristics of the three layers of the blood vessel wall are considerably different in arteries, veins, and capillaries. They are easy to identify if you bear the following in mind:

- An artery has a much thicker tunica media, with prominent elastic fibers that typically appear as a wavy purple line. It appears circular in cross sections because of its thick wall. An artery closer to the heart is under very high pressure and so has more elastic fibers in the tunica media and more collagen fibers in the tunica externa.
- A vein has a thin tunica media with few elastic fibers and little smooth muscle. The lumen is wider because the wall is so much thinner, and the vein is typically collapsed on the slide.
- A capillary is extremely thin-walled and consists only of a thin tunica interna with its basal lamina. The smallest capillaries are wide enough for only one red blood cell to fit through at a time.

Procedure 1 Microscopy

Examine prepared microscope slides of an artery, a capillary, and a vein. The capillary may be on a separate slide. Use colored pencils to draw what you see and label your diagrams with the listed terms. When you have completed the activity, answer Check Your Understanding question 5 (p. 504).

1 Artery

a. Tunica interna (endothelium)
b. Tunica media
   (1) Smooth muscle
   (2) Elastic fibers
c. Tunica externa
d. Lumen



2 Capillary

a. Tunica interna
b. Blood cell(s)



3 Vein

a. Tunica interna
b. Tunica media
c. Tunica externa
d. Lumen



Exercise 18-5

Clinical Applications

MATERIALS

- ❑ Blood vessel model or diagram
- ❑ Tourniquets
- ❑ Water-soluble marking pen
- ❑ Alcohol swabs

Knowledge of blood vessel anatomy is important for many different clinical applications. Here we will examine two: (1) pulse palpation, and (2) locating veins for blood draws and intravenous access. Note that you're not actually going to be sticking each other with needles—you're just going to be finding the veins, not actually putting needles in them.

Procedure 1 Pulse Palpation

Pulse palpation is the process of using the fingertips to feel **pulse points**—locations where the artery is superficial enough that the artery's pulsations with each systole can be felt. It is performed to assess the rate, rhythm, and regularity of the heartbeat, and to assess the arterial circulation to different parts of the body. The pulse points commonly assessed are those found at the radial, ulnar, brachial, carotid, temporal, femoral, popliteal, posterior tibial, and dorsalis pedis arteries, shown in Figure 18.24.

When pulses are palpated, they are **graded** according to a standard scale. This allows healthcare professionals to communicate about a patient unambiguously and to assess the progress or deterioration of a patient's condition. The scale utilizes the following four grades:

- Grade **0/4**: The pulse is absent.
- Grade **1/4**: The pulse is barely or only lightly palpable.
- Grade **2/4**: The pulse is normal.
- Grade **3/4**: The pulse is abnormally strong.
- Grade **4/4**: The pulse is bounding and visible through the skin.

Notice that this scale has no negative numbers or decimal numbers (e.g., you would not use –1/4 or 2.5/4). In a healthy person most pulses are grade 2/4 (read as, "two out of four"), although occasionally a pulse is weak or absent. This is simply normal anatomical variation and does not signify pathology. Students often mistakenly grade any strong pulse as 4/4. If a pulse were truly 4/4, however, this would be a sign of extremely high blood pressure in that artery and would possibly be a medical emergency. Most strong, healthy pulses are graded as 2/4.

Please note before you begin that you should never assess both of your lab partner's carotid pulses at the same time. Doing so might initiate the **baroreceptor reflex** (BEHR-oh-reh-sep-ter), in which the parasympathetic nervous system triggers a reflexive and often dramatic drop in blood pressure and heart rate. This could cause your lab partner to momentarily lose consciousness.

When you have completed the procedure, answer Check Your Understanding question 6 (p. 504).

1. Wash your hands prior to palpating your lab partner's pulses.
2. On a model or diagram, locate the artery you are palpating.
3. Lightly place your index finger and middle finger over the artery. You may increase the pressure slightly, but be careful not to press too hard, because you could cut off blood flow through the artery and also could mistake the pulse in your fingertips for your partner's pulse. If you are unsure if the pulse is yours or your partner's, feel the lab table. If the lab table "has a pulse," you are feeling the pulse in your own fingertips.
4. Palpate *only* one side (right or left) at a time, especially in the carotid artery.
5. Grade your partner's pulses according to the 0/4 to 4/4 scale, and record the results in Table 18.3.

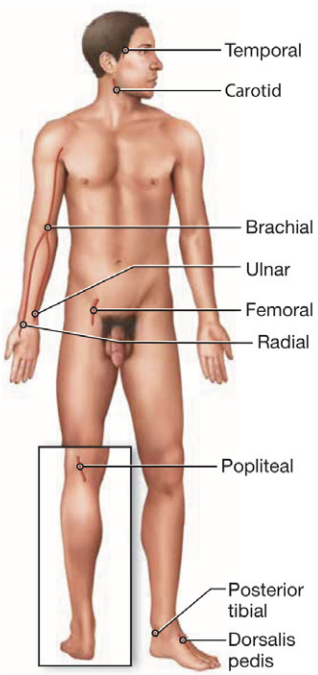

FIGURE **18.24** Common pulse points.

TABLE **18.3** Pulse Points Grades

Artery	Right-Side Grade	Left-Side Grade
Carotid		
Temporal		
Brachial		
Radial		
Ulnar		
Dorsalis pedis		
Posterior tibial		

Procedure 2 Locating Common Blood Draw and Intravenous Access Points

The superficial veins of the arm, forearm, and hand provide multiple places that are relatively easy to access when we need to obtain venous blood. When performing a *blood draw*, or the withdrawal of blood for analysis, the most commonly used veins are the median cubital vein, the cephalic vein, or the basilic vein. When placing an *intravenous catheter* into a vein, generally one of the posterior veins of the hand is used.

If you take a look at your arms and hands right now, you'll see that these superficial veins aren't really all that visible. You might see a few small, very superficial veins, but usually none that are large enough in which to place a needle. To get these veins to "pop," medical professionals wrap a tourniquet around the proximal arm, which increases the pressure in the distal veins and decreases venous return. This increases the amount of blood in the veins, and makes them more visible from the surface of the skin (Fig. 18.25). Your goal in this activity is to use a tourniquet to make your lab partner's veins "pop" and identify as many superficial veins as possible.

1. Obtain a tourniquet of the appropriate size and place it around your partner's arm about 7.5–10 cm (3–4 inches) proximal to the antecubital fossa. It should be tight, but avoid pinching your partner's skin or causing too much discomfort.
2. First look for the veins on the anterior arm. Wait about 15 to 20 seconds for the veins to begin to fill with blood. It may help for your partner to open and close his or her fist once or twice. If you can't see the superficial veins, tapping them lightly may also help make them more visible. Do not leave the tourniquet on your partner's arm for longer than 1 minute.
3. When you can see your partner's veins, trace them lightly with a water-soluble marking pen. Which veins were you able to find and identify?

4 Remove the tourniquet from your partner's arm and repeat the procedure on the opposite arm, this time looking for veins on the posterior hand. Again, do not leave the tourniquet on your partner's arm for longer than 1 minute. Which veins were you able to find and identify?

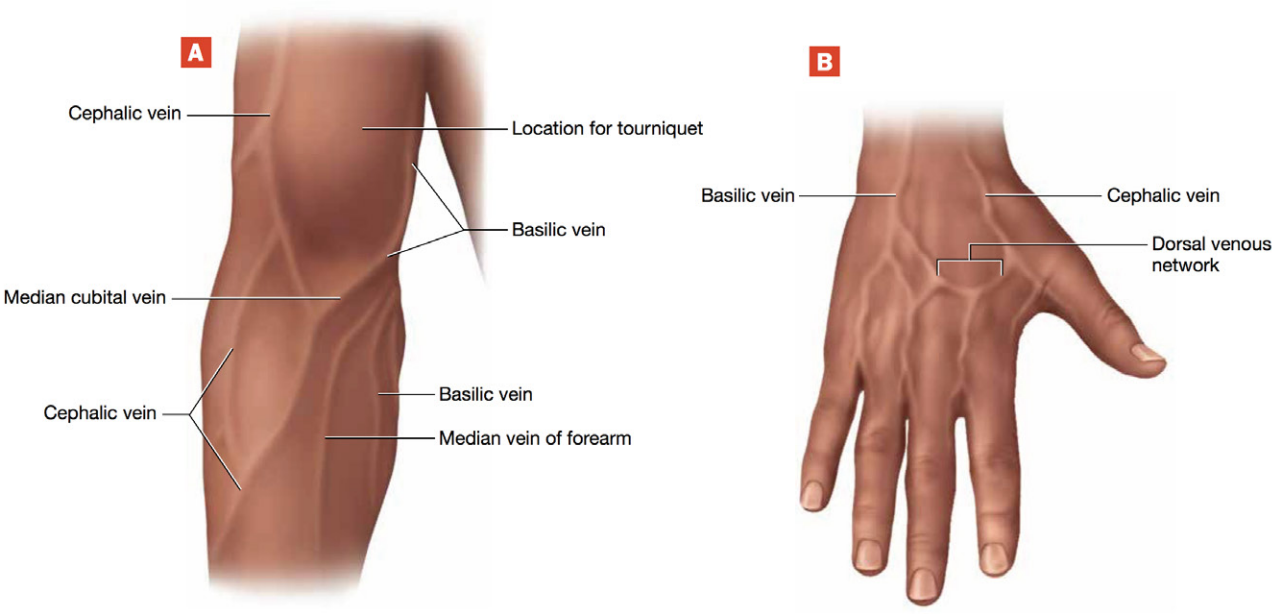

FIGURE **18.25** Surface anatomy of the superficial veins: (**A**) veins of the anterior arm and forearm; (**B**) veins of the posterior hand.

Name _____

Section _____ Date _____

Check Your Recall

REVIEW

1 Label the following arteries in Figure 18.26.

- ❑ Basilar artery
- ❑ Brachiocephalic trunk
- ❑ Cerebral arterial circle
- ❑ External carotid artery
- ❑ Internal carotid artery
- ❑ Middle cerebral artery
- ❑ Posterior communicating artery
- ❑ Right common carotid artery
- ❑ Vertebral artery

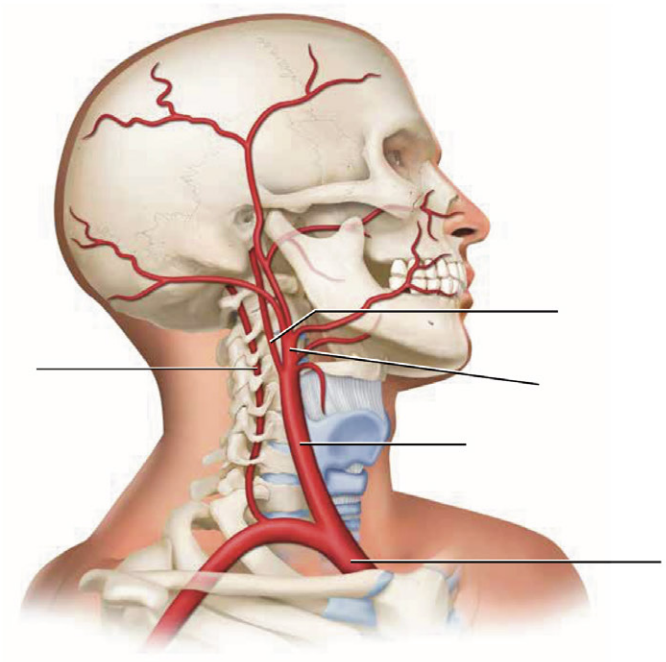

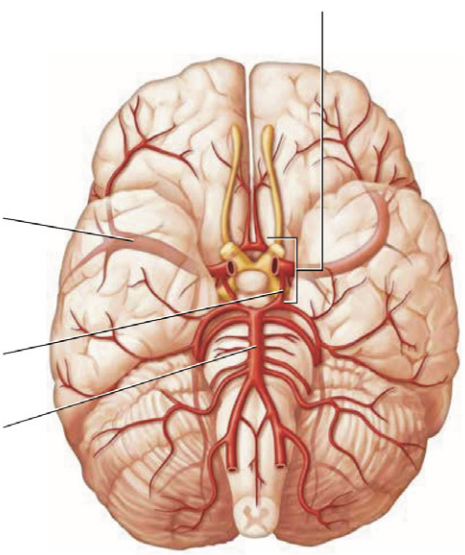

FIGURE **18.26** Arteries of the head, neck, and brain.

2 Label the following arteries in Figure 18.27.

- ❑ Brachial artery
- ❑ Dorsalis pedis artery
- ❑ Femoral artery
- ❑ Left common carotid artery
- ❑ Posterior tibial artery
- ❑ Radial artery
- ❑ Subclavian artery
- ❑ Ulnar artery

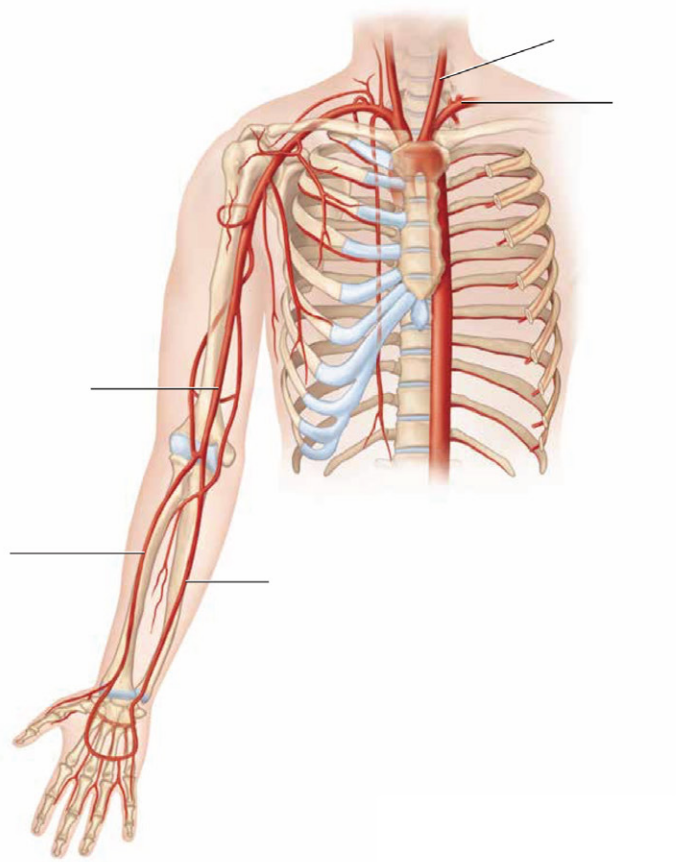

FIGURE **18.27** Arteries of the upper and lower limb.

Name _____

Section _____ Date _____

3 Label the following arteries in Figure 18.28.

- ❑ Celiac trunk
- ❑ Common hepatic artery
- ❑ Common iliac artery
- ❑ External iliac artery
- ❑ Inferior mesenteric artery
- ❑ Renal artery
- ❑ Splenic artery
- ❑ Superior mesenteric artery

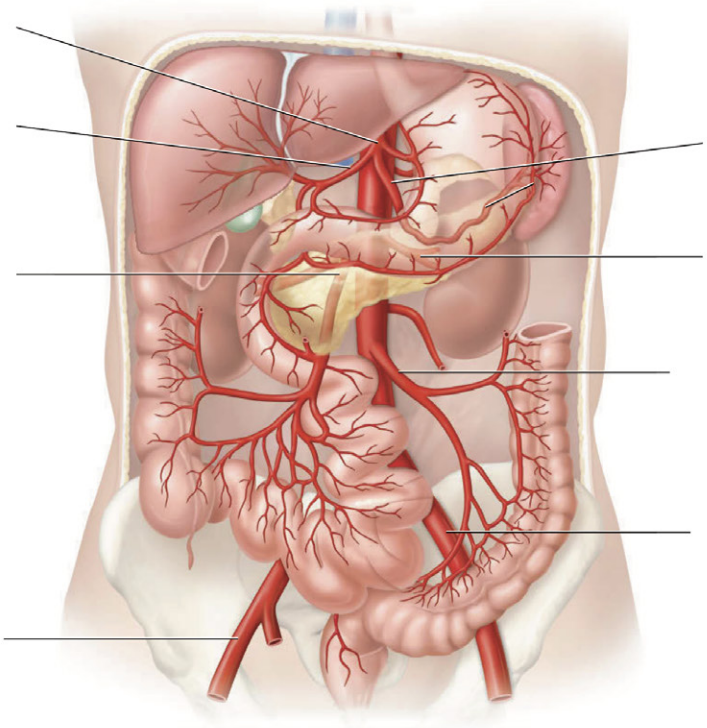

FIGURE **18.28** Arteries of the abdomen.

4 Label the following veins on Figure 18.29.

- ❑ Brachiocephalic vein
- ❑ External jugular vein
- ❑ Inferior sagittal sinus
- ❑ Internal jugular vein
- ❑ Subclavian vein
- ❑ Superior sagittal sinus
- ❑ Vertebral vein

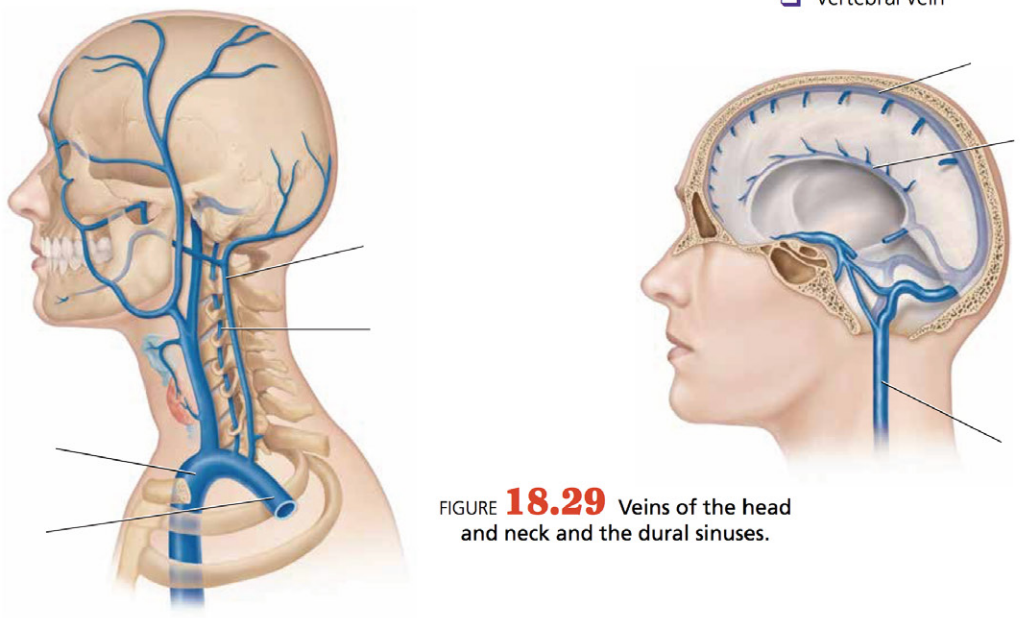

FIGURE **18.29** Veins of the head and neck and the dural sinuses.

5 Label the following veins on Figure 18.30.

- ❑ Axillary vein
- ❑ Basilic vein
- ❑ Brachial vein
- ❑ Cephalic vein
- ❑ External iliac vein
- ❑ Femoral vein
- ❑ Great saphenous vein
- ❑ Internal iliac vein
- ❑ Median cubital vein
- ❑ Popliteal vein

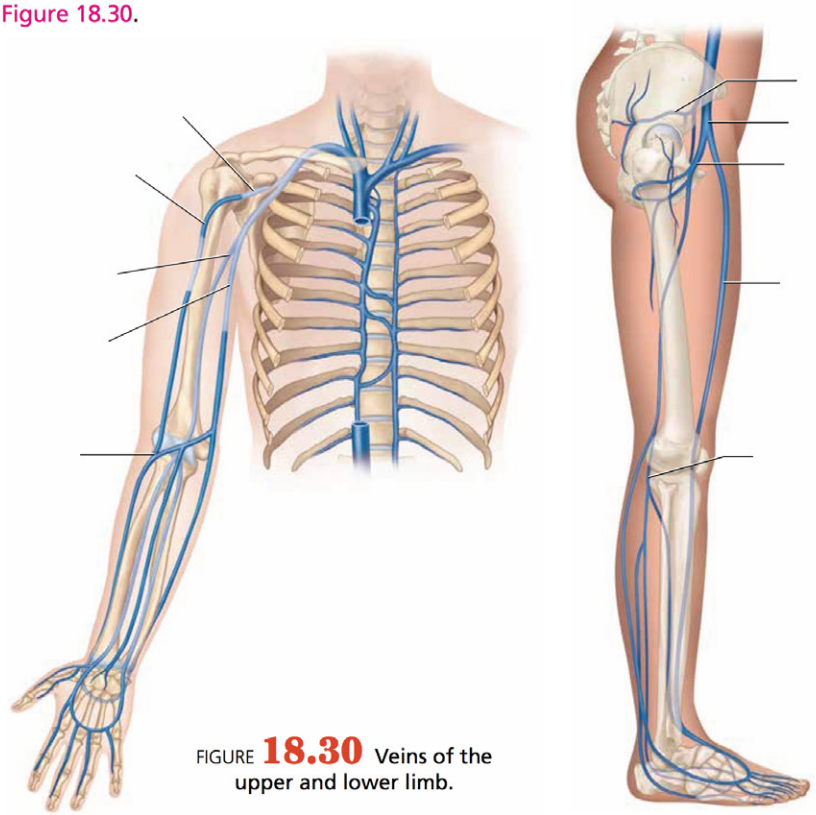

FIGURE **18.30** Veins of the upper and lower limb.

Name _____

Section _____ Date _____

6 Label the following veins on Figure 18.31.

- ❑ Common iliac vein
- ❑ Hepatic portal vein
- ❑ Hepatic veins
- ❑ Inferior mesenteric vein
- ❑ Left gastric vein
- ❑ Renal veins
- ❑ Splenic vein
- ❑ Superior mesenteric vein
- ❑ Suprarenal vein

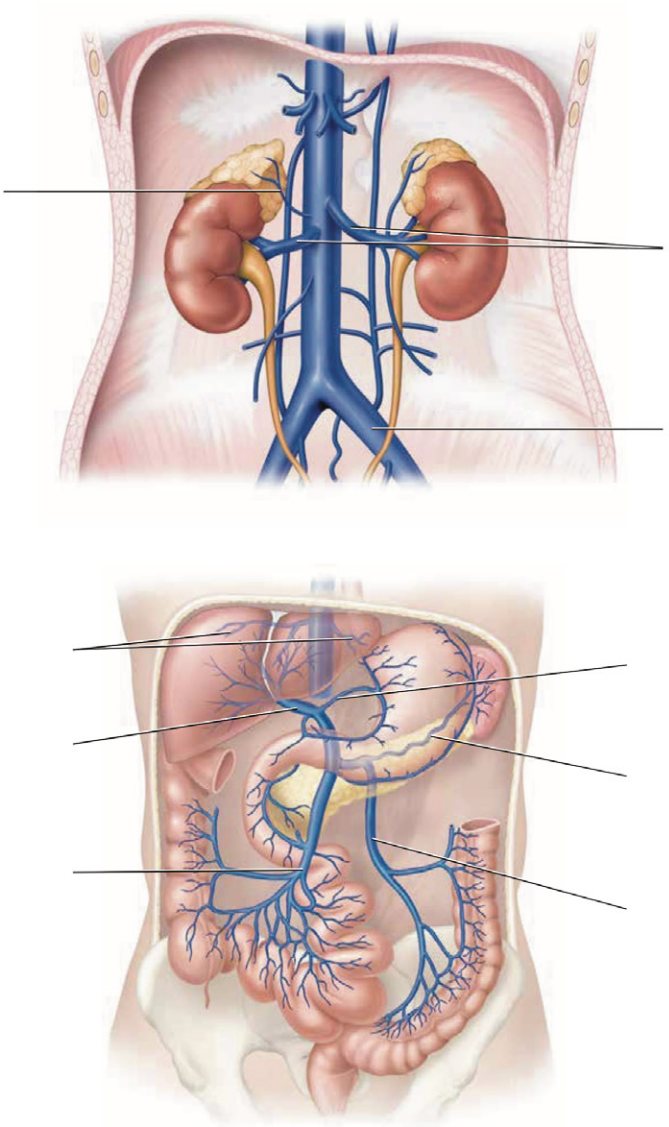

FIGURE **18.31** Veins of the abdomen.

7 *True/False:* Mark the following statements as true (T) or false (F). If the statement is false, correct it to make it a true statement.

_____ a. The three major circuits of blood flow in the body are the systemic, cerebral, and pulmonary circuits.

_____ b. The external carotid arteries and vertebral arteries supply blood to the brain.

_____ c. Blood is drained from the brain by a set of dural sinuses.

_____ d. Venous blood from the spleen, digestive tract, and pancreas drains into the inferior vena cava.

8 What is the purpose of the hepatic portal system?

_____

_____

9 The middle layer of the blood vessel wall is the _____ and contains _____.

a. tunica interna; smooth muscle
b. tunica externa; endothelium
c. tunica media; endothelium
d. tunica interna; endothelium
e. tunica media; smooth muscle

10 Which of the following is not a common pulse point?

a. Subclavian artery.
b. Femoral artery.
c. Brachial artery.
d. Dorsalis pedis artery.

Name _____

Section _____ Date _____

REVIEW

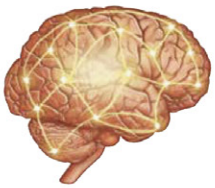

Check Your Understanding

Critical Thinking and Application Questions

1 David has an ultrasound of his common carotid arteries, which shows that his right common carotid artery is nearly 90 percent blocked. He wonders how the right side of his brain is getting enough blood if this artery is so occluded. What do you tell him?

2 Your patient presents with severe abdominal pain. Your team orders a CT scan and discovers a large blood clot lodged in the celiac trunk. What organs could this blood clot potentially affect? Why do you think the clot is causing abdominal pain?

3 Certain drugs cannot be taken by mouth because the entire dose of the drug is destroyed in the liver before it ever reaches the general circulation. Explain why these same drugs can be given by injection, either intravenously or intramuscularly. (***Hint:*** Consider the hepatic portal system.)

4 A blood clot that forms along the wall of a blood vessel is called a *thrombus*. An *embolus* is piece of a thrombus that breaks off and flows through the blood until its gets stuck in a small blood vessel downstream from the original thrombus.

a Trace the pathway an embolus that broke off from a thrombus in the femoral artery would take (assume it gets stuck in arterioles, before it reaches capillary beds):

b Trace the pathway an embolus that broke off from a thrombus in the femoral vein would take (assume it gets stuck in arterioles, before it reaches capillary beds):

5 Yasmin was diagnosed with an abdominal aortic *aneurysm*, which means that part of the wall of her abdominal aorta was ballooning out abnormally. Her physician performed surgery to correct the aneurysm, and sent a sample of the vessel wall to pathology. The pathology report stated that that Yasmin's tunica media had very few elastic fibers, and her tunica externa had few collagen fibers. How does this explain why she developed the aneurysm?

6 You are working as a medic at a gymnastics competition, and one of the gymnasts has a bad landing after a vault, injuring her leg. Her leg is bent at an awkward angle and her tibia and fibula are obviously fractured. You palpate her posterior tibial and dorsalis pedis pulses on her non-injured limb and they are 2/4. However, on her injured limb, they are 0/4. You also notice that her injured limb is becoming pale and cold to the touch distal to the injury. What has likely happened? Explain.

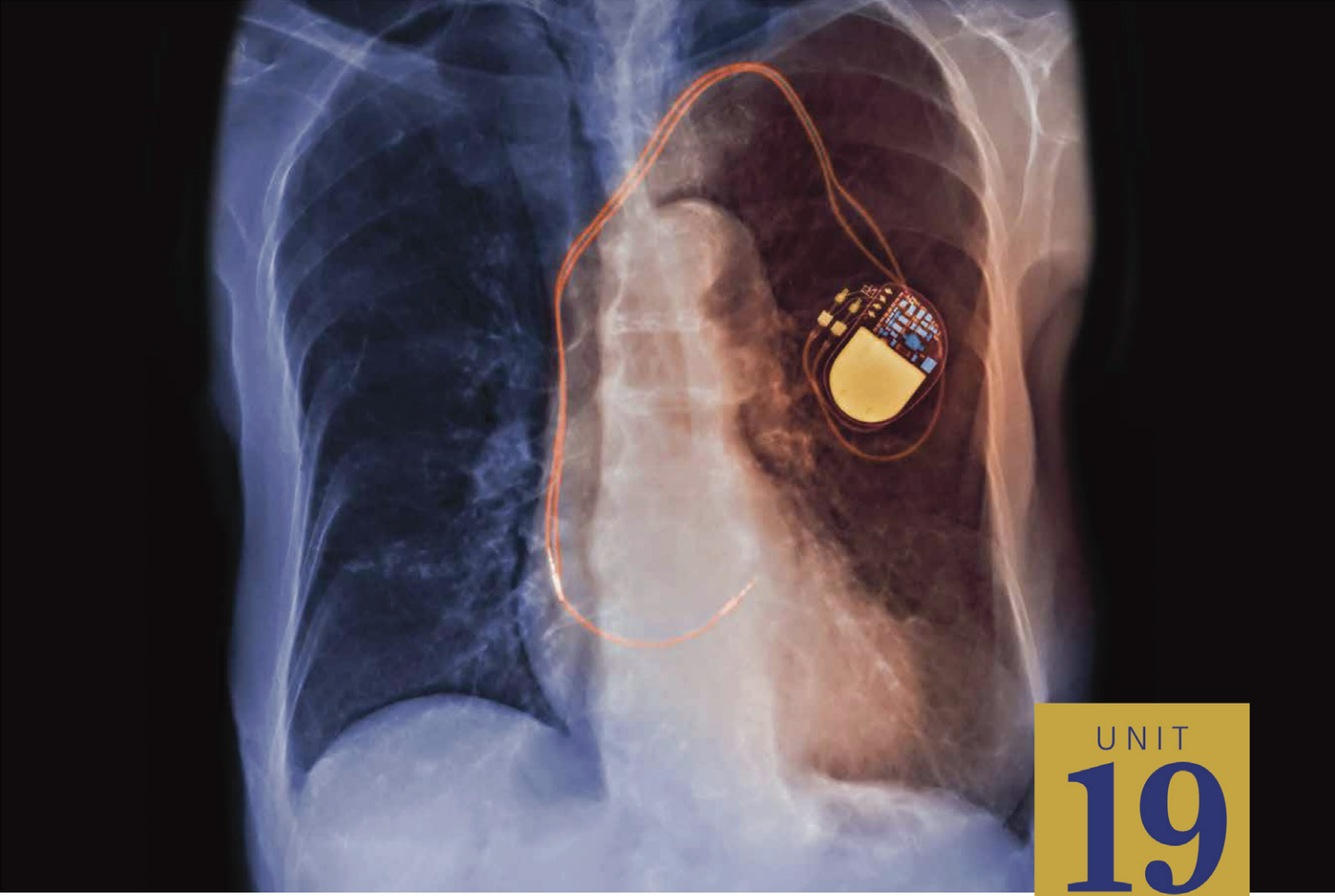

UNIT
19

Cardiovascular System—Part III: Cardiovascular Physiology

Once you have completed this unit, you should be able to:

1. Auscultate the sounds of the heart.
2. Describe and demonstrate common physical examination tests of the blood vessels.
3. Measure blood pressure using a stethoscope and a sphygmomanometer.
4. Describe the effects of the autonomic nervous system on blood pressure and pulse rate.
5. Measure and interpret the ankle-brachial index using a Doppler ultrasound device.
6. Describe the cardiac conduction system, and correlate the electrical activity of the heart with the waves and intervals on an ECG.

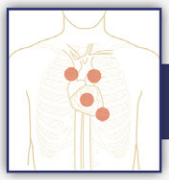

Name _____ Section _____ Date _____

PRE-LAB EXERCISES

Complete the following exercises prior to coming to lab, using this lab manual and your textbook for reference.

Pre-Lab Exercise 19-1



Key Terms

You should be familiar with the following terms before coming to lab.

Term	Definition

Heart Sounds and Pulses

Auscultation _____

S1 _____

S2 _____

Tachycardia _____

Bradycardia _____

Pulse point _____

19

Blood Pressure

Systolic pressure _____

Diastolic pressure _____

Sounds of Korotkoff _____

Electrophysiology

Sinoatrial node _____

Name _____ Section _____ Date _____

Atrioventricular node _____

Purkinje fiber system _____

Electrocardiogram _____

P wave _____

QRS complex _____

T wave _____

Dysrhythmia _____

Pre-Lab Exercise 19-2



Autonomic Nervous System and the Cardiovascular System

As you learned in Exercise 14-4 (pp. 381–382), the autonomic nervous system (ANS) has profound effects on other body systems and overall homeostasis. The cardiovascular system is no exception, which you will see in this unit's exercises. Fill in Table 19.1 with the basic effects of the two divisions of the ANS to refresh your memory.

TABLE **19.1** Effects of the Divisions of the ANS

Organ	Sympathetic Nervous System Effects	Parasympathetic Nervous System Effects
Heart		
Blood vessels serving skin and abdominal viscera		
Net effect on blood pressure		
Lungs (bronchial smooth muscle)		
Metabolic rate		
Urinary functions		
Digestive functions		

Color-enhanced X-ray of an implantable cardioverter-defibrillator, or pacemaker.

EXERCISES

Every physical examination includes an assessment of the cardiovascular system, in which the heart rate is counted, heart sounds are auscultated, and the blood pressure is measured. In this unit you will perform these and other common tests and learn how they are interpreted. You will also determine the effects of the autonomic nervous system on these measurements and examine the electrocardiogram.

Exercise 19-1

Heart Auscultation

MATERIALS

- ❑ Stethoscope
- ❑ Alcohol and cotton swab

Heart sounds are produced by the closing of valves at certain points during the cardiac cycle. The first heart sound, called **S1**, is caused by simultaneous closure of the mitral and tricuspid valves when the ventricles begin to contract during *isovolumetric contraction*. The second heart sound, called **S2**, is caused by simultaneous closure of the aortic and pulmonary valves as the ventricles begin to relax during *isovolumetric relaxation*.

The process of listening to heart sounds is known as **auscultation** (aws-kuhl-TAY-shun). Heart sounds typically are auscultated in four areas, each of which is named for the valve that is best heard at that specific location. The position of each area is described relative to the sternum and the spaces between the ribs, known as *intercostal spaces*. The first intercostal space is located between the first and second rib, which is roughly inferior to the clavicle. From the clavicle you can count down to consecutive spaces to auscultate in the appropriate areas. The four areas, shown in Figure 19.1, are as follows:

1. **Aortic area.** The **aortic area** is the location where the sounds of the aortic valve are best heard. It is located in the second intercostal space (between ribs two and three) at the right sternal border (to the right of the sternum).
2. **Pulmonic area.** The pulmonary valve is best heard over the **pulmonic area,** which is located at the second intercostal space at the left sternal border.
3. **Tricuspid area.** The sounds produced by the tricuspid valve are best heard over the **tricuspid area,** which is found in the fourth intercostal space at the left sternal border.
4. **Mitral area.** The **mitral area** is located in the fifth intercostal space at the left midclavicular line (draw an imaginary line down the middle of the clavicle).

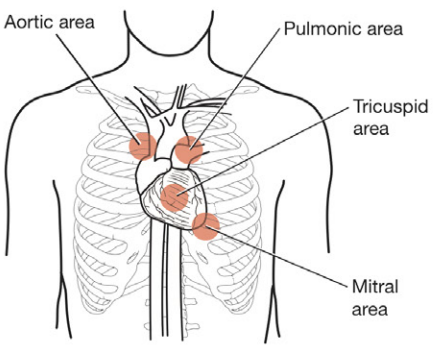

FIGURE **19.1** Areas of auscultation.

The following variables are evaluated during heart auscultation.

- **Heart rate.** The heart rate refers to the number of heartbeats per minute. If the rate is more than 100, it is termed **tachycardia** (tak-ih-KAR-dee-uh). If the rate is below 60 beats per minute, it is termed **bradycardia** (bray-dih-KAR-dee-uh).
- **Heart rhythm.** The heart's **rhythm** refers to the pattern and regularity with which it beats. Some rhythms are *regularly irregular*, in which the rhythm is irregular but still follows a defined pattern. Others are *irregularly irregular*, in which the rhythm follows no set pattern.
- **Additional heart sounds.** Sometimes sounds in addition to S1 and S2 are heard, which could be a sign of pathology. These sounds are called **S3**, which occurs just after S2, and **S4**, which occurs immediately prior to S1.
- **Heart murmur.** A heart **murmur** is a clicking or "swooshing" noise heard between the heart sounds. Murmurs are caused by a valve leaking, called **regurgitation**, or by a valve that has lost its pliability, called **stenosis** (sten-OH-sis).

Heart sounds are auscultated with a **stethoscope** (STETH-oh-skohp), which you will use in this unit. Most stethoscopes contain the following parts (Fig. 19.2):

- **Earpieces** are gently inserted into the external auditory canal and allow you to auscultate the heart sounds.
- The **diaphragm** is the broad, flat side of the end of the stethoscope. It is used to auscultate higher-pitched sounds and is the side used most often in auscultation of heart sounds.
- The **bell** is the concave, smaller side of the end of the stethoscope. It is used to auscultate lower-pitched sounds.

FIGURE **19.2** Stethoscope.

Note that sounds are not audible through both the bell and the diaphragm at the same time. Typically, the end can be flipped from one side to the other by simply turning it clockwise or counterclockwise. Before auscultating with either side, lightly tap the end to ensure that you can hear sound through it. If the sounds are faint or muted, turn the end to the other side and try again. If the end of your stethoscope has only one side (the diaphragm), it works slightly differently. In these stethoscopes, placing light pressure on the end as you are auscultating yields sounds associated with the diaphragm, while placing heavier pressure yields sounds associated with the bell. If you are trying to auscultate with the diaphragm and the sounds are faint, try decreasing the amount of pressure you are placing on the end. When you have completed the procedure, answer Check Your Understanding question 1 (p. 527).

Procedure 1 Heart Auscultation

1. Obtain a stethoscope and clean the earpieces and diaphragm with alcohol and cotton swabs.
2. Place the earpieces in your ears and gently tap the diaphragm to ensure that it is on the proper side. If it is not, flip it to the other side.
3. Lightly place the diaphragm on your partner's chest in the aortic area. (***Note:*** You may wish to have your lab partner place the stethoscope on his or her chest under the shirt, as the sounds are heard best on bare skin.)
4. Auscultate several cardiac cycles and determine which sound is S1 and which sound is S2.
5. Measure the heart rate by counting the number of beats for 15 seconds and multiplying by four. Also note the rhythm, and whether it is regular, regularly irregular, or irregularly irregular. Finally, note the presence of any extra heart sounds or murmurs.
6. Record your results in Table 19.2.
7. Move on to the next area, and repeat.

TABLE **19.2** Heart Auscultation Results

Area	Rate	Rhythm	Extra Heart Sounds? (yes/no)	Murmurs Present? (yes/no)
Aortic area				
Pulmonic area				
Tricuspid area				
Mitral area				

Exercise 19-2

Vascular Examination

MATERIALS

- ❑ Stethoscope
- ❑ Alcohol and cotton swab

A vascular examination is the portion of a physical examination that assesses the health of the blood vessels. You performed one common test, pulse palpation, in the blood vessels unit. Two other common tests include auscultation of vessels to check for noises called **bruits** (broo-eez) and measuring the time it takes for capillary beds to refill. Each of these procedures is outlined in the sections that follow.

Procedure 1 Auscultating Carotid Bruits

Vascular disease in large vessels may lead to turbulent blood flow through the vessel, producing a bruit. Here we will auscultate for bruits in the carotid arteries.

1. Obtain a stethoscope and switch from the diaphragm to the bell. Clean the earpieces and bell with alcohol and cotton swabs.
2. Place the earpieces in your ears and gently tap the bell to ensure that it is on the proper side. If it's not, flip it to the other side. If your stethoscope has only one side, recall that you will have to use slightly heavier pressure to hear the sounds associated with the bell.
3. Palpate the carotid pulse (remember to palpate only one carotid artery at a time) and place the bell over it. Auscultate for bruits, which sound like a "swooshing" sound with each heartbeat.
4. Repeat the process for the other carotid artery.
5. Were bruits present in either side? _____

Procedure 2 Measuring Capillary Refill Time

Blood flows through arteries, which branch into successively smaller arteries until they branch into arterioles. Arterioles then feed **capillary beds**, known collectively as the **microcirculation**, where gas, nutrient, and waste exchange takes place (Fig. 19.3). Capillary beds are then drained by venules, which merge to form veins. Notice that capillary beds form interweaving networks. This creates a large surface area for the rapid exchange of substances that occurs across capillary walls.

The amount of blood that flows to a tissue through capillary beds is called *tissue perfusion*. A tissue's perfusion is tightly regulated—if it's too low, the cells will get insufficient oxygen and nutrients and may die, and if it's too high, the high pressure in the capillaries can force excess water out of the blood and into the interstitial fluid.

A simple way to assess tissue perfusion in the clinic is by measuring the **capillary refill time**, which is the time

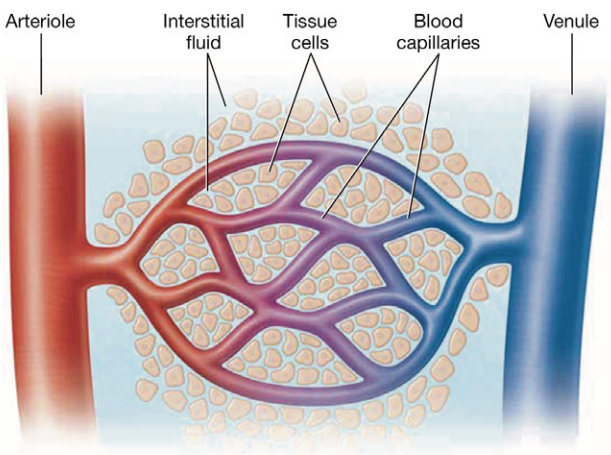

FIGURE **19.3** Structure of a capillary bed.

it takes for capillary beds to refill after they have been forcibly emptied by pressure. This standard physical examination test is done to evaluate a patient for a variety of vascular diseases, particularly arterial disease. A normal capillary refill time measures 1–3 seconds; a value greater than 3 seconds may signify some sort of pathology (but be aware that it may also just mean that the patient is cold). Measure the capillary refill time for each of your lab partner's digits in the procedure outlined below. When you have completed the activity, answer Check Your Understanding question 2 (p. 527).

1. Squeeze the end of the fingertip over the fingernail until the fingernail bed blanches (turns white).
2. Release the fingernail and count the number of seconds it takes for the fingernail bed to return to a pinkish color (note that this may occur immediately, in which case simply record it as 1 second).
3. Repeat for each fingertip of each hand, and record your results in Table 19.3.

TABLE **19.3** Capillary Refill Times

Digits: Right Hand	Refill Time	Digits: Left Hand	Refill Time
1 (thumb)		1 (thumb)	
2		2	
3		3	
4		4	
5		5	

Exercise 19-3

Blood Pressure

MATERIALS

- ❑ Sphygmomanometer
- ❑ Stethoscope
- ❑ Alcohol and cotton swab
- ❑ Bucket of ice water

Blood pressure is defined as the pressure exerted by the blood on the walls of the blood vessels. It is determined by the following three factors:

1. **Cardiac output. Cardiac output** is the amount of blood each ventricle pumps in 1 minute. It is a product of heart rate and **stroke volume**, or the amount of blood pumped with each beat.
2. **Peripheral resistance. Resistance** is defined as any impedance to blood flow encountered in the blood vessels. It is determined largely by the degree of **vasoconstriction** or **vasodilation** in the systemic circulation. Vasoconstriction increases resistance, and vasodilation has the opposite effect. Other factors that influence resistance include obstructions such as atheromatous plaques within the arteries. Resistance is highest away from the heart in the body's periphery, so it is often called **peripheral resistance**.
3. **Blood volume.** The amount of blood found in the blood vessels at any given time is known as the **blood volume**. It is greatly influenced by overall fluid volume and is largely controlled by the kidneys and hormones of the endocrine system.

Note that cardiac output and peripheral resistance are factors that can be altered quickly to change blood pressure. Alterations to blood volume, however, occur relatively slowly and generally require several hours to days to have a noticeable effect.

Arterial blood pressure is measured clinically and experimentally using instruments called a **sphygmomanometer** (sfig-moh-muh-NAH-muh-ter) and a stethoscope. This procedure yields two pressure readings:

1. **Systolic pressure.** The pressure in the arteries during the period of ventricular contraction, called **ventricular systole** (SIS-toh-lee), is known as the **systolic pressure** (sis-TAHL-ik). This is the larger of the two readings, averaging between 100 and 120 mmHg.
2. **Diastolic pressure.** The pressure in the arteries during ventricular relaxation, or **ventricular diastole** (dy-AEH-stoh-lee), is the **diastolic pressure** (dy-uh-STAHL-ik). This is the smaller of the two readings, averaging between 60 and 80 mmHg.

Arterial blood pressure is measured by placing the cuff of the sphygmomanometer around the upper arm. When the cuff is inflated, it compresses the brachial artery and cuts off blood flow. When the pressure is released to the level of the systolic arterial pressure, blood flow through the brachial artery resumes but is turbulent. This results in noises known as **Korotkoff sounds** (koh-ROT-koff), which may be auscultated with a stethoscope.

Procedure 1 Measuring Blood Pressure

Practice is necessary to develop the skills to accurately measure arterial blood pressure. Following are the steps that you may use to practice using the sphygmomanometer and stethoscope together, which is shown in Figure 19.4. All readings should be taken with your lab partner seated and relaxed. When you have completed the activity, answer Check Your Understanding question 3 (p. 527).

1. Obtain a stethoscope and sphygmomanometer of the appropriate size (about 80 percent of the circumference of the arm).
2. Clean the earpieces and diaphragm as in Exercise 19-1.
3. Wrap the cuff around your partner's arm. It should not be noticeably tight, but it should stay in place when you are not holding it. It should be about 1½ inches proximal to the antecubital fossa.
4. Place the stethoscope in your ears and tap the end gently to ensure that it is on the diaphragm side. Palpate for your partner's brachial pulse in the antecubital fossa. When you find it, set the diaphragm of your stethoscope

over the pulse. You will *not* hear anything through the stethoscope at this point.

5 Support your partner's arm by cradling it in your arm, or have your partner rest his or her arm on the lab table.

6 Locate the screw of the sphygmomanometer near the bulb, and close it by turning it clockwise. Inflate the cuff by squeezing the bulb several times. Pay attention to the level of pressure you are applying by watching the pressure gauge. Do not inflate it beyond about 30 mmHg above your partner's normal systolic pressure (for most people, this is no higher than 180 mmHg). Your lab partner will not likely be happy with you if you inflate it above about 200 mmHg, as this can be uncomfortable.

7 Slowly open the screw by turning it counterclockwise. Watch the pressure gauge, and listen to the brachial artery with your stethoscope.

8 Eventually you will see the needle on the pressure gauge begin to bounce; at about the same time, you will begin to hear the pulse in the brachial artery. The pressure you read at that moment should be recorded as the systolic pressure.

FIGURE **19.4** Measuring blood pressure.

9 Continue to listen and watch the gauge. Eventually, the sound of the pulse will become softer and then finally stop (at this point the needle usually stops bouncing, too). Record the pressure reading from when the sound ends as the diastolic pressure. The numbers should be recorded as a fraction (e.g., 110/70, where 110 is the systolic pressure and 70 is the diastolic pressure).

10 Take your partner's blood pressure twice, and record both readings here:

Blood pressure 1: _____

Blood pressure 2: _____

19

Procedure 2 Measuring the Effects of the Autonomic Nervous System on the Blood Pressure and Heart Rate

The autonomic nervous system (ANS) exerts a great deal of control over blood pressure through its influence on cardiac output, peripheral resistance, and blood volume. Recall that the two divisions of the ANS are the sympathetic nervous system (SNS) and the parasympathetic nervous system (PSNS).

The SNS is the "fight or flight" branch that helps the body to maintain homeostasis during situations such as exercise, emotion, and emergency. Its neurons release norepinephrine onto cardiac muscle cells to increase the rate and force of their contraction, which increases cardiac output. They also release norepinephrine onto the smooth muscle cells lining the walls of blood vessels, which triggers most blood vessels to constrict (note that some blood vessels, such as those serving skeletal muscles, dilate). This vasoconstriction increases peripheral resistance. The combined effect of increased cardiac output and peripheral resistance leads to an increase in blood pressure.

The PSNS is the "rest and digest" branch of the ANS that helps the body to maintain homeostasis in between those bursts of sympathetic activity. As you might expect, the PSNS has the opposite effects on blood pressure as from the SNS. Parasympathetic neurons release acetylcholine onto cardiac muscle cells and slow the heart rate, which decreases cardiac output. The vast majority of blood vessels aren't innervated by PSNS neurons; however, blood vessels do dilate when

sympathetic stimulation stops. So indirectly, vasodilation occurs when PSNS activity increases, which decreases peripheral resistance. Together, the decreased cardiac output and peripheral resistance cause a decrease in blood pressure.

Here we will witness the effects of the ANS on blood pressure, although we are limited to measuring the effects on cardiac output and peripheral resistance. When you have completed this activity, answer Check Your Understanding questions 4 and 5 (pp. 527–528).

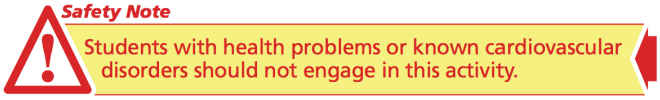

1. Have your lab partner remain seated and relaxed for 3 minutes. After 3 minutes, measure your partner's pulse rate by palpating the radial artery and counting the number of beats. Then, take your partner's blood pressure. Record these data in Table 19.4.
2. Have your partner place one hand into a bucket of ice water.
3. Repeat the blood pressure and pulse measurements with your partner's hand still in the ice water. (***Note:*** Be kind to your partner and do this quickly!) Record these data in Table 19.4.
4. Have your partner remove the hand from the ice water.
5. Wait 5 minutes, and then repeat the blood pressure and pulse measurements. Record these data in Table 19.4.

TABLE **19.4** Blood Pressure and Pulse Readings: Ice Water Experiment

Test Situation	Blood Pressure	Pulse Rate
At rest		
After immersing in ice water		
5 minutes after removing from ice water		

6. Interpret your results:
   a. In which situation(s) was the sympathetic nervous system dominant? How can you tell?

   b. In which situation(s) was the parasympathetic nervous system dominant? How can you tell?

Exercise 19-4

The Ankle–Brachial Index

MATERIALS

- ❑ Doppler ultrasound device
- ❑ Sphygmomanometer
- ❑ Stethoscope
- ❑ Alcohol and cotton swab
- ❑ Ultrasound gel

Peripheral artery disease (**PAD**), also called *peripheral vascular disease*, is any disease of the arteries outside of the brain and coronary circuit. Although any of these vessels can be affected, it is the arteries of the lower limbs that tend to show the most symptoms of the disease. There are many risk factors for PAD; some of the most common include poorly controlled diabetes mellitus, atherosclerosis, cigarette smoking, and hypertension.

The **ankle–brachial index** (**ABI**) is a test that is used to assess the severity of PAD. The ABI compares the systolic blood pressure in the legs (the "ankle" portion) to the systolic blood pressure in the arms (the "brachial" portion). If an individual has PAD, the ankle pressure is generally much lower than the brachial pressure, which reflects the fact that less blood is flowing to the lower limbs.

The ABI is obtained by dividing the systolic pressure in the ankle by the systolic pressure in the arm. Typically, the ABI is a decimal number because ankle pressure is slightly lower than the brachial pressure. This is because the legs are farther from the heart than the arms, which causes a slight decline in blood pressure. Interpretation of the ABI is as follows:

- 0.9–1.0 = normal
- 0.5–0.9 = peripheral artery disease
- 0.2–0.5 = intermittent claudication (temporary blockages to blood flow)
- <0.2 = severe disease causing death of tissue

Note that in younger or more athletic persons, the ABI is often greater than 1. This is simply a result of more muscle mass in the lower limb, which is difficult to completely compress with a sphygmomanometer cuff. This falsely elevates the ankle pressure, and so it appears higher than the brachial pressure.

Procedure 1 Ankle-Brachial Index

You cannot easily auscultate either of the pedal pulses with a stethoscope, so a Doppler ultrasound device is used to hear the blood flow instead (Fig. 19.5). A Doppler ultrasound device uses sound waves transmitted through a liquid medium (ultrasound gel) to produce audible sounds of the blood flowing through the vessel. Following is the procedure for measuring the ankle pressure:

1. Take your partner's brachial pressure in the standard way with a sphygmomanometer and a stethoscope. Record *only* the systolic pressure on the answer blank in step 7.
2. Wrap the sphygmomanometer cuff around the ankle.
3. Palpate either the dorsalis pedis or the posterior tibial pulses—use whichever is easiest to find and strongest.
4. Place a small amount of ultrasound gel over the pulse. Place the Doppler probe in the gel so it is lightly touching the skin. (***Note:*** If you press too hard with the probe, it is possible to cut off blood flow. If you do this, you will hear no sound.)
5. When you can hear sounds of the blood flowing, hold the probe in place as your lab partner inflates the sphygmomanometer cuff. Continue to inflate the cuff until you no longer hear any sound. At this point, the pressure of the cuff has cut off blood flow through the vessel.

FIGURE **19.5** Performing the ankle-brachial index.

6 Have your lab partner slowly deflate the cuff while you continue to hold the probe in place and watch the pressure gauge. Record the pressure at which you first hear the blood flowing again on the answer blank in step 7. Note that this is a systolic pressure only; you will not obtain a diastolic pressure for the ankle.

7 Calculate the ABI by dividing the systolic pressure of the ankle by the systolic pressure of the arm. You most likely will get a decimal number, and this is your ABI.

Systolic pressure of the ankle: _____

Systolic pressure of the arm (brachial): _____

Ankle pressure/Brachial pressure: _____

Exercise 19-5

The Electrocardiogram

Within the heart we find two populations of cardiac muscle cells: *pacemaker cells*, which account for about 1 percent of the total cells of the heart, and *contractile cells*, which make up the remainder. Pacemaker cells are unique because they rhythmically, spontaneously depolarize and have action potentials. It is their depolarizations that trigger the contractile cells to depolarize and have action potentials. There are three groups of pacemaker cells (Fig. 19.6):

- **Sinoatrial node.** We find the cells of the **sinoatrial node** (sy-noh-AY-tree-uhl), or **SA node,** in the superior portion of the right atrium. The SA node depolarizes about 60 times per minute and is the normal pacemaker of the heart.
- **Atrioventricular node.** The next cluster of pacemaker cells is collectively called the **atrioventricular node**, or **AV node,** which is located posterior and medial to the tricuspid valve. It depolarizes about 40 times per minute and acts as a backup pacemaker should the SA node stop pacing the heart.
- **Purkinje fiber system.** The final series of pacemaker cells is a group that is collectively called the **Purkinje fiber system** (pur-KIN-jee). The system begins with an **atrioventricular bundle** (**AV bundle**) in the inferior interatrial septum and the superior interventricular septum. The AV bundle then splits into the **right** and **left bundle branches**, which run down the right and left sides of the interventricular septum, respectively. Near the apex of the heart, the bundle branches split into the **terminal branches**, which fan out through the ventricles and contact ventricular contractile cells.

Together, these three groups of pacemaker cells make up what is known as the **cardiac conduction system**. This system is named as such because it represents a sort of "hardwiring" of the heart. It allows depolarizations from pacemaker cells to spread extremely rapidly to other pacemaker cells and to contractile cells. You can see in Figure 19.6 how action potentials are spread through the heart:

1. The cells of the SA node depolarize; these depolarizations spread through the atria via specialized *atrial conducting fibers*, and the atrial contractile cells depolarize.
2. The impulse reaches the AV node as the atrial cells complete their action potentials and contract. Conduction slows at the AV node, a phenomenon known as the *AV node delay*, which allows the atria to depolarize and contract before the ventricles depoarize and contract.

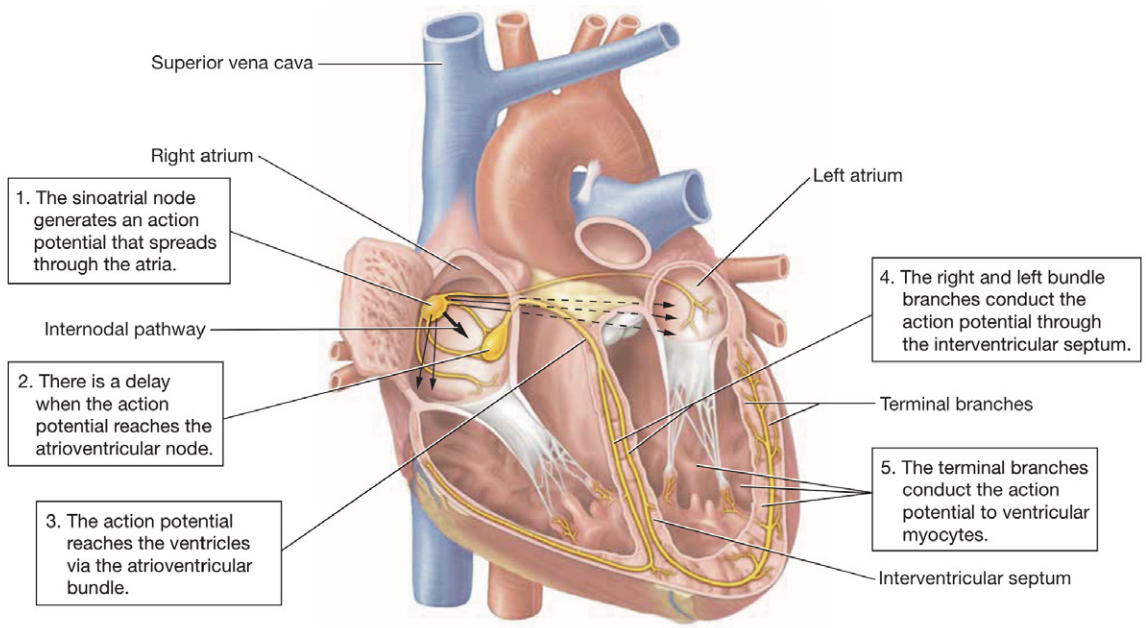

FIGURE **19.6** Anatomy of the cardiac conduction system.

3. The depolarization next propagates along the Purkinje fiber system, first along the AV bundle.
4. The depolarization spreads down either side of the interventricular septum along the right and left bundle branches.
5. The terminal branches trigger contractile cells of the ventricles to depolarize, have action potentials, and contract.

The electrical activity of the heart can be examined by taking an **electrocardiogram**, or **ECG**, which is a recording of the changes that occur in the electrical activity of cardiac muscle cells over a period of time. Electrical activity is recorded by placing electrodes on the surface of the skin that record the changes in electrical activity. The changes in electrical activity are visible on the ECG as **waves**. Note that if there is no *net* change in electrical activity, the line on the ECG is flat. However, even when the ECG is flat between waves, the cells of the heart are in some phase of an action potential. Also note that the ECG appears flat during pacemaker cell action potentials. This is because there are so few pacemaker cells in the heart that their activity isn't detectable with a standard ECG.

A standard ECG recording is shown in Figure 19.7. Notice that it consists of five waves, each of which represents the depolarization or repolarization of different parts of the heart.

- **P wave.** The initial **P wave** shows the depolarization of the cells of the right and left atria. It is fairly small because of the small number of cells in the atria. Note that the flat segment right before the P wave is when the SA node depolarization takes place.
- **QRS complex.** The **QRS complex** is actually a set of three waves that represent the depolarization of the right and left ventricles. The first wave is the **Q wave**, a downward deflection, the next is the **R wave**, a large upward deflection, and the last is the **S wave**, the final downward deflection. The large size of the QRS complex compared with the P wave results from the large number of ventricular cells.
- **T wave.** The small **T wave** is usually the final wave, and it represents the repolarization of the right and left ventricles.

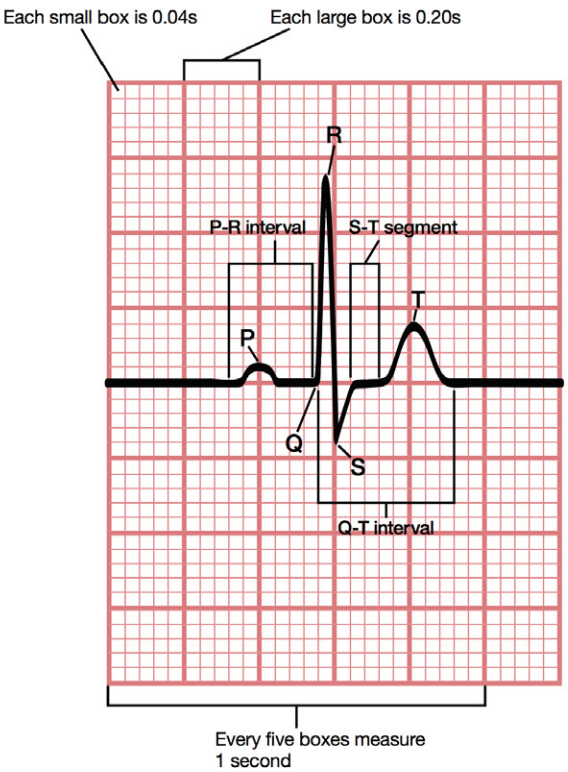

FIGURE **19.7** Standard ECG recording.

19

The waves aren't the only important landmarks of the ECG. In addition, we consider the periods between the waves, which show the spread of electrical activity through the heart and phases of the contractile cells' action potentials. We look at two types of periods: intervals, which include one or more waves in the measurement, and segments, which do not include waves in the measurement.

One important interval is the **R-R interval**, or the period of time between two R waves. This interval represents the duration of the generation and spread of an action potential through the heart. It can be used to determine the heart rate, which we discuss shortly. Another interval we examine is the **P-R interval**, defined as the period from the beginning of the P wave to the beginning of the QRS complex. During the P-R interval, the depolarization from the SA node spreads through the atria to the ventricles via the AV node; this interval includes the AV node delay. A final key interval is the **Q-T interval**, the time from the beginning of the Q wave to the end of the T wave. During the Q-T interval, the ventricular cells are depolarizing and repolarizing.

An important segment that we examine is the **S-T segment**, which is between the end of the S wave and the beginning of the T wave. This segment is recorded during the ventricles' plateau phase. Recall that there is no net change in electrical activity during this phase, and for this reason, the S-T segment is generally flat.

The normal pattern seen on an ECG is known as a **normal sinus rhythm**, which means that the SA node is pacing the heart at a rate between 60 and 100 beats per minute. Any deviation from the normal sinus rhythm is known as a **dysrhythmia** or **arrhythmia**.

An electrocardiograph records the tracing at a standard speed of 25 mm/second. This allows us to determine precisely the heart rate and the duration of the intervals we discussed. As you can see in Figure 19.7, each small box on the ECG tracing measures 0.04s, and each large box measures 0.20s. Five large boxes together measure 1 second. Determining the duration of most intervals is simple—just count the small or large boxes, and add the seconds together. Calculating the heart rate is equally simple: count the number of large boxes, and divide 300 by this number. For example, if you count 4.2 boxes: 300/4.2 = 71 beats per minute. The normal values for the periods we discussed are given in Table 19.5.

TABLE **19.5** Normal Values for ECG Periods

Period	Normal Value
Heart rate	60–100 beats per minute
R-R interval	0.60–1.0s
P-R interval	0.12–0.20s
Q-T interval	0.42–0.44s
QRS complex duration	Less than or equal to 0.12s

Procedure 1 Identifying Waves of an ECG

Let's start by correlating the waves on the ECG with the electrical activity occurring in the heart. Identify the electrical events taking place in cardiac cells at each of the six points in the ECG in Figure 19.8, and explain the events in the answer lines provided. Do remember though that the ECG shows only *electrical* events, not mechanical events. A heart can have electrical activity but not be beating.

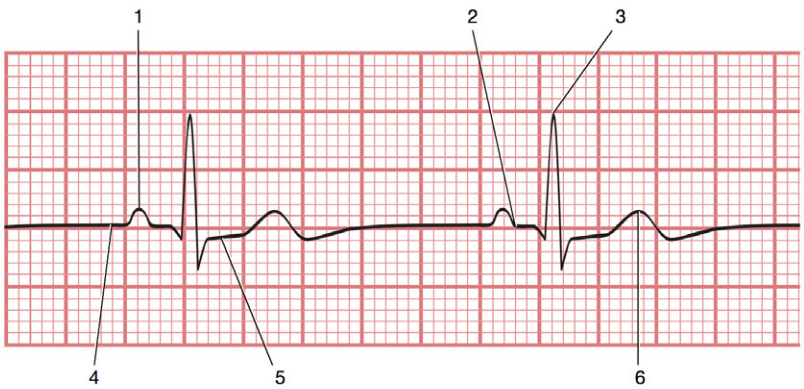

FIGURE **19.8** ECG tracing.

1 _____

2 _____

3 _____

4 _____

5 _____

6 _____

Procedure 2 Interpreting an ECG

Now that you understand what the wave forms on an ECG mean, you can perform some basic ECG interpretation. Following are two tracings for which you will calculate the heart rate and determine the duration of key intervals of the ECG. When you have completed the activity, answer Check Your Understanding question 6 (p. 528).

1 Identify and label the P wave, QRS complex, T wave, P-R interval, R-R interval, and Q-T interval on Tracings 1 and 2 in Figure 19.9.

Tracing 1

Tracing 2

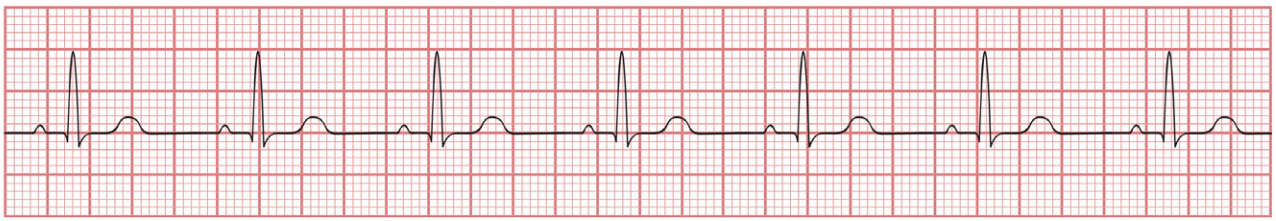

FIGURE **19.9** ECG tracings.

2 Calculate the heart rate for each tracing. Are the values normal or abnormal?

Heart Rate Tracing 1: _____

Heart Rate Tracing 2: _____

3 Determine the R-R interval, QRS duration, P-R interval, and Q-T interval for each tracing, and record the values in Table 19.6.

TABLE **19.6** Values for ECG Periods

Value	Tracing 1	Tracing 2
R-R interval		
QRS duration		
P-R interval		
Q-T interval		

Name _____

Section _____ Date _____

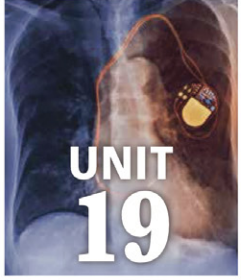

REVIEW

Check Your Recall

1 The heart sounds S1 and S2 are caused by

a. contraction of the ventricles.
b. closing of the atrioventricular and semilunar valves.
c. opening of the atrioventricular and semilunar valves.
d. contraction of the atria and the ventricles.

2 Which of the following terms refers to an abnormally elevated heart rate?

a. Tachycardia.
b. Murmur.
c. Dysrhythmia.
d. Bradycardia.

3 What takes place at capillary beds?

_____

_____

4 The amount of blood that flows to a tissue through capillary beds is called

a. bruits.
b. microcirculation.
c. tissue perfusion.
d. capillary refill.

5 *Fill in the blanks:* Blood pressure is determined by three factors: (1) _____, which is a product of heart rate and _____, or the amount of blood pumped with each beat; (2) _____, or any impedance to blood flow, which is determined largely by the degree of _____ or _____ in the systemic blood vessels; and (3) the _____.

6 The pressure in the arteries when the heart is contracting is the

a. cardiac pressure.
b. osmotic pressure.
c. diastolic pressure.
d. systolic pressure.

7 The actions of the sympathetic nervous system _____ blood pressure, and the actions of the parasympathetic nervous system _____ blood pressure.

a. increase; decrease
b. increase; increase
c. decrease; increase
d. decrease; decrease

8 The T wave on an ECG represents:

a. depolarization of the atria.
b. repolarization of the atria.
c. depolarization of the ventricles.
d. repolarization of the ventricles.

9 Label the parts of the cardiac conduction system on Figure 19.10.

- ❑ Atrioventricular bundle
- ❑ Atrioventricular node
- ❑ Left bundle branch
- ❑ Right bundle branch
- ❑ Sinoatrial node
- ❑ Terminal branches

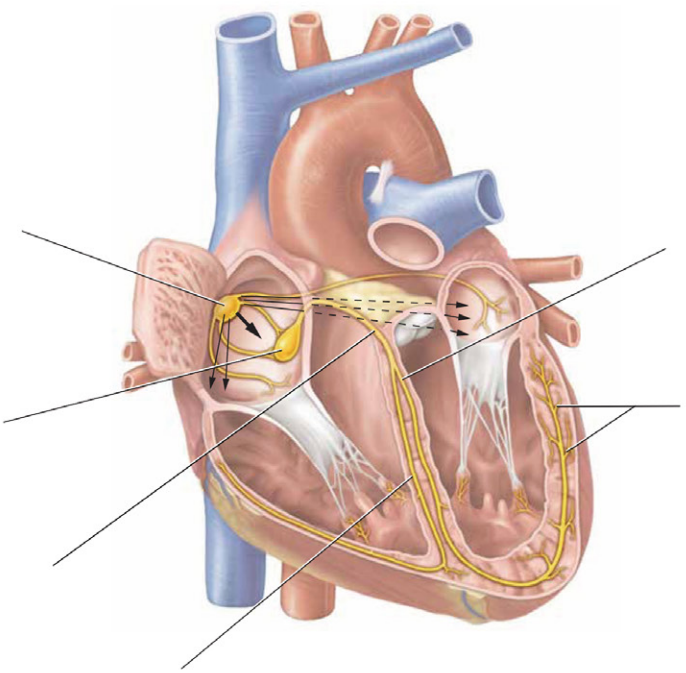

FIGURE **19.10** Anatomy of the cardiac conduction system.

Name _____

Section _____ Date _____

10 Label the parts of the electrocardiogram on Figure 19.11.

- ❑ T wave
- ❑ P wave
- ❑ P-R interval
- ❑ Q-T interval
- ❑ QRS complex
- ❑ S-T segment

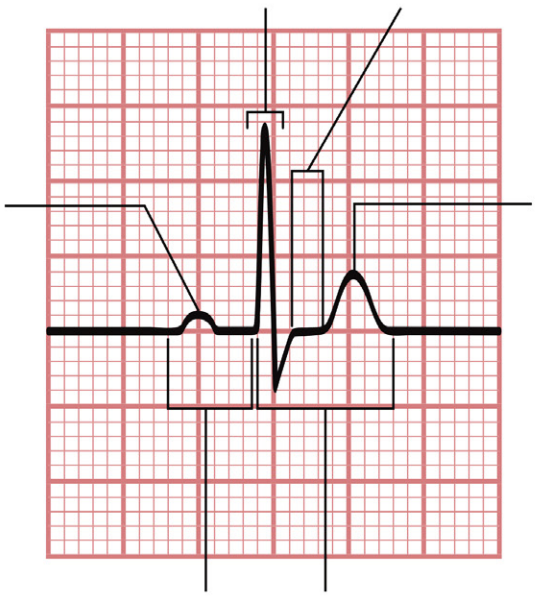

FIGURE **19.11** ECG tracing.

Name _____

Section _____ Date _____

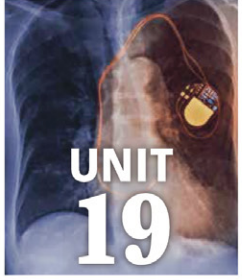

REVIEW

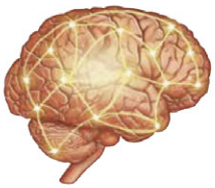

Check Your Understanding

Critical Thinking and Application Questions

1 You are auscultating your patient's chest, and you notice that the S2 sound seems to be "split," meaning that you can hear two separate sounds. You can also hear a noticeable murmur during S2. Is the abnormality in the atrioventricular valves or the semilunar valves? How do you know? Explain.

2 What might it mean if the capillary refill time measures 10 seconds in the digits of one hand and 2 seconds in the digits of the other hand? What might it mean if the capillary refill time measures 10 seconds in all digits?

3 Your patient has been admitted to the emergency room with an occupational injury caused by an industrial saw. He has lost significant volumes of blood. What effect has this blood loss likely had on his blood pressure, and why?

4 Predict the effects of a drug that blocks the sympathetic nervous system on blood pressure and heart rate. How would this drug affect the three factors that determine blood pressure?

5 Predict the effects of a drug that blocks the parasympathetic nervous system on blood pressure and heart rate. How would this drug affect the three factors that determine blood pressure?

6 You are presented with a stack of ECGs on your first day of your cardiology rotation and are given a single instruction: "Read them." As you progress through the pile, you note the following abnormalities. Explain from where in the heart or cardiac conduction system each abnormality might have come:

a Absent P waves

b Abnormally long QRS complex

c Abnormally long P-R interval

d Extra QRS complexes

UNIT
20

Blood

Once you have completed this unit, you should be able to:

1. Identify and describe the formed elements of blood.
2. Determine the differential white blood cell count of a blood smear.
3. Perform blood typing of the ABO and Rh blood groups using simulated blood.
4. Explain the basis for blood typing and matching for blood donation.
5. Determine appropriate blood donors for a given recipient.
6. Determine your own blood type and the hemoglobin content of your blood.

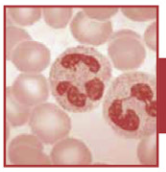

Name _____ Section _____ Date _____

PRE-LAB EXERCISES

Complete the following exercises prior to coming to lab, using this lab manual and your textbook for reference.

Pre-Lab Exercise 20-1



Key Terms

You should be familiar with the following terms before coming to lab.

Term	Definition

Formed Elements

Erythrocyte _____

Leukocyte _____

Granulocyte _____

Neutrophil _____

Eosinophil _____

Basophil _____

Agranulocyte _____

T Lymphocyte _____

B Lymphocyte _____

Monocyte _____

Platelets _____

Name _____ Section _____ Date _____

Blood Typing

Antigen _____

Antiserum _____

Antibody _____

Blood Donation

Universal donor _____

Universal recipient _____

Pre-Lab Exercise 20-2



Formed Elements

In this unit we will identify the formed elements of blood on a peripheral blood smear. Each formed element has unique morphological characteristics and functions. Use your text and Exercise 20-1 (p. 533) in this unit to fill in Table 20.1 with these functions and characteristics.

TABLE **20.1** Properties of Formed Elements

Formed Element	Nucleus Shape	Cytoplasm and/or Granule Color	Function(s)	Prevalence
Erythrocyte				
Neutrophil				
Eosinophil				
Basophil				
Lymphocyte				
Monocyte				
Platelet				

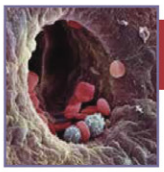

Colored SEM of sectioned liver tissue showing erythrocytes and leukocytes in a hepatic capillary.

EXERCISES

Safety concerns often preclude the use of real blood in the laboratory, but we can still demonstrate important principles of blood by viewing prepared microscope slides of blood cells and by using simulated blood to learn about blood typing. There is no real concern over blood-borne diseases with simulated blood, but do keep in mind that the simulated blood contains chemicals that are hazardous. Therefore, use appropriate safety protocols when handling all materials in this lab.

In this unit you will identify the formed elements of blood on microscope slides. You will also play a murder mystery game in which you use simulated blood to apply blood-typing techniques, after which you use the same cast of characters to examine blood donation. If your lab has the appropriate protocols for the use of real blood, you will also type your own blood and determine its hemoglobin content.

Exercise 20-1

Formed Elements (Cells) of Blood

MATERIALS

- ❑ Blood slides
- ❑ Light microscope
- ❑ Colored pencils

Whole blood consists of two main components: **plasma**, the fluid portion of blood, and **formed elements**, or the cellular portion of blood. Plasma accounts for about 55 percent of the volume of whole blood and consists primarily of water, proteins, and other solutes such as nutrients and ions. Formed elements account for about 45 percent of the volume of whole blood. There are three classes of formed elements: erythrocytes, platelets, and leukocytes.

1. **Erythrocytes. Erythrocytes** (eh-RITH-roh-syt′z), also known as **red blood cells**, carry oxygen around the body on an iron-containing protein called **hemoglobin** (HEE-moh-glohb-in) (Fig. 20.1). They are the most numerous blood cells, averaging about 44 percent of the total blood volume. This value, known as the **hematocrit** (heh-MAEH-toh-krit), is typically higher in males (40 to 50 percent) than in females (36 to 44 percent). Erythrocytes are easily distinguished from the other formed elements by their reddish-pink color and the fact that mature erythrocytes lack nuclei and most organelles.
2. **Platelets.** Note in Figure 20.1 that **platelets** (PLAYT-letz) aren't actually cells at all but are instead just small cellular fragments. As such, they lack nuclei and most organelles and are much smaller than the other formed elements. Platelets are involved in blood clotting and make up less than 1 percent of the total blood volume.
3. **Leukocytes. Leukocytes** (LOO-koh-syt′z), also known as **white blood cells**, play a role in the immune system and make up less than 1 percent of the total blood volume. The two subclasses of leukocytes are based upon the presence or absence of visible granules in their cytoplasm.

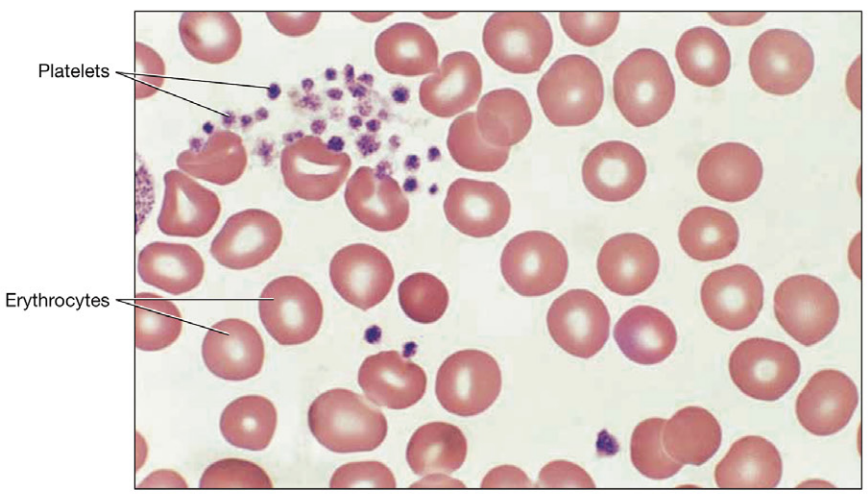

FIGURE **20.1** Photomicrograph of erythrocytes and platelets.

a. **Granulocytes.** As implied by their name, **granulocytes** (GRAN-yoo-loh-syt′z) are cells containing cytoplasmic granules that are visible when stained. The three types of granulocytes stain differently when treated with the dyes hematoxylin and eosin and are named for the type of stain with which they interact.

   i. **Neutrophils** (NOO-troh-filz) do not interact strongly with either type of dye, and their granules stain a light violet-pink color. They are the most numerous type of leukocyte, making up about 60 to 70 percent of the total leukocytes in the blood. They typically have multilobed nuclei, although their nuclei often vary in appearance, which gives rise to their other name: *polymorphonucleocytes*. One common variation in nucleus shape, shown in Figure 20.2, is seen in immature neutrophils called *band cells*. As you can see, the nucleus of a band cell has a single lobe that is stretched into a U-shape (or a single "band"). Neutrophils are attracted to the site of any cellular injury, and are particularly active in ingesting and destroying bacteria.

   ii. **Eosinophils** (ee-oh-SIN-oh-filz) interact strongly with the red dye eosin, and their granules stain bright red. They are far less numerous than neutrophils, accounting for only about 4 percent of the total leukocytes in the blood. As with neutrophils, their nuclei are segmented into lobes, although eosinophils' nuclei tend to be bilobed. Eosinophils play a role in the immune response to infection with parasitic worms and the allergic response.

   iii. **Basophils** (BAY-zoh-filz) take up the dark purple stain hematoxylin (it is a basic dye, hence their name *baso*phil), and their granules appear dark blue-purple. Like eosinophils, they tend to have bilobed nuclei, but their nuclei are often obscured by their dark granules. They are the least numerous of the leukocytes, making up fewer than 1 percent of the total leukocyte count, and will likely be the most difficult to find on your slide. Basophils are primarily involved in the allergic response.

b. **Agranulocytes.** The cells known as **agranulocytes** (AY-gran-yoo-loh-syt′z) lack visible cytoplasmic granules. The two types of agranulocytes are the following:

   i. **Lymphocytes** (LIMF-oh-syt′z) tend to be smaller than granulocytes and have large, spherical nuclei that are surrounded by a rim of light blue-purple cytoplasm. They are the second most numerous type of leukocyte, making up 20 to 25 percent of the total leukocyte count. There are two populations of lymphocytes. *B lymphocytes* produce proteins called *antibodies* that bind foreign glycoproteins called *antigens*. *T lymphocytes* play numerous roles, including enhancing other aspects of the immune response, destroying cancer cells, and destroying cells infected with viruses.

   ii. **Monocytes** (MAHN-oh-syt′z) are the largest of the leukocytes and have U-shaped or horseshoe-shaped nuclei with light blue or light purple cytoplasm. They are the third most numerous type of leukocyte, accounting for 3 to 8 percent of the total. Monocytes exit the blood to mature into cells called **macrophage**s (MAK-roh-feyj-uhz), which are very active phagocytes.

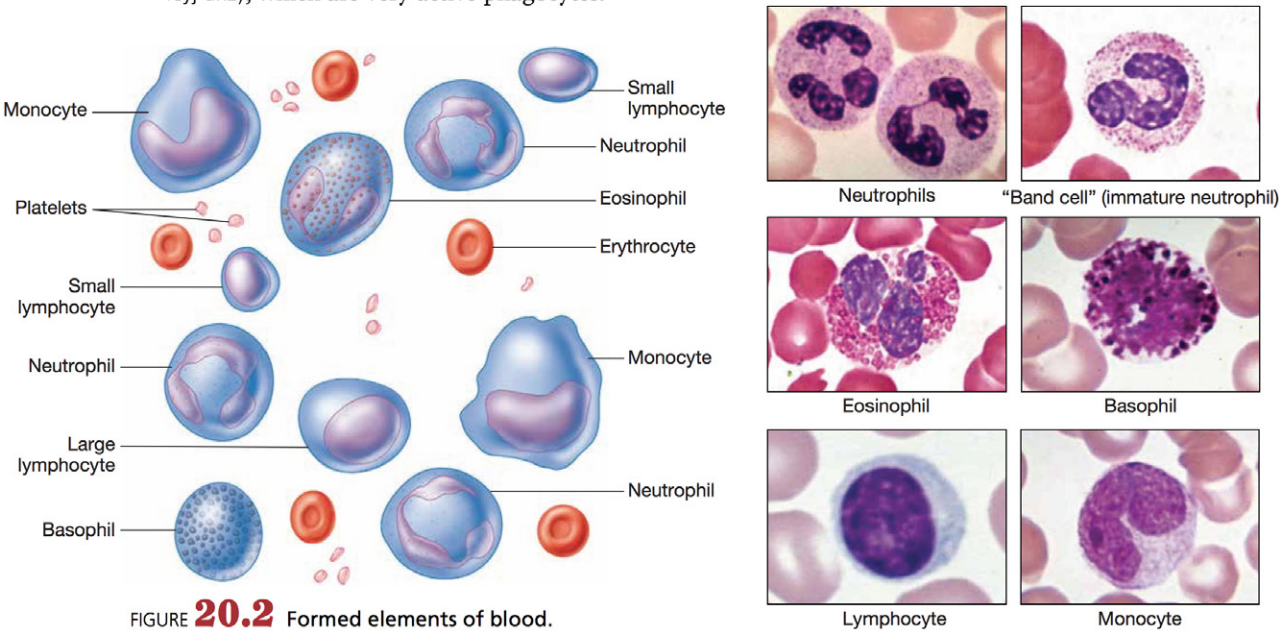

FIGURE **20.2** Formed elements of blood.

Procedure 1 Microscopy of a Peripheral Blood Smear

In this exercise, you will examine a blood slide called a **peripheral blood smear**. Examine the peripheral blood smear on high power, and scroll through to find each of the formed elements. Note that you may have to find a second slide to locate certain cells, because some types are more difficult to find (in particular the eosinophils and basophils). In the spaces provided, use colored pencils to draw and describe each formed element you locate. When you have finished, answer Check Your Understanding questions 1 through 3 (p. 551).

1 Erythrocyte

2 Neutrophil

3 Eosinophil

4 Basophil

5 Lymphocyte

6 Monocyte

7 Platelets

Procedure 2 Performing a Differential White Blood Cell Count

One of the most common blood analyses performed by a laboratory is a *differential white blood cell count*. In this procedure, the number and types of leukocytes in a blood sample are counted to determine the relative frequency of each type. This can give important information about the cause of a patient's illness, because different conditions will cause an elevation of different types of leukocytes. Differential counts were previously performed manually by a laboratory technician, as you will do here. Now, however, they are generally done by a machine, but the technician will still manually examine the cells if any abnormalities are noted.

1. Obtain a blood smear slide, and scan it on low power to find an area where the cells appear to be evenly distributed.
2. Advance the microscope objective to a power high enough for you to distinguish between the different types of leukocytes. For some microscopes, medium power will suffice, and for others, high power or even oil immersion might be necessary.
3. Scan the slide for leukocytes, and create a running tally of the number of each type you find below. Do this until you have counted 100 total leukocytes.

Neutrophils	*Eosinophils*	*Basophils*	*Lymphocytes*	*Monocytes*

4. Total the number of each leukocyte you counted, and record these data in Table 20.2. Refer to Table 20.1 in the Pre-Lab Exercises (p. 532) or Exercise 20-1 for the predicted percentage of each type of leukocyte in the blood. How do the totals you found compare with the predicted percentages?

TABLE **20.2** Differential White Blood Cell Totals

Leukocyte	Number Counted	Percentage (of 100)	Predicted Percentage
Neutrophils			
Eosinophils			
Basophils			
Lymphocytes			
Monocytes			

Exercise 20-2

ABO and Rh Blood Groups

MATERIALS

- ❑ Well plates
- ❑ Simulated blood types A–, B+, AB–, and O+
- ❑ Simulated antisera: anti-A, anti-B, anti-Rh
- ❑ Well plates
- ❑ Sharpie

Blood typing is done by checking the blood for the presence or absence of specific glycoproteins called **antigens** found on the cell surface. Two clinically relevant antigens are the **A antigen** and the **B antigen**. The blood type is named based upon which of the antigens is present (Fig. 20.3).

- Type A blood has A antigens on the cell surface.
- Type B blood has B antigens on the cell surface.
- Type AB blood has both A and B antigens on the cell surface.
- Type O blood has neither A nor B antigens on the cell surface.

An additional clinically relevant antigen is the Rh antigen.

- Blood that has the Rh antigen is denoted as Rh positive (e.g., A+).
- Blood that lacks the Rh antigen is denoted as Rh negative (e.g., A−).

The prevalence of different blood types in the United States varies with different ethnic groups. In general, we can say that the most common type is O+, followed by A+, and then B+.

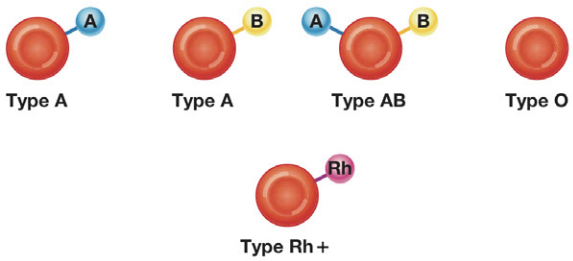

FIGURE **20.3** Basic ABO and Rh blood types.

The antigens present on the surface of an erythrocyte can be determined by combining it with a solution called an **antiserum**. An antiserum is a solution that contains proteins produced by B lymphocytes called **antibodies** that bind to specific antigens. When antibodies bind to antigens on erythrocytes, they cause **agglutination** (uh-gloo-tin-AY-shun), or clumping of the erythrocytes, in the sample. In this exercise we are using simulated blood, so you won't see agglutination unless your instructor sets up a demonstration or permits you to type your blood (which is in a later, optional procedure). The antisera used to determine the blood type of a sample are named according to the antigen they bind:

- Anti-A antiserum contains anti-A antibodies that bind to erythrocytes with A antigens.
- Anti-B antiserum contains anti-B antibodies that bind to erythrocytes with B antigens.
- Anti-Rh antiserum contains anti-Rh antibodies that bind to erythrocytes with Rh antigens.

Antigen-Antibody Reactions

This exercise allows you to examine the antigen-antibody reactions of known blood types. Each table should take one well plate and one set of dropper bottles. The bottles are labeled A−, B+, AB−, and O+ to represent each of those blood types, and anti-A, anti-B, and anti-Rh to represent the different antisera. You can see what a positive reaction looks like in Figure 20.4. Notice that a positive reaction is indicated by the formation of a white, cloudy precipitate. (***Note:*** However, your sample may form either a granular or clumping precipitate, depending on the type of simulated blood used by your lab.) So, for type A+, a positive reaction is seen in the wells to which anti-A and anti-Rh antisera were added, but there is no reaction in the well containing anti-B antiserum.

Safety Note

Safety glasses and gloves are required!

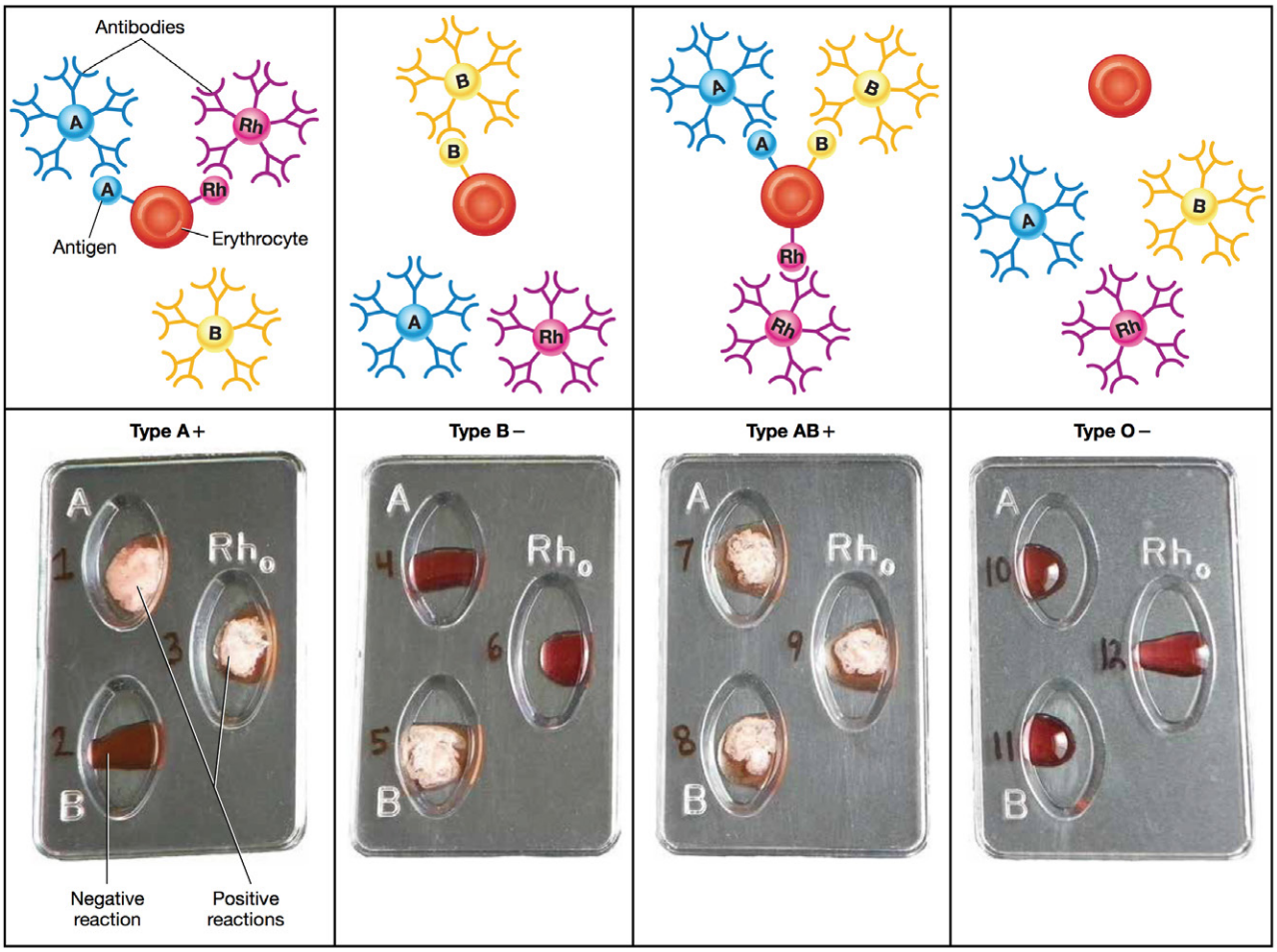

FIGURE **20.4** Reactions of simulated blood with simulated antisera.

20

Procedure 1 Testing Simulated Blood

Use Figure 20.5 as a guide to placement of samples in the wells.

1. Label wells on the well plate as wells 1 through 12 with a Sharpie.
2. Drop two drops of type A− blood in well 1, well 2, and well 3.
3. Drop two drops of type B+ blood in well 4, well 5, and well 6.
4. Drop two drops of type AB− blood in well 7, well 8, and well 9.
5. Drop two drops of type O+ blood in well 10, well 11, and well 12.
6. Add two drops of the anti-A antiserum to wells 1, 4, 7, and 10.
7. Add two drops of the anti-B antiserum to wells 2, 5, 8, and 11.
8. Add two drops of the anti-Rh antiserum to wells 3, 6, 9, and 12.
9. Observe the samples for changes in color symbolizing the agglutination or clumping that would normally occur between antisera and specific blood types. Record your results in Table 20.3.

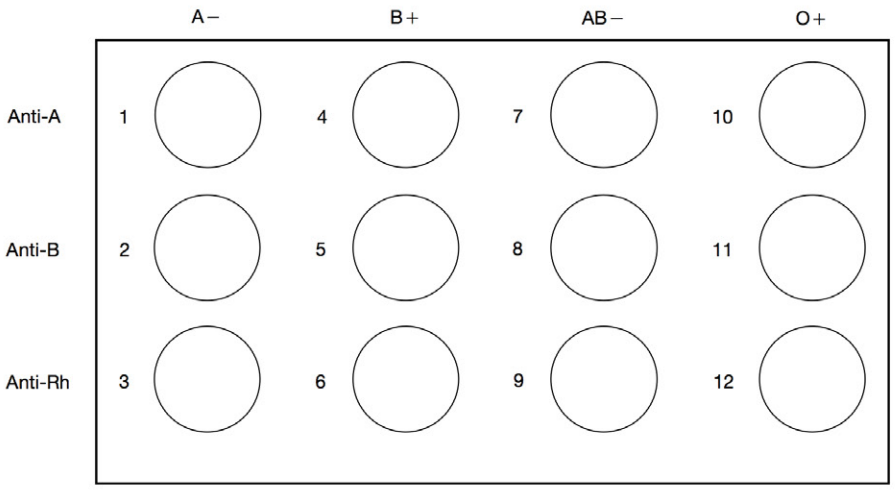

FIGURE **20.5** Well plate diagram.

TABLE **20.3** Blood Typing Results

Blood Type	Reacted with Anti-A? (yes/no)	Reacted with Anti-B? (yes/no)	Reacted with Anti-Rh? (yes/no)	Antigens Present on Cell Surface
A−				
B+				
AB−				
O+				

Exercise 20-3

Murder Mystery Game

MATERIALS

- ❑ Well plate
- ❑ Simulated antisera: anti-A, anti-B, anti-Rh
- ❑ Murder mystery game

In this game you will be applying the blood-typing techniques you learned in Exercise 20-2 (p. 537) to solve a series of murder mysteries. Each of the following cases presents a victim, a murderer, three suspects, three possible murder rooms, and three possible murder weapons. Your job is to play the role of detective and determine the identity of the murderer, which weapon he or she used, and in which room the crime was committed.

Procedure 1 Solving the Murder Mysteries

For each case a unique set of bottles is marked with a number that corresponds to the specific cases (i.e., the bottles are marked 1 for Case 1, 2 for Case 2, and 3 for Case 3). The murderer, rooms, and murder weapons are different for each case, but the cast of characters remains the same across the cases.

1. To begin the game, assemble into groups of two or three students. Obtain a well plate, and choose one set of samples to test (e.g., the rooms from Case 1, the suspects from Case 2, or the weapons from Case 3).
2. Test the samples by placing drops of the sample in three separate wells. Add two drops of anti-A antiserum to the first well, add two drops of anti-B antiserum to the second well, and add two drops of anti-Rh antiserum to the third well. After you have tested each of the samples, return them to their proper places in the front of the lab.
3. Read and record the blood type by watching for a reaction with the antisera. Remember that this is simulated blood, just as in Exercise 20-2. A positive reaction is denoted by the formation of a precipitate.
4. To determine the
   - *Murderer:* Match the blood type of one of the **suspects** to that of the **murderer**.
   - *Weapon and room:* Match the blood type of the **victim** to the blood types found in the **rooms** and on the **weapon**.

Case 1: Ms. Magenta

We enter the scene to find the dearly departed Ms. Magenta. Forensic analysis determines that there are two types of blood on the body. One blood type is Ms. Magenta's, and the other blood type is a trace amount left behind from the murderer.

Ms. Magenta's blood type: _____ **Murderer's blood type:** _____

We have three suspects:

1. *Mrs. Blanc* was being blackmailed by Ms. Magenta and Col. Lemon. They had discovered that Mrs. Blanc had murdered her late husband. Mrs. Blanc knew this would ruin her reputation at the country club.
2. *Col. Lemon* wanted to keep the blackmail money for himself and wanted Ms. Magenta out of the way.
3. *Mr. Olive* had been secretly in love with Ms. Magenta for years, and when he told her of his feelings, she rejected him harshly.

Mrs. Blanc's blood type: _____ **Col. Lemon's blood type:** _____

Mr. Olive's blood type: _____

We have three possible murder rooms:

Ballroom blood type: _____ **Library blood type:** _____

Den blood type: _____

We have three possible murder weapons:

Candlestick blood type: _____ **Noose blood type:** _____

Knife blood type: _____

Case 1: Conclusion

Ms. Magenta was killed by _____, in the _____,

with the _____.

Case 2: Col. Lemon

Our next victim is poor Col. Lemon. On his body we find his blood and also trace amounts of the blood of another person, presumably the murderer.

Col. Lemon's blood type: _____ **Murderer's blood type:** _____

We have three potential suspects:

1. *Mrs. Blanc*. Now, with Ms. Magenta out of the way, Mrs. Blanc could easily rid herself of her problem by disposing of the only other person who knows her secret—Col. Lemon.
2. *Professor Purple* believed the colonel had stolen his groundbreaking FrozenForehead™ wrinkle-eraser formula.
3. *Mr. Olive* couldn't stand the colonel because of his close relationship with Ms. Magenta.

Mrs. Blanc's blood type: _____ **Professor Purple's blood type:** _____

Mr. Olive's blood type: _____

We have blood in three different rooms:

Hall blood type: _____ **Kitchen blood type:** _____

Billiards room blood type: _____

Forensics found blood on three different weapons:

Copper pipe blood type: _____ **Hammer blood type:** _____

Revolver blood type: _____

Case 2: Conclusion

Col. Lemon was killed by _____, in the _____,

with the _____.

Case 3: Mr. Olive

Our next (and hopefully last) victim is Mr. Olive. Analysis demonstrates two blood types: one belonging to Mr. Olive, and trace amounts of another belonging to the murderer.

Mr. Olive's blood type: _____ **Murderer's blood type:** _____

We have three potential suspects:

1. *Ms. Feather* simply didn't like Mr. Olive and thought that he had a "bad aura."
2. *Mrs. Blanc* was worried that Mr. Olive knew her secret and wanted him out of the way.
3. *Professor Purple* discovered that Mr. Olive—not Col. Lemon—had actually stolen the FrozenForehead™ formula. Whoops!

Ms. Feather's blood type: _____ **Mrs. Blanc's blood type:** _____

Professor Purple's blood type: _____

Blood was found in three rooms:

Lounge blood type: _____ **Dining room blood type:** _____

Greenhouse blood type: _____

We have three potential murder weapons:

Noose blood type: _____ **Hammer blood type:** _____

Revolver blood type: _____

Case 3: Conclusion

Mr. Olive was killed by _____, in the _____, with the _____.

20

Exercise 20-4

Blood Donation

Blood transfusion, the infusion of a recipient with a donor's blood cells, is a commonly performed medical procedure. Before a recipient is given a blood transfusion, the medical team must first learn the patient's blood type and then find a suitable, or "matching," donor. This is necessary because of the A, B, and Rh antigens on the surface of the donor erythrocytes and the presence of preformed antibodies in the recipient's blood. If a donor's erythrocytes have antigens the recipient's immune system recognizes as foreign, the recipient's antibodies will agglutinate the foreign erythrocytes. The agglutinated erythrocytes are then destroyed by the immune system, a process known as **hemolysis** (heem-AW-lih-sis). This is called a **transfusion reaction**, and it is a medical emergency that can lead to kidney failure and death.

To ensure that a transfusion reaction does not occur, we must make sure the donor blood does not have antigens the recipient's immune system will recognize as foreign. For the ABO blood group, our immune systems produce antibodies to any antigen *not* present on the surface of our own cells.

- People with type A blood have A antigens and so produce anti-B antibodies.
- People with type B blood have B antigens and so produce anti-A antibodies.
- People with type O blood have neither A nor B antigens and so produce anti-A and anti-B antibodies.
- People with type AB blood have both A and B antigens and so produce neither anti-A nor anti-B antibodies.

If you're wondering about the Rh factor, wait just a moment—we're getting there. Let's do an example with the ABO blood group first:

Felix has type B blood, which means that he has anti-A antibodies. What will happen if we give him blood from a donor with:

- Type A blood? There are A antigens on these donor erythrocytes, and Felix's anti-A antibodies would agglutinate them. ✕
- Type B blood? Felix's anti-A antibodies would have no effect on the B antigens on these donor erythrocytes, so this blood is safe. ✓
- Type O blood? There are no antigens on these donor erythrocytes, so Felix's anti-A antibodies would have no effect on them, and this blood is safe. ✓
- Type AB blood? There are both A and B antigens on these donor erythrocytes, and Felix's anti-A antibodies would bind and agglutinate the A antigens. ✕

Now that's easy, isn't it?

Next let's address the Rh factor. The blood of an Rh-negative person does *not* contain preformed antibodies to the Rh antigen. However, anti-Rh antibodies are made if an Rh-negative person is exposed to the Rh antigen. In an emergency setting, it is generally not possible to determine if an Rh-negative person has been exposed to the Rh antigen, so health-care professionals err on the side of caution and assume that the person has anti-Rh antibodies. For the sake of simplicity, we will assume the same thing in this exercise. So, for our purposes:

- People with Rh-positive blood *do not* produce anti-Rh antibodies.
- People with Rh-negative blood *do* produce anti-Rh antibodies.

Let's do one more example, taking into account the Rh factor this time:

Lourdes has A− blood, which means that she has anti-B and anti-Rh antibodies. What will happen if we give her blood from a donor with:

- Type A+ blood? There are A and Rh antigens on these donor erythrocytes, and Lourdes' anti-Rh antibodies would agglutinate the Rh antigens. ✕
- Type B− blood? There are B antigens on these donor erythrocytes, and Lourdes' anti-B antibodies would agglutinate them. ✕
- Type O− blood? There are no antigens on these donor erythrocytes, so Lourdes' anti-B and anti-Rh antibodies would have no effect on them, and this blood is safe. ✓
- Type AB+ blood? There are A, B, and Rh antigens on these donor erythrocytes, and Lourdes' anti-B and anti-Rh antibodies would agglutinate the B and Rh antigens. ✕

Procedure 1 Blood-Type Matching Practice

Use the information from the preceding section and your text to complete Table 20.4. After you have filled in the table, answer Check Your Understanding questions 4 and 5 (p. 552).

TABLE **20.4** Blood Donation

Blood Type	Antigens Present	Antibodies Present	Can Donate Safely to Which Blood Types?	Can Receive Safely from Which Blood Types?
A+				
A−				
B+				
B−				
AB+				
AB−				
O+				
O−				

You should notice something from Table 20.4: People with AB+ blood can receive from any donor blood type, and people with O− blood can donate to any recipient blood type. This is because people with AB+ erythrocytes have all three antigens and so their blood contains no antibodies to bind to donor blood. Conversely, people with type O− erythrocytes have none of the three antigens and so there is nothing for any recipient's antibodies to bind. For these reasons, type AB+ blood is often called the **universal recipient** and type O− blood is often called the **universal donor**.

Procedure 2 Type Matching for Transfusions

Gasp! It turns out that Ms. Magenta, Col. Lemon, and Mr. Olive all survived their injuries! But they have lost blood and are in need of blood transfusions. All of the suspects have had a sudden change of heart and have offered to help the three victims by donating blood. When they arrived at the hospital, the blood of all victims and suspects was retested. This was fortunate, as it turned out the results obtained at the crime scenes were inaccurate due to a suspected mole in the police lab. The correct blood types are listed in Table 20.5. Your job is to determine who among the suspects could safely donate blood to whom. After you have finished this activity, answer Check Your Understanding questions 6 and 7 (p. 552).

TABLE **20.5** Corrected Blood Types of the Suspects and Victims

Suspect/Victim	Blood Type
Ms. Magenta	B+
Ms. Feather	O+
Mrs. Blanc	A−
Prof. Purple	AB−
Col. Lemon	AB+
Mr. Olive	O−

Recipient 1: Ms. Magenta

Ms. Magenta's blood type: _____

Donors:

Ms. Feather's blood type: _____

Mrs. Blanc's blood type: _____

Professor Purple's blood type: _____

Who could safely donate blood to Ms. Magenta? _____

Who could not safely donate blood to Ms. Magenta? _____

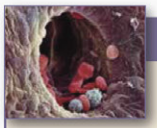

HINTS & TIPS

Remember—when trying to work out who can donate blood to whom, you are concerned with the recipient's antibodies and the donor's antigens. So first work out which antibodies the recipient has, then make sure the recipient's antibodies won't bind any antigens on the donor's erythrocytes.

Recipient 2: Col. Lemon

Col. Lemon's blood type: _____

Donors:

Ms. Feather's blood type: _____

Mrs. Blanc's blood type: _____

Professor Purple's blood type: _____

Who could safely donate blood to Col. Lemon? _____

Who could not safely donate blood to Col. Lemon? _____

Recipient 3: Mr. Olive

Mr. Olive's blood type: _____

Donors:

Ms. Feather's blood type: _____

Mrs. Blanc's blood type: _____

Professor Purple's blood type: _____

Who could safely donate blood to Mr. Olive? _____

Who could not safely donate blood to Mr. Olive? _____

Exercise 20-5

Typing and Examining Your Own Blood

MATERIALS

- ❑ Lancet
- ❑ Alcohol wipes
- ❑ Anti-A, anti-B, and anti-Rh antisera
- ❑ Blank microscope slide
- ❑ Sharpie
- ❑ Toothpicks
- ❑ Tallquist paper and scale
- ❑ Dissection microscope or magnifying glass

If your lab has the appropriate equipment and biohazard disposal means, your instructor may permit you to type and examine your own blood in this optional exercise. Working with blood is actually very safe provided you follow some basic procedures outlined here:

1. Wash your hands with soap and water before starting and after completing the procedures.
2. Prepare your work area by placing a disposable absorbent liner on the lab table.
3. Wear gloves and safety glasses when handling all materials for this lab.
4. Handle only your own lab materials to avoid coming into contact with blood other than your own.
5. Dispose of all lancets and microscope slides in the designated sharps container only.
6. Dispose of all nonsharp materials (disposable pads, gloves, alcohol wipes, and any other materials you have used) in the designated red biohazard bag.
7. When you are finished with the procedures, clean your work area with the disinfectant solution provided by your lab instructor.

In the following procedures, you will determine your blood type and measure the approximate hemoglobin content of your blood. Note that these exercises involve lancing your own finger to stimulate bleeding. If you have any medical conditions that render this activity unsafe, discuss this with your lab instructor.

Procedure 1 Determining Your Blood Type

The process of determining the blood type of real blood is similar to the one you performed earlier with simulated blood: You use three blood samples, and apply three different antisera to look for a reaction; in this case, you are looking for agglutination of erythrocytes (Fig. 20.6). The reaction between real blood antigens and antibodies is more subtle than in the simulated blood; in particular, the reaction with Rh antigens and the anti-Rh antibodies can be difficult to see. You may wish to examine your samples under a magnifying glass to more clearly see the reaction.

Safety Note

Safety glasses and gloves are required!

1. Obtain a blank microscope slide, and draw three circles on it with a Sharpie. Label the circles A, B, and Rh.
2. Wash your hands, and prepare your work area with a disposable absorbent liner.
3. Place a glove on one hand, and prepare one finger of your ungloved hand by cleaning it with an alcohol wipe.



FIGURE **20.6** Erythrocyte agglutination.

4. Use a fresh lancet to lance the finger you just cleaned. Dispose of the used lancet in the sharps bin.
5. Squeeze your finger to stimulate bleeding, and squeeze a small drop of blood onto each of the three circles on the slide.
6. Place a drop of anti-A antiserum in the circle marked A, anti-B in the circle marked B, and anti-Rh in the circle marked Rh.
7. Use three toothpicks, one for each circle, to gently mix the blood with the antisera. You must use a different toothpick for each circle to avoid cross-contamination. Watch carefully for a reaction, using a dissection microscope or magnifying glass if needed (be sure to hold a magnifying glass in your gloved hand to avoid coming into contact with blood from your classmates).
8. Determine your blood type based upon the reactions with the antisera. Remember, if the blood reacts with an antiserum, that antigen is present. For example, if your blood reacts with anti-B antiserum and anti-Rh antiserum, the B and Rh antigens are present, and the blood type is B+. Record your blood type here: _____
9. Dispose of your microscope slide in the sharps bin when you have completed the blood-typing procedure.

Procedure 2 Determining the Hemoglobin Content of Your Blood

As you learned in Exercise 20-1, erythrocytes are filled with the protein hemoglobin, which binds and transports oxygen through the blood. The average amount of hemoglobin in erythrocytes averages about 12–16 g/dl in females and about 14–18 g/dl in males. Medically, this is an important value, because a decreased amount of hemoglobin can indicate conditions such as *iron-deficiency anemia*. In a hospital lab, the amount of hemoglobin in the blood is measured with an instrument known as a *hemoglobinometer*. However, in this lab we will employ an older (and less expensive) method using *Tallquist paper*, which provides an estimate of the blood's hemoglobin content.

1. Squeeze your finger to continue to stimulate bleeding. If you need to lance your finger again, obtain a new lancet, and follow the same steps from the first procedure.
2. Obtain a piece of Tallquist paper. Roll your bleeding finger on the paper.
3. Compare the color the paper turns with the scale on the container while the paper is still slightly wet—do not let the paper dry, or you will need to repeat the procedure.

   Estimated hemoglobin value: _____
4. Dispose of any remaining sharps in the sharps container and all other blood-containing materials, including the Tallquist paper, in the red biohazard bag. Clean your work area with the disinfectant provided by your lab instructor.

Procedure 3 Calculating the Average Hemoglobin and Most Common Blood Type for Your Class

After you have completed the first two procedures and cleaned up your work area, you may pool the results for your class to find the most common blood types and the average values for hemoglobin content.

1. Record your blood type on the whiteboard.
2. When everyone in the class has recorded his or her blood type, pool the results, and complete Table 20.6. Calculate the percentage of your class that has each blood type.
3. Your instructor will have two columns for hemoglobin values on the whiteboard, one for female and one for male members of the class. Write your estimated hemoglobin value on the whiteboard under the appropriate column.
4. When all of your classmates have recorded their numbers on the board, calculate the average value for the females and males of your class. Record these data in Table 20.7. How do the values for your class compare with the averages?

TABLE 20.6 Blood Types for Your Class

Blood Type	Number in Class	Percentage of Total
A+		
A−		
B+		
B−		
O+		
O−		
AB+		
AB−		

TABLE 20.7 Average Hemoglobin Values for Your Class

Group	Average Hemoglobin Value
Females	
Males	

Name _____

Section _____ Date _____



Check Your Recall

REVIEW

1 *True/False:* Mark the following statements as true (T) or false (F). If the statement is false, correct it to make it a true statement.

_____ a. The liquid portion of blood is known as plasma.

_____ b. Erythrocytes are generally involved in some aspect of the immune system.

_____ c. The granulocytes include the neutrophils, eosinophils, and basophils.

_____ d. Eosinophils are involved in mediating responses to parasitic worms and allergies.

_____ e. Lymphocytes leave the blood and become macrophages, very active phagocytes.

2 Label the formed elements on the peripheral blood smear in Figure 20.7.

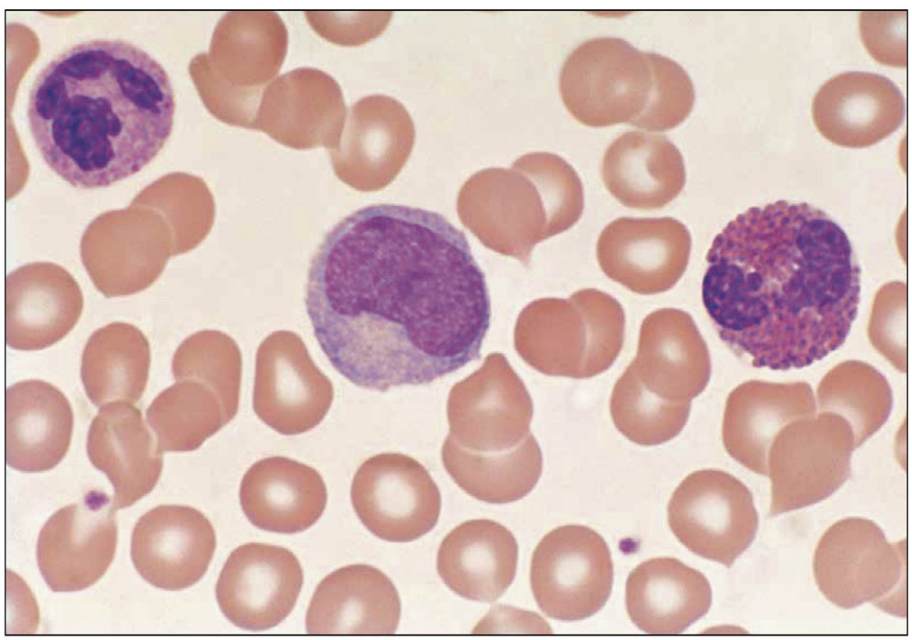

FIGURE **20.7** Peripheral blood smear.

3 *Fill in the blanks:* Erythrocytes carry _____ on the protein _____.

4 Which of the following is *not* an antigen that may be found on the surface of an erythrocyte?

a. A antigen
b. B antigen
c. O antigen
d. Rh antigen

5 State which antigens are present on the surface of erythrocytes of the following blood types:

a A– _____

b O– _____

c AB+ _____

d B+ _____

6 *Fill in the blanks:* Antibodies are produced by _____ and bind to specific _____ on erythrocytes, causing _____, or clumping of erythrocytes.

7 *Circle all that apply*: A person with type O blood has

a. anti-A antibodies.
b. anti-B antibodies.
c. anti-O antibodies.
d. no antibodies.

8 A person with type A– blood has which of the following antibodies? (Assume the person has been exposed to Rh antigens. Circle all that apply.)

a. Anti-A antibodies.
b. Anti-B antibodies.
c. Anti-Rh antibodies.
d. No antibodies.

9 Which blood type is considered the universal donor? Why can this blood type be given to all other blood types?

_____

_____

10 Which blood type is considered the universal recipient? Why can people with this blood type receive blood from all other blood types?

_____

_____

Name _____

Section _____ Date _____



REVIEW

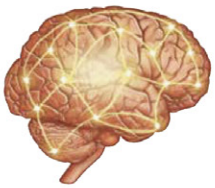

Check Your Understanding

Critical Thinking and Application Questions

1 Your hospital patient has been admitted for a cough, fever, and shortness of breath. Lab analysis of blood work shows an elevated leukocyte count with, specifically, a high neutrophil count. The nurse practitioner says that based on this information the patient likely has a bacterial infection, although he needs further information to confirm the diagnosis. What led him to conclude that the patient has a bacterial infection, and why?

2 A common consequence of many cancer chemotherapy drugs is destruction of bone marrow cells. This leads to a decrease in the number of circulating erythrocytes and leukocytes, resulting in conditions called *anemia* and *leukopenia*, respectively. Predict the consequences of anemia and leukopenia, considering the function of these types of cells.

3 The poison ricin, derived from the castor bean plant, interferes with protein synthesis. Which formed elements of blood would ricin affect directly? Are there any mature formed elements in the blood that ricin would not affect? Explain. (***Hint:*** Where does the first part of protein synthesis take place?)

4 The disease *erythroblastosis fetalis* (also called *hemolytic disease of the newborn*) develops in a fetus or a newborn infant with Rh-positive blood and an Rh-negative mother. Symptoms result when maternal anti-Rh antibodies cross the placenta and interact with the fetus' erythrocytes. Why are the children of Rh-positive mothers not at risk for this disease? Why are Rh-negative fetuses not at risk for this disease?

5 Explain why a person who is blood type O− can donate blood to any blood type but can receive only from individuals who are also blood type O−.

6 List all of the blood types to which the following people could donate, assuming the recipients have been exposed to Rh antigens:

a Donor 1: Type A−

b Donor 2: Type O+

c Donor 3: Type AB+

d Donor 4: Type B−

7 List all of the blood types from which the following people could receive, assuming the recipients have been exposed to Rh antigens:

a Recipient 1: Type O+

b Recipient 2: Type B+

c Recipient 3: Type A−

d Recipient 4: Type AB−

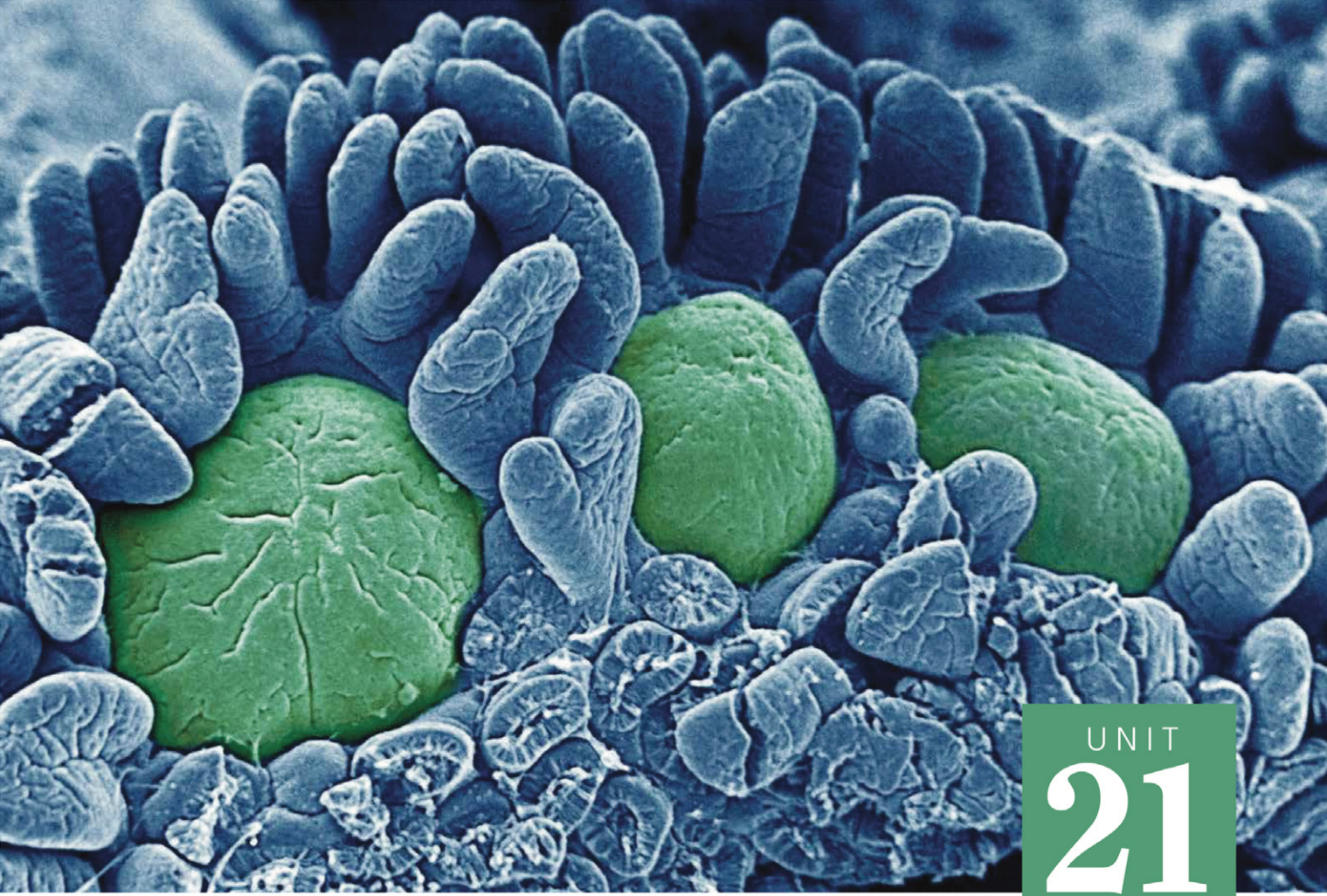

UNIT
21

Lymphatics and Immunity

Once you have completed this unit, you should be able to:

1. Identify structures of the lymphatic system.
2. Describe the role of the immune system in processing lymph as it is returned to the heart.
3. Trace the pathway of lymph as it is returned to the cardiovascular system.
4. Identify features of lymphatic organs on microscope slides.
5. Describe the three lines of defense of the immune system and trace the immune response to a bacterial and viral infection.
6. Describe the theory behind the ELISA procedure.

Name _____ Section _____ Date _____

PRE-LAB EXERCISES

Complete the following exercises prior to coming to lab, using this lab manual and your textbook for reference.

Pre-Lab Exercise 21-1



Key Terms

You should be familiar with the following terms before coming to lab.

Term	Definition

Lymphatic Structures

Lymphatic capillary _____

Lymph _____

Lymph-collecting vessel _____

Lymph trunk _____

Thoracic duct _____

Right lymphatic duct _____

Thymus _____

21

Lymph node _____

Spleen _____

Mucosa-associated lymphatic tissue _____

Tonsil _____

Name _____ Section _____ Date _____

Components of the Immune System

Innate immunity _____

Inflammation _____

Adaptive immunity _____

Antigen _____

Humoral (antibody-mediated) immunity _____

Antibody _____

Cell-mediated immunity _____

Pre-Lab Exercise 21-2

Anatomy of the Lymphatic System

Label and color the structures of the lymphatic system in Figure 21.1 with the terms from Exercise 21-1 (p. 557). Use your text and Exercise 21-1 in this unit for reference.

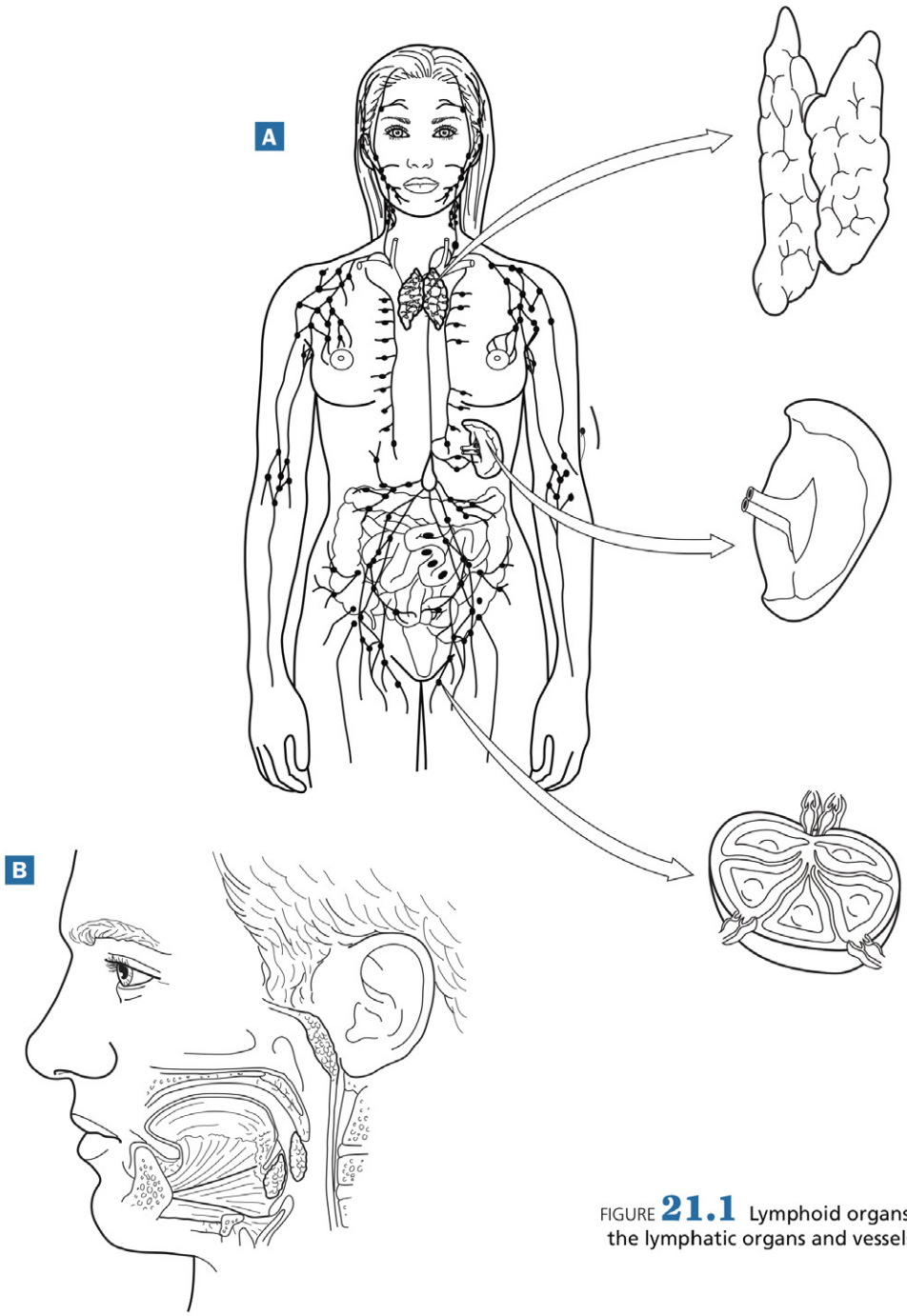

FIGURE **21.1** Lymphoid organs: (**A**) overview of the lymphatic organs and vessels; (**B**) the tonsils.

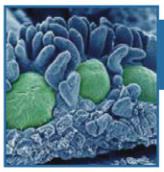

SEM of lymphatic nodules in the small intestine called Peyer's patches.

EXERCISES

The **lymphatic system** (limf-AEH-tik) is a diverse group of organs, tissues, and vessels that serves numerous functions in the body. For one, it is an important part of the immune system and combats harmful agents in the internal and external environments. It also works with the cardiovascular system to maintain fluid homeostasis in the extracellular fluid and with the gastrointestinal system to absorb fats.

The exercises in this unit introduce you to this important system. In the first exercise, you will study the lymphatic system's anatomy, and trace the flow of lymph throughout the body. In the second exercise, you will examine different types of lymph tissue on microscope slides. Finally, in the last two exercises you will explore the immune system response.

Exercise 21-1

Lymphatic System Anatomy

MATERIALS

- ❑ Human torso models
- ❑ Head and neck models
- ❑ Intestinal villus model
- ❑ Laminated outline of the human body
- ❑ Water-soluble marking pens
- ❑ Colored pencils

As you have learned, the lymphatic system consists of organs and tissues that have three primary functions:

1. **Transporting excess interstitial fluid back to the heart.** The process of filtration pushes water out of the blood and into the interstitial fluid. Approximately 1.5 mL/min. of fluid is lost from the circulation in this manner. This may not sound like a lot, but if this fluid is not returned to the blood vessels, we could lose our entire plasma volume in about a day. Fortunately, the lymphatic system picks up this lost fluid, carries it through lymphatic vessels, and returns it to the cardiovascular system.

   The water in the interstitial fluid first enters small, blind-ended **lymph capillaries** that surround blood capillary beds. These lymph capillaries have highly permeable walls that allow large substances and large volumes of fluid to enter and exit. Once inside the lymph capillaries, the fluid is called **lymph** (LIMF) and is delivered to larger **lymph-collecting vessels**, which contain valves to ensure that lymph flows in a single direction. Lymph-collecting vessels drain into larger **lymph trunks**. There are nine main lymph trunks that drain lymph from major body regions (Fig. 21.2A): the **jugular trunks**, which drain the head and the neck; the **subclavian trunks**, which drain the upper limbs; the **bronchomediastinal trunks** (brongk-oh-mee-dee-ah-STYN-uhl), which drain the thorax; the **intestinal trunk**, which drains the abdomen; and the **lumbar trunks**, which drain the pelvis and lower limbs.

   The lymph trunks then drain into the final vessels of the lymphatic circuit: **lymph ducts**. Note in Figure 21.2A that there are two lymph ducts—the **right lymphatic duct**, which drains the right upper limb and the right side of the head, neck, and thorax, and the **thoracic duct**, which drains lymph from the remainder of the body. The right lymphatic duct delivers lymph to the blood at the junction of the right subclavian and internal jugular veins. Similarly, the thoracic ducts drain lymph into the blood at the junction of the left subclavian and internal jugular veins (Fig. 21.2B).

2. **Absorbing dietary fats.** Fats are not absorbed from the small intestine directly into the blood capillaries because they are too large to enter these small vessels. Instead, fats enter a lymphatic capillary called a **lacteal** (lak-TEEL; see Fig. 24.19, p. 643). The lacteal delivers the fats to lymph-collecting vessels and intestinal trunks, after which the fatty lymph enters a large lymphatic vessel called the **cisterna chyli** (sis-TER-nah KY-lee). The cisterna chyli then drains into the thoracic duct, at which point the fats join the rest of the lymph.

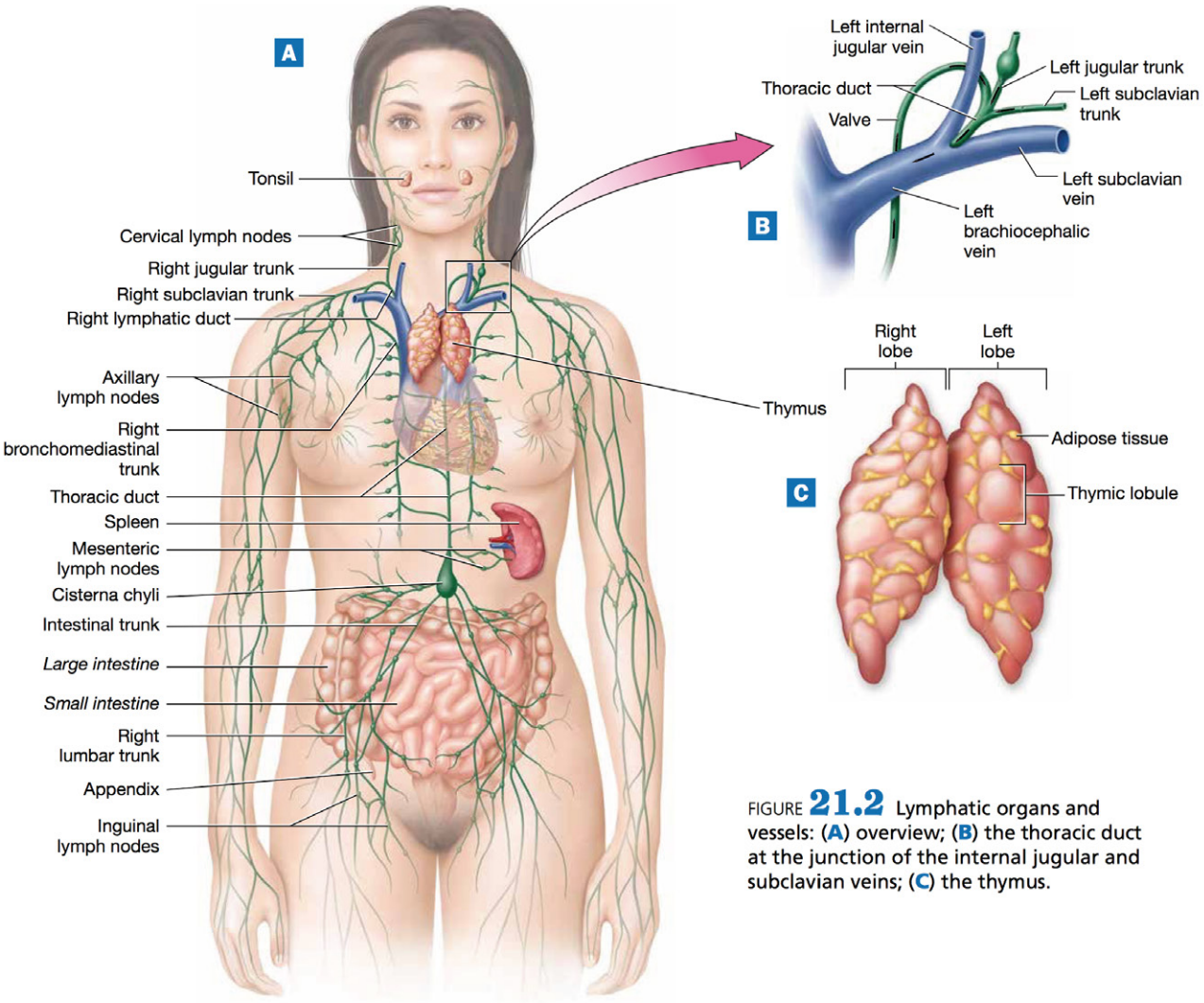

FIGURE **21.2** Lymphatic organs and vessels: (**A**) overview; (**B**) the thoracic duct at the junction of the internal jugular and subclavian veins; (**C**) the thymus.

21

3. **Activating the immune system.** Several of the lymphatic organs activate the *immune system*, a group of cells and proteins that protects the body from cellular injury such as trauma or pathogens (disease-causing organisms, cells, or chemicals). The lymphatic organs include the following:
   a. **Thymus.** The **thymus** is an organ composed of two lobes and many small lobules that is located in the anterior mediastinum (Fig. 21.2C). Recall from Unit 16, the endocrine unit, that the thymus secretes the hormones thymosin and thymopoietin that stimulate T lymphocyte maturation. The thymus is largest and most active in infants and young children. In adults, it atrophies (shrinks) and becomes filled with adipose and other connective tissue. (***Note:*** The adult thymus is smaller and less distinct than what is shown in Figure 21.2C; the thymus is shown larger and more distinct here for clarity.)
   b. **Lymph nodes.** The lymphatic organs called **lymph nodes** are arrangements of lymphatic tissue surrounded by a connective tissue capsule. Lymph nodes are often called "lymph glands," but this is a misnomer—they are not glands because they do not secrete any products. Instead, they act as filters that remove potential pathogens from the lymph before it is delivered to the blood. Lymph nodes are found along lymphatic vessels, where lymph is delivered by *afferent lymphatic vessels* and drained by an *efferent lymphatic vessel*. As lymph percolates through the node, it is filtered and pathogens are removed. All lymph nodes are individual, but there are clusters of them that are named as a group. Notice in Figure 21.2A that we find lymph nodes in

clusters in specific areas; these groupings are referred to as the **cervical, axillary, inguinal** (IN-gwin-uhl), and **mesenteric** (or intestinal) **lymph nodes.**

Figure 21.3 shows the internal structure of a lymph node, which consists of an outer **cortex** and an inner **medulla.** In the cortex, immune cells such as lymphocytes and macrophages are arranged into clusters called **lymphoid follicles,** which are separated from one another by inward extensions of the capsule called *trabeculae.* In the center of lymphoid follicles are lighter areas called **germinal centers** with large numbers of B lymphocytes.

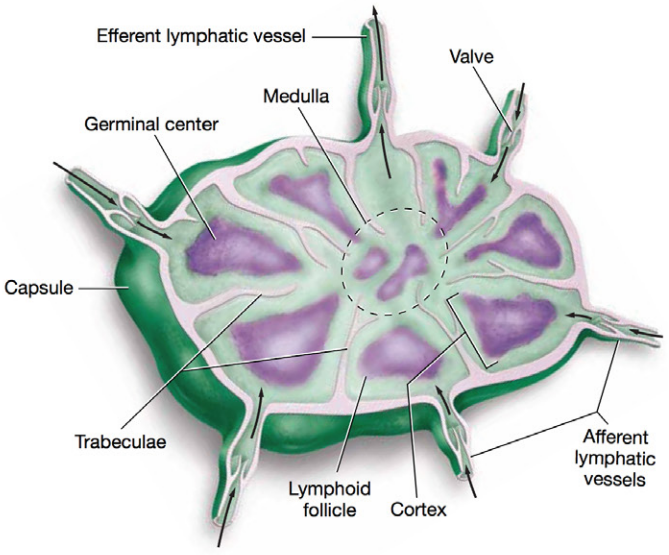

FIGURE **21.3** Structure of a lymph node.

c. **Spleen.** The **spleen** is a lymphatic organ that resides in the upper left quadrant of the abdominopelvic cavity that filters the blood and houses phagocytes. As you can see in Figure 21.4, it has two histologically distinct regions: red pulp and white pulp. **Red pulp** contains macrophages surrounding *trabecular veins* that destroy old or damaged erythrocytes. **White pulp** contains T lymphocytes, B lymphocytes, macrophages, and dendritic cells that surround branches of the splenic artery called **central arteries.** Blood flows through the central arteries and a series of arterioles until it gets to the spleen's very leaky capillaries: the *sinusoids.* From here pathogens leak from the blood into the white pulp, where they encounter the many immune cells that attempt to remove them from the blood.

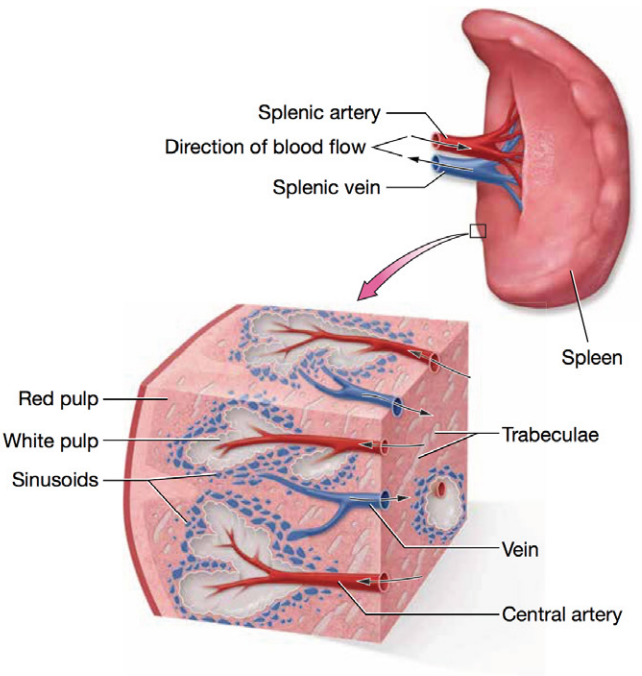

FIGURE **21.4** Anatomy and microanatomy of the spleen.

d. **Mucosa-associated lymphatic tissue and tonsils.** Clusters of loosely organized lymphatic tissue are scattered throughout mucous membranes in locations such as the gastrointestinal tract. These clusters are known as **mucosa-associated lymphatic tissue,** or **MALT.** Most MALT lacks a connective tissue capsule; however, some types of MALT, known as specialized MALT, are partially encapsulated. The most prominent examples of specialized MALT are the **tonsils,** which are found in the posterior oropharynx and nasopharynx (Fig. 21.5). Notice in the figure the three named tonsils: the **pharyngeal tonsil** (or **adenoid**), located in the posterior nasopharynx; the paired **palatine tonsils** (PAL-uh-ty'n), located in the posterior oropharynx; and the **lingual tonsil** (LING-yoo-uhl), located at the base of the tongue. There is another small pair of *tubal tonsils* adjacent to the opening of the pharyngotympanic tubes that may or may not be present in every individual.

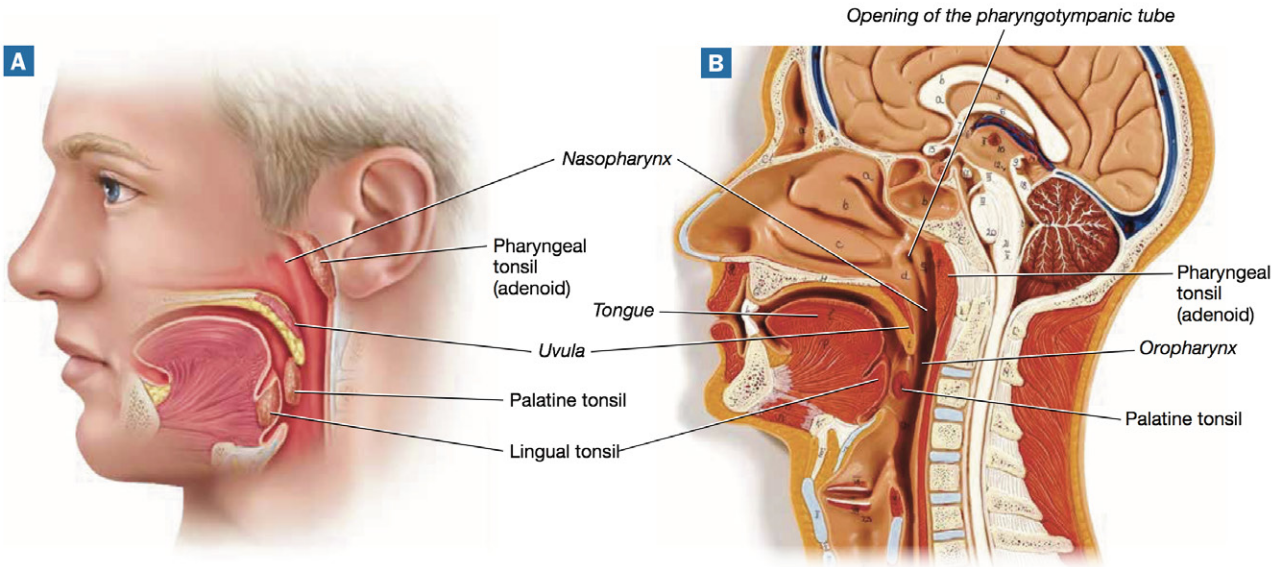

FIGURE **21.5** Anatomy of the tonsils: (**A**) illustration of a midsagittal section of the oral cavity; (**B**) anatomical model photo, midsagittal section of the head.

In the following activities you will identify structures of the lymphatic system, and then trace the flow of lymph through the vessels on its way back to the cardiovascular system. Your instructor may also wish you to dissect a preserved small mammal to identify some of the structures difficult to see on models, such as the thymus. If so, follow the procedure outlined in Unit 1 (p. 15) to open the animal and identify the required structures.

Procedure 1 Model Inventory for the Lymphatic System

Identify the following structures of the lymphatic system on models and diagrams, using your textbook and this unit for reference. As you examine the anatomical models and diagrams, record the name of the model and the structures you were able to identify on the model inventory in Table 21.1. When you have completed this activity, answer Check Your Understanding questions 1 through 5 (pp. 577–578).

1. Lymph vessels
   a. Lymph-collecting vessels
   b. Lymph trunks: jugular, subclavian, bronchomediastinal, intestinal, lumbar
   c. Right lymphatic duct
   d. Thoracic duct
   e. Lacteal
   f. Cisterna chyli
2. Thymus (this may be best viewed on a fetal model)
3. Lymph nodes
   a. Cervical lymph nodes
   b. Axillary lymph nodes
   c. Inguinal lymph nodes
   d. Mesenteric lymph nodes
4. Spleen
5. Mucosa-associated lymphatic tissue (MALT)
6. Tonsils
   a. Pharyngeal tonsil
   b. Palatine tonsils
   c. Lingual tonsil

TABLE **21.1** Model Inventory for the Lymphatic System

Model/Diagram	Structures Identified

Procedure 2 Tracing the Flow of Lymph through the Body

In this exercise you will trace the pathway of lymph flow from the starting location to the point at which the lymph is delivered to the cardiovascular system. You will trace the flow through the major lymph-collecting vessels, trunks, and ducts, and highlight clusters of lymph nodes through which the lymph passes as it travels.

1. Write the sequence of the flow.
2. Then use differently colored water-soluble markers to draw the pathway on a laminated outline of the human body. If no outline is available, use colored pencils and Figure 21.6.
3. Trace the flow from the following locations:

Start: Right foot _____

Start: Right arm _____

Start: Intestines (with fat) _____

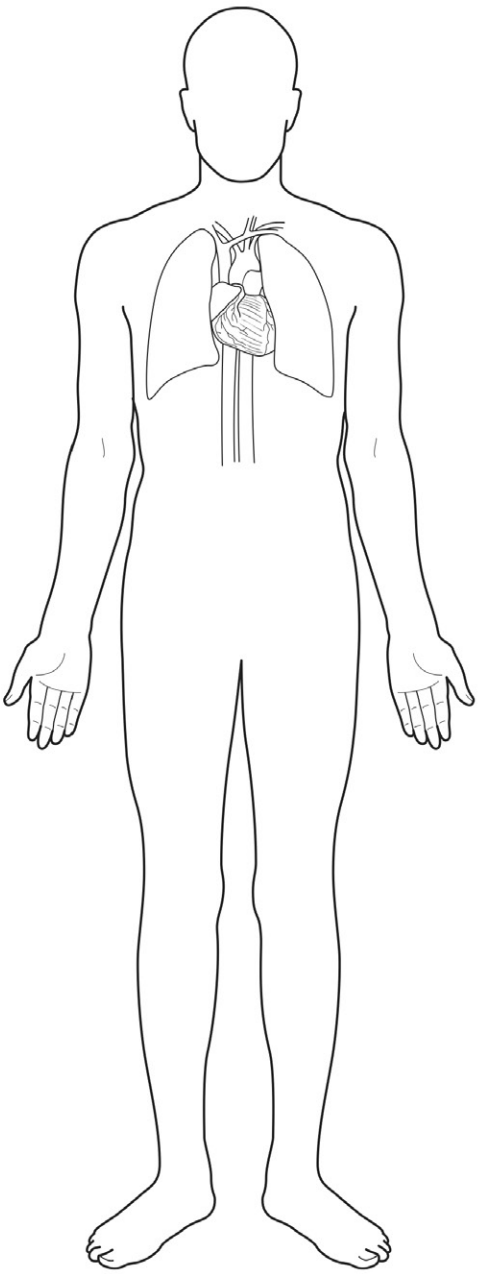

FIGURE **21.6** Outline of human body, anterior view.

Exercise 21-2

Lymphatic Organ Histology

MATERIALS

- ❑ Spleen section slide
- ❑ Lymph node slide
- ❑ Peyer's patch slide
- ❑ Palatine tonsil slide
- ❑ Light microscope
- ❑ Colored pencils

In this exercise, you will examine the microscopic anatomy of four different lymphatic organs and tissues: the spleen, a lymph node, a special type of MALT found in the terminal portion of the small intestine called a **Peyer's patch**, and the **palatine tonsil**. Following are some hints regarding what to look for on each slide.

1. **Spleen.** As you read in Exercise 21-1, the spleen consists of two types of tissue: **red pulp**, which is involved in the destruction of old and worn-out red blood cells, and **white pulp**, which contains phagocytes and lymphocytes that play a role in the immune system. Notice in Figure 21.7A that the red pulp is reddish in color, but the white pulp doesn't appear on the slide as white; instead, it appears as purplish "islands" within the red pulp. The purple color is caused by the presence of white blood cells, which have prominent nuclei that stain purple with commonly used stains.
2. **Lymph node.** Recall that lymph nodes have an outer **cortex** that contains spherical clusters of immune cells (primarily B lymphocytes) called lymphoid follicles. In the center of the follicle is a lighter-staining region consisting of B lymphocytes, dendritic cells, and macrophages called a **germinal center** (Fig. 21.7B). Deep to the lymphoid follicles we find an area of the cortex that houses primarily T lymphocytes. The innermost region of the node, called the **medulla**, houses primarily macrophages. The entire lymph node is surrounded by a capsule made of dense irregular collagenous connective tissue. Start first on low power and find the lymphoid follicles, then advance to higher powers to see them in greater detail.
3. **Peyer's patch. Peyer's patches** are clusters of MALT located in the terminal portion of the small intestine, which is called the *ileum*. This portion of the small intestine is continuous with the large intestine, which contains a large number of bacteria. The small intestine is sterile, meaning it normally contains no bacteria, so these Peyer's patches play an important role in protecting it from any bacteria that migrate in from the large intestine. The Peyer's patches somewhat resemble lymph nodes, although their lymphoid follicles and germinal centers are less well defined, and their capsules are incomplete or absent (Fig. 21.7C). To have the best chance of finding them, examine your section on low power, and look for the epithelial lining of the small intestine. Scroll downward (deep to the epithelium) into the connective tissue, where you will note large, oval or teardrop-shaped, purplish clusters. These are Peyer's patches.

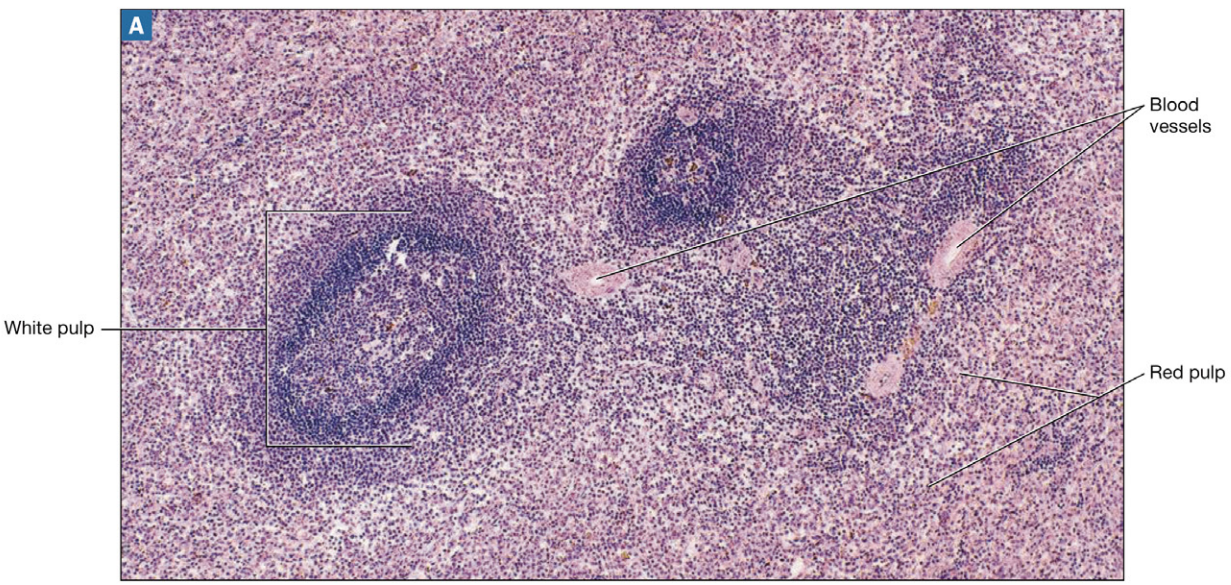

FIGURE **21.7** Lymphatic organs, photomicrographs: (**A**) spleen; *(continues)*

4. **Tonsil.** As tonsils have similar functions to MALT and lymph nodes, they also have a similar structure (Fig. 21.7D). Internally, they also consist of lymphoid follicles with germinal centers. Externally, however, they are lined with stratified squamous epithelium and feature deep indentations called **tonsillar crypts** that help to trap pathogens in the oral cavity. You will have the best chance of finding all of these structures by examining your slide on low power.

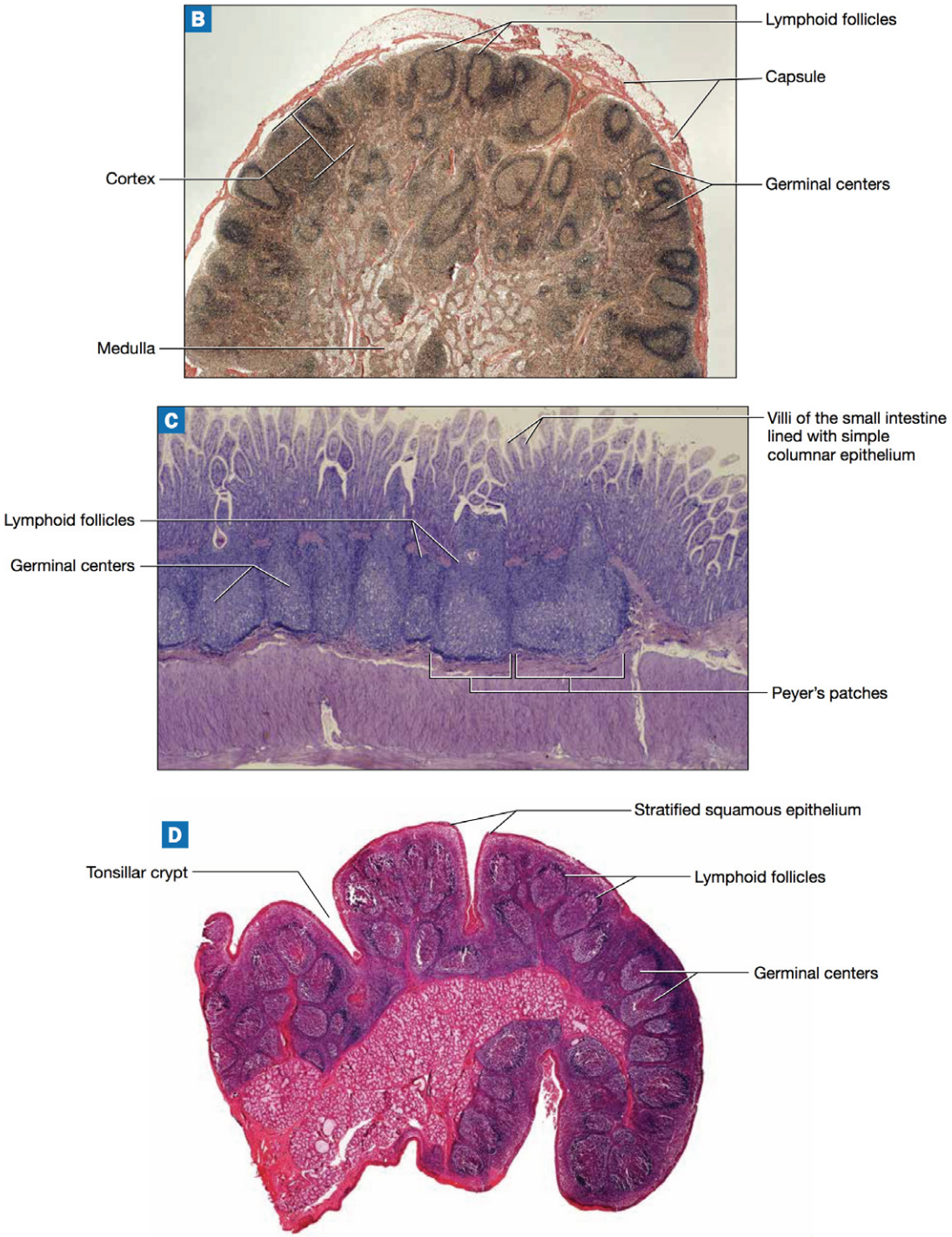

FIGURE **21.7** Lymphatic organs, photomicrographs *(cont.)*: (**B**) lymph node; (**C**) Peyer's patches in the ileum; (**D**) palatine tonsil.

Procedure 1 Microscopy

Obtain prepared slides of the spleen, a lymph node, the small intestine (the *ileum*), and the palatine tonsil. Use your colored pencils to draw what you see in the field of view, and label your drawing with the listed terms.

1 Spleen

1. Red pulp
2. White pulp



2 Lymph node

1. Capsule
2. Cortex
3. Medulla
4. Lymphoid follicle
5. Germinal center



3 Peyer's patch

1. Mucosa (simple columnar epithelium)
2. Peyer's patch
3. Lymphoid follicle
4. Germinal center



4 Palatine tonsil

1. Stratified squamous epithelium
2. Tonsillar crypt
3. Lymphoid follicle
4. Germinal center



Exercise 21-3

The Immune Response

The immune system may be divided into three lines of defense against tissue injury:

1. The first line of defense involves **surface barriers** that prevent the entry of pathogens into the body. Surface barriers include the skin and mucous membranes. Both provide continuous, avascular surfaces that secrete substances that deter the growth of microorganisms, wash away pathogens, or trap foreign particles.
2. The second line of defense consists of the responses of the cells and proteins that are collectively known as **innate immunity**, which reacts the same way to any invading organism or cellular injury. The components of innate immunity are named as such because we are born with these responses, and they do not require exposure to a foreign cell or molecule to be produced.
3. The third line of defense consists of the responses of the cells and proteins of **adaptive immunity**, which respond to foreign cells and molecules with a unique set of cells and molecules for each individual threat. The components of adaptive immunity do require exposure to a foreign agent to be produced, and for this reason they are often referred to as **acquired immunity**.

The responses of innate immunity may be subdivided into the following:

- **Inflammation and fever.** When cells are damaged by microorganisms, foreign cells, toxins, viruses, or trauma, the injured cells release chemicals called **inflammatory mediators**. The inflammatory mediators first attract local immune cells to the area, which are primarily macrophages as they reside in many tissues. Inflammatory mediators also stimulate local *vasodilation*, which causes the area to become red and warm; *increased capillary permeability*, which causes the area to become swollen; and *increased sensitivity to pain*. As this occurs, activated macrophages continue to release inflammatory mediators that attract other phagocytes, particularly neutrophils, to the damaged area in large numbers in a process called *chemotaxis*. Macrophages and other cells also produce inflammatory mediators called **pyrogens** (PY-roh-jenz) that act on the hypothalamus to raise the body temperature "set point." This results in the elevated temperatures known as **fever**.
- **Granulocytes and macrophages.** The body's main phagocytic cells, the **granulocytes** (**neutrophils**, **basophils**, and **eosinophils**) and the **macrophages** (mature monocytes), will nonspecifically ingest and destroy any foreign or damaged cell. Macrophages can perform this task repeatedly; however, neutrophils can ingest a cell only once, after which they die as well. When tissue damage is extensive, many neutrophils in one area will die and accumulate, leaving a whitish liquid called **pus**. Note that eosinophils and basophils can function as phagocytes, but their main role is to secrete inflammatory mediators such as histamine.
- **Antimicrobial proteins.** Several proteins in the blood will nonspecifically attack and lyse invading organisms when activated. The largest such system is the **complement system**, a collection of more than 20 proteins, most of which are made by the liver. Complement proteins perform a variety of functions, including lysing foreign cells, enabling phagocytes to function better, and enhancing the inflammatory response.

Adaptive immunity involves primarily B and T lymphocytes, which respond specifically to unique **antigens**, or chemical markers. Antigens are present in many molecules, such as toxins and allergens, and on the surfaces of all cells, including our own cells. Each population of T and B lymphocytes has a unique receptor that binds to a unique antigen.

There are two branches of adaptive immunity:

- **Humoral immunity. Humoral immunity**, which is also known as *antibody-mediated immunity*, is a response brought about by B lymphocytes and proteins they produce called **antibodies**. The humoral response is initiated when a macrophage or T lymphocyte presents a specific B lymphocyte with its unique antigen. This causes the B lymphocyte to activate and differentiate into two cell types: **plasma cells**, which secrete **antibodies**, and **memory cells**, which will "remember" the antigen and permit a more rapid antibody response upon subsequent exposures. As you learned in the blood unit, antibodies are proteins that bind and **agglutinate** antigens and facilitate their destruction by phagocytes and other components of the immune system. Antibodies also activate innate defenses, particularly complement defenses, and neutralize toxins such as venoms.
- **Cell-mediated immunity.** As its name implies, **cell-mediated immunity** is mediated by cells—specifically T lymphocytes—rather than by antibodies. Of the several different kinds of T lymphocytes, we will consider two here—the **CD4**, or **helper T cells**, and the **CD8**, or **cytotoxic T cells**. The cell-mediated response begins when a macrophage

ingests an antigen and presents it to the helper T cell that has a receptor to bind that specific antigen. The helper T cell then secretes chemicals called **cytokines** (SY-toh-kyn′z), which activate cells of innate immunity such as macrophages, encourage inflammation, activate B lymphocytes, and activate cytotoxic T cells. The activated cytotoxic T cells bind to cells whose antigens correspond to their receptors, and *lyse* and destroy them. The cells targeted by cytotoxic T cells may include those infected with viruses or intracellular bacteria, cancer cells, and transplanted cells. Both helper and cytotoxic T cells may become **memory T cells**, which "remember" the antigen and mount a stronger, faster response upon subsequent exposure.

Note that any kind of cell damage or invading organism is potentially met with all three lines of defense. For example, cancer cells are prevented from spreading by surface barriers; are phagocytized by granulocytes and macrophages in the blood and in the lymph nodes; are lysed by antimicrobial proteins released when healthy cells are damaged; cause local and systemic inflammation and fever; are met with an antibody response from B lymphocytes; and are located and lysed by cytotoxic T cells. This same cascade of responses is seen with viral infections, bacterial infections, envenomations, severe burns, major trauma, organ and tissue transplantations, fungal infections, parasitic infections, and more.

The immune response is . . . well, *complicated*, to say the least, and you could nearly fill this entire book tracing through everything that happens when you get a cold. The concept can be simplified somewhat because most types of invading organisms or cellular damage will trigger one type of response slightly more than the others. For example, bacterial infections tend to lead to elevated levels of neutrophils that phagocytize the bacterial cells. Similarly, viral infections and cancer cells tend to trigger a predominantly cell-mediated response and lead to elevated levels of cytotoxic T cells that lyse affected cells.

Procedure 1 Time to Trace!

In this exercise, you will be tracing two invaders: bacteria in the extracellular fluid that enter the lymphatic vessels and virus-infected cells that enter the blood. To keep things simple, you will trace the *main* pathway and the *main* immune response to the invading organism. Do note, however, that the actual response is much more complex, and your instructor may wish you to include more information. You are provided with hints and the number of steps you should aim to include for each organism, but you will likely want to consult your book for more help. After you have completed the activity, answer Check Your Understanding question 6 (p. 578).

Start: bacteria in the extracellular fluid ➜ bacteria damage local macrophages and damaged macrophages release _____ that attract _____ to the area ➜ these cells phagocytize _____ ➜ bacteria enter lymph capillaries ➜ bacteria travel through _____ vessels then enter lymphatic organs called _____ ➜ bacteria encounter macrophages in these organs ➜ macrophages _____ bacteria ➜ macrophages present antigens to B lymphocytes, which differentiate into _____ cells that proliferate and secrete proteins called _____, which _____ **End**

Start: virus-infected cells in the blood ➜ viruses damage tissue and damaged cells release _____ that attract local cells that reside in the tissue called _____ ➜ these cells release additional _____ and chemicals called _____ ➜ inflammation and fever begin ➜ virus-infected cells enter the blood ➜ virus-infected cells in the blood encounter macrophages in the lymphatic organ called the _____ ➜ macrophages _____ infected cells ➜ macrophages present antigens to _____ T cells ➜ this group of T cells proliferates and secretes _____ , which activate _____ T cells ➜ this group of T cells _____ and _____ infected cells **End**

Exercise 21-4

ELISA Test for Antigens

MATERIALS

- ❑ ELISA well plate
- ❑ Micropipettor and tips
- ❑ Microcentrifuge tube with "blood" sample
- ❑ Empty microcentrifuge tube
- ❑ Antibody solution
- ❑ Colorant solution
- ❑ Washing solution
- ❑ Sharpie

One of the most commonly performed diagnostic laboratory tests is **ELISA**, which stands for **enzyme-linked immunosorbent assay**. ELISA allows you to detect the presence of an antigen from a sample using a reaction with a specific antibody. Laboratories commonly use ELISA to determine if an individual has been exposed to certain infectious agents such as influenza or HIV.

The basic procedure for the type of ELISA we use in this exercise is outlined in Figure 21.9 on page 571. As you can see, solutions are added to wells, and any antigens present in the solution bind to the base of the wells. The solutions are allowed to sit for 5 minutes, after which a washing solution is applied to remove any unbound antigens. In the next step, a solution containing antibodies is added to all three wells. Again, the solutions are allowed to sit undisturbed for 5 minutes, after which a second washing solution is applied. Antibodies that have bound to their specific antigens will remain in the wells, whereas those that did not bind to antigens will be washed away.

In the final step, a colorant that reacts with an enzyme associated with the antibody is added to the solution. Notice in Figure 21.8 that the colorants in wells 1 and 2 react with the enzyme on the antibody and change the color of the solution. This is read as a positive result, meaning that the antigen for which you were initially testing was present in the solution. Well 3, on the other hand, has no antibodies with which the colorant can react, and so it does not change color. This is interpreted as a negative reaction, meaning your test solution did not contain the antigen in question.

In this exercise, you will be demonstrating the spread of infection of the "influenza virus" through your class (note that no samples have the actual influenza virus—the antigens in the samples are harmless). Each student will be given a sample that represents his or her own "blood." One or two random members of your class will receive a sample that has the antigen; these samples represent the "infected" individuals. During the first part of the procedure (steps 1 through 4), you will exchange and combine portions of your sample with three classmates. For the second part (step 5; see Fig. 21.9), you will run the ELISA and determine who among your classmates has become infected with the flu! When you have completed the procedure, answer Check Your Understanding question 7 (p. 578).



Three samples are placed in wells. Note that the sample placed in wells 1 and 2 have antigen; the sample placed in well 3 has no antigen.

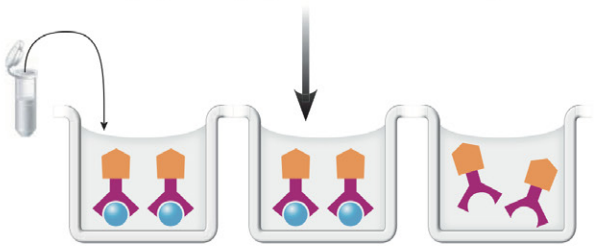

An antibody solution is added to all three wells. The antibodies bind to the antigens in wells 1 and 2 and are not removed in the washing step. The antibodies in well 3 do not bind to antigens and so are washed away in the washing step.

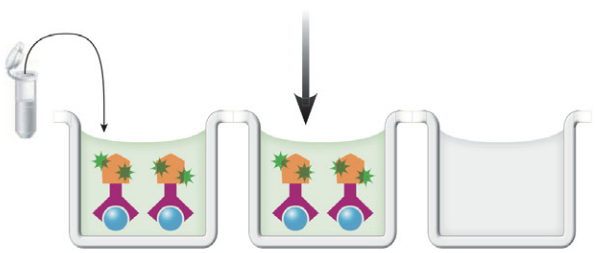

A colorant is added that binds to an enzyme associated with the antibody. This leads to a colored solution in wells 1 and 2 and no color in well 3.

FIGURE **21.8** Interpretation of ELISA results.

Procedure 1 Who's Got the Flu?

1. Obtain two microcentrifuge tubes from your instructor: one empty and one containing a fluid to be your "blood" sample. Write your initials on both tubes with a Sharpie.
2. Use a micropipettor to withdraw 200 µl of your sample, and transfer it to the empty tube. Set this tube aside for now.
3. At your instructor's prompt, begin the swapping portion of the lab. Note that you should choose partners from the entire lab, not just your immediate lab group.
   - **a** Randomly choose a partner in your lab. Each of you will use a micropipettor to withdraw 100 µl of your sample, and place it into one another's microcentrifuge tube.
   - **b** Use the tip of your micropipettor to mix your remaining solution with your partner's solution so that they are thoroughly mixed.
   - **c** Choose another partner in your lab, and repeat the procedure. Your tube should now contain your original sample and portions of two of your classmates' samples.
   - **d** Choose your third and final partner, and repeat the procedure. At the end, your microcentrifuge tube will contain four total samples: yours and three from your classmates. Record the names of each of your partners here:

     Partner 1: _____

     Partner 2: _____

     Partner 3: _____
4. Mix your sample thoroughly, and then transfer 100 µl into three wells on your group's ELISA plate using a micropipettor (300 µl total). You are running three tests to ensure that your results are accurate.
5. When all partners have added their samples to the wells, follow the ELISA procedural steps illustrated in Figure 21.9:
   - **a** Allow the plate to sit undisturbed on your lab table for 5 minutes.
   - **b** After 5 minutes have passed, empty the contents of the plate into a sink or designated container. If antigens were present in your solution, they will be bound to the bottom of the well.



Step 5a: When everyone has added samples to the wells, allow the plate to sit undisturbed on your lab table for 5 minutes.



Step 5b: After 5 minutes have passed, empty the contents of the plate into a sink or designated container. If antigens were present in your solution, they will be bound to the bottom of the well.

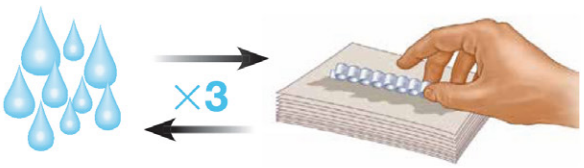

Step 5c: Rinse the wells with washing solution, and discard the fluid in the sink or designated container. Repeat this procedure three times.

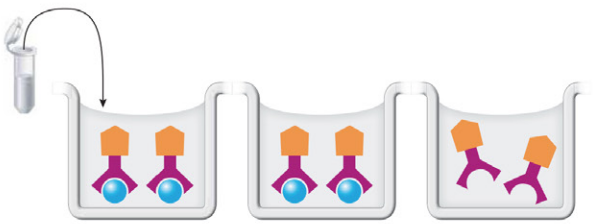

Step 5d: Add about three drops (100 µl) of antibody solution to each well. Allow the plate to sit undisturbed on your lab table for 5 minutes.



Step 5e: Discard the fluid in the sink or designated container. Rinse the wells with washing solution three times.

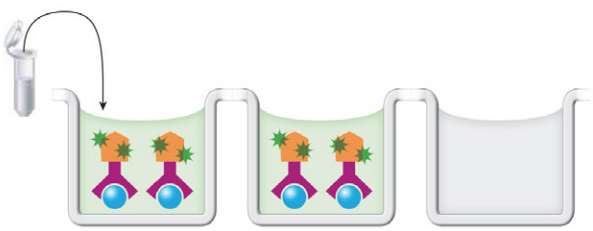

Step 5f: Add about three drops (100 µl) of colorant solution to each well. Allow the plate to sit undisturbed on your lab table for 5 minutes.

FIGURE **21.9** ELISA procedure.

c Rinse the wells with washing solution, and discard the fluid in the sink or designated container. Repeat this procedure three times.

d Add about three drops (100 µl) of antibody solution to each well. Allow the plate to sit undisturbed on your lab table for 5 minutes.

e Discard the fluid in the sink or designated container, and rinse the wells with washing solution three times.

f Add about three drops (100 µl) of colorant solution to each well. Allow the plate to sit undisturbed on your lab table for 5 minutes.

6 Interpret your results. Who among your group was infected with the flu?

7 Compile the results for your class.

a How many were infected? _____

b Determine as a class who you believe had the initial infected sample(s). _____

8 Determine to whom the initial infected sample belonged by running an ELISA on the microcentrifuge tube you set aside at the beginning of the procedure. Repeat step 5 with this uncontaminated sample.

9 Who in your class had the initial infected sample(s), according to these results?

Name _____

Section _____ Date _____

UNIT 21 REVIEW

Check Your Recall

1 Label Figure 21.10 with the terms below.

- ❑ Axillary lymph nodes
- ❑ Cervical lymph nodes
- ❑ Cisterna chyli
- ❑ Inguinal lymph nodes
- ❑ Right lymphatic duct
- ❑ Spleen
- ❑ Thoracic duct
- ❑ Thymus

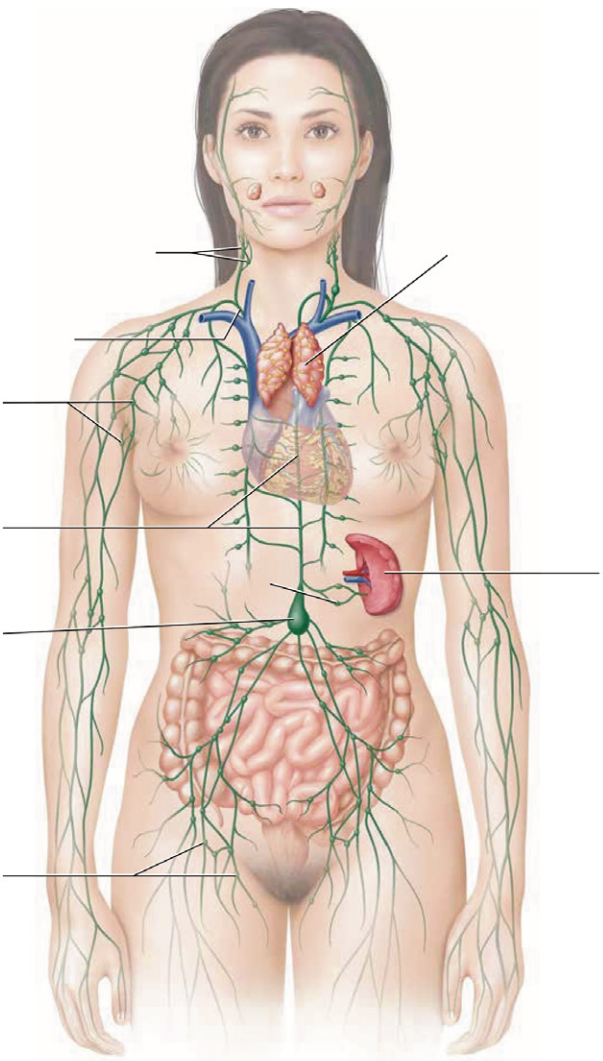

FIGURE **21.10** Overview of the lymphatic organs and vessels.

2 Label Figure 21.11 with the terms below.

- ❑ Cortex
- ❑ Germinal center
- ❑ Lingual tonsil
- ❑ Lymphoid follicle
- ❑ Medulla
- ❑ Palatine tonsil
- ❑ Pharyngeal tonsil

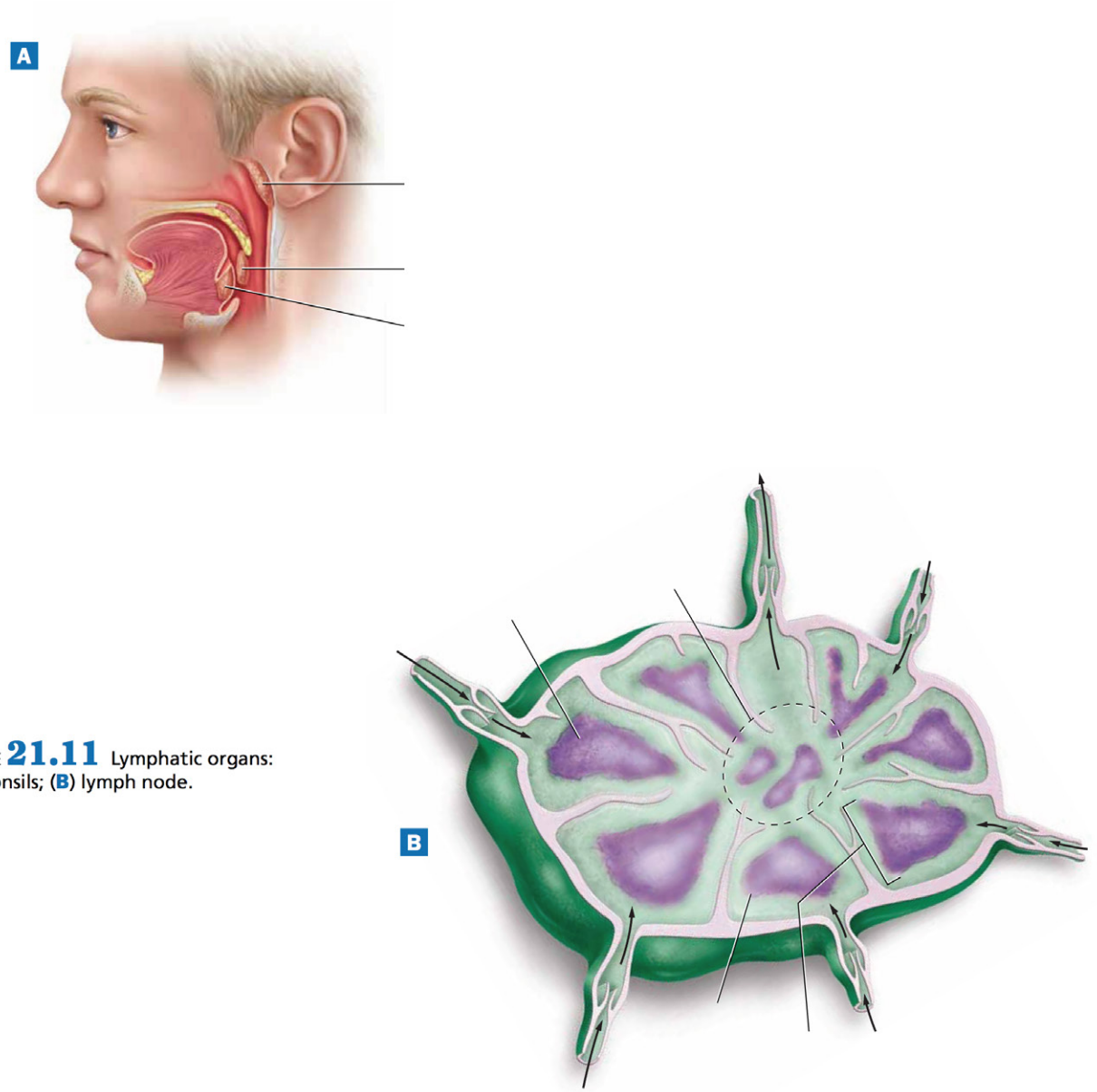

FIGURE **21.11** Lymphatic organs: (A) tonsils; (B) lymph node.

21

Name _____

Section _____ Date _____

3 Which of the following is not a function of the lymphatic system?

a. Maintaining blood glucose levels.
b. Absorbing dietary fats.
c. Activating the immune system.
d. Transporting excess interstitial fluid back to the heart.

4 *True/False:* Mark the following statements as true (T) or false (F). If the statement is false, correct it to make it a true statement.

_____ a. The thoracic duct drains lymph from the right upper limb and the right side of the head, neck, and thorax.

_____ b. The spleen filters lymph, whereas lymph nodes filter blood.

_____ c. Lymph capillaries surround blood capillaries and pick up excess interstitial fluid to return it to the blood.

_____ d. Tonsils are specialized MALT that are partially encapsulated.

5 What is the function of the thymus?

a. Traps pathogens in lymph.
b. Filters the blood.
c. Mediates inflammation.
d. Serves as the site of T lymphocyte maturation.

6 Lymph from the intestinal lymph trunks drains into the _____ and contains _____.

a. lymphatic capillaries; fats
b. cisterna chyli; fats
c. lacteal; proteins
d. blood capillaries; proteins

7 Describe the components and functions of the three lines of immune defense.

8 Explain how each of the following sets of terms differ.

a Innate immunity and adaptive immunity

b Cell-mediated immunity and humoral immunity

9 Which of the following is not a part of adaptive immunity?

a. Inflammation and fever.
b. Antibodies.
c. Cell-mediated immunity.
d. B lymphocytes.
e. Humoral immunity.

10 *Fill in the blanks:* When tissues are damaged, macrophages release inflammatory mediators that cause _____, _____, and _____. Certain inflammatory mediators called _____ increase the hypothalamus' "set point" for temperature and cause fever.

Name _____

Section _____ Date _____



REVIEW

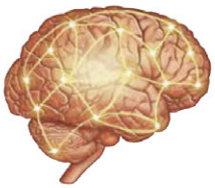

Check Your Understanding

Critical Thinking and Application Questions

1 Nilesh has Hodgkin's lymphoma, a cancer that primarily involves lymphocytes. As part of his treatment plan, he is undergoing surgery to remove his spleen, a procedure called a *splenectomy*, and several affected cervical lymph nodes.

a How does the role of the spleen differ from the role of lymph nodes?

b What potential complications might Nilesh face without a spleen? Explain.

c How would the complications in part b differ from potential issues resulting from removal of multiple cervical lymph nodes?

2 The condition *aplastic anemia* is characterized by complete failure of the bone marrow to produce formed elements of the blood due to damaged hematopoietic stem cells. Explain how aplastic anemia would affect the immune response.

3 Explain why blockage or removal of the lymphatic vessels can result in significant *edema* (accumulation of fluid in a limb or body part).

4 Juliet is a 42-year-old patient who is preparing to undergo surgery to remove her thymus gland, which has a tumor (a *thymoma*). She has read about the thymus and its functions and is concerned that her immune system will be much weaker after the surgery. What do you tell her, and why?

5 As you learned, the tonsils are only partially encapsulated. How does this better enable them to perform their function? How does this also place them at greater risk for infection?

6 After his surgery, Nilesh (from question 1) developed a fever. Prior to the surgery, he was undergoing chemotherapy with drugs that are known to kill healthy bone marrow cells as well as cancerous cells. Considering this, why do you think Nilesh's fever is of particular concern to his medical team?

7 You are running an ELISA on a sample to test for the presence of antigens from the *influenza A virus*. When it comes time to add the antibody, you realize that you only have antibodies for the *influenza B virus*. Would these antibodies give you accurate results? Why or why not?

UNIT
22

Respiratory System Anatomy

Once you have completed this unit, you should be able to:

1 Identify structures of the respiratory system.

2 Trace the pathway of gases through the respiratory system.

3 Identify histological structures of the respiratory system on microscope slides.

Name _____ Section _____ Date _____

PRE-LAB EXERCISES

Complete the following exercises prior to coming to lab, using this lab manual and your textbook for reference.

Pre-Lab Exercise 22-1

Key Terms

You should be familiar with the following terms before coming to lab.

Term	Definition

General Structures of the Respiratory System

Respiratory tract _____

Parietal pleura _____

Visceral pleura _____

Pleural cavity _____

Lungs and lobes _____

Structures of the Respiratory Tract

Nasal cavity _____

Pharynx _____

Larynx _____

Trachea _____

Primary bronchi _____

Secondary bronchi _____

Name _____ Section _____ Date _____

Terminal bronchioles _____

Respiratory bronchioles _____

Alveolar ducts _____

Alveoli _____

Pre-Lab Exercise 22-2

Respiratory System Anatomy

Label and color the diagrams of the structures of the respiratory system in Figure 22.1 with the terms from Exercise 22-1 (p. 585). Use your text and Exercise 22-1 in this unit for reference.

A

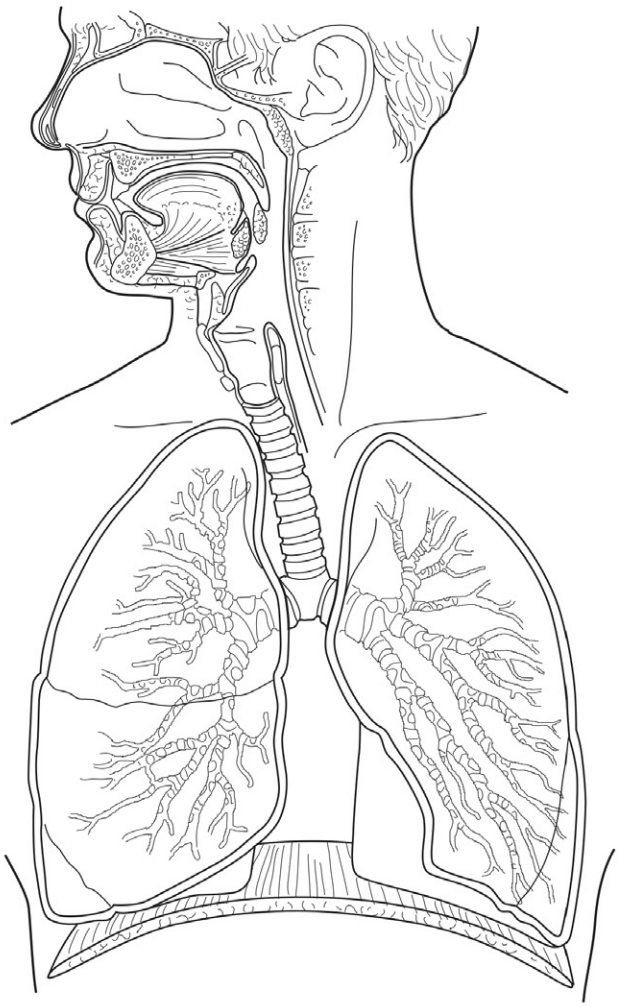

FIGURE **22.1** Structures of the respiratory system: (**A**) anatomy of the lungs and respiratory tract; *(continues)*

B

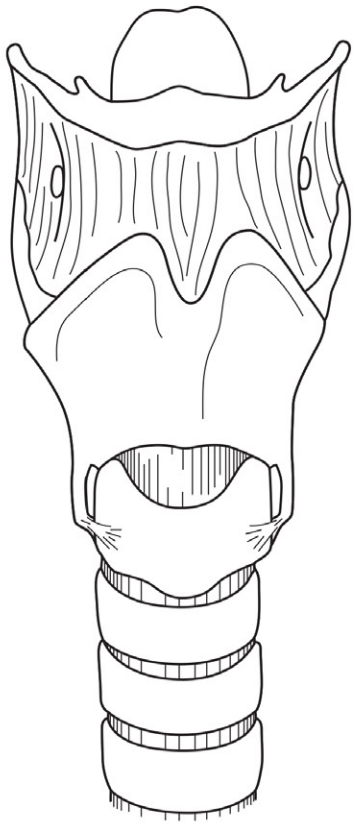

C

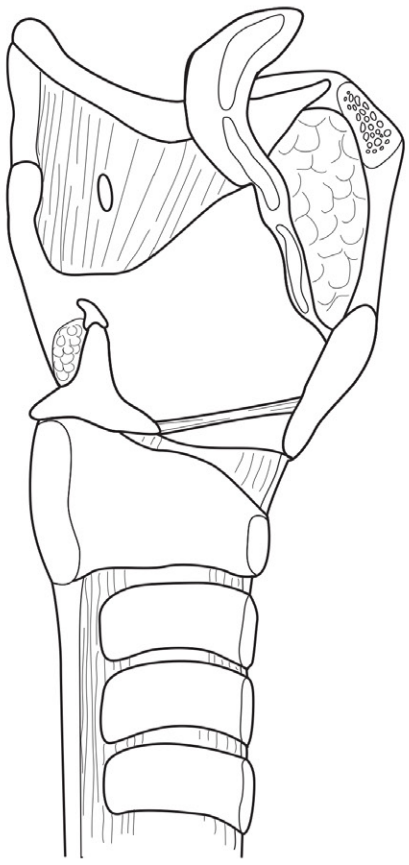

FIGURE **22.1** Structures of the respiratory system *(cont.)*: (**B**) the larynx, anterior view; (**C**) the larynx, midsagittal section;

(continues)

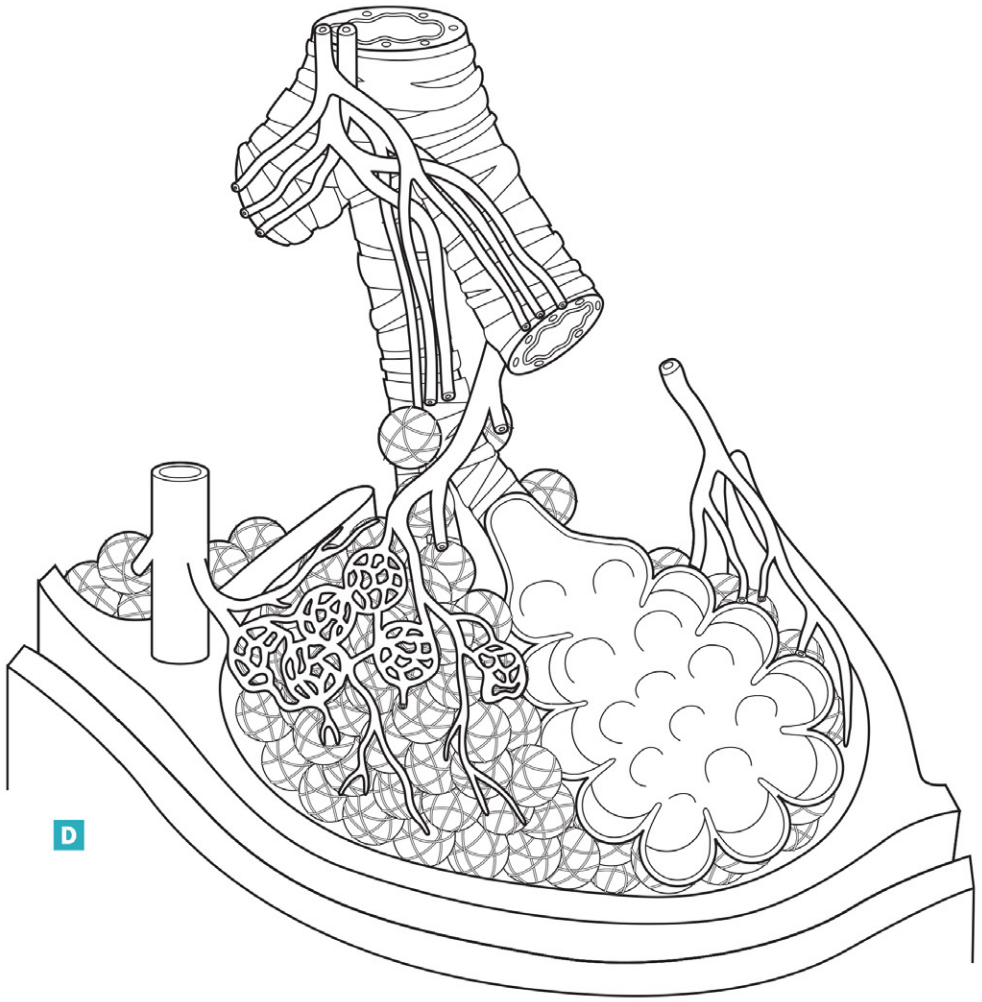

FIGURE **22.1** Structures of the respiratory system *(cont.)*: (**D**) bronchiole and alveolar sac.

Ciliated epithelium of the respiratory tract.

EXERCISES

Cells require oxygen in the processes that synthesize ATP, and these reactions produce carbon dioxide as a waste product. The respiratory system and the cardiovascular system work together to supply the cells with the oxygen they need and to rid the body of carbon dioxide.

The exercises in this unit will familiarize you with the organs and histology of the respiratory system, including the paired *lungs* and the collection of airway passages known as the *respiratory tract*. In the final exercise you will observe how the changes in pressure of the thoracic cavity lead to changes in lung volume with the process known as *pulmonary ventilation*.

Exercise 22-1

Respiratory System Anatomy

MATERIALS

- ❑ Lung models
- ❑ Larynx models
- ❑ Alveolar sac model
- ❑ Head and neck model
- ❑ Colored pencils

The lungs are composed of elastic connective tissue and tiny air sacs called **alveoli** (al-vee-OH-lye), where gas exchange takes place. Each lung is divided into smaller structures called **lobes**. The right lung has three lobes (upper, middle, and lower), and the left lung has two lobes (upper and lower) (Fig. 22.2). The lobes are separated from one another by deep indentations called **fissures**. The **horizontal fissure** separates the right upper and right middle lobes; the **right oblique fissure** separates the right middle and right lower lobes; and the **left oblique fissure** separates the left upper and left lower lobes. The left upper lobe has a groove, called the **cardiac notch**, on its medial surface where it comes into contact with the heart. Each lung has an **apex** that sits just above the clavicle, and a **base** that rests on the **diaphragm muscle**, the main muscle for ventilation.

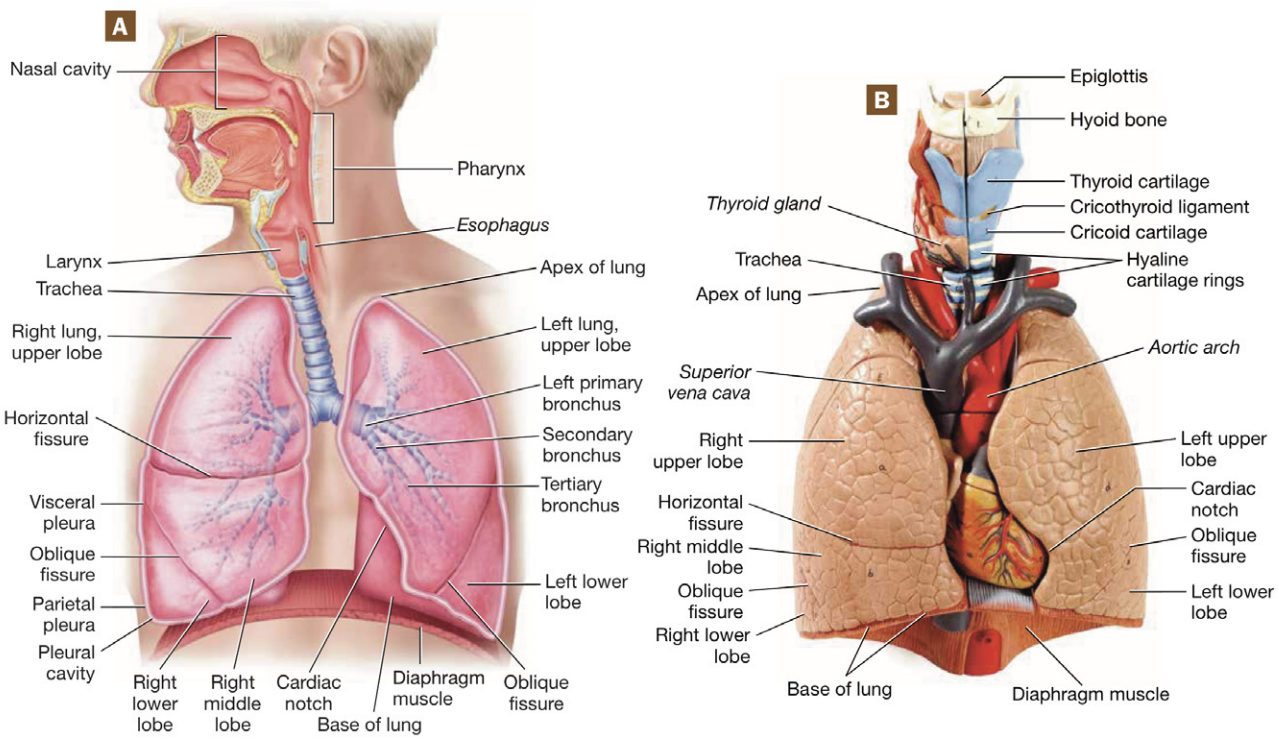

FIGURE **22.2** Anatomy of the lungs and respiratory tract: (**A**) illustration; (**B**) model photo.

Each lung is surrounded by serous membranes, similar in structure and function to the pericardial membranes, known as the **pleural membranes** (PLOO-ruhl). There are two layers of the pleural membranes:

1. **Parietal pleura.** The outer **parietal pleura** lines the interior of the thoracic cavity and the superior surface of the diaphragm.
2. **Visceral pleura.** When the parietal pleura reaches the structures of the mediastinum, it folds inward to become the **visceral pleura.** The visceral pleura adheres tightly to the surface of the lung.

The very thin potential space between the parietal and visceral pleurae is the **pleural cavity.** The space is only a "potential" space because it is filled with a thin layer of serous fluid that reduces friction as the lungs change in shape and size during ventilation.

If we flip a lung on its side and examine its medial or mediastinal surface (the surface that faces the mediastinum), as we do in Figure 22.3, we can see an area called the **hilum** (HY-lum) of the lung. This is an indentation where the pulmonary vessels, nerves, lymphatic vessels, and airway passages called *primary bronchi* enter and exit the lungs.

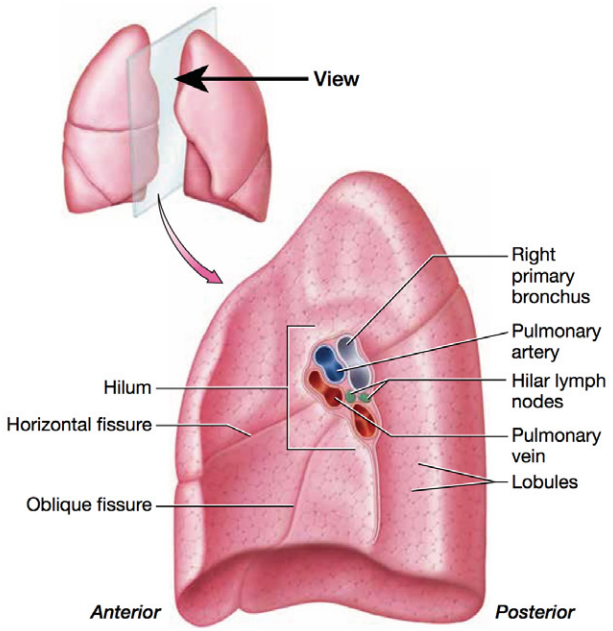

FIGURE **22.3** Mediastinal surface of the right lung.

Air is delivered to the lungs' alveoli through the passageways of the **respiratory tract.** The respiratory tract may be divided into two regions according to both structure and function. Structurally, it is divided into (1) the *upper respiratory tract*, which consists of the passages from the nasal cavity to the larynx; and (2) the *lower respiratory tract*, which consists of the passages from the trachea to the alveoli. Functionally, it is divided into the conducting zone and respiratory zone. The *conducting zone* consists of passages that carry, or "conduct," air to where gas exchange takes place. Most of the respiratory tract belongs to the conducting zone. The *respiratory zone* consists of the passages in which gas exchange takes place, located in the terminal respiratory tract.

The conducting zone begins with the **nasal cavity** (Fig. 22.4), which warms, filters, and humidifies the incoming air. Air first enters through the **nares** (or nostrils) and the hair-lined *vestibule*, then enters the actual nasal cavity. Lining the walls of the nasal cavity are three projections known as the **superior, middle,** and **inferior nasal conchae** (KAHN-kee). These projections make airflow turbulent, which removes dust and other debris from the inhaled air. The nasal cavity is lined with pseudostratified ciliated columnar epithelium with copious mucus-secreting **goblet cells,** a type of tissue known as **respiratory epithelium.**

22

Air flow is continuous between the nasal cavity and the **paranasal sinuses,** which assist in filtering, warming, and humidifying the inhaled air. Recall from Unit 8 that there are four paranasal sinuses: the frontal, maxillary, ethmoid, and sphenoid sinuses (see Figure 8.12, p. 188, for a review).

From the nasal cavity, air next enters the **pharynx** (FEHR-inks), also known as the throat, which has the following three divisions:

1. **Nasopharynx.** The **nasopharynx** (nayz-oh-FEHR-inks) is the region posterior to the nasal cavity, color-coded green in Figure 22.4A. The muscles of the soft palate and *uvula* move superiorly to close off the nasopharynx during swallowing to prevent food from entering the passage. Sometimes this mechanism fails (such as when a person is laughing and swallowing simultaneously), and the unfortunate result is that food or liquid comes out of the nose. Like the nasal cavity, the nasopharynx is lined with respiratory epithelium.
2. **Oropharynx.** The **oropharynx** (ohr-oh-FEHR-inks) is the region posterior to the oral cavity, color-coded yellow in Figure 22.4A. Both food and air pass through the oropharynx, and it is therefore lined with stratified squamous epithelium. This tissue provides more resistance to mechanical and thermal stresses.

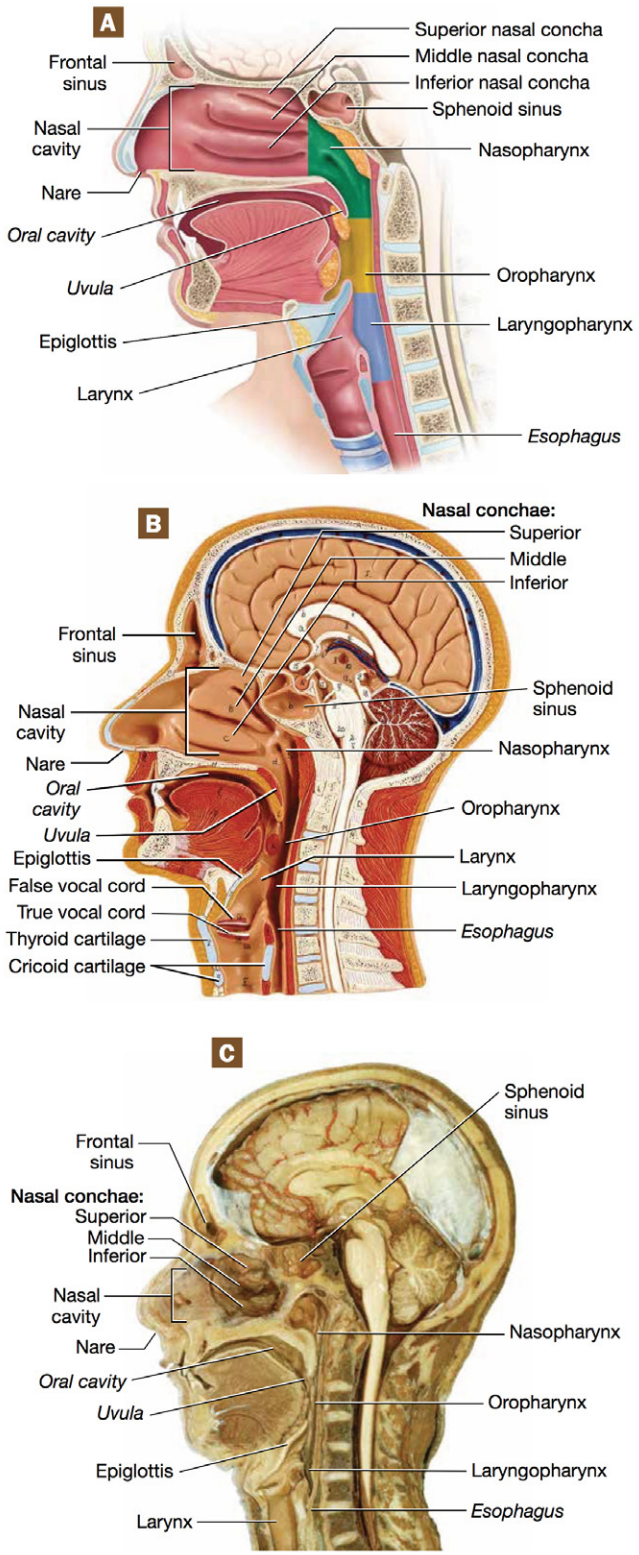

FIGURE **22.4** Midsagittal section of the head and neck: (**A**) illustration; (**B**) model photo; (**C**) cadaver dissection.

3. **Laryngopharynx.** The **laryngopharynx** (lah-ring-oh-FEHR-inks) is the intermediate region between the larynx and the esophagus, color-coded light blue in Figure 22.4A. As with the oropharynx, both food and air pass through the laryngopharynx, and it is lined with stratified squamous epithelium.

Next, air passes from the pharynx to the **larynx** (LEHR-inks), a short passage framed by the hyoid bone and nine cartilages (Fig. 22.5). The "lid" of the larynx is a piece of elastic cartilage called the **epiglottis** (ep-ih-GLAW-tiss). During swallowing, muscles of the pharynx and larynx move the larynx superiorly, and the epiglottis seals off the larynx from food and liquids. The largest cartilage of the larynx is the shieldlike **thyroid cartilage,** which is inferior to the hyoid bone and forms the larynx's anterior and lateral walls. Inferior to the thyroid cartilage is the smaller **cricoid cartilage** (KRY-koyd), which is the only cartilage in the respiratory tract that is a complete ring—the remainder are C-shaped. The thyroid and cricoid cartilages are united by a connective tissue membrane called the **cricothyroid ligament** (kry-koh-THY-royd). The smaller cartilages of the larynx include the **arytenoid** (uh-RIT-uh-noyd), **corniculate** (kor-NIK-yoo-layt), and **cuneiform cartilages** (kyoo-NEE-ih-form), which are found in its posterior and lateral walls (Fig. 22.5C).

As its common name "voice box" implies, the larynx is the structure where sound is produced. As you can see in Figure 22.5C, it contains two sets of elastic ligaments known as the **vocal folds** or **vocal cords.** The superior set of vocal folds, the **false vocal cords** (also called the *vestibular folds*), plays no role in sound production. They do, however, serve an important sphincter function and can constrict to close off the larynx. The inferior set of vocal folds, called the **true vocal cords,** vibrates as air passes over it to produce sound. Superior to the vocal cords, the larynx is lined with stratified squamous epithelium; inferior to the vocal cords, it is lined with respiratory epithelium, as is the remainder of the respiratory tract until we reach much smaller passageways.

Inspired air passes from the larynx into a passage supported by C-shaped rings of hyaline cartilage called the **trachea** (TRAY-kee-uh; Fig. 22.6). The trachea bifurcates in the mediastinum at its final cartilage ring, called the **carina** (kuh-RY-nuh), into two **primary bronchi** (BRONG-kye) that begin the large and branching **bronchial tree** (BRONG-kee-uhl). The right primary bronchus is short, fairly straight, and wide, and the left primary bronchus is long, more horizontal, and narrow because of the position of the heart.

Each primary bronchus divides into smaller **secondary bronchi,** each of which serves one lobe of the lung. The two left secondary bronchi serve the two

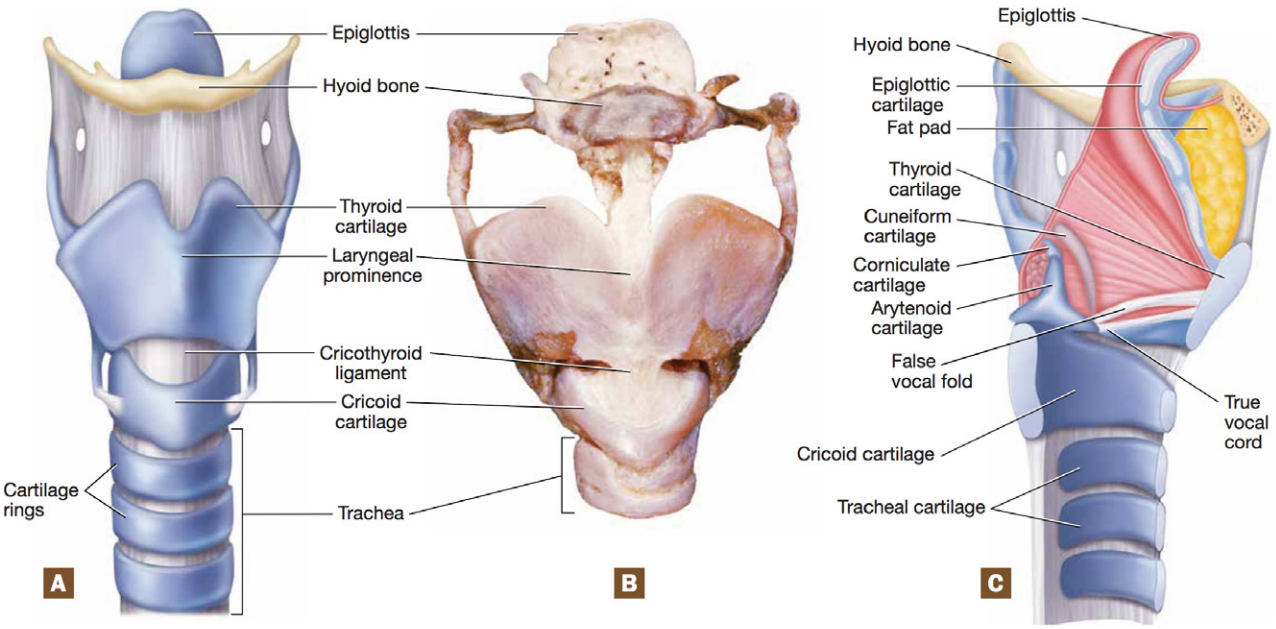

FIGURE **22.5** Larynx: (**A**) anterior view; (**B**) anterior view from a cadaver; (**C**) midsagittal section.

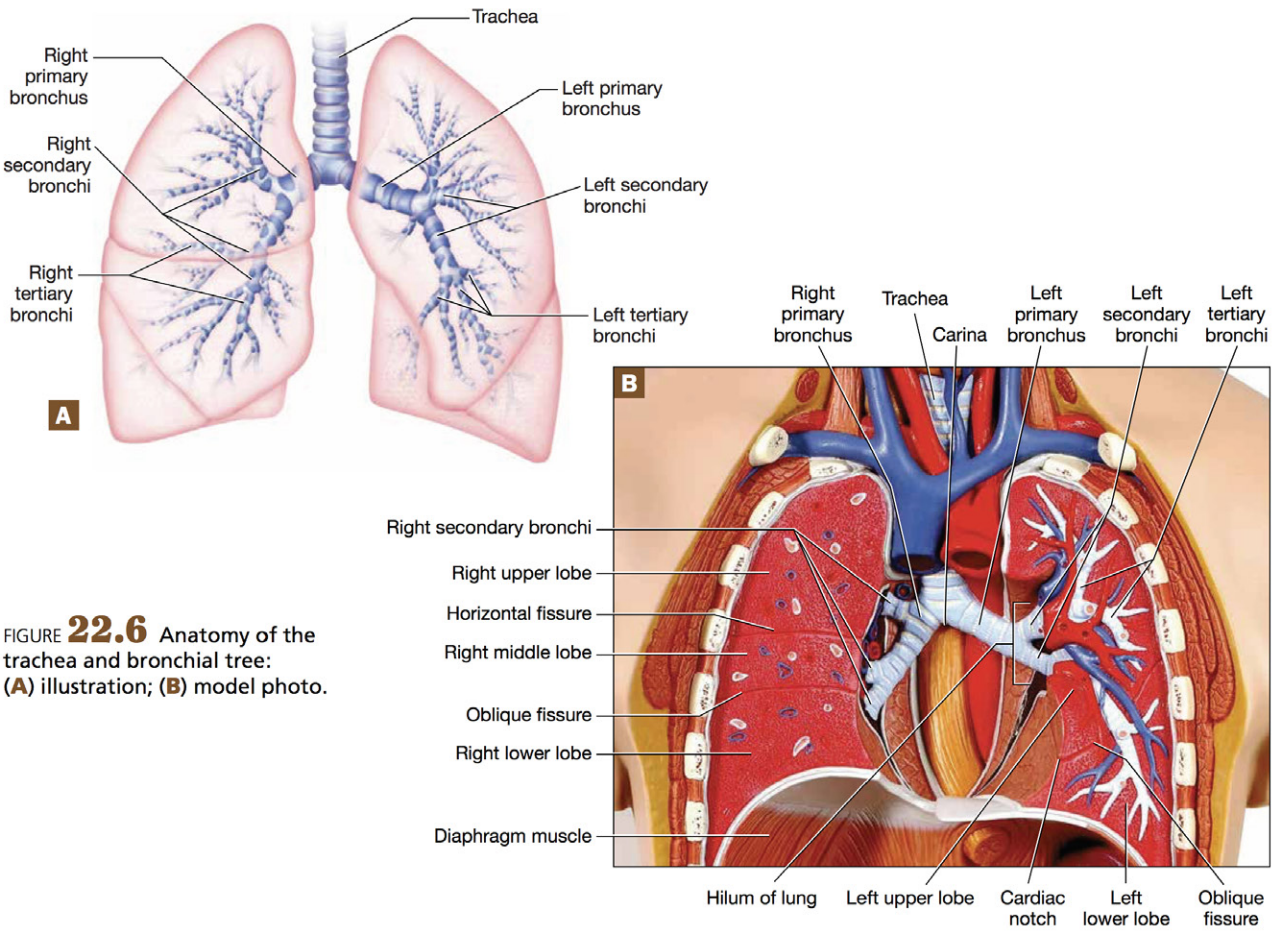

22

FIGURE **22.6** Anatomy of the trachea and bronchial tree: (**A**) illustration; (**B**) model photo.

lobes of the left lung, while the three right secondary bronchi serve the three lobes of the right lung. The bronchi continue to branch and become tertiary bronchi, quaternary bronchi, and so on until the air reaches tiny air passages smaller than 1 millimeter in diameter called **bronchioles** (BRONG-kee-ohlz; Fig. 22.7). At this level, the epithelium changes to simple cuboidal epithelium.

Bronchioles smaller than 0.5 mm in diameter are called the **terminal bronchioles**, and these mark the end of the conducting zone. The respiratory zone begins with small branches called **respiratory bronchioles** that have alveoli in their walls. As the respiratory bronchioles progressively branch, the number of alveoli in their walls increases until the walls are made up exclusively of alveoli, at which point they are termed an **alveolar ducts** (al-vee-OH-lahr). The terminal portions of the respiratory zone, called **alveolar sacs**, are grapelike clusters of alveoli.

The alveoli are surrounded by **pulmonary capillaries**, which are fed by pulmonary arterioles and drained by pulmonary venules. The capillary-alveolus junction, along with their fused basal laminae, forms a structure known as the **respiratory membrane**, which is where pulmonary gas exchange takes place. During pulmonary gas exchange, oxygen from the air in the alveoli diffuses into the blood, and carbon dioxide from the blood diffuses into the air in the alveoli to be exhaled. Alveolar walls and capillary walls are both composed of simple squamous epithelium, so the gases have only a short distance to diffuse, which is critical to effective gas exchange. In addition, the structure of the alveolar sacs creates a huge surface area (around 1,000 square feet on average), another factor that allows gas exchange to take place rapidly and efficiently.

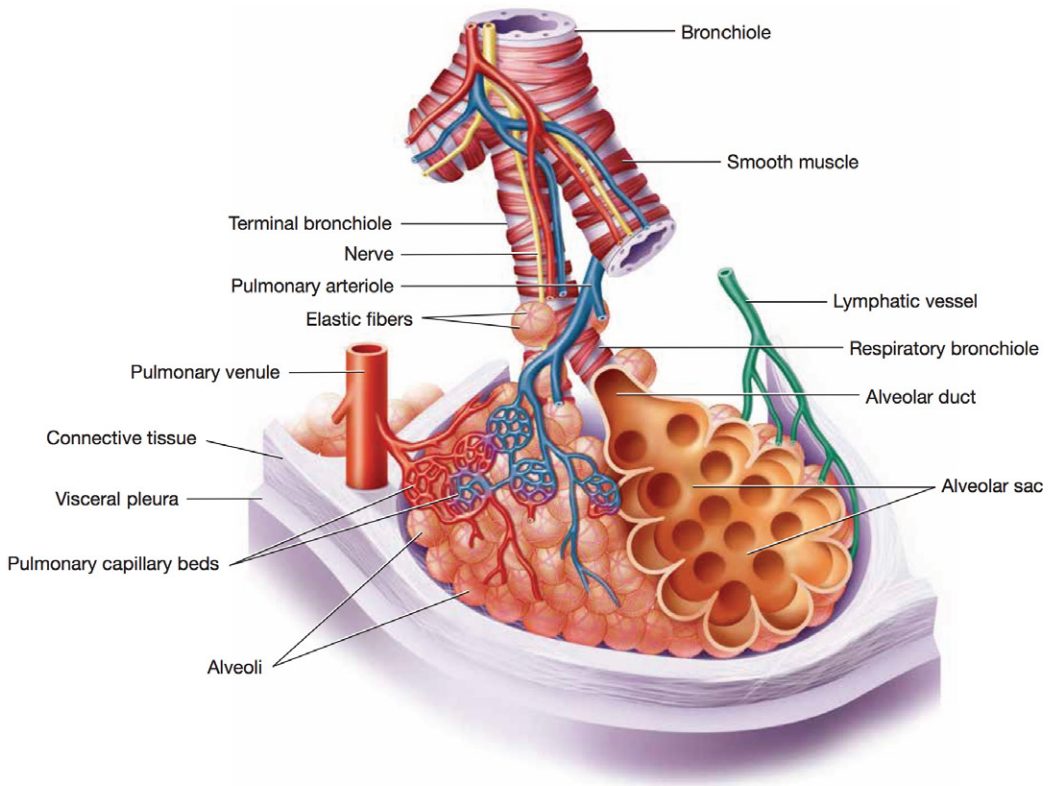

FIGURE **22.7** Bronchiole and alveolar sac.

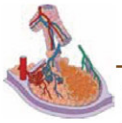

Procedure 1 Model Inventory for the Respiratory System

Identify the following structures of the respiratory system on models and diagrams, using your textbook and this unit for reference. As you examine the anatomical models and diagrams, record the name of the model and the structures you were able to identify on the model inventory in Table 22.1. After you have completed the activity, answer Check Your Understanding questions 1 through 3 (p. 603).

1. Right lung
   a. Upper, middle, lower lobes
   b. Horizontal fissure
   c. Oblique fissure
2. Left lung
   a. Upper and lower lobes
   b. Oblique fissure
   c. Cardiac notch
3. Lungs, general
   a. Apex
   b. Base
   c. Diaphragm muscle
   d. Pleurae
      (1) Parietal pleura
      (2) Visceral pleura
      (3) Pleural cavity
   e. Hilum
4. Nasal cavity
   a. Nares
   b. Nasal conchae
      (1) Superior nasal conchae
      (2) Middle nasal conchae
      (3) Inferior nasal conchae
   c. Paranasal sinuses
      (1) Frontal sinus
      (2) Maxillary sinus
      (3) Ethmoid sinus
      (4) Sphenoid sinus
5. Pharynx
   a. Nasopharynx
   b. Oropharynx
   c. Laryngopharynx
6. Larynx
   a. Hyoid bone
   b. Epiglottis
   c. Thyroid cartilage
   d. Cricoid cartilage
   e. Cricothyroid ligament
   f. Arytenoid cartilages
   g. Corniculate cartilages
   h. Cuneiform cartilages
   i. False vocal cords
   j. True vocal cords
7. Trachea
   a. Hyaline cartilage rings
   b. Carina
8. Bronchi
   a. Right and left primary bronchi
   b. Secondary bronchi
   c. Tertiary bronchi
9. Bronchioles
   a. Terminal bronchioles
   b. Respiratory bronchioles
   c. Alveolar duct
10. Alveoli and alveolar sacs

TABLE **22.1** Model Inventory for the Respiratory System

Model/Diagram	Structures Identified

Procedure 2 Time to Draw

In the space below, draw, color, and label one of the respiratory system models that you examined. In addition, write the function of each structure that you label.

Procedure 3 Time to Trace!

In this next procedure, you will trace the pathway taken by oxygen and carbon dioxide molecules through the respiratory tract and through parts of the systemic and pulmonary vascular circuits. When you have completed your tracings, answer Check Your Understanding question 4 (pp. 603–604).

Part 1

You are a molecule of oxygen floating happily through the atmosphere when all of a sudden you are inhaled by Ms. Magenta.

1 Trace your pathway through Ms. Magenta's respiratory tract beginning in her nasal cavity to the point at which you cross the respiratory membrane and enter the pulmonary capillaries.

Start: _____

_____

_____

_____

_____

_____

_____ **End**

2 Trace your pathway from Ms. Magenta's pulmonary capillaries through the blood, beginning in the pulmonary circuit in her lungs, going through her heart, then through her systemic arteries to your final destination in a hepatocyte (liver cell). You likely will have to review Unit 18 (p. 469) for some help with this.

Start: _____

_____

_____

_____

_____

_____

_____ **End**

Part 2

While in her hepatocyte, you notice that a molecule of carbon dioxide has just been produced.

1 Trace the carbon dioxide's pathway from Ms. Magenta's hepatocyte through the systemic veins to her heart, then through her heart to the pulmonary circuit, and finally through the pulmonary circuit to her pulmonary capillaries. You will likely need to review Unit 18 (p. 469) for some help with this.

Start: _____

_____

_____

_____

_____

_____

_____

_____ **End**

2 Trace the pathway of the carbon dioxide molecule from the pulmonary capillaries through the respiratory tract to the point at which it exits from Ms. Magenta's body through her nares.

Start: _____

22

_____

_____

_____

_____

_____

_____

_____ **End**

Exercise 22-2

Histology of the Respiratory Tract

MATERIALS

- ❑ Trachea slide
- ❑ Lung tissue slide
- ❑ Bronchiole slide
- ❑ Light microscope
- ❑ Colored pencils

As you learned in Exercise 22-1 (p. 585), the respiratory tract is a series of branching passages that conduct air to and from the respiratory zone for gas exchange. The passages of the respiratory tract are similar in structure histologically to other hollow organs of the body and consist of three tissue layers. Figure 22.8A uses the example of the trachea to show these layers: the mucosa, the submucosa, and the adventitia.

1. **Mucosa.** Mucous membranes, or **mucosae,** line all passageways that open to the outside of the body, including the passages of the respiratory tract. Mucosae consist of epithelial tissue overlying the basement membrane. As we have seen elsewhere in the body, there is a clear relationship of structure and function in the respiratory tract, because the epithelial tissue of the mucosae are adapted for each region's function. Some examples of the epithelia found in different regions include the following:

   a. **Pseudostratified ciliated columnar epithelium with goblet cells.** The nasopharynx, larynx (inferior to the vocal cords), trachea, and bronchi are lined with **respiratory epithelium** or pseudostratified ciliated columnar epithelium with mucus-secreting cells called **goblet cells.** Figure 22.8B shows you an example of respiratory epithelium from the nasal cavity, but note that you can see respiratory epithelium in Figure 22.8A in the trachea, as well. The cilia of respiratory epithelium sweep dust and other particulates that become trapped in the mucus out of the respiratory tract. Some of the dust and debris is removed from the body via sneezing or coughing, but most is simply pushed toward the laryngopharynx and esophagus and swallowed. The actions of the cilia prevent this material from reaching the deeper parts of the respiratory tract.

   b. **Stratified squamous epithelium.** The oropharynx, laryngopharynx, and larynx (superior to the vocal cords) are lined with stratified squamous epithelium. This helps to protect these areas from mechanical abrasion from food.

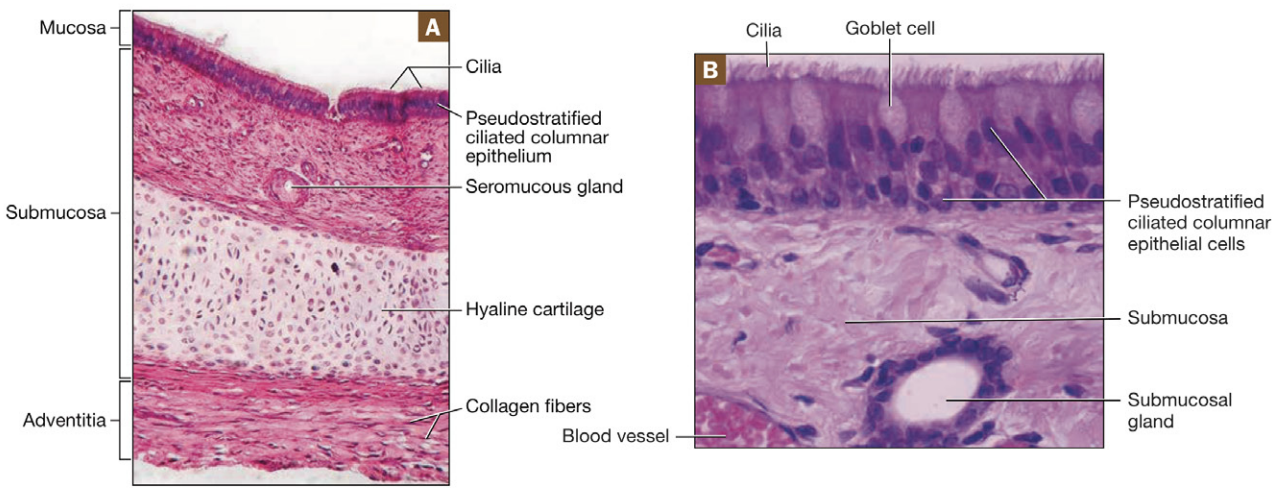

FIGURE **22.8** Histology of the respiratory tract: (**A**) photomicrograph of the trachea; (**B**) photomicrograph of the nasal mucosa with goblet cells.

c. **Simple cuboidal epithelium.** The bronchioles are lined with simple cuboidal epithelium, which is shown in Figure 22.9. These small passageways need fewer goblet cells and cilia because most dust and debris have already been removed by the time air reaches them.

d. **Simple squamous epithelium.** Alveoli are lined with simple squamous epithelium. Note in Figure 22.10 that the alveoli consist of a mucosa only, having no other tissue layers, which minimizes the distances gases must diffuse across the alveoli and into the pulmonary capillaries. As you read earlier, the structure through which gases must diffuse, called the **respiratory membrane**, consists of the squamous alveolar epithelial cells, the endothelial cells of the pulmonary capillaries, and their fused basal laminae.

2. **Submucosa.** Deep to the mucosa we find the **submucosa,** a layer of loose connective tissue. The submucosa contains specialized **seromucous glands** (seer-oh-MYOO-kuss) that secrete watery mucus. The submucosa of larger passages contains hyaline cartilage for support; it also contains smooth muscle that controls the diameter of the airways.

3. **Adventitia.** The outermost layer of the respiratory tract, the **adventitia** (ad-ven-TISH-uh), consists of dense irregular collagenous connective tissue with elastic fibers for support.

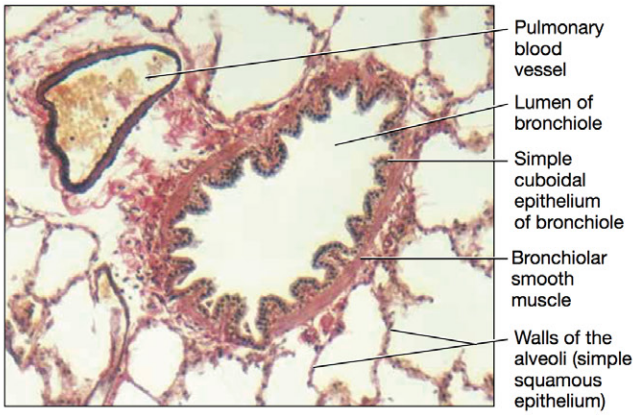

FIGURE **22.9** Photomicrograph of a bronchiole.

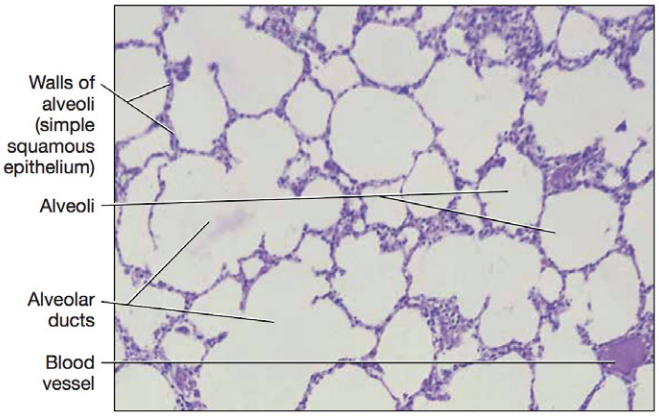

FIGURE **22.10** Photomicrograph of alveoli and lung tissue.

As you examine different regions of the respiratory tract, you will note a few trends:

- The epithelial tissue changes from taller (pseudostratified) in the upper passages to shorter (cuboidal) in the lower passages and, finally, to flat (squamous) in the alveoli.
- The amount of hyaline cartilage gradually decreases as the passages of the bronchial tree become smaller (it is absent in bronchioles), as does the number of goblet cells.
- The amount of smooth muscle tissue and elastic fibers increases as we move deeper into the respiratory tract.

22

These trends can help you to determine the portion of the respiratory tract from which the section on your slide was taken. In the following exercise you will be able to see these trends as you examine photomicrographs of the trachea, a bronchiole, and the alveoli.

Procedure 1 Microscopy

View prepared slides of a section of the trachea, a bronchiole, and alveoli. Note that the bronchiole may be on the same slide as the alveoli. Begin your examination of the slides on low power, and advance to medium and high power to observe details. Use colored pencils to draw what you see under the microscope, and label your drawing with the terms listed. When you have completed the activity, answer Check Your Understanding questions 5 and 6 (p. 604).

1 Trachea

Label the following on your drawing:

- ❑ Pseudostratified columnar epithelium
- ❑ Cilia
- ❑ Goblet cells
- ❑ Submucosa
- ❑ Seromucous glands
- ❑ Hyaline cartilage



2 Bronchioles

Label the following on your drawing:

- ❑ Simple columnar or cuboidal epithelium
- ❑ Smooth muscle
- ❑ Pulmonary arteriole



3 Alveoli

Label the following on your drawing:

- ❑ Simple squamous epithelium
- ❑ Alveolar duct
- ❑ Alveolus



Exercise 22-3

Lung Inflation

MATERIALS

- ❑ Preserved small mammal
- ❑ Dissection equipment
- ❑ Dissection trays
- ❑ Straw
- ❑ Air hose
- ❑ Fresh lungs
- ❑ Air pump

In movies or television programs you may have seen a hero rescuing a choking victim by poking a hole in the victim's neck (usually with a pocketknife) and inserting a straw (or pen) into the hole to restore the airway and save the victim's life. This is actually a somewhat crude version of a legitimate procedure called a **cricothyroidotomy** (kry-koh-thy-royd-AW-toh-mee)—but don't try this at home!

A cricothyroidotomy is performed when the upper respiratory tract is blocked and air is prevented from moving into the lungs. The first step in the procedure is to place an incision (hopefully with a scalpel, not a pocketknife) in the cricothyroid ligament, the soft spot between the thyroid and cricoid cartilages. A tube called an *endotracheal tube* is then inserted into the opening, and the patient is ventilated artificially. This restores the patient's airway by bypassing the upper respiratory tract.

In the following procedure you will be able to see the effects of a cricothyroidotomy firsthand by performing the procedure on a fetal pig (or other preserved small mammal) and inflating its lungs. You will also inflate fresh lungs from a sheep, a pig, or a cow. As you perform both procedures, note the difference in the textures and appearances of the preserved lungs and fresh lungs. After you have completed both procedures, answer Check Your Understanding question 7 (p. 604).

Procedure 1 Cricothyroidotomy and Inflating Preserved Lungs

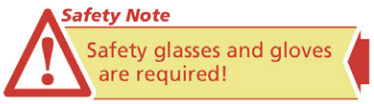

1. Obtain a fetal pig or other preserved small mammal and dissection equipment.
2. Carefully dissect the animal's neck and remove tissue so the larynx is clearly visible.
3. Locate the cricothyroid ligament and make a small incision with a scalpel into its anterior surface.
4. Insert a small straw into the hole you have just made.
5. Attach the straw to a small hose and attach the hose to an air outlet or air pump.
6. Turn on the air slowly and watch the lungs inflate. Crimp the hose to cut off the airflow, and watch the lungs deflate.

Procedure 2 Inflating Fresh Lungs

Safety Note
Safety glasses and gloves are required!

1. Obtain a fresh specimen and a large air hose.
2. Examine the specimen for structures covered in Exercise 22-1 (p. 585), in particular the epiglottis and vocal folds, the other laryngeal cartilages, the trachea and its hyaline cartilage rings, and the pleural membranes.
3. Squeeze the deflated lungs between your fingertips and note their texture. Deflated lungs are shown in Figure 22.11A. Compare their texture with that of the lungs of the preserved mammal:

4. Insert the air hose into the larynx and feed it down into the trachea. Take care not to get the hose stuck in one of the primary bronchi.
5. Attach the hose to the air outlet or air pump and turn it on slowly. You may have to squeeze the trachea and the hose to prevent air leakage.
6. Observe the lungs as they inflate, shown in Figure 22.11B. You may inflate the lungs quite fully. Don't worry—they're very unlikely to pop.
7. Squeeze the inflated lungs between your fingers and note their texture:

8. Crimp the air hose and watch the lungs deflate. Again feel the lungs, and note changes in texture:

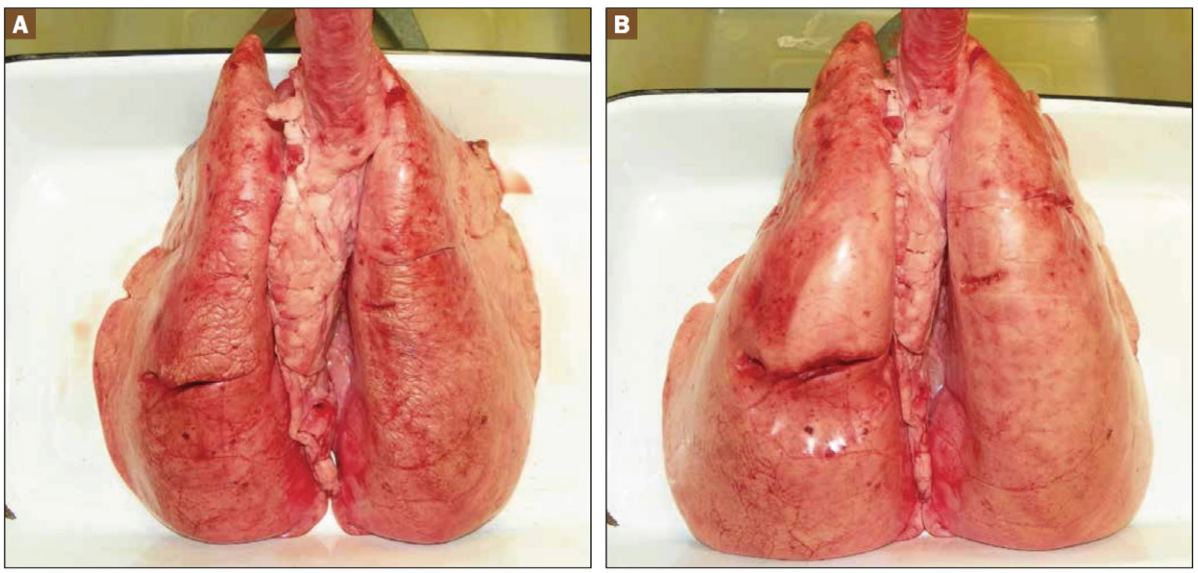

FIGURE **22.11** Fresh lungs: (**A**) deflated; (**B**) inflated.

Name _____

Section _____ Date _____

UNIT 22 REVIEW

Check Your Recall

1 Label Figure 22.12A and 22.12B with the terms below.

- ❑ Cricoid cartilage
- ❑ Epiglottis
- ❑ Horizontal fissure
- ❑ Hyoid bone
- ❑ Left primary bronchus
- ❑ Oblique fissure
- ❑ Pleural cavity
- ❑ Right primary bronchus
- ❑ Secondary bronchi
- ❑ Thyroid cartilage

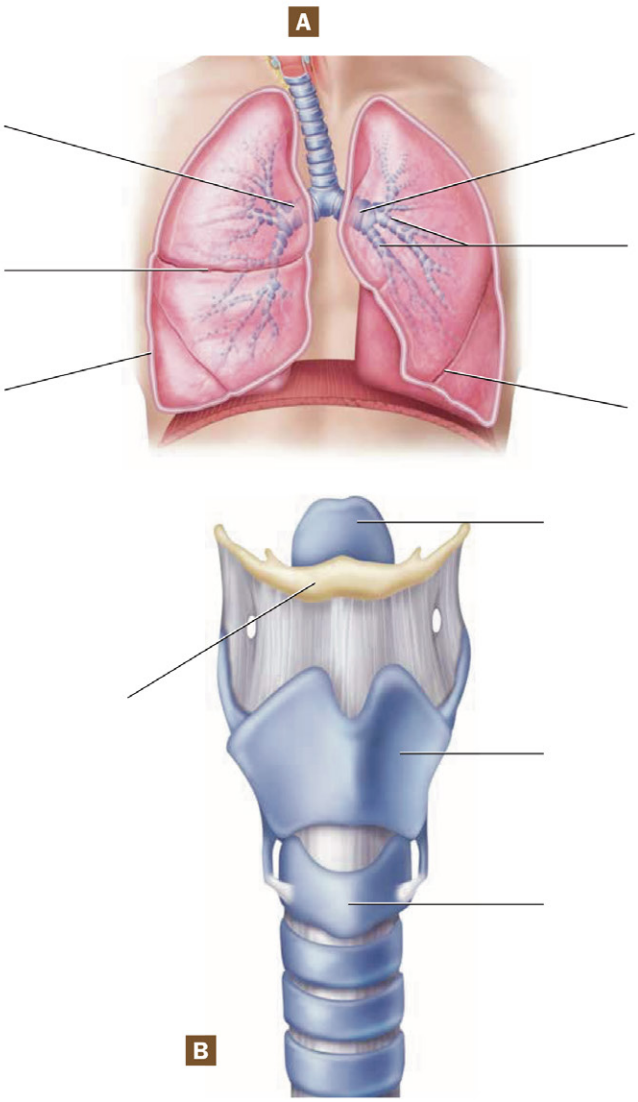

FIGURE **22.12** Respiratory structures: (**A**) anatomy of the lungs and respiratory tract; (**B**) the larynx, anterior view.

2 Label Figure 22.13 with the terms below.

- ❑ Alveolar duct
- ❑ Alveolar sac
- ❑ Alveoli
- ❑ Pulmonary arteriole
- ❑ Pulmonary capillaries
- ❑ Pulmonary venule
- ❑ Respiratory bronchiole
- ❑ Terminal bronchiole

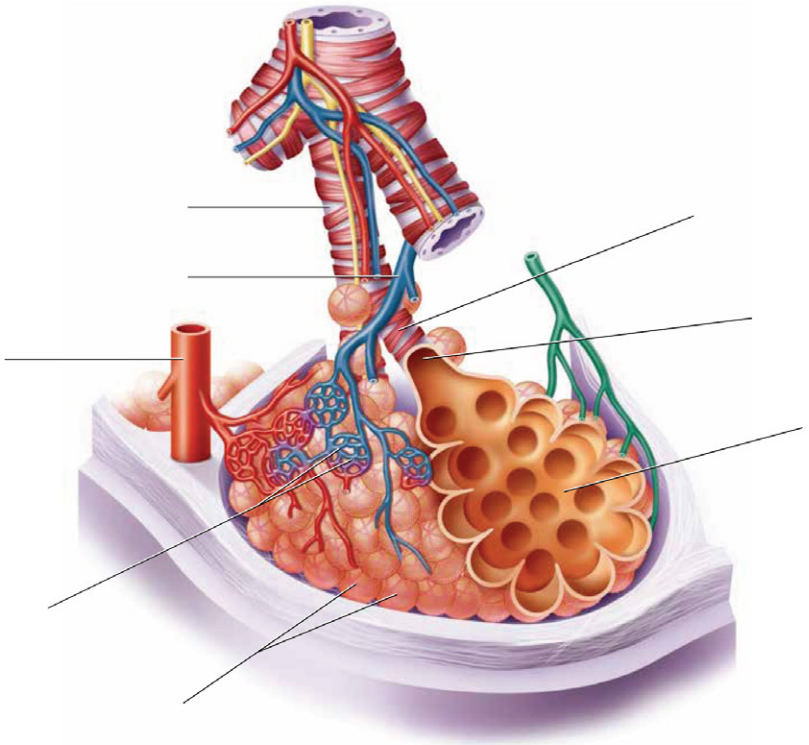

FIGURE **22.13** Bronchiole and alveolar sac.

3 Label Figure 22.14 with the terms below.

- ❑ Laryngopharynx
- ❑ Larynx
- ❑ Nasal cavity
- ❑ Nasal conchae
- ❑ Nasopharynx
- ❑ Oropharynx

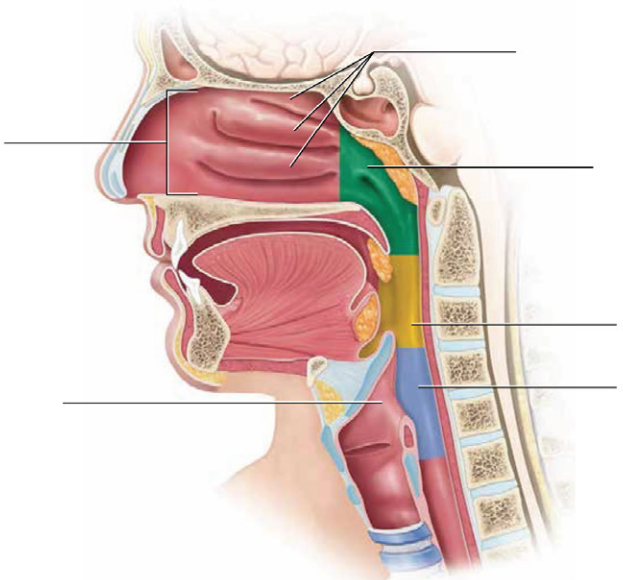

FIGURE **22.14** Midsagittal section of the head and neck.

Name _____

Section _____ Date _____

4 Where is the pleural cavity located? What is its function?

5 Number the following structures of the respiratory tract in the proper order. The structure that comes into contact with oxygenated air first should be number 1, and the structures where gas exchange takes place should be number 12.

_____ Oropharynx

_____ Trachea

_____ Nasal cavity

_____ Bronchiole

_____ Alveolar duct

_____ Larynx

_____ Nasopharynx

_____ Bronchi

_____ Alveolar sac

_____ Terminal bronchiole

_____ Laryngopharynx

_____ Respiratory bronchiole

6 The structure that seals off the nasopharynx during swallowing is called the

a. uvula.
b. false vocal cord.
c. true vocal cord.
d. epiglottis.

7 The first passages of the respiratory zone, which have alveoli in their walls, are called

a. terminal bronchioles.
b. respiratory bronchioles.
c. alveolar ducts.
d. alveolar sacs.

8 Respiratory epithelium is best defined as

a. simple squamous epithelium with goblet cells.
b. stratified squamous epithelium without goblet cells.
c. ciliated simple columnar epithelium without goblet cells.
d. pseudostratified ciliated columnar epithelium with goblet cells.

9 What takes place across the respiratory membrane? Be specific.

10 Which of the following is not a trend we find within the respiratory tract?

a. The epithelium gets progressively shorter in the lower passages.
b. The amount of hyaline cartilage gradually increases as we move to smaller passages.
c. The amount of smooth muscle increases in the smaller passages.
d. The amount of elastic fibers increases in the smaller passages.

Name _____

Section _____ Date _____

REVIEW

Check Your Understanding

Critical Thinking and Application Questions

1 Certain viral or bacterial infections can cause inflammation of the epiglottis, a condition known as *epiglottitis*, which is considered a medical or surgical emergency. Why do you think epiglottitis is so dangerous?

2 The condition pulmonary edema, in which fluid collects around alveoli, increases the thickness of the respiratory membrane. Predict the effect this would have on the efficiency of gas exchange. Explain your reasoning.

3 When a patient has a procedure called a *tracheostomy*, a hole is cut into the trachea and a tube is inserted through which the patient breathes. This allows the air to bypass the upper respiratory tract and enter the trachea directly. Could this have potential negative consequences for the patient? Explain. (***Hint:*** Consider the function of the nasal cavity and other upper airways.)

4 A *pulmonary embolus* is a piece of a blood clot, adipose tissue, or other substance that lodges somewhere in the pulmonary circuit.

a Henry has a pulmonary embolus lodged in one of his pulmonary arterioles. Trace the pathway of blood flow from his inferior vena cava to the pulmonary arteriole where the embolus is lodged.

b How will the embolus affect gas exchange in Henry's pulmonary capillaries? Be specific.

5 Explain how the epithelium in each of the following regions of the respiratory tract is adapted so its structure follows its function.

a Nasal cavity:

b Bronchiole:

c Alveolus:

6 Cilia lining the nasal cavity and nasopharynx beat in unison to propel mucus and debris inferiorly. Cilia lining the respiratory tract inferior to the true vocal cords beat in unison to propel mucus and debris superiorly. Explain the reason for this functional difference.

7 You have just performed an emergency cricothyroidotomy and inserted an endotracheal tube. Your partner has begun ventilating the patient, when you notice that only the right side of the patient's chest is rising and falling with each breath. When you auscultate the patient's chest, you hear breath sounds in the right lung, but not the left lung. What has likely happened during the procedure? How can the mistake be fixed?

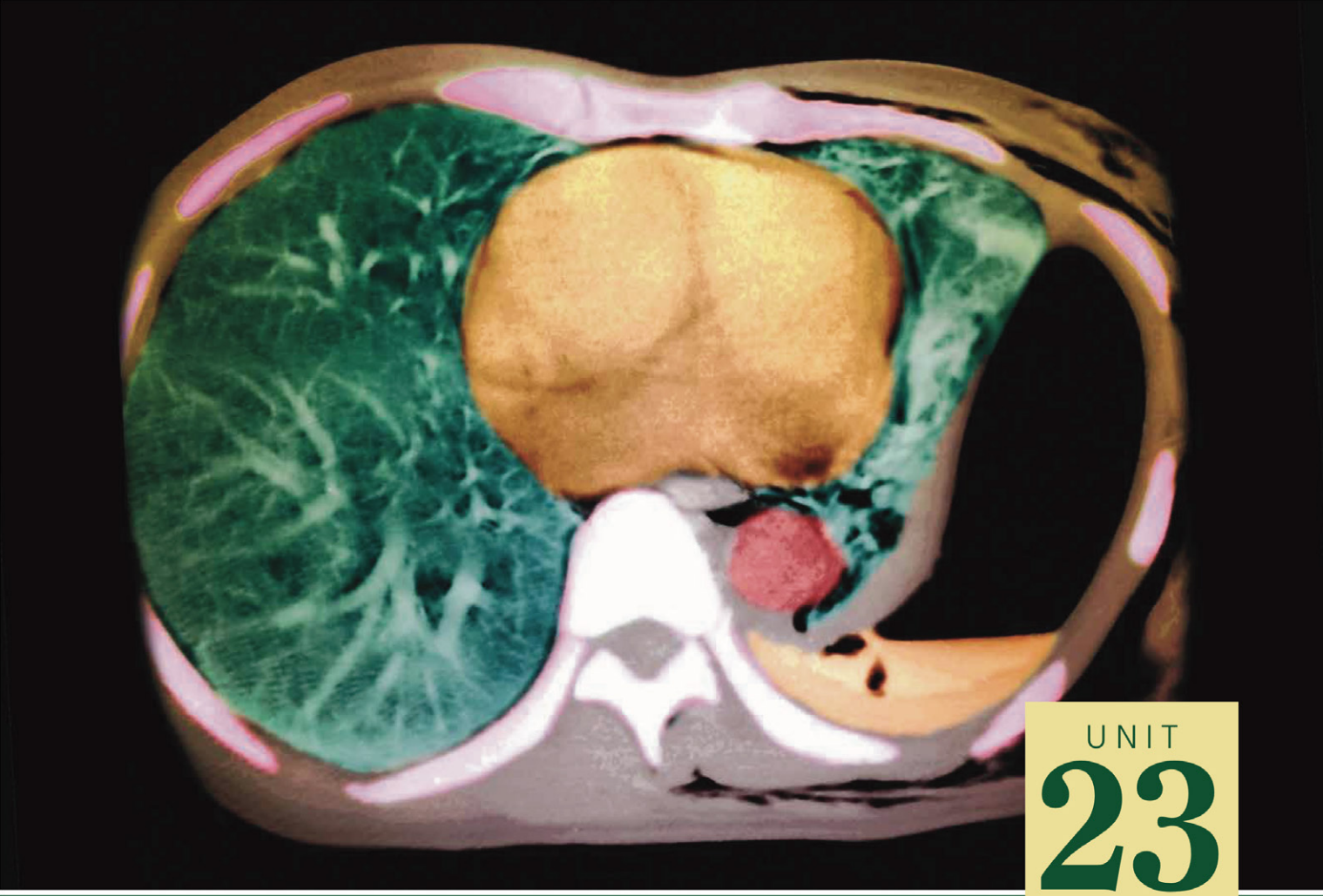

UNIT
23

Respiratory System Physiology

Once you have completed this unit, you should be able to:

1 Describe the pressure-volume relationships in the lungs.

2 Describe and measure respiratory volumes and capacities.

3 Explain the effects of carbon dioxide concentration on blood pH.

Name _____ Section _____ Date _____

PRE-LAB EXERCISES

Complete the following exercises prior to coming to lab, using this lab manual and your textbook for reference.

Pre-Lab Exercise 23-1



Key Terms

You should be familiar with the following terms before coming to lab. Please note that the respiratory volumes and capacities are covered in Pre-Lab Exercises 23-2 and 23-3.

Term	Definition

Basic Respiratory Processes

Pulmonary ventilation _____

Pulmonary gas exchange _____

Gas transport _____

Tissue gas exchange _____

Pulmonary Ventilation Terms

Inspiration _____

Expiration _____

Boyle's law _____

Intrapulmonary pressure _____

Atmospheric pressure _____

Spirometer _____

Respiratory volume _____

Respiratory capacity _____

Name _____ Section _____ Date _____

Gas Transport and External Respiration Terms

Carbonic acid-bicarbonate buffer system _____

Carbonic anhydrase _____

Hyperventilation _____

Hypoventilation _____

Pre-Lab Exercise 23-2



Defining Pulmonary Volumes and Capacities

Define and give the normal value for males and females for each of the following respiratory volumes and capacities listed in Table 23.1.

TABLE **23.1** Respiratory Volumes and Capacities

Volume/Capacity	Definition	Normal Value
Tidal volume		Male: _____ mL Female: _____ mL
Inspiratory reserve volume		Male: _____ mL Female: _____ mL
Expiratory reserve volume		Male: _____ mL Female: _____ mL
Residual volume		Male: _____ mL Female: _____ mL
Inspiratory capacity		Male: _____ mL Female: _____ mL
Functional residual capacity		Male: _____ mL Female: _____ mL
Vital capacity		Male: _____ mL Female: _____ mL
Total lung capacity		Male: _____ mL Female: _____ mL

Pre-Lab Exercise 23-3

Labeling Pulmonary Volumes and Capacities

Label and color the respiratory volumes and capacities depicted in Figure 23.1 using the terms from Exercise 23-2 (p. 611). Use your text and Exercise 23-2 in this unit for reference.

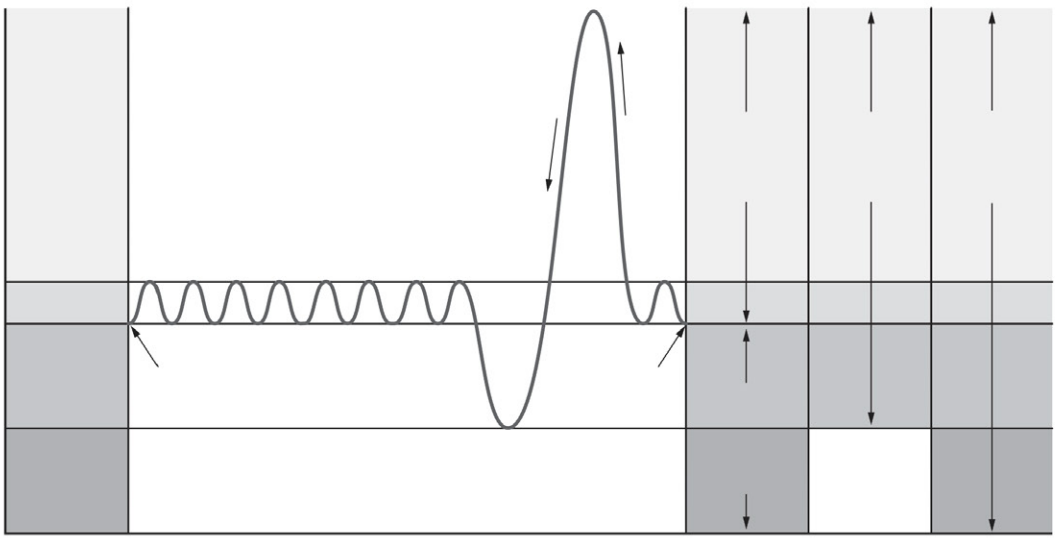

FIGURE **23.1** Respiratory volumes and capacities.

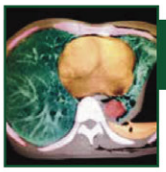

CT scan through the chest showing a collapsed lung.

EXERCISES

In the previous unit we covered respiratory system anatomy, and now we turn our attention to respiratory system physiology. **Respiration** consists of four basic physiological processes:

1. **Pulmonary ventilation** is the physical movement of air into and out of the lungs.
2. **Pulmonary gas exchange** is the movement of gases across the respiratory membrane in the pulmonary capillaries or into the alveoli.
3. **Gas transport** is the movement of gases through the blood.
4. **Tissue gas exchange** is the exchange of gases between the blood in the systemic capillaries and the tissues.

In this unit we examine the first three processes by studying a model of the lungs, measuring respiratory volumes, and measuring the effect of exercise on carbon dioxide exchange.

Exercise 23-1

Pressure-Volume Relationships in the Lungs

MATERIALS

- ❑ Bell-jar model of the lungs

Pulmonary ventilation, the physical movement of air into and out of the lungs, consists of two phases: (1) **inspiration**, during which air is brought into the lungs, and (2) **expiration**, during which air is expelled from the lungs. The movement of air during inspiration and expiration is driven by changes in the lungs' volume and pressure (Fig. 23.2). The relationship of gas pressure and volume is expressed in what is known as **Boyle's law**, expressed mathematically as:

$$P_1V_1 = P_2V_2 \text{ or } P = 1/V$$

Stated simply, this means that pressure (P) and volume (V) are inversely proportional: As the volume of a container increases, the pressure inside the container decreases, and as the volume of a container decreases, the pressure inside the container increases.

The changes in volume during the phases of ventilation are driven by the **inspiratory muscles**. The main inspiratory muscle is the **diaphragm muscle**, and it is assisted by the **external intercostal muscles** (see Figure 10.6, p. 263, for a

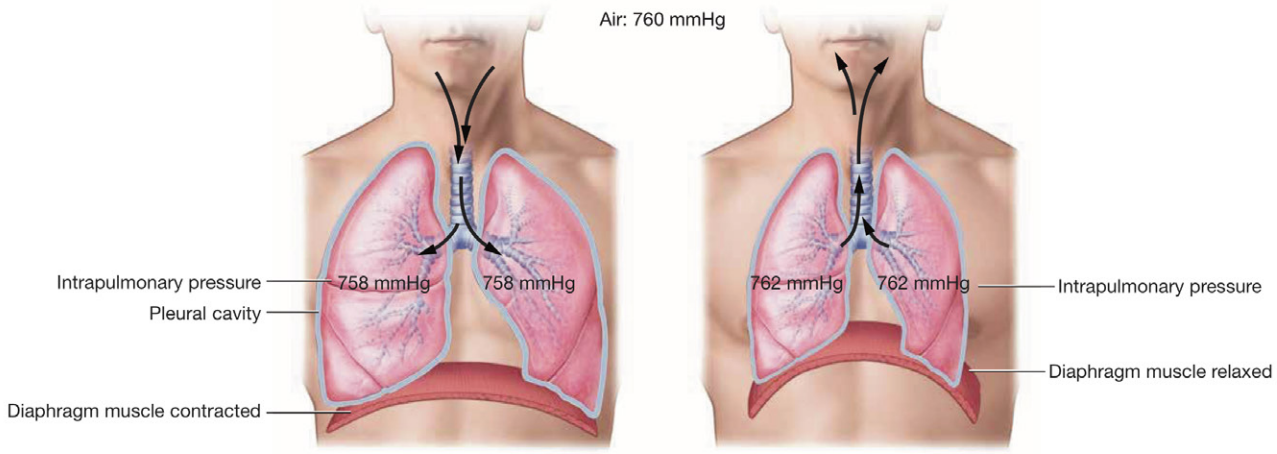

FIGURE **23.2** Pressure-volume relationships in the lungs during inspiration and expiration.

review). During forced inspiration, several other muscles, termed *accessory muscles of inspiration*, assist the diaphragm and external intercostal muscles. When the inspiratory muscles contract, they increase both the height and the diameter of the thoracic cavity, which increases its volume. Recall that the lungs are attached to the thoracic cavity directly by the pleural membranes. For this reason, the lungs' height and diameter increases as well, as does their volume. As the lungs' volume increases, the pressure within the alveoli, called the **intrapulmonary pressure**, decreases. When intrapulmonary pressure is lower than the **atmospheric pressure**, inspiration occurs, and air rushes into the lungs.

Expiration is achieved primarily by the elastic recoil of the lungs. As the inspiratory muscles relax, the lungs' elastic tissue causes them to recoil to their original, smaller size. This decreases the volume of the lungs and increases the intrapulmonary pressure. When the intrapulmonary pressure is higher than the atmospheric pressure, air exits the lungs, and expiration occurs. In the event of forced expiration, several accessory muscles of expiration, including the **internal intercostal muscles**, will further decrease the height and diameter of the thoracic cavity.

Procedure 1 Model Ventilation with the Bell-Jar Model

In this procedure we will use a bell-jar model of the lungs, shown in Figure 23.3, to view the effects of pressure and volume on ventilation. The bell-jar model has two balloons, each representing one lung, and a flexible membrane on the bottom that represents the diaphragm muscle. When you have completed the activity, answer Check Your Understanding questions 1 and 2 (p. 619).

FIGURE **23.3** Bell-jar model of the lungs, simulated inspiration.

1 Apply upward pressure to the membrane. This represents how the diaphragm muscle looks when it is relaxed. What has happened to the pressure of the system (has it increased or decreased)? What happened to the volume of the lungs?

2 Now slowly release the membrane. This represents the diaphragm muscle flattening out as it contracts. What is happening to the pressure as you release the membrane? What happened to the volume of the lungs?

3 If your bell-jar model has a rubber stopper in the top, you can use it to demonstrate the effects of a **pneumothorax** (noo-moh-THOR-ax) on lung tissue. A pneumothorax generally is caused by a tear in the pleural membranes that allows air to enter the pleural cavity. With the membrane flat and the lungs (balloons) inflated, loosen the rubber stopper. What happens to the lungs? Why?

Exercise 23-2

Measuring Pulmonary Volumes and Capacities

MATERIALS

- ❑ Wet or handheld spirometer
- ❑ Disposable mouthpiece

Respiratory volumes are the volumes of air that are exchanged with each breath. These volumes of air are measured with an instrument called a **spirometer** (spih-RAH-meh-ter) and include the following (Fig. 23.4):

1. **Tidal volume (TV).** The **tidal volume,** or **TV,** is the amount of air exchanged with each breath during normal, quiet breathing. It measures about 500 mL in a healthy adult.
2. **Expiratory reserve volume (ERV).** The **expiratory reserve volume,** or the **ERV,** is the volume of air that may be expired after a tidal expiration. It averages between 700 and 1,200 mL of air.
3. **Inspiratory reserve volume (IRV).** The **inspiratory reserve volume,** or the **IRV,** is the amount of air that may be inspired after a tidal inspiration. It averages between 1,900 and 3,100 mL of air.

Note that there is also a fourth volume, called the **residual volume (RV),** which cannot be measured with a spirometer. It is defined as the amount of air that remains in the lungs after maximal expiration, and is generally equal to about 1,100 to 1,200 mL of air. This amount of air accounts for the difference between the IRV and the ERV.

Two or more respiratory volumes may be combined to give **respiratory capacities.** As you can see in Figure 23.4, there are four respiratory capacities:

1. **Inspiratory capacity (IC).** The **inspiratory capacity,** or **IC,** is equal to the TV plus the IRV and is the amount of air that a person can maximally inspire after a tidal expiration. It averages between 2,400 and 3,600 mL of air.
2. **Functional residual capacity (FRC).** The **functional residual capacity,** or the **FRC,** is the amount of air that is normally left in the lungs after a tidal expiration. It is the sum of the ERV and the RV and averages between 1,800 and 2,400 mL of air. It is not measurable with general spirometry.
3. **Vital capacity (VC).** The **vital capacity,** or **VC,** represents the total amount of exchangeable air that moves in and out of the lungs. It is equal to the sum of the TV, IRV, and the ERV and averages between 3,100 and 4,800 mL of air.
4. **Total lung capacity (TLC).** The **total lung capacity,** or **TLC,** represents the total amount of exchangeable and nonexchangeable air in the lungs. It is the total of all four respiratory volumes and is not measureable with general spirometry. It averages between 4,200 and 6,000 mL of air.

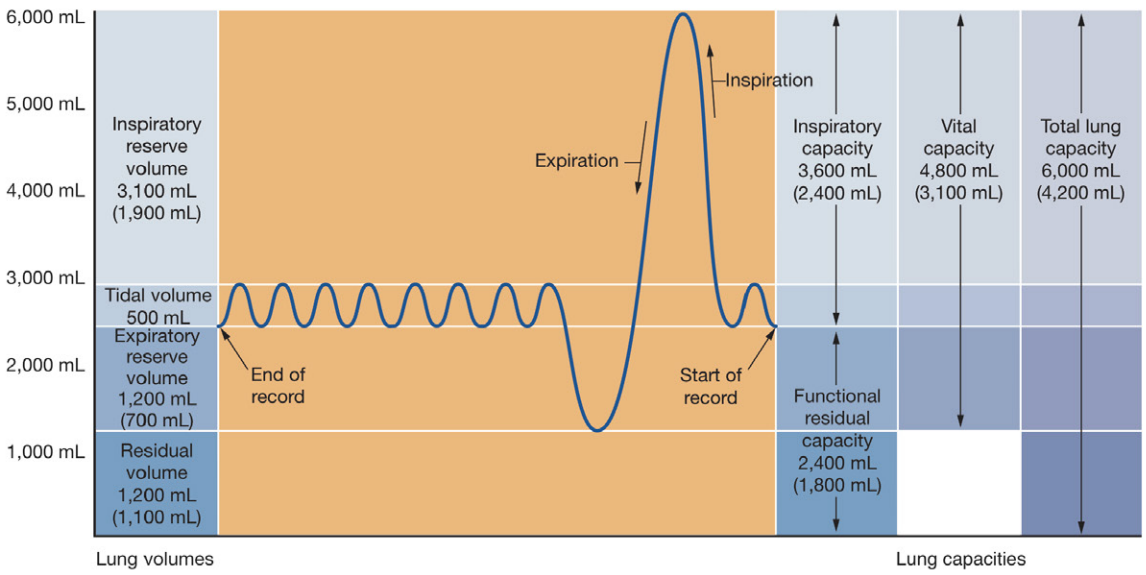

FIGURE **23.4** Respiratory volumes and capacities (note that the top value in the figure is the average value for males, and the value in parentheses is the average value for females).

Spirometry is a useful tool with which to assess pulmonary function. The respiratory volumes and capacities are especially helpful in differentiating the two primary types of respiratory disorders—restrictive diseases and obstructive diseases. **Restrictive diseases,** such as pneumoconiosis (coal-miner's lung) and tuberculosis, are characterized by a loss of lung or chest distensibility, meaning that the lungs or chest are unable to stretch and increase in size. As a result, restrictive diseases cause difficulty with *inspiration*. This decreases the IRV, IC, VC, and TLC.

Obstructive diseases, such as chronic obstructive pulmonary disease (COPD) and asthma, are characterized by increased airway resistance caused by narrowing of the bronchioles, increased mucus secretion, and/or an obstructing body such as a tumor. It may seem counterintuitive, but obstructive diseases make *expiration* difficult. This is because the increased intrapulmonary pressure during expiration naturally tends to shrink the diameter of the bronchioles. When the bronchioles are already narrowed, as in an obstructive disease, the increased intrapulmonary pressure can actually collapse the bronchioles and trap oxygen-poor air in the distal respiratory passages. Therefore, patients with obstructive diseases often exhale slowly and through pursed lips to minimize the pressure changes and maximize the amount of air exhaled. Obstructive diseases decrease the ERV and VC and increase the RV and FRC.

Procedure 1 Measure Respiratory Volumes with a Wet or Handheld Spirometer

Three types of spirometers are commonly found in anatomy and physiology labs: (1) a bell, or "wet" spirometer; (2) a computerized spirometer; and (3) a handheld spirometer (shown in Figure 23.5). Many types of wet and handheld spirometers allow you to assess only expiratory volumes, whereas computerized spirometers typically allow you to assess both inspiratory and expiratory volumes. All types of devices allow measurement of one or more respiratory capacities.

The following procedure is intended for a wet or handheld spirometer. If your lab has a computerized spirometer, however, you can either follow the procedure below or follow the prompts by the computer program. When you have completed the activity, answer Check Your Understanding questions 3 and 4 (pp. 619–620).

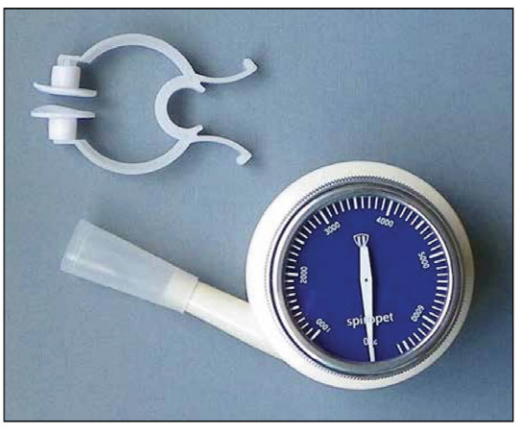

FIGURE **23.5** Handheld spirometer.

Safety Note

You should not be the subject of this experiment if you have cardiovascular or pulmonary disease or are prone to dizziness or fainting.

1. Obtain a disposable mouthpiece and attach it to the end of the tube.
2. Before you begin, practice exhaling through the tube several times. Note that you are supposed to only *exhale* into the tube, as the tube likely has no filter.
3. *Measure the tidal volume*: Sit in a chair with your back straight and your eyes closed. Inhale a normal tidal inspiration, and exhale this breath through the tube. Getting a true representation of the tidal volume is often difficult, because people have a tendency to force the expiration. To get the most accurate tidal volume, take several measurements and average the numbers. Note that some handheld spirometers are not terribly sensitive and so give a value for the tidal volume that is too low. If you find that this is the case, you may need to take extra readings to get an approximately accurate measurement.

   Measurement 1: _____

   Measurement 2: _____

   Measurement 3: _____

   Average Tidal Volume: _____

4 *Measure the expiratory reserve volume*: Before taking this measurement, inhale and exhale a series of tidal volumes. Then inspire a normal tidal inspiration, breathe out a normal tidal expiration, put the mouthpiece to your mouth, and exhale as forcibly as possible. Don't cheat and take in a large breath first! As before, perform several measurements and average the numbers.

Measurement 1: _____

Measurement 2: _____

Measurement 3: _____

Average Expiratory Reserve Volume: _____

5 *Measure the vital capacity*: As before, inhale and exhale a series of tidal volumes. Then bend over and exhale maximally. Once you have exhaled as much air as you can, raise yourself upright and inhale as much air as you possibly can (until you feel like you are nearly about to "pop"). Quickly place the mouthpiece to your mouth and exhale as forcibly and as long as possible. Take several measurements (you may want to give yourself a minute to rest between measurements), and record the data below.

Measurement 1: _____

Measurement 2: _____

Measurement 3: _____

Average Vital Capacity: _____

6 *Calculate the inspiratory reserve volume*: Even though the bell or handheld spirometer cannot measure inspiratory volumes, you can calculate this volume now that you have the vital capacity (VC), tidal volume (TV), and expiratory reserve volume (ERV). Recall that VC = TV + IRV + ERV. Rearrange the equation: IRV = VC + (TV + ERV).

Average IRV: _____

7 How do your values compare with the average values? What factors, if any, do you think may have affected your results?

_____

_____

_____

8 Pool the results for your class, and divide the results into four categories: female cigarette smokers, female nonsmokers, male cigarette smokers, and male nonsmokers. Calculate the average TV, ERV, and VC for each group, and record these data in Table 23.2.

TABLE **23.2** Respiratory Volumes and Capacities for Smokers and Nonsmokers

Group	Tidal Volume	Expiratory Reserve Volume	Inspiratory Reserve Volume	Vital Capacity
Female smokers				
Female nonsmokers				
Male smokers				
Male nonsmokers				

9 Interpret your results:

a How did the average values differ for males and females?

b How did the average values differ for smokers and nonsmokers?

c What disease pattern would you expect to see with the smokers? Did your results follow this expectation?

Exercise 23-3

pH and Ventilation

MATERIALS

- ❑ One 200 mL beaker
- ❑ Deionized water
- ❑ pH meter
- ❑ Drinking straw

Pulmonary ventilation is required not only to bring oxygen into the body but also to remove carbon dioxide from the body. Carbon dioxide is a nonpolar gas that does not dissolve fully in the water of plasma, so only about 7 to 10 percent of the carbon dioxide that we produce is transported in this manner. Another 20 percent of the carbon dioxide entering the blood binds to hemoglobin to form a molecule called *carbaminohemoglobin*. The remainder of the carbon dioxide is transported as another compound entirely: the weak base called the **bicarbonate ion** (HCO_3^-).

When carbon dioxide encounters water, it undergoes a reversible reaction to form the weak acid **carbonic acid** (H_2CO_3). Most carbonic acid dissociates to form hydrogen and bicarbonate ions, which form a system known as the **carbonic acid-bicarbonate buffer system**. In the body, this reaction is catalyzed by an enzyme called **carbonic anhydrase** (kar-BAW-nik an-HY-dray′z) and proceeds as follows:

$$H_2O + CO_2 \Longleftrightarrow H_2CO_3 \Longleftrightarrow HCO_3^- + H^+$$

Recall from the chemistry unit that a solution's concentration of hydrogen ions determines whether it is acidic, basic, or neutral, a value that is represented by the solution's **pH**. As you can see from this reaction, the amount of carbon dioxide in the blood is a major determinant of the concentration of hydrogen ions in the blood. As the amount of carbon dioxide in the blood is determined directly by the rate and depth of ventilation, anything that affects ventilation can change the hydrogen ion concentration and so the pH of the blood.

When the rate and depth of ventilation increase during **hyperventilation**, more carbon dioxide is expelled from the body and the amount of carbon dioxide concentration in the blood decreases. This in turn decreases the number of hydrogen ions released, which raises the pH of the blood (remember fewer hydrogen ions = higher pH). Conversely, when the rate and depth of ventilation decrease during **hypoventilation**, carbon dioxide is retained and there is a greater amount in the blood. This increases the number of hydrogen ions released and decreases the blood pH (similarly, more hydrogen ions = lower pH).

When the pH of the blood increases or decreases due to factors unrelated to ventilation, a negative feedback loop involving the brainstem attempts to correct this pH imbalance by adjusting the rate and depth of ventilation. This is something you witness when you engage in moderate to strenuous exercise—as you exercise, you produce more metabolic acids such as carbon dioxide and lactic acid. This triggers an increase in the rate and depth of ventilation to remove more carbon dioxide from the blood and so restore blood pH homeostasis. A similar response occurs to an abnormal rise in pH—the brainstem slows ventilation to retain carbon dioxide and lower pH.

Procedure 1 Measure the Effect of Carbon Dioxide on the pH of a Solution

We can't measure the effects of ventilatory rate on blood pH directly in the lab because it requires an analysis of arterial blood. However, we can observe and measure the effects of carbon dioxide on the pH of water and correlate this with the changes you would see in the blood, which is what you will do in the following experiment. When you have completed the activity, answer Check Your Understanding questions 5 through 7 (p. 620).

1. Measure your partner's respiratory rate while he or she is seated and resting. Measuring the respiratory rate can be tricky because as soon as you tell your partner to breathe normally, he or she automatically becomes conscious of breathing and alters the rate. A trick you may want to try is to place two fingers on your partner's radial artery and take his or her pulse. This will cause your partner to focus more on the pulse rate and breathe more naturally. Record this value in Table 23.3.
2. Fill a 200 mL beaker about half-full of deionized water. Measure the pH of the water with a pH meter. Record this value below:

   pH of deionized water: _____

3 Place a drinking straw into the water, and have your partner exhale through the straw into the water (the water should bubble) for 20 seconds. Repeat the pH measurement of the water with the pH meter, and record the value in Table 23.3.

4 Empty your beaker, and refill it with new water. Have your partner do vigorous exercise for at least 5 minutes (running up and down stairs or doing jumping jacks usually does the job). The longer and more vigorously your partner exercises the better results you will obtain from the procedure. Immediately upon finishing the exercise, have your partner blow through the straw into the beaker of water for 20 seconds. Measure the pH of the water with the pH meter, and record the value in Table 23.3.

5 After you record the pH, measure your partner's respiratory rate (you may want to use the pulse trick again), and record the value in Table 23.3.

6 Empty your beaker again, and refill it with new water. Allow your partner to have a (well-deserved) rest for at least 5 minutes. Again, have your partner blow through the straw into the beaker of water for 20 seconds, and measure the pH of the water with the pH meter. Record the value in Table 23.3.

7 After you record the pH, measure your partner's respiratory rate, and record the value in Table 23.3.

TABLE **23.3** pH of Water and Rate of Ventilation

Setting	Respiratory Rate	pH
At rest		
Immediately after exercise		
After 5 minutes of rest		

8 Interpret your results:

a Start with the basics: What happens to the metabolic rate during exercise? What is generated as a waste product of glucose catabolism?

b What does this waste product do to the pH of the blood? Why?

c What sort of ventilatory response does this change in pH cause (increase or decrease in rate/depth of ventilation)? Why?

d Now apply this to your results:

(1) What happened to the respiratory rate during and after exercise? Why? (***Hint:*** See question 8c.)

(2) What happened to the pH of the water after exercise? Why?

(3) What happened to the respiratory rate and the pH of the water after resting? Why?

Name _____

Section _____ Date _____

Check Your Recall

REVIEW

1 Pulmonary ventilation is best defined as

a. the movement of gases across the respiratory membrane.
b. the exchange of gases between the blood in the systemic capillaries and the tissues.
c. the physical movement of air into and out of the lungs.
d. the movement of gases through the blood.

2 How are pressure and volume related, according to Boyle's law?

_____

_____

3 Air moves out of the lungs when

a. intrapulmonary pressure is less than atmospheric pressure.
b. intrapulmonary pressure is greater than atmospheric pressure.
c. blood pressure is greater than intrapulmonary pressure.
d. blood pressure is less than intrapulmonary pressure.

4 Passive expiration is achieved primarily by the

a. contraction of the diaphragm and external intercostal muscles.
b. decrease in intrapulmonary pressure.
c. increase in atmospheric pressure.
d. elastic recoil of the lungs.

5 *Matching:* Match the following pulmonary volumes and capacities with their correct definition or description.

_____ Total lung capacity
_____ Residual volume
_____ Functional residual capacity
_____ Vital capacity
_____ Inspiratory reserve volume
_____ Tidal volume
_____ Inspiratory capacity
_____ Expiratory reserve volume

A. Volume of air in the lungs after a tidal expiration
B. Volume of air forcibly expired after a tidal expiration
C. Volume of air forcibly inspired after a tidal inspiration
D. Total amount of exchangeable and nonexchangeable air in the lungs
E. Maximum amount of air that can be inhaled with a forced inspiration
F. Volume of air remaining in the lungs after forceful expiration
G. Maximum amount of exchangeable air that can be ventilated with forced inspiration and expiration
H. Volume of air exchanged with normal, quiet breathing

6 *Fill in the blanks:* A restrictive disease generally causes difficulty with _____,

whereas an obstructive disease generally causes difficulty with _____.

7 Calculate the inspiratory capacity, vital capacity, and total lung capacity for a patient with the following respiratory volumes:

- Tidal Volume = 550 mL
- Expiratory Reserve Volume = 1,200 mL
- Inspiratory Reserve Volume = 2,100 mL
- Residual Volume = 1,100 mL

Inspiratory Capacity = _____

Vital Capacity = _____

Total Lung Capacity = _____

8 Carbon dioxide is transported through the blood primarily as

a. dissolved gas.
b. bicarbonate.
c. carbonic anhydrase.
d. carbaminohemoglobin.

9 *True/False:* Mark the following statements as true (T) or false (F). If the statement is false, correct it to make it a true statement.

_____ a. Hyperventilation causes a retention of carbon dioxide and an increase in the hydrogen ion concentration of the blood.

_____ b. When the pH of the blood falls (i.e., the blood becomes more acidic), a negative feedback loop is triggered that increases the rate and depth of ventilation to remove carbon dioxide from the blood.

_____ c. The two main muscles of inspiration are the diaphragm muscle and internal intercostal muscles.

_____ d. The muscles of inspiration increase the pressure inside of the lungs above atmospheric pressure in order to cause inspiration.

10 The enzyme that converts carbon dioxide and water into carbonic acid is called

a. bicarbonate dehydrogenase.
b. adenosine deaminase.
c. carbonic anhydrase.
d. hemoglobin carboxylase.

Name _____

Section _____ Date _____

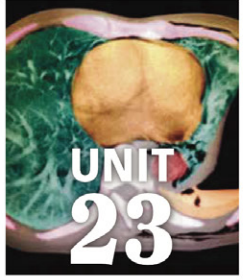

REVIEW

Check Your Understanding

Critical Thinking and Application Questions

1 The condition *pulmonary fibrosis* is caused by the replacement of elastic fibers in the lung with inelastic collagen fibers, which decreases the lungs' distensibility (the ability to stretch outward). Would pulmonary fibrosis make inspiration or expiration difficult? Explain.

2 Certain chest deformities prevent normal expansion of the chest. Explain why this makes ventilation difficult in terms of pressure and volume.

3 A male patient presents with the following respiratory volumes and capacities: TV = 500 mL, ERV = 600 mL, IRV = 2,700 mL. What is this patient's VC? Are these values normal? If not, are they more consistent with an obstructive or restrictive disease pattern? Explain.

4 The condition *influenza* is caused by a virus that infects the epithelium of the respiratory tract. The virus can cause severe inflammation of the airways, death of the epithelial cells, and excess secretion of mucus. Is influenza likely to show an obstructive disease pattern or a restrictive disease pattern? Predict the values you would expect to see on spirometry for a patient with influenza.

5 A patient with influenza will have decreased pulmonary gas exchange occurring in the alveoli. What effect is this likely to have on the pH of a patient's blood? Explain.

6 Leda presents after an episode of food poisoning that caused prolonged vomiting. You notice during the exam that her respiratory rate is fairly low at eight breaths per minute. You run some lab tests and find that the pH of her blood is abnormally alkaline (basic), a condition called *metabolic alkalosis*. Are her respiratory rate and blood pH related? If so, how and why?

7 Why does the ventilatory rate increase during exercise?

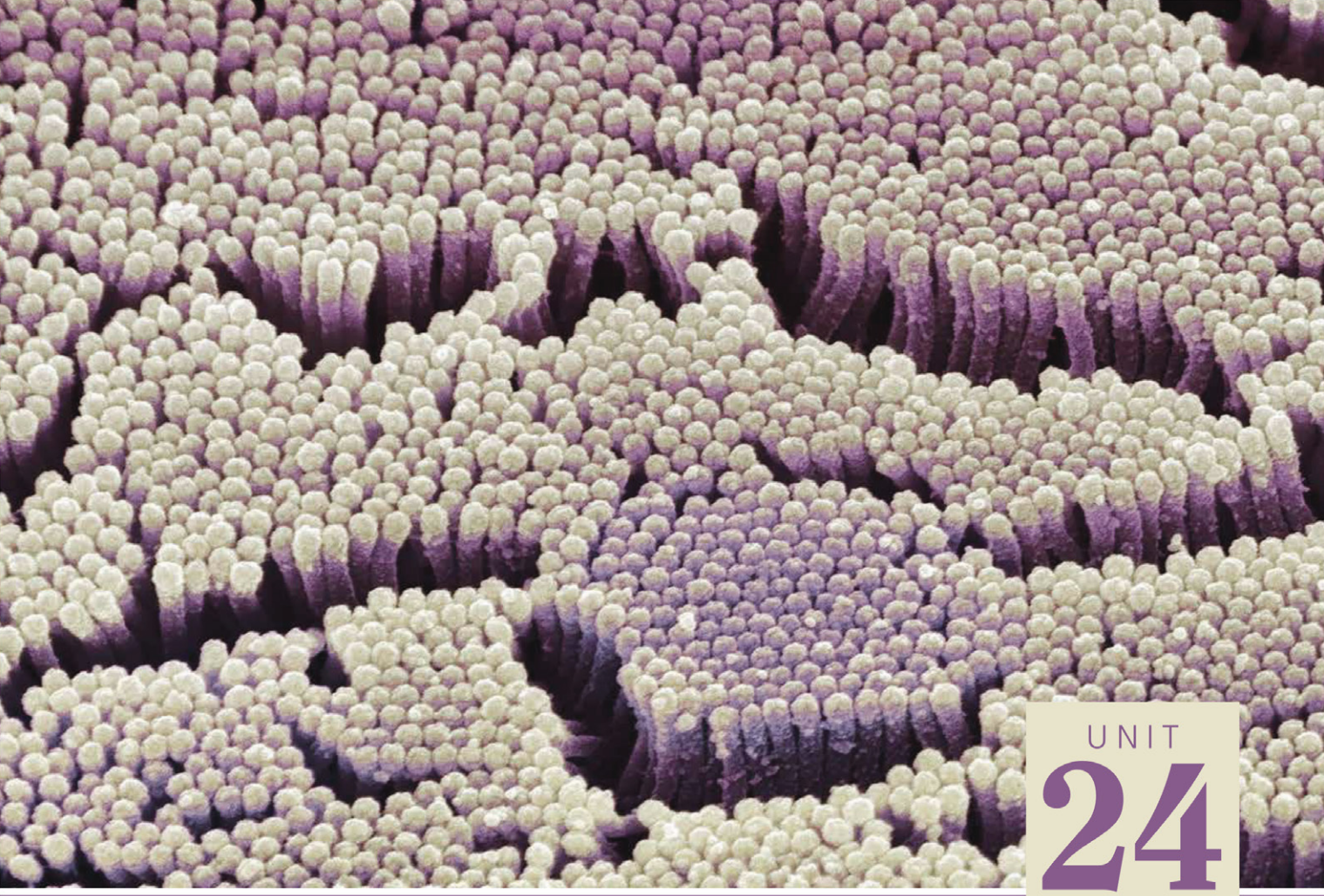

UNIT
24

Digestive System

Once you have completed this unit, you should be able to:

1. Identify structures of the digestive system.
2. Identify the microscopic anatomy of the digestive system.
3. Describe the action of emulsifying agents on lipids.
4. Explain the factors that influence the functions of digestive enzymes.
5. Describe the anatomical pathway taken by carbohydrates, proteins, and lipids as they are digested and absorbed into the blood.
6. Describe the physiological processes that physically and chemically break down carbohydrates, proteins, and lipids as they are digested.

Name _____ Section _____ Date _____

PRE-LAB EXERCISES

Complete the following exercises prior to coming to lab, using this lab manual and your textbook for reference.

Pre-Lab Exercise 24-1



Key Terms

You should be familiar with the following terms before coming to lab. Please note that this list is not all-inclusive, because the terminology for the digestive system is extensive. Digestive enzymes are covered separately in Pre-Lab Exercise 24-3 (p. 628).

Term	Definition
Digestive System Structures	
Alimentary canal (gastrointestinal tract)	
Accessory organ	
Peritoneal cavity	
Gastroesophageal sphincter	
Pyloric sphincter	
Duodenum	
Jejunum	
Ileum	
Colon	
Salivary glands	
Pancreas	

Name _____ Section _____ Date _____

Liver _____

Gallbladder _____

Digestive Histology

Mucosa _____

Submucosa _____

Muscularis externa _____

Serosa _____

Acinar cells _____

Pancreatic islet _____

Liver lobule _____

Digestive Physiology

Digestive enzyme _____

Chemical digestion _____

Emulsification _____

Bile _____

Pre-Lab Exercise 24-2

Anatomy of the Digestive System

Label and color the structures of the digestive system in Figures 24.1 through 24.4 with the terms from Exercise 24-1 (p. 629). Use your text and Exercise 24-1 in this unit for reference.

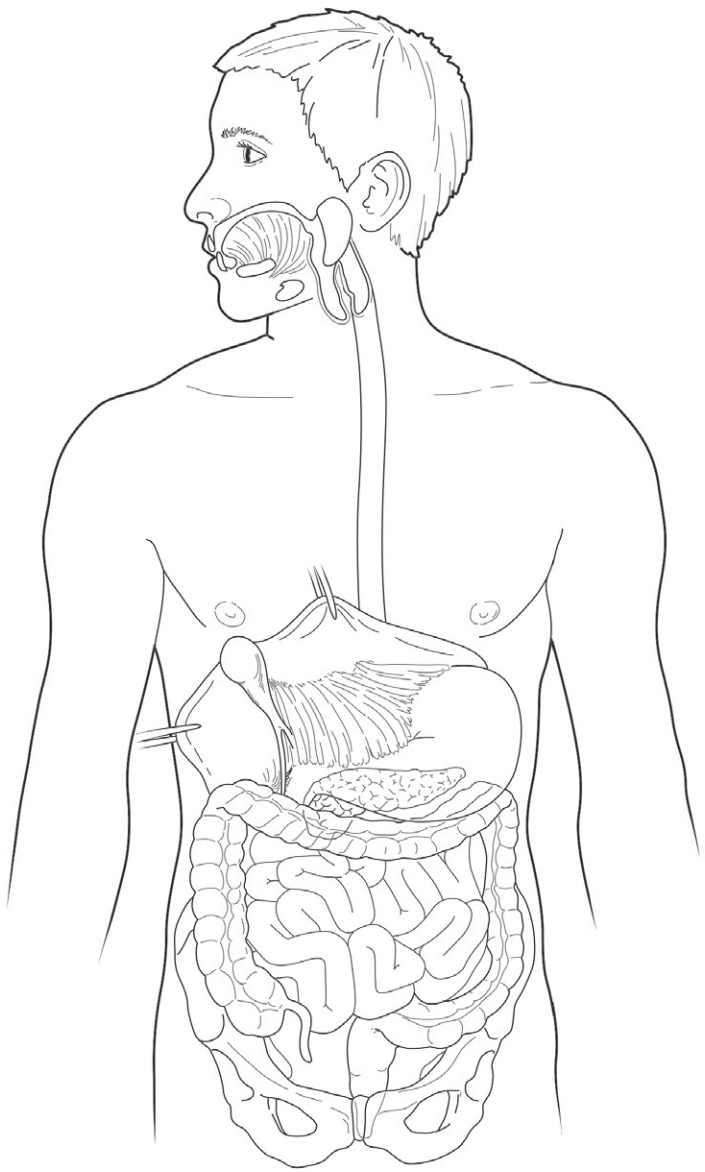

FIGURE **24.1** Anatomy of the digestive system.

Name _____ Section _____ Date _____

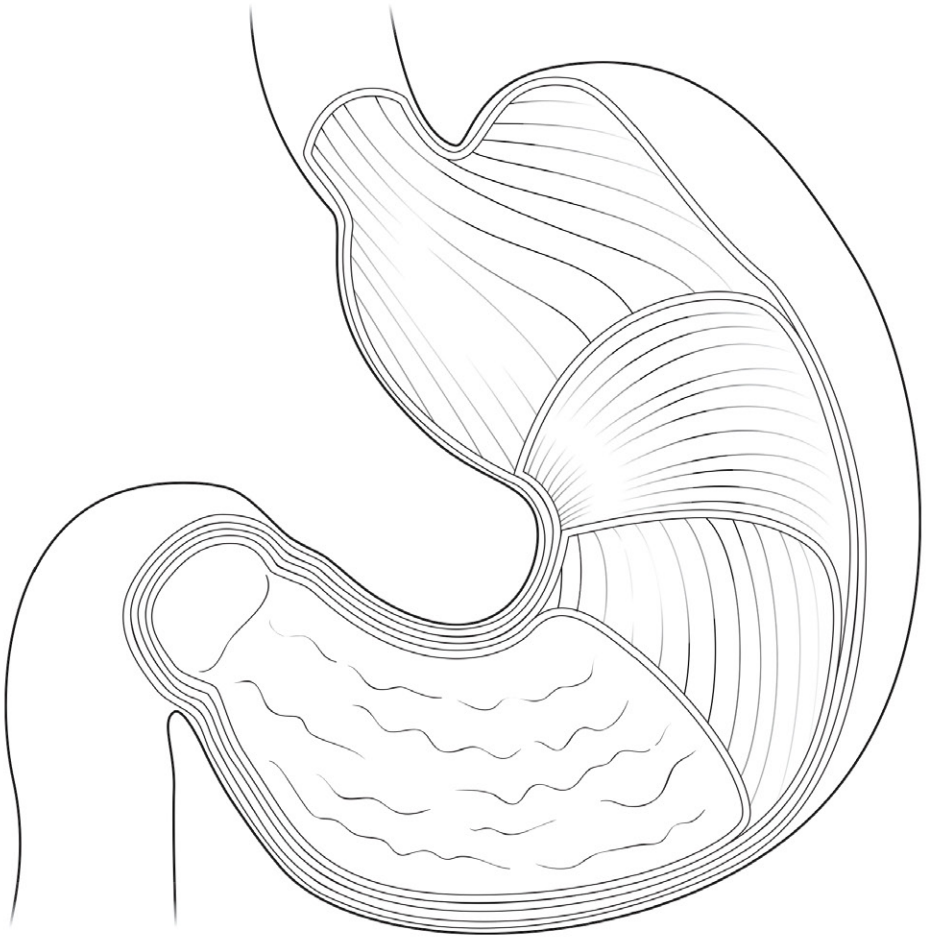

FIGURE **24.2** Structure of the stomach.

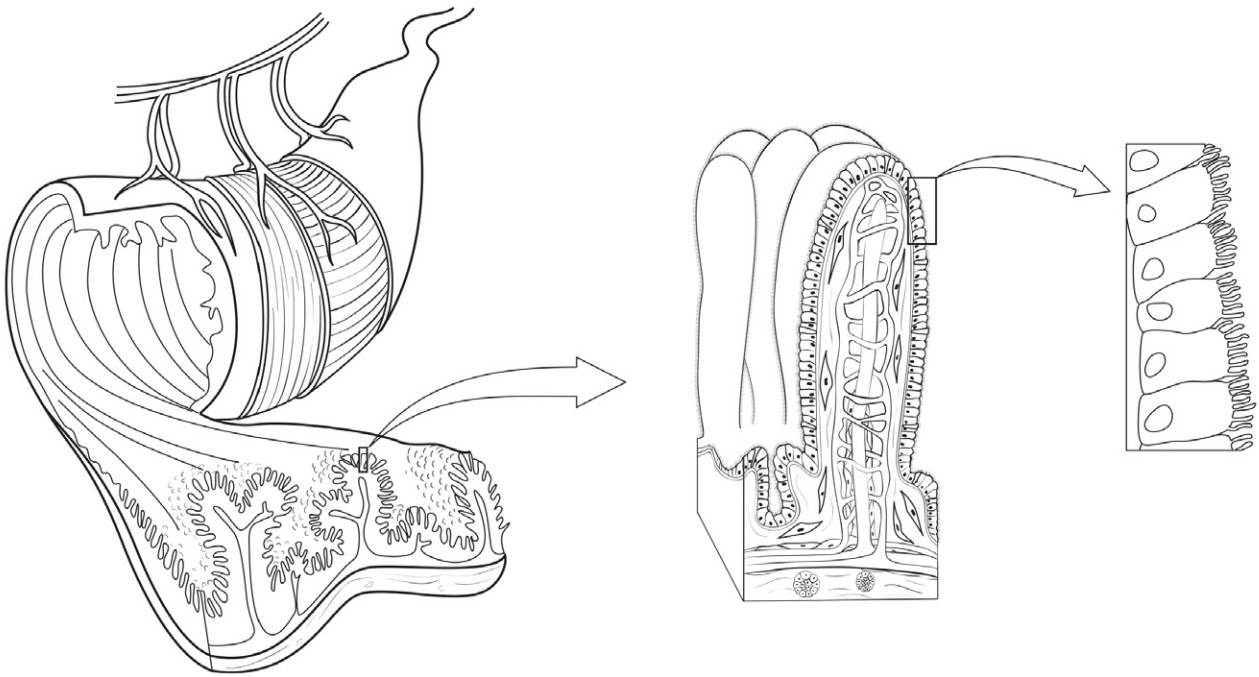

FIGURE **24.3** Gross and microscopic anatomy of the small intestine.

Name _____ Section _____ Date _____

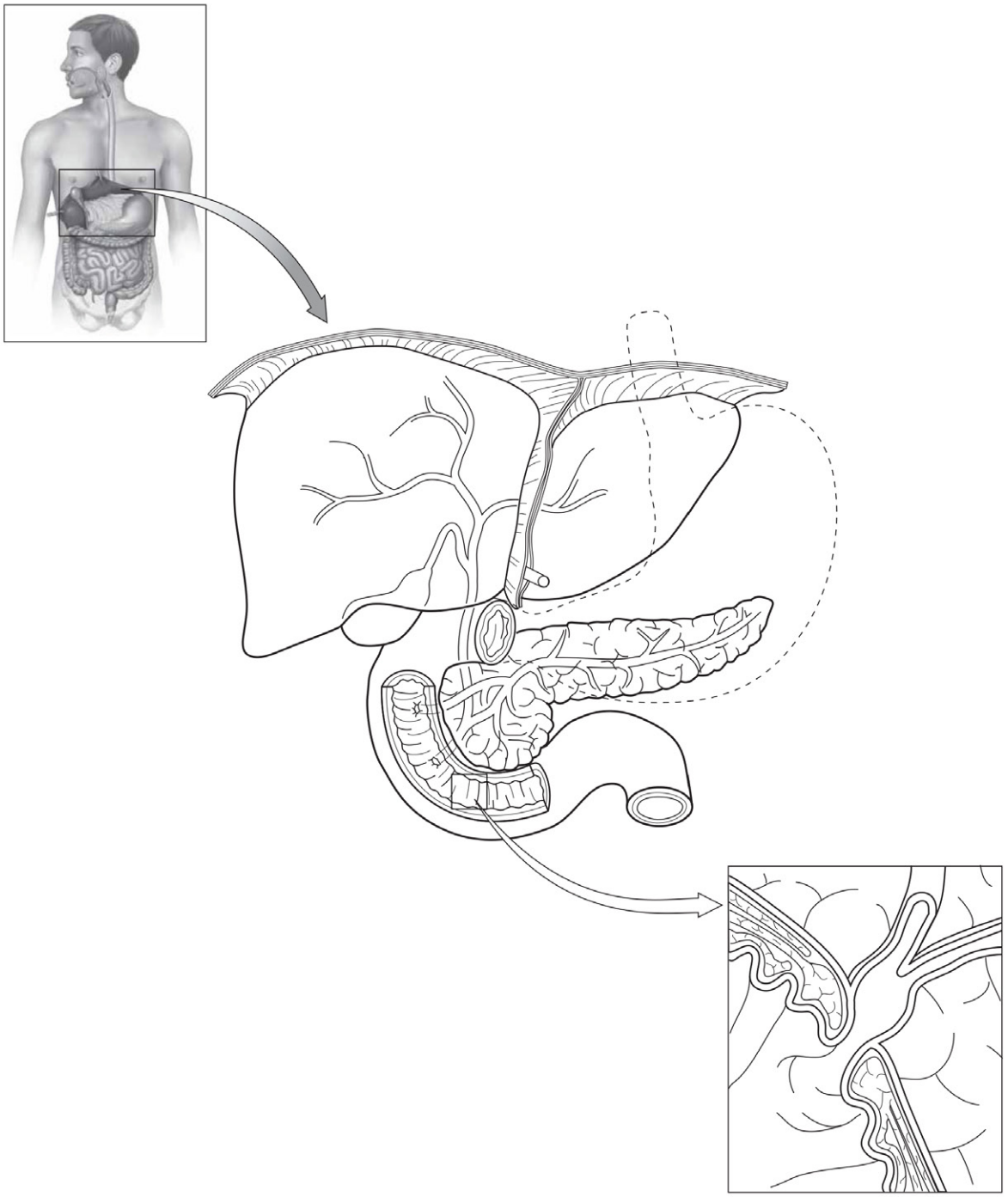

FIGURE **24.4** Structure of the liver, gallbladder, pancreas, and duodenum.

Pre-Lab Exercise 24-3



Digestive Enzymes

Chemical digestion is one of the main functions of the digestive system and is carried out with the help of numerous digestive enzymes. List the organ that produces each enzyme and the enzyme's function in Table 24.1.

TABLE **24.1** Digestive Enzymes

Enzyme	Source	Function
Salivary amylase		
Pepsin		
Trypsin		
Pancreatic lipase		
Brush border enzymes		



Colored SEM of microvilli in the duodenum.

EXERCISES

The food we eat contains nutrients our cells use to build and repair body tissues and to make ATP. Food macromolecules, however, are typically too large for the body to absorb and utilize, so they must be broken down into smaller molecules. This process of breaking down foods into smaller substances that can enter body cells is called **digestion** and is carried out by the **digestive system**. In general, the functions of the digestive system include ingesting food, breaking down food mechanically and chemically into nutrients, absorbing these nutrients into the bloodstream, and eliminating indigestible substances.

We begin this unit with an introduction to the anatomy and histology of the organs of the digestive system. Next we examine the physiological processes of chemical digestion and emulsification. We conclude with a "big picture" view of digestion through a tracing exercise.

Exercise 24-1

Digestive System Anatomy

MATERIALS

- ❑ Digestive system models
- ❑ Head and neck models
- ❑ Human torso models
- ❑ Human skulls with teeth
- ❑ Intestinal villus model
- ❑ Models of the tissue layers of the alimentary canal
- ❑ Digestive organ models (stomach, pancreas, liver, and duodenum)
- ❑ Colored pencils

The digestive system is composed of two groups of organs: (1) the organs of the **alimentary canal**, also known as the **gastrointestinal** or **GI tract,** through which food travels, and (2) the **accessory organs**, which assist in mechanical or chemical digestion (Fig. 24.5). The organs of the alimentary canal include the *oral cavity*, *pharynx*, *esophagus*, *stomach*, *small intestine*, and *large intestine*. The accessory organs include the *teeth*, *tongue*, *salivary glands*, *liver*, *gallbladder*, and *pancreas*. We discuss the structure of each in greater detail shortly.

Much of the alimentary canal and many of the accessory organs reside inside a cavity known as the **peritoneal cavity** (pehr-ih-toh-NEE-uhl; Fig. 24.6). Like the pleural and pericardial cavities, the peritoneal cavity is found between a double-layered serous membrane. The membrane secretes serous fluid to enable the organs within the cavity to slide over one another without friction. Organs that are within the peritoneal cavity are known as *intraperitoneal*, while those that are behind the cavity are *retroperitoneal*. You can see in Figure 24.6 how widespread the peritoneal cavity is, and how many of the abdominal organs are located either partially or totally within it.

The two layers of the peritoneal membranes are as follows:

1. **Parietal peritoneum.** The outer **parietal peritoneum** is a thin membrane functionally fused to the abdominal wall and certain organs.
2. **Visceral peritoneum.** The inner **visceral peritoneum** adheres to the surface of many abdominal organs. The visceral peritoneum around the intestines folds over on itself to form a thick membrane known as the **mesentery** (MEZ-en-tehr-ee; Fig. 24.7). The mesentery houses blood vessels, nerves, and lymphatic vessels and anchors these structures and the intestines in place. Mesenteries in different regions have specific names, such as the **greater omentum** (oh-MEN-tum), which covers the abdominal organs like an apron. The smaller **lesser omentum** runs from the liver to the lesser curvature of the stomach (visible in Figures 24.5 and 24.6). The mesentery attached to the large intestine is often called the *mesocolon*; for example, the *transverse mesocolon* is attached to the transverse colon, and the *sigmoid mesocolon* is attached to the sigmoid colon.

Let's now turn to the alimentary canal, which is a hollow passageway that extends from the mouth to the anus. Ingested food within the alimentary canal is broken down mechanically and chemically into nutrient molecules. The nutrients, along with water, vitamins, ions, and other substances, then cross the epithelium of the canal to enter the body and be absorbed into the blood or lymph.

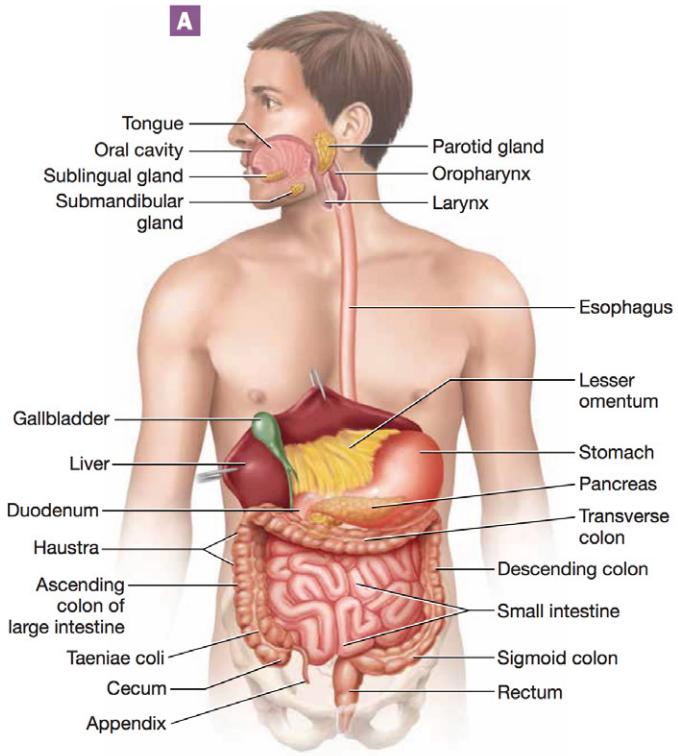

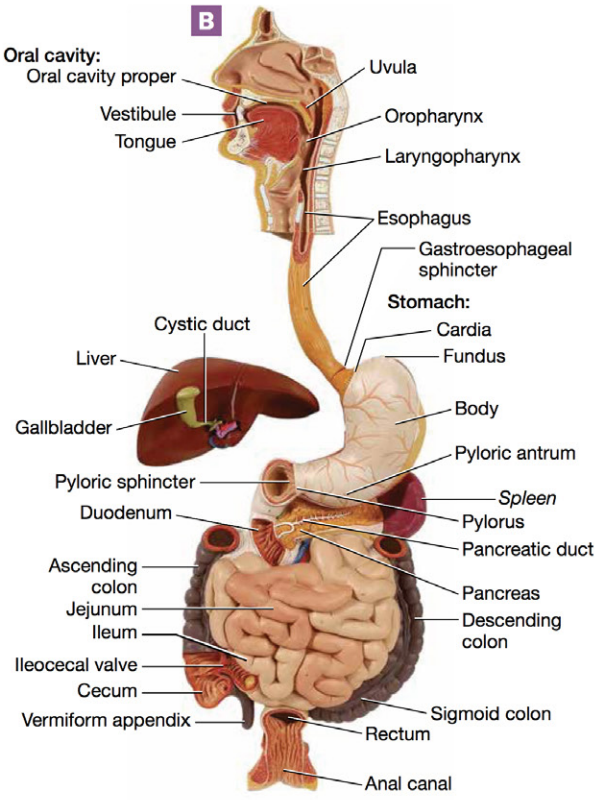

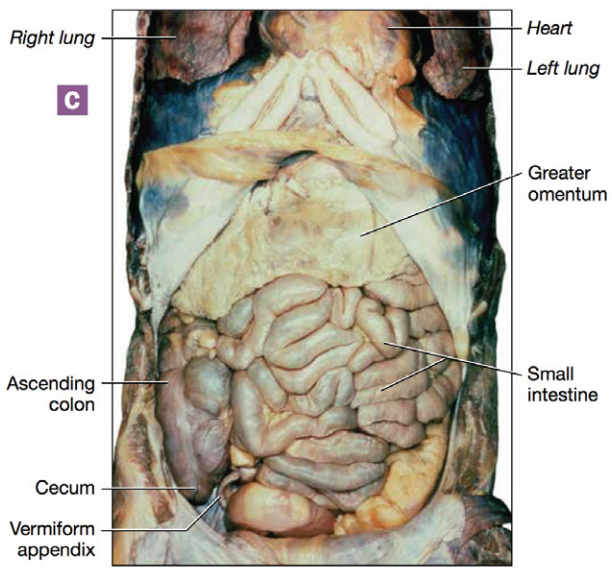

FIGURE **24.5** Overview of the digestive system: (A) illustration; (B) anatomical model photo; (C) a dissected abdominopelvic cavity.

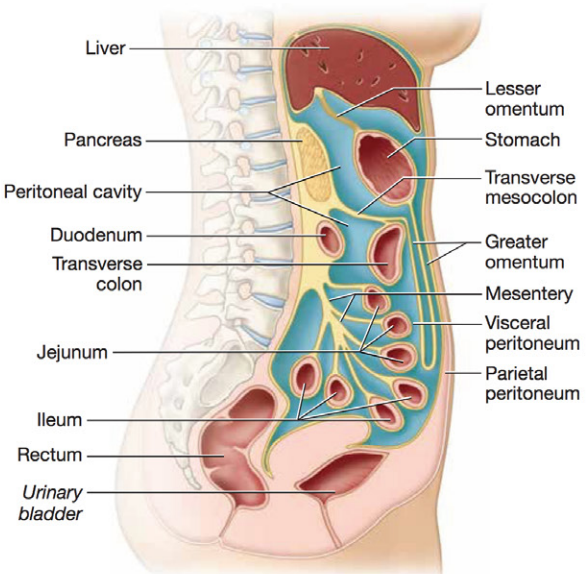

FIGURE **24.6** Structure of the peritoneal membranes and cavity.

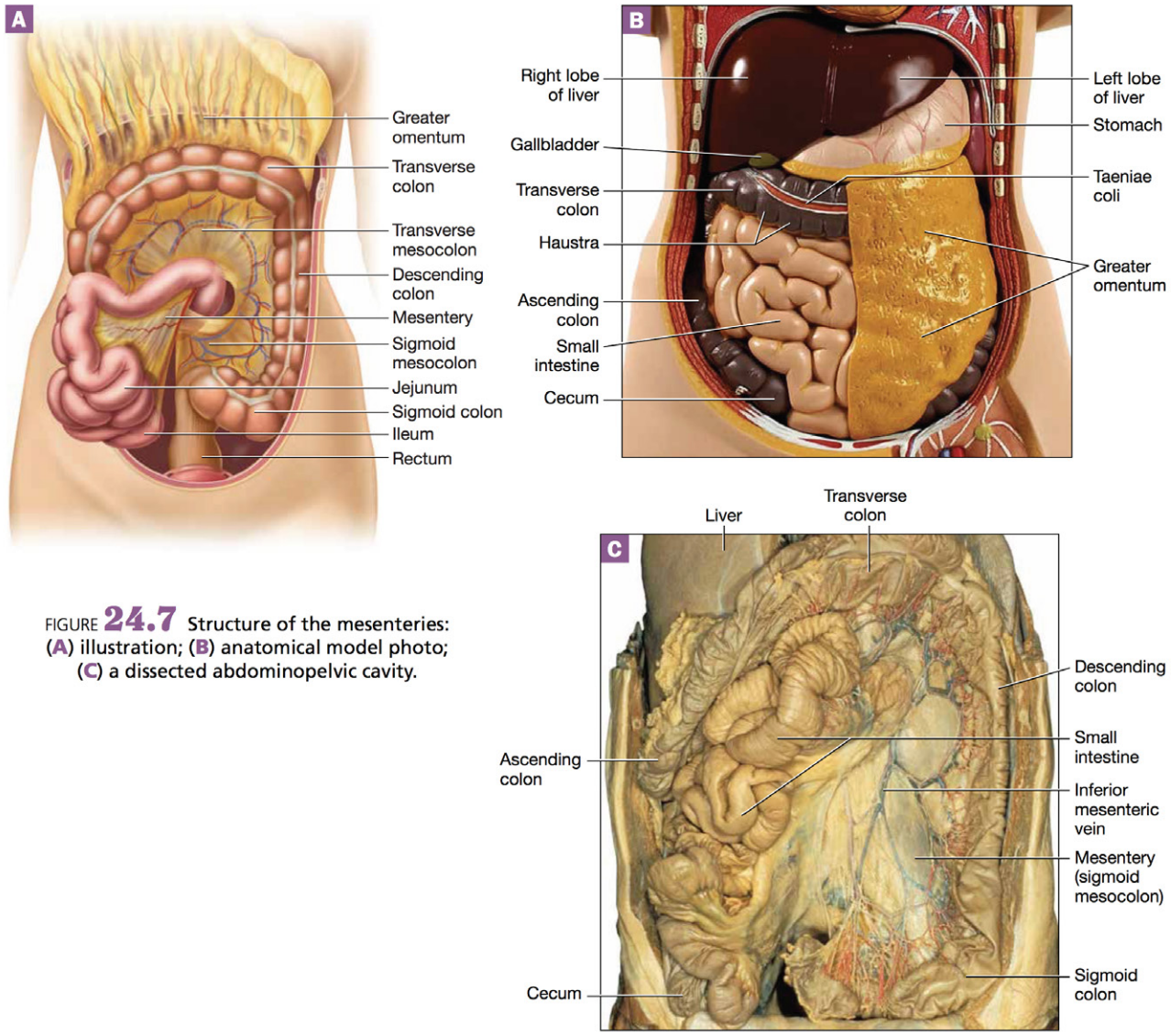

FIGURE **24.7** Structure of the mesenteries: (**A**) illustration; (**B**) anatomical model photo; (**C**) a dissected abdominopelvic cavity.

The alimentary canal consists of the following organs:

1. **Mouth.** The alimentary canal begins with the **mouth**, which has two internal regions: the vestibule and the oral cavity (Fig. 24.8). The **vestibule** is the space between the lips and the teeth. Within the vestibule we find the **gums**, or *gingivae* (JIN-jih-vay), and the maxilla and mandible, where the teeth are housed. We also find a narrow band of mucosa called the **labial frenulum** on each of the lips (both upper and lower) that attaches their internal surfaces to the upper and lower gums.

   Posterior to the vestibule we find the **oral cavity**, which is defined as the area posterior to the teeth and bounded by the palate, cheeks, and tongue. The "roof" of the mouth is the **palate** (PAL-it), which consists of two portions. The first, which makes up the anterior two-thirds of the palate, is the bony **hard palate**. Recall from the skeletal unit that the hard palate is formed by the palatine processes of the maxillary bones and the palatine bones. The second portion of the hard palate, which makes up its posterior one-third, is the muscular, arch-shaped **soft palate** (you can see this shape in Figure 24.8A). Extending inferiorly from the soft palate is the **uvula** (YOO-vyoo-luh)—both move posteriorly to prevent food from entering the nasopharynx and nasal cavity when we swallow.

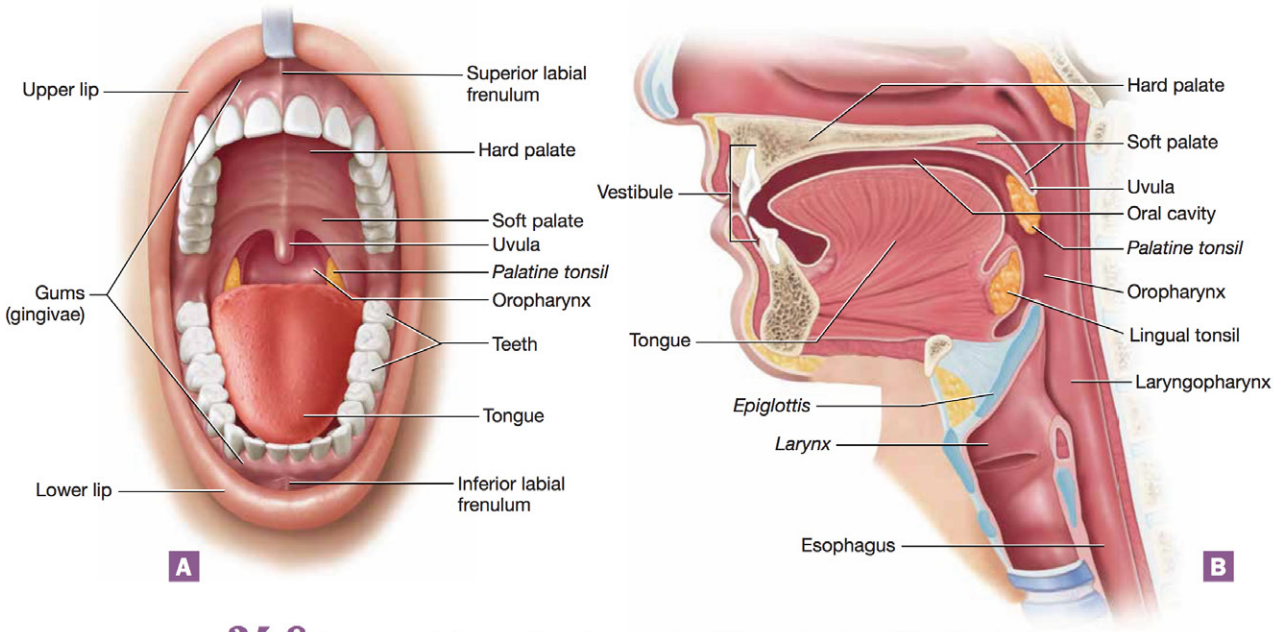

FIGURE **24.8** Structure of the mouth and oral cavity: (**A**) anterior view; (**B**) midsagittal section.

2. **Pharynx.** The food next enters the **pharynx** (FEHR-inks), also known as the throat. Food passes through two divisions of the pharynx: the **oropharynx** (ohr-oh-FEHR-inks) and the **laryngopharynx** (lah-ring-oh-FEHR-inks; Fig. 24.8B). The muscles surrounding the pharynx propel swallowed food, which is known as a *bolus*, into the next portion of the alimentary canal. Recall from the lymphatic and immune unit that two sets of tonsils are located in the oropharynx—the lingual tonsil and the palatine tonsil—which protect the alimentary canal from ingested pathogens.

3. **Esophagus.** The bolus next enters the **esophagus** (eh-SOF-ah-gus), a narrow tubular organ posterior to the heart and the trachea in the thoracic cavity. Smooth and skeletal muscle in the wall of the esophagus propel the bolus toward the stomach via rhythmic contractions called **peristalsis** (pehr-ih-STAHL-sis). At the inferior end of the esophagus is a ring of smooth muscle called the **gastroesophageal sphincter** (also known as the *lower esophageal sphincter* or *cardiac sphincter*). Several sphincters are found in the alimentary canal, where they regulate the flow of materials from one section of the canal to another. The gastroesophageal sphincter normally remains closed, which prevents the contents of the stomach from regurgitating into the esophagus.

4. **Stomach.** The **stomach,** shown in Figure 24.9, has five regions: the **cardia** near the gastroesophageal sphincter, the dome-shaped **fundus,** the middle **body,** the inferior **pyloric antrum,** and the terminal portion of the stomach, the **pylorus** (py-LOHR-us). At the pylorus we find another sphincter, the **pyloric sphincter,** which regulates the flow of material from the stomach to the initial portion of the small intestine.

   Note in Figure 24.9 that the stomach has interior folds called **rugae** (ROO-ghee) that allow it to expand considerably when it is filled with food and liquid. In addition, notice that the wall of the stomach has three layers of smooth muscle (inner oblique, middle circular, and outer longitudinal layers) that work together to pummel the bolus into a liquid material called **chyme** (KAYE'M).

5. **Small intestine.** Chyme passes through the pyloric sphincter to enter the **small intestine,** the portion of the alimentary canal where most chemical digestion and absorption take place. It has three divisions: the initial **duodenum** (doo-AW-den-um), the middle **jejunum** (jeh-JOO-num), and the terminal **ileum** (ILL-ee-um; Fig. 24.10).

   Of the three divisions, the duodenum is the shortest, measuring only about 10 inches. The jejunum and the ileum measure about 8 feet and 12 feet long, respectively. Notice in Figure 24.10 that at the terminal ileum there is a sphincter called the **ileocecal valve** (ill-ee-oh-SEE-kuhl) that abuts the first portion of the large intestine, the *cecum*. This valve helps to prevent bacteria in the large intestine from reaching the normally sterile small intestine.

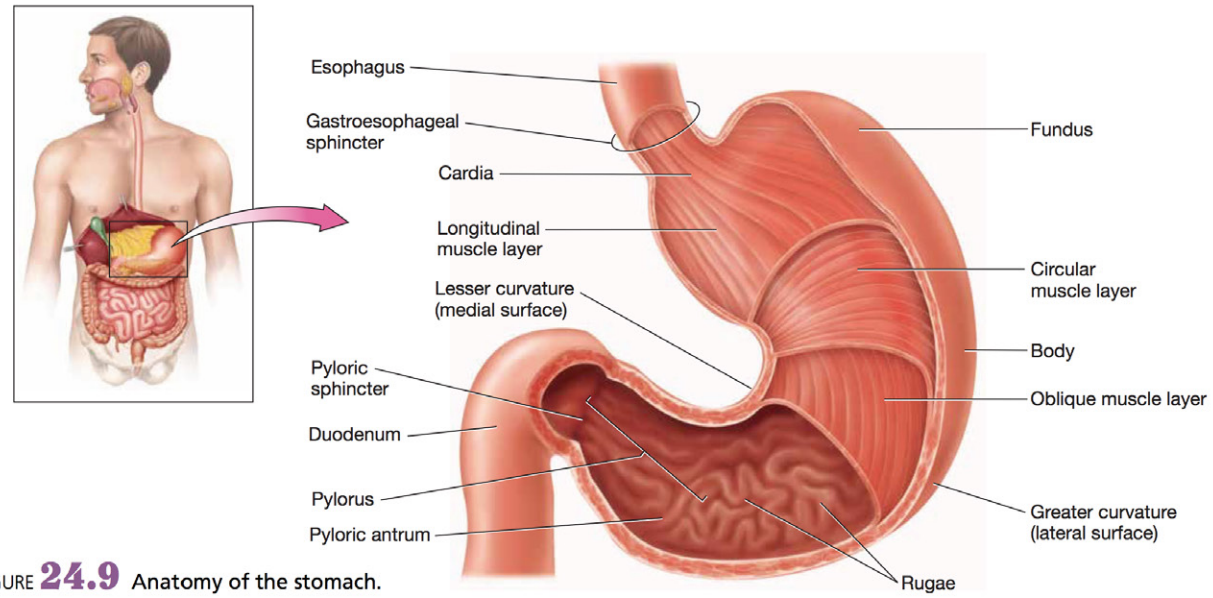

FIGURE **24.9** Anatomy of the stomach.

6. **Large intestine.** Material from the small intestine that was not digested or absorbed moves next to the terminal part of the alimentary canal, the **large intestine,** which is named for its large diameter rather than its length (about 5.5 feet). Much of the large intestine features bands of longitudinal smooth muscle called **taeniae coli** (TEE-nee-ee KOHL-aye). These smooth muscle bands have a drawstring effect on the large intestine, pulling it into pouches called **haustra** (HAW-struh; Figs. 24.11A and B). Extending from the external surface of the large intestine are fat-filled pouches of visceral peritoneum called *epiploic appendages* (ep-ih-PLOH-ik).

The large intestine may be divided into four regions:

a. The **cecum** (SEE-kum) is the blind pouch that receives contents from the ileum, from which it is separated by the ileocecal valve. It features an extension called the **vermiform appendix,** also visible in Figure 24.11C, which is a blind-ended sac that contains lymphoid follicles.

b. The next segment is the **colon,** which itself has four divisions. It begins as the **ascending colon,** which turns left at the **hepatic flexure** and crosses the superior abdomen as the **transverse colon.** At the spleen, the colon turns inferiorly at the **splenic flexure** to become the **descending colon,** which curves into an S-shape as it approaches the sacrum to become the **sigmoid colon.**

c. The **rectum** is the straight part of the large intestine that runs anterior to the sacrum. Its walls have *rectal valves* that help to control the passage of flatus and feces.

d. The terminal portion of the large intestine is the **anal canal.** It has two sphincters: the involuntary **internal anal sphincter** and the voluntary **external anal sphincter.**

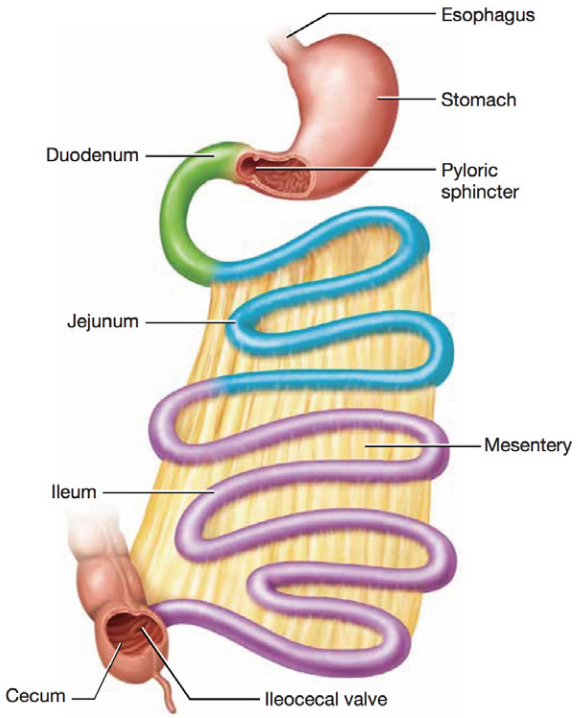

FIGURE **24.10** Small intestine, spread out to show the divisions.

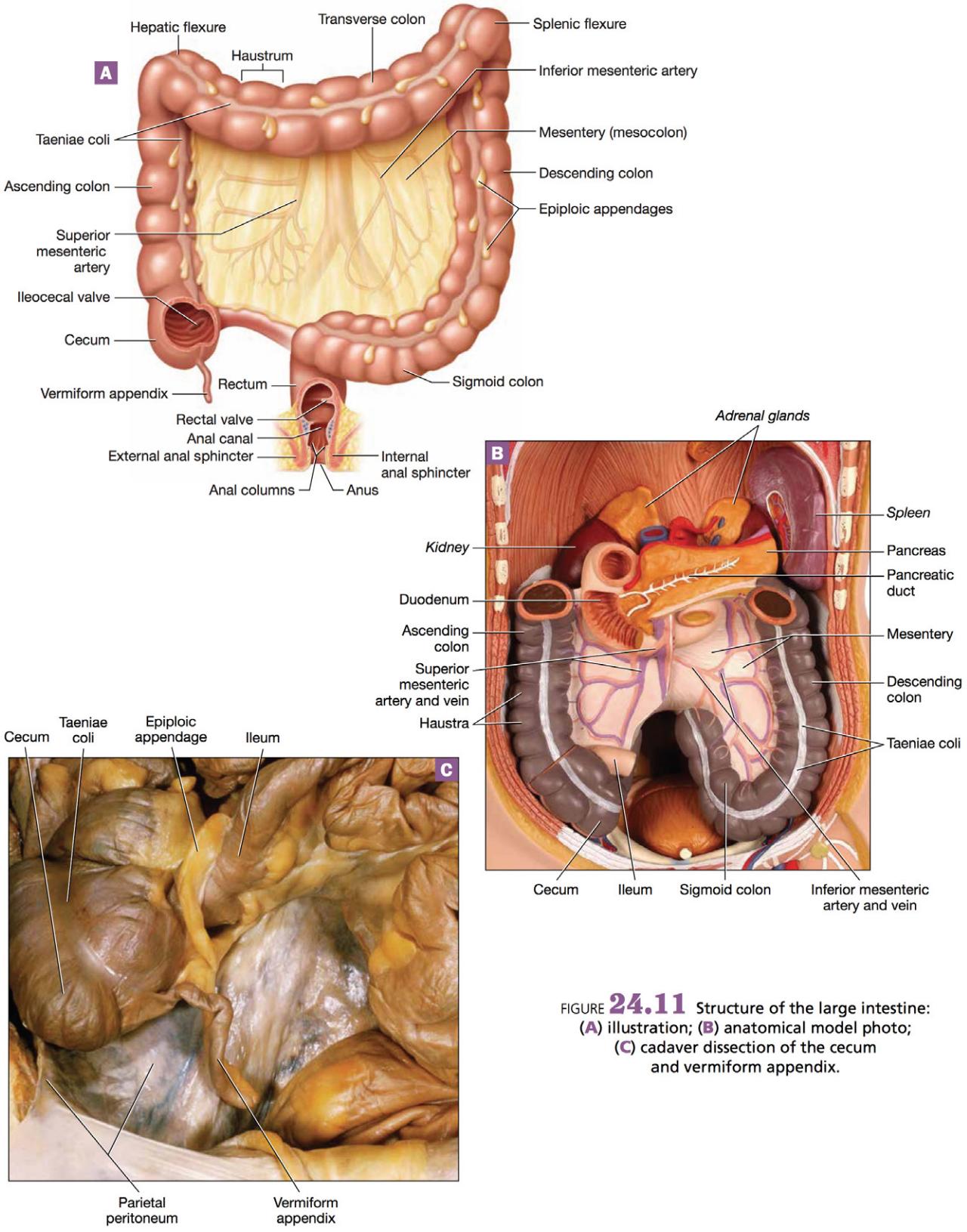

FIGURE **24.11** Structure of the large intestine: (A) illustration; (B) anatomical model photo; (C) cadaver dissection of the cecum and vermiform appendix.

The accessory digestive organs generally do not come into direct contact with the ingested food (the teeth and tongue are exceptions). Most of them instead secrete substances such as bile salts and enzymes that travel through a duct to the alimentary canal. The accessory digestive organs are as follows:

1. **Teeth and tongue.** The **teeth** and the **tongue** are accessory organs located in the mouth that assist in mechanical digestion of ingested food. The tongue's surface features keratinized papillae called **filiform papillae** that provide a rough surface to help break down food physically. Note that filiform papillae do not contain taste buds, which are located only on circumvallate, foliate, and fungiform papillae (for a review of tongue anatomy, see Unit 15, p. 408).

   The **teeth** are located in bony sockets known as *alveoli* within the mandible and maxilla. They are held in place by bands of collagen fibers known collectively as the *periodontal ligament* (pehr-ee-oh-DAHN-tuhl). There are three classes of teeth:

   - **Incisors.** The **incisors** are the broad and flat central teeth. There are four incisors: the two *central incisors*, and the two *lateral incisors*.
   - **Canines.** The **canines** (KAY-nynz), also known as *cuspids*, are the pointed teeth located to the sides of the lateral incisors.
   - **Molars.** There are two sets of molars. First are the **premolars**, located lateral to the canines, and second are the larger **molars**, which are the posterior teeth.

   As you are no doubt aware, humans normally have two sets of teeth: one set of "baby teeth" and one set of "permanent teeth." The "baby teeth" are known as the **primary dentition** or **deciduous teeth** (dih-SIJ-oo-uhs), and are shown in Figure 24.12A. Notice that there are 20 deciduous teeth: 4 incisors, 2 canines, and 4 molars each in the maxilla and mandible. The **secondary dentition** or **permanent teeth** generally begin to erupt at about 6 years of age when these teeth enlarge and cause the roots of the deciduous teeth to dissolve. There are 32 permanent teeth, shown in Figure 24.12B: 4 incisors, 2 canines, 4 premolars, and 6 molars each in the maxilla and mandible. Generally by age 12 all of the deciduous teeth have fallen out and all but the third set of molars, the "wisdom teeth," have erupted. These third molars tend to erupt later, around age 17, although they often remain embedded in the bone, a condition called *impaction*.

2. **Salivary glands.** The **salivary glands** are exocrine glands located around the mouth (Fig. 24.13). There are three sets of salivary glands:
   a. The largest salivary glands are the paired **parotid glands** (puh-RAWT-id), which are located superficial to the masseter muscles. The secretions of the parotid gland pass through a duct called the **parotid duct**, which enters the oral cavity by piercing the buccinator muscle.
   b. The smaller **submandibular glands** are located just medial to the mandible. They secrete saliva through the **submandibular ducts**, which open into the floor of the oral cavity under the tongue.
   c. The **sublingual glands** (sub-LING-gwuhl) are located under the tongue, as their name implies. They secrete saliva through multiple **sublingual ducts**.

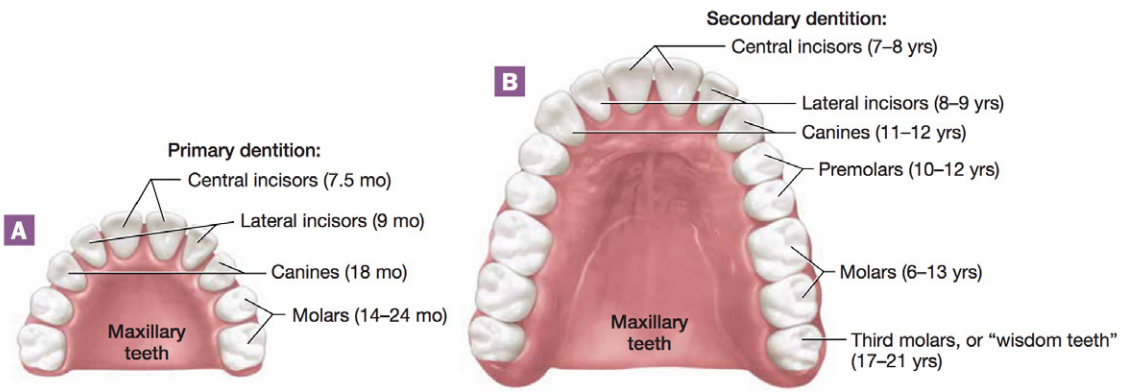

FIGURE **24.12** Teeth: (A) primary dentition of the maxilla; (B) secondary dentition of the maxilla.

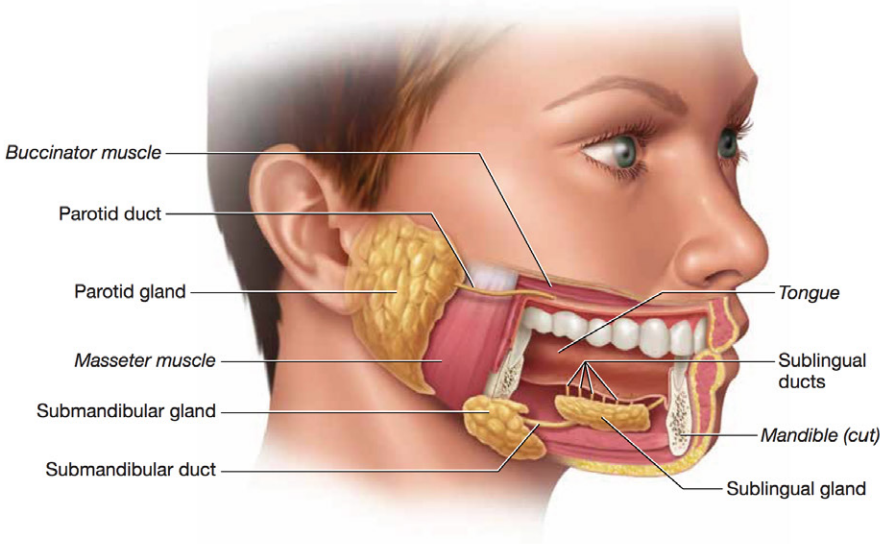

FIGURE **24.13** Salivary glands.

All three types of glands secrete **saliva,** which contains water, mucus, an enzyme called *salivary amylase*, and antimicrobial proteins such as *lysozyme*.

3. **Liver and gallbladder.** The liver and gallbladder are organs located in the right upper quadrant of the abdominal cavity.
   a. The **liver** consists of four lobes: the large **right** and **left lobes,** and the small **caudate** and **quadrate lobes,** which are located on the posterior side of the right lobe (Fig. 24.14). The liver is wrapped in a thin connective tissue capsule, and most of it is covered by the visceral peritoneum. On the liver's anterior side, shown in Figure 24.14A, we find the **falciform ligament** (FALL-sih-form), which is a fold of visceral peritoneum that separates the right and left lobes and anchors the liver to the abdominal wall. Inferior to the falciform ligament is the **round ligament,** which is a remnant of a structure called the *umbilical vein* that brings oxygenated blood to the fetus.

      On the liver's posterior side near the quadrate lobe, shown in Figure 24.14B, is an area called the **porta hepatis** (POHR-tuh heh-PAEH-tis). This area serves as a main "gateway" into and out of the liver, as the hepatic artery, the hepatic portal vein, and the common hepatic duct all enter and exit via the porta hepatis. Note the exception is the hepatic veins, which exit at the superior side of the liver, where they drain into the inferior vena cava.

      The liver has multiple functions in the body, most of which are metabolic in nature. For example, recall from Unit 18 that all blood from the digestive organs and the spleen travels via the hepatic portal vein to the hepatic portal system of

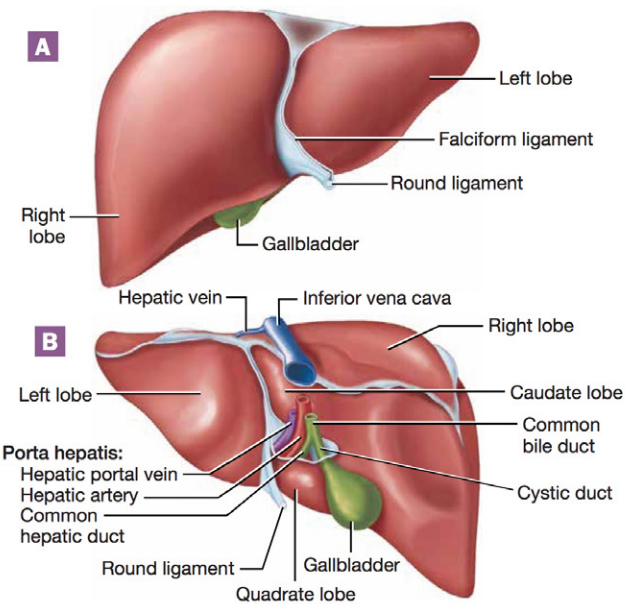

FIGURE **24.14** Anatomy of liver: (**A**) anterior view; (**B**) posterior view.

the liver. There, the absorbed nutrients and other substances are processed before they enter the general circulation. One of the liver's main digestive functions is to produce a chemical called *bile*, required for the digestion and absorption of fats.

b. The **gallbladder** is a small, saclike organ on the posterior side of the liver that stores and concentrates bile. Bile leaves the right and left lobes of the liver by the *right* and *left hepatic ducts*, which merge to form the **common hepatic duct**. Some bile may be released into the duodenum depending on hormonal signals, but most of it enters the gallbladder for storage (Fig. 24.15). When stimulated by certain hormones, the gallbladder contracts, and the bile contained within it is ejected through the **cystic duct** (SIS-tik). Notice that the cystic duct joins with the common hepatic duct to form the **common bile duct**, which empties into the duodenum at the **hepatopancreatic ampulla** (heh-PAEH-toh-payn-kree-at-ik am-POOL-ah). A sphincter controls the release of bile from the ampulla to the duodenum.

4. **Pancreas.** The **pancreas** (PAYN-kree-us) is an exocrine and endocrine gland that sits posterior and inferior to the stomach. Its exocrine functions are digestive, whereas its endocrine functions are metabolic. The exocrine portion of the pancreas produces a fluid called **pancreatic juice** that contains water, bicarbonate ions to neutralize the acid produced by the stomach, and multiple digestive enzymes. Pancreatic juice is released through the **pancreatic duct** and enters the duodenum at the hepatopancreatic ampulla.

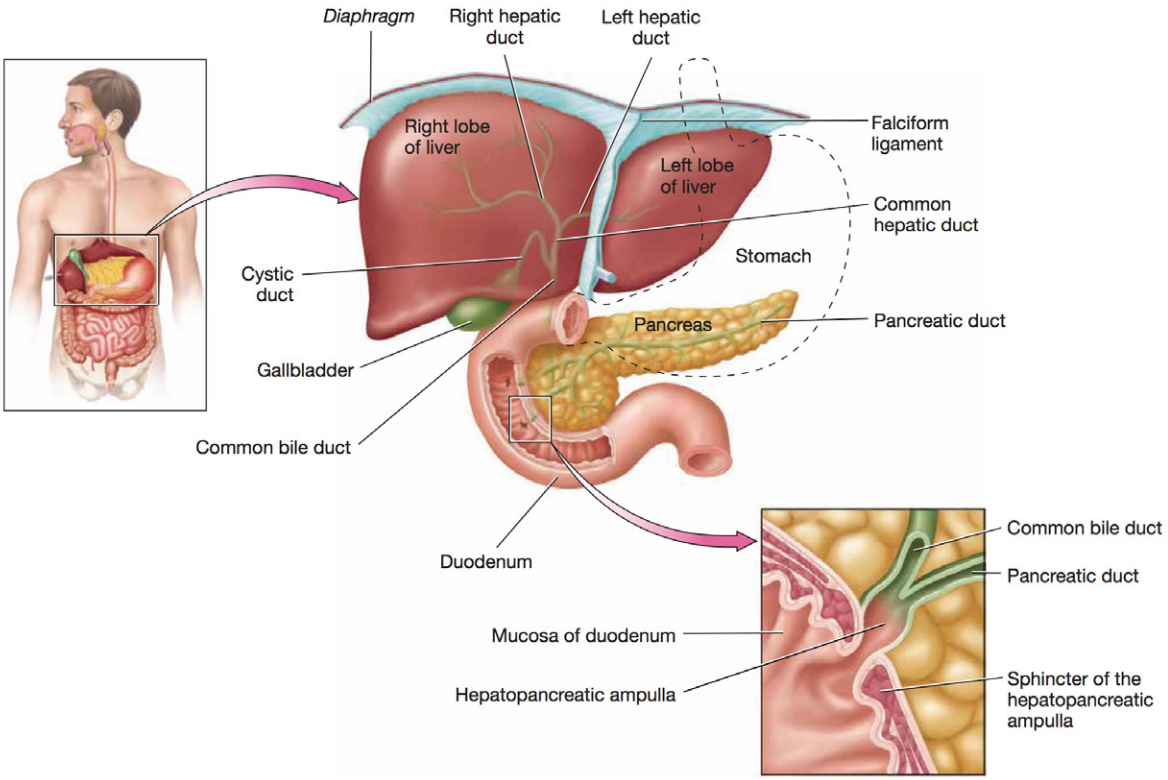

FIGURE **24.15** Structure of the liver, gallbladder, pancreas, and duodenum.

Procedure 1 Model Inventory for the Digestive System

Identify the following structures of the digestive system on models and diagrams, using your textbook and this unit for reference. As you examine the anatomical models and diagrams, record the name of the model and the structures you were able to identify on the model inventory in Table 24.2. After you have completed the activity, answer Check Your Understanding questions 1 through 3 (p. 661).

Peritoneum

1. Peritoneal cavity
2. Parietal peritoneum
3. Visceral peritoneum
4. Mesentery
5. Greater omentum
6. Lesser omentum

Accessory Organs

1. Tongue
   a. Filiform papillae
2. Teeth
   a. Incisors
   b. Canines
   c. Premolars
   d. Molars
   e. Primary dentition
   f. Secondary dentition
3. Salivary glands
   a. Parotid gland with parotid duct
   b. Submandibular gland with submandibular duct
   c. Sublingual gland with sublingual ducts
4. Liver
   a. Right lobe, left lobe, caudate lobe, and quadrate lobe
   b. Falciform ligament
   c. Round ligament
   d. Porta hepatis
   e. Hepatic arteries
   f. Hepatic portal vein
   g. Hepatic veins
   h. Common hepatic duct
5. Gallbladder
   a. Cystic duct
   b. Common bile duct
   c. Hepatopancreatic ampulla
6. Pancreas
   a. Pancreatic duct

Alimentary Canal

1. Mouth
   a. Vestibule
   b. Gums (gingivae)
   c. Labial frenulum
   d. Oral cavity
   e. Hard palate
   f. Soft palate
      (1) Uvula
2. Pharynx
   a. Oropharynx
   b. Laryngopharynx
3. Esophagus
   a. Gastroesophageal sphincter (or lower esophageal sphincter)
4. Stomach
   a. Cardia
   b. Fundus
   c. Body
   d. Pyloric antrum
   e. Pylorus
   f. Pyloric sphincter
   g. Rugae
5. Small intestine
   a. Duodenum
   b. Jejunum
   c. Ileum
   d. Ileocecal valve
6. Large intestine
   a. Taeniae coli
   b. Haustra
   c. Cecum
      (1) Vermiform appendix
   d. Colon
      (1) Ascending colon
      (2) Hepatic flexure
      (3) Transverse colon
      (4) Splenic flexure
      (5) Descending colon
      (6) Sigmoid colon
   e. Rectum
   f. Anal canal
      (1) Internal anal sphincter
      (2) External anal sphincter

Your instructor may wish to omit certain structures or add structures not included in these lists. List any additional structures below:

TABLE **24.2** Model Inventory for the Digestive System

Model/Diagram	Digestive Structures Identified

Procedure 2 Time to Draw

In the space below, draw, color, and label the arrangement of the liver, gallbladder, pancreas, and duodenum. In addition, write the function of each structure that you label.

Exercise 24-2

Digestive System Histology

MATERIALS

- ❑ Model of the layers of the alimentary canal
- ❑ Esophagus slide
- ❑ Stomach slide
- ❑ Duodenum slide
- ❑ Pancreas slide
- ❑ Liver slide
- ❑ Tooth slide
- ❑ Light microscope
- ❑ Colored pencils

The organs of the alimentary canal follow the same basic pattern we have seen for other hollow organs: an inner layer of epithelial tissue that rests on connective tissue, a middle layer of smooth muscle, and an outer layer of supportive connective tissue. The tissue layers of the alimentary canal, shown in Figure 24.16, are named as follows:

1. **Mucosa.** The inner epithelial tissue lining of the alimentary canal is called the **mucosa.** Throughout most of the alimentary canal, it consists of simple columnar epithelium overlying a lamina propria and a thin layer of smooth muscle called the **muscularis mucosa.** Within the mucosa we find a collection of lymphoid follicles called **mucosa-associated lymphatic tissue** (**MALT**), mucus-secreting goblet cells, and other glands that secrete products such as hydrochloric acid and enzymes. The mucosa is generally covered with a layer of mucus, which helps protect the underlying epithelium from the effects of acid and digestive enzymes.
2. **Submucosa.** Deep to the mucosa we find the **submucosa,** a layer of connective tissue that houses blood vessels, nerves, lymph vessels, and elastic fibers.
3. **Muscularis externa.** The **muscularis externa** in most regions of the alimentary canal has two layers of smooth muscle—an inner circular layer and an outer longitudinal layer. These two layers contract alternately to produce the rhythmic contractions of peristalsis.
4. **Serosa** or **adventitia.** The outer layer of the alimentary canal is called the **serosa** in the locations where it is composed of the visceral peritoneum, and the **adventitia** in places where it is composed of dense irregular collagenous connective tissue.

Although this pattern is followed throughout most of the alimentary canal, there are some notable differences in some organs, particularly in the esophagus (Fig. 24.17). The mucosa of the esophagus is composed of stratified squamous epithelium with no goblet cells or thick mucus layer. In addition, the esophagus' muscularis externa changes as it progresses toward the stomach. The upper one-third of the esophagus is skeletal muscle, the middle one-third is about half skeletal muscle and half smooth muscle, and the lower one-third is smooth muscle. These differences in the muscularis externa help you to determine the location of the section you are examining.

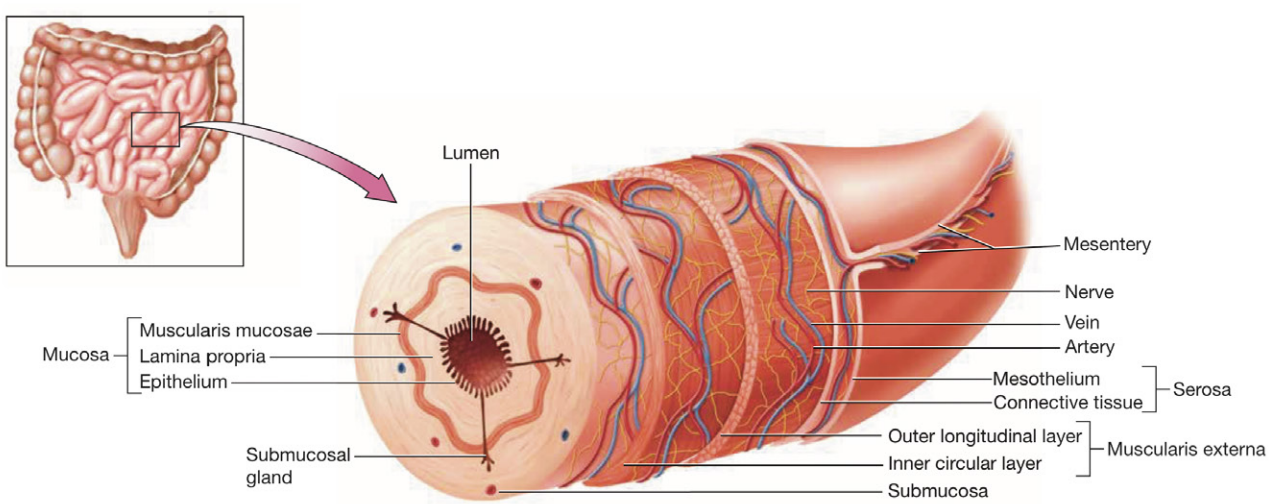

FIGURE **24.16** Tissue layers of the alimentary canal.

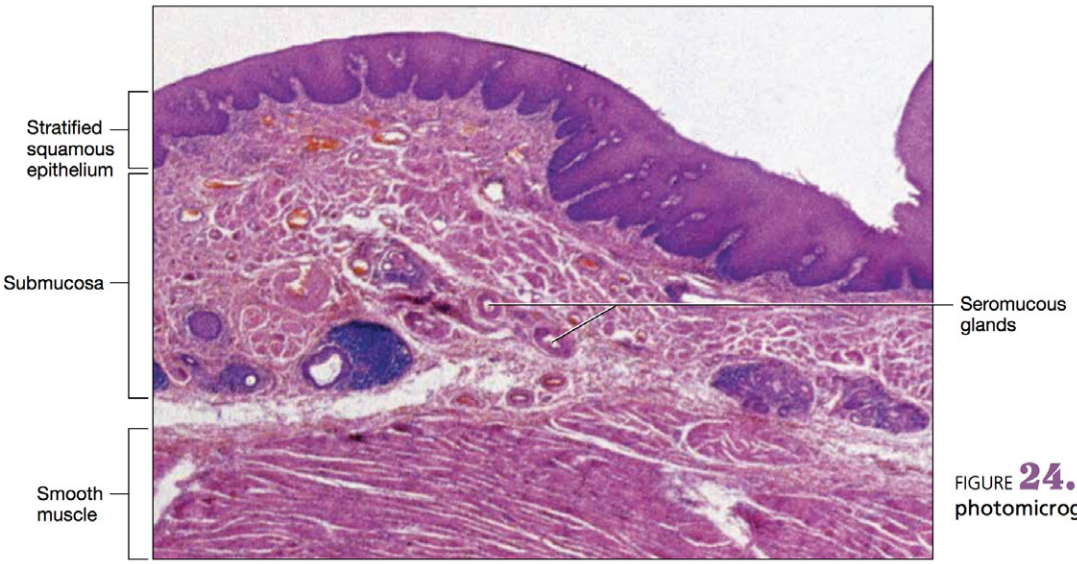

FIGURE **24.17** Esophagus, photomicrograph.

You will also find variations in the pattern in the stomach. Recall from Exercise 24-1 (p. 629) that the muscularis externa of the stomach has three layers of smooth muscle, with an additional oblique layer. In addition, the stomach's mucosa is heavily indented, which reflects the presence of numerous **gastric pits** that lead to **gastric glands** (Fig. 24.18). These glands secrete products for digestion into the stomach, including hydrochloric acid and enzymes, known collectively as **gastric juice**. Certain cells within the glands also produce hormones that are secreted into the blood. The stomach mucosa between the gastric pits contains a large number of goblet cells.

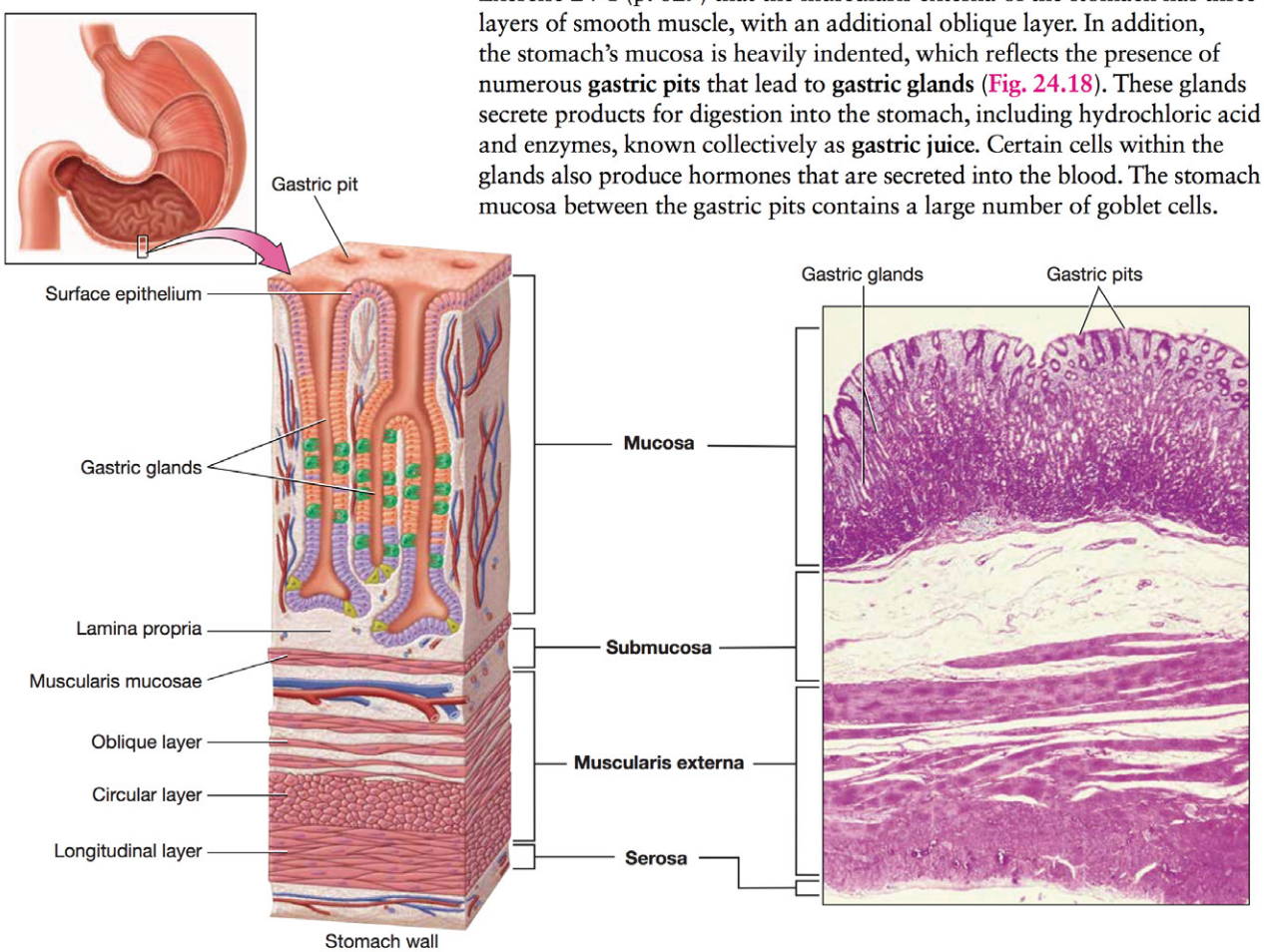

FIGURE **24.18** Microanatomy of the stomach and gastric glands.

The structure of the small intestinal wall also features numerous specializations. For example, the submucosa of the duodenum houses *duodenal glands*, which secrete a protective alkaline mucus to coat the mucosa. Also, notice in Figure 24.19 that the wall of the small intestine is highly folded, an adaptation that increases the surface area available for absorption. There are three sets of folds:

1. **Circular folds.** The **circular folds,** also known as *plicae circulares*, are folds of the mucosa and submucosa. They are visible as ridges along the surface of the small intestinal wall.

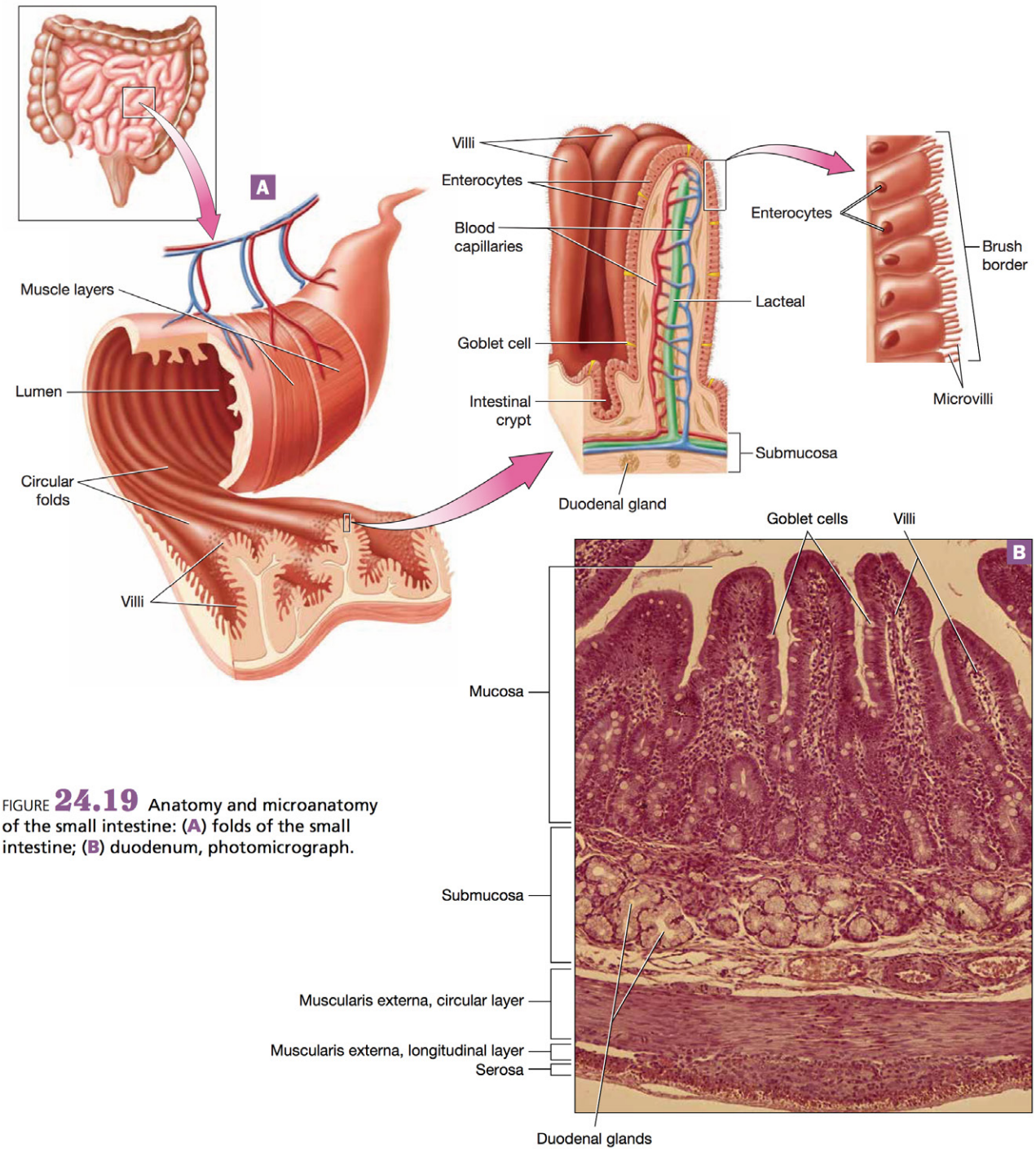

FIGURE **24.19** Anatomy and microanatomy of the small intestine: (A) folds of the small intestine; (B) duodenum, photomicrograph.

2. **Villi.** The fingerlike **villi** (VILL-aye) are folds of the mucosa, and they make up the "fringe" on the circular folds. Note in Figure 24.19 that between the villi are glands called **intestinal crypts**. Each villus consists of an outer layer of simple columnar epithelial cells called **enterocytes** surrounding a connective tissue core. Within the core of the villus we find blood vessels and a lymphatic vessel called a **lacteal** (lak-TEEL).
3. **Microvilli.** The smallest folds are **microvilli,** which are extensions of the enterocytes' plasma membranes. The enterocytes and their microvilli are often collectively referred to as the *brush border*.

The three accessory digestive organs we will examine in this exercise—the pancreas, liver, and a tooth—are not hollow organs, so they do not follow the same histological pattern as the alimentary canal. The pancreas is a gland that consists of clusters of cells that produce exocrine and endocrine secretions (Fig. 24.20). The exocrine cells of the pancreas, called **acinar cells** (AY-sin-ahr), produce and secrete pancreatic juice (digestive enzymes, bicarbonate ions, and water) into ducts. The endocrine cells of the pancreas, called **pancreatic islets** (AYE-lets), secrete hormones such as insulin into the bloodstream. They are visible as small, circular groups of cells that stain less darkly than the surrounding acinar cells.

The liver is composed of hepatocytes organized into hexagonal plates of cells called **liver lobules** (Fig. 24.21). At the center of each lobule is a central vein that will eventually drain into a hepatic vein. At each of the six corners of a liver lobule we find three small vessels collectively called **portal triads**. The three vessels are: (1) a **bile duct**, which transports bile made by hepatocytes to the hepatic duct; (2) a **portal venule**, which is a tiny branch off the hepatic portal vein that delivers nutrient-rich blood to the liver for processing and detoxification; and (3) a **hepatic arteriole**, which delivers oxygen-rich blood to hepatocytes.

The last slide you will examine is a tooth, which has two components: the **crown**, which is the visible portion above the gum line, and the **root**, which is embedded within the bone (Fig. 24.22). The outer layer of the tooth in the crown is composed of **enamel**, which is the hardest substance in the body being made almost completely of calcium hydroxyapatite crystals. In the root, the outer layer of the tooth is called **cementum**; its composition is similar to bone, and so it is about as hard as bone tissue. Collagen fibers from the *periodontal ligament* extend into the cementum to help hold the tooth in place. Both enamel and cementum cover the next layer of the tooth, the **dentin**, which is the second hardest material in the body. Dentin covers the soft, inner **pulp** that resides in the **pulp cavity**, along with nerves and blood vessels. The pulp cavity, blood vessels, and nerves extend into the root of the tooth via the **root canal**.

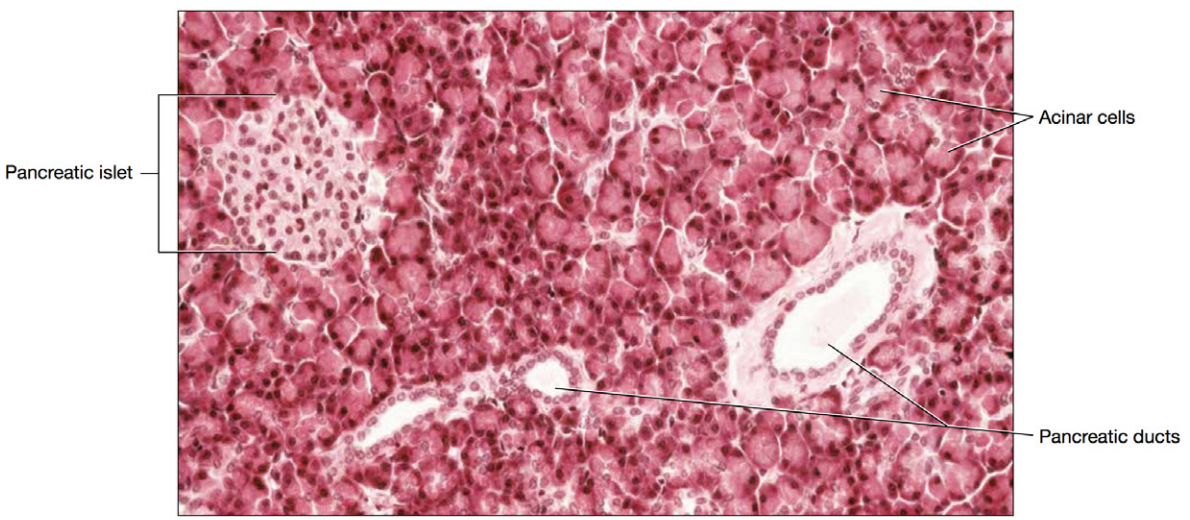

FIGURE **24.20** Pancreas, photomicrograph.

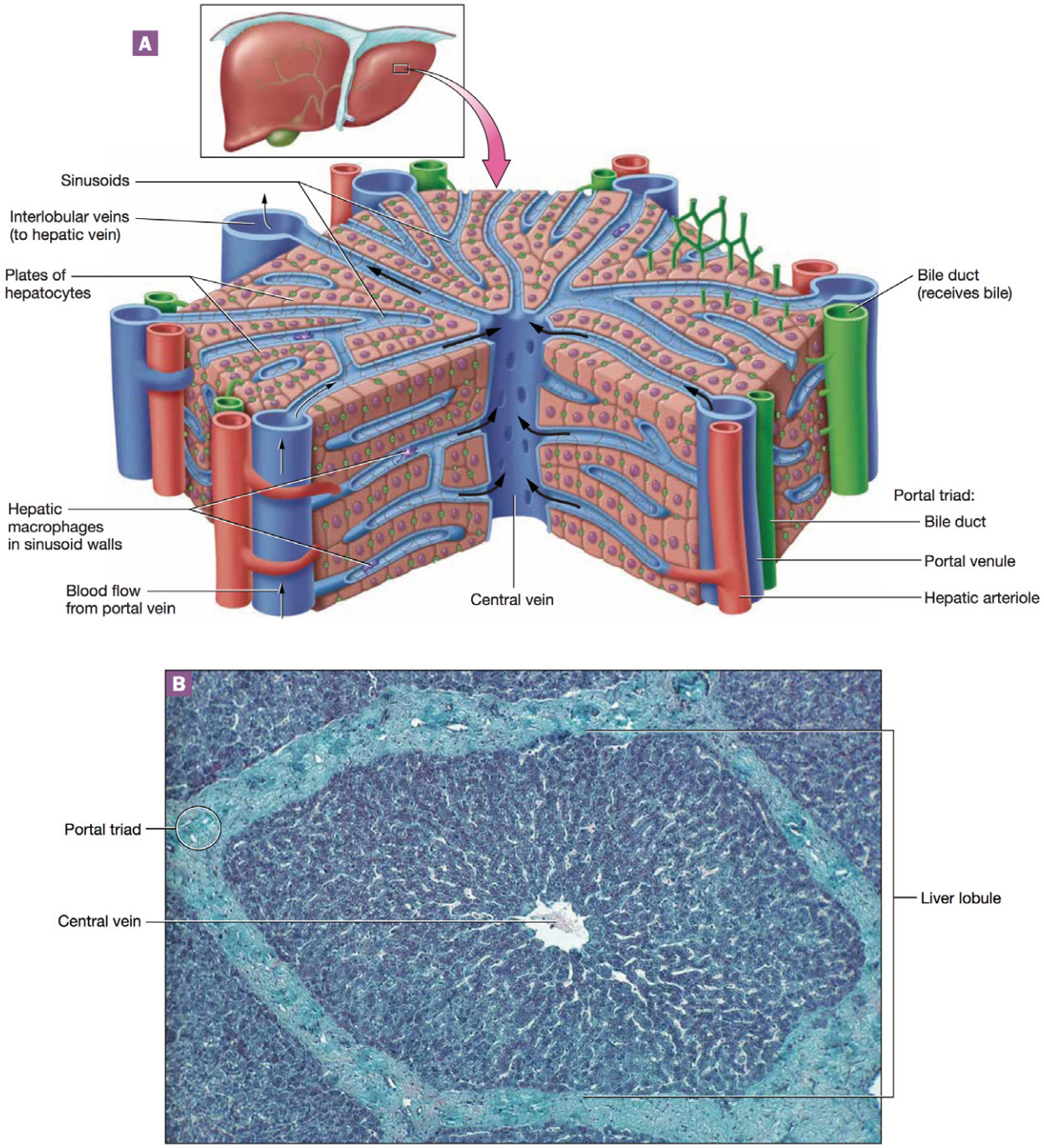

FIGURE **24.21** Microscopic structure of the liver: (A) liver lobule; (B) liver section from a pig, photomicrograph.

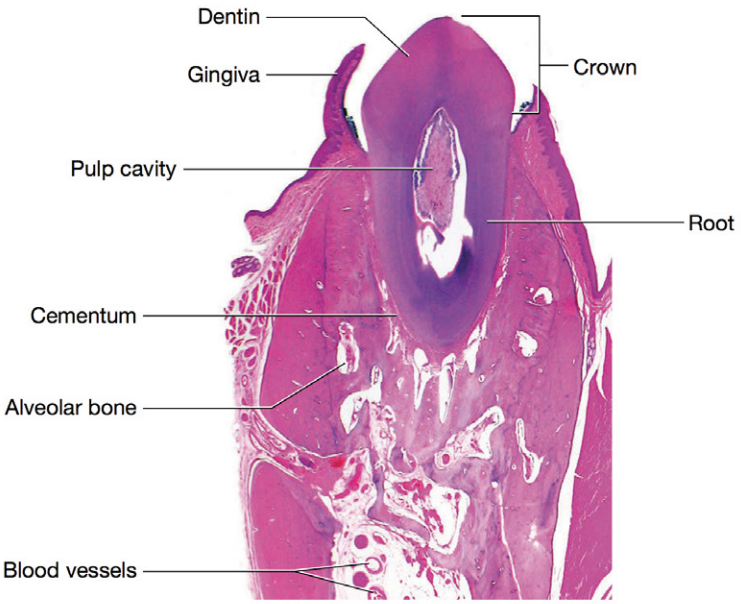

FIGURE **24.22** Microscopic structure of a human tooth.

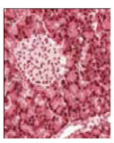

Procedure 1 Model Inventory for the Histologic Structures of the Digestive System

Identify on models and diagrams the following histologic structures of the digestive system, using your textbook and this unit for reference. As you examine the models and diagrams, record the name of the model and the structures you were able to identify on the model inventory in Table 24.2 (p. 639—note that this is the model inventory in Exercise 24-1).

1. Mucosa
   a. Epithelial tissue (simple columnar epithelium)
   b. Muscularis mucosae
   c. MALT
   d. Glands
2. Submucosa
   a. Blood vessels
   b. Nerves
   c. Lymphatic vessels
3. Muscularis externa
   a. Inner circular layer
   b. Outer longitudinal layer
   c. Inner oblique layer (stomach only)
4. Serosa or adventitia
5. Intestinal villi
   a. Enterocytes
   b. Lacteal
   c. Microvilli

Procedure 2 Microscopy of Digestive Organs

Obtain prepared slides of the esophagus, the fundus of the stomach, the duodenum, the pancreas, the liver, and a tooth. You will have the best results viewing most of the slides on low power. Use your colored pencils to draw what you see and label your drawing with the listed terms. When you have completed the activity, answer Check Your Understanding questions 4 and 5 (p. 662).

1 Esophagus

1. Stratified squamous epithelium
2. Submucosa with blood vessels
3. Muscularis externa
   a. Smooth muscle
   b. Skeletal muscle
4. Adventitia



2 Fundus of the stomach

1. Mucosa with goblet cells and gastric glands
2. Submucosa with blood vessels
3. Muscularis externa with smooth muscle layers
4. Serosa



3 Duodenum

1. Villi
2. Mucosal-associated lymphatic tissue
3. Enterocytes
4. Microvilli (visible as small "hairs" projecting from the cells); may only be visible on oil immersion
5. Duodenal glands



4 Pancreas

1. Acinar cells
2. Pancreatic ducts
3. Pancreatic islets



2 Liver

1. Liver lobule
2. Portal triad
3. Central vein



6 Tooth (best viewed on low power)

1. Crown
2. Root
3. Gingiva
4. Dentin
5. Pulp cavity
6. Cementum



Exercise 24-3

Digestion

MATERIALS

- ❑ 15 glass test tubes
- ❑ Test tube rack
- ❑ Glass stirring rods
- ❑ Rubber stopper
- ❑ Liquid detergent
- ❑ Distilled water
- ❑ Vegetable oil
- ❑ Sudan red stain
- ❑ Graduated cylinders
- ❑ Starch solution
- ❑ Amylase enzyme
- ❑ Water bath set to 37°C
- ❑ Boiling water bath
- ❑ Lugol's iodine solution
- ❑ Benedict's reagent
- ❑ 0.1 M Sodium hydroxide
- ❑ Bile
- ❑ Lipase
- ❑ Phenol red
- ❑ Egg white
- ❑ Pepsinogen in KCl buffer
- ❑ 0.5 M Hydrochloric acid
- ❑ Biuret reagent
- ❑ Sharpie

We now turn our attention to the physiology of food breakdown and absorption. Three major types of nutrients are broken down and absorbed in the alimentary canal: *carbohydrates*, *proteins*, and *lipids*. Carbohydrate digestion begins in the mouth with the enzyme **salivary amylase** (AM-uh-layz), which catalyzes the reactions that digest polysaccharides into smaller oligosaccharides. The remaining polysaccharides and oligosaccharides are digested in the small intestine. These reactions are catalyzed by *pancreatic amylase* and enzymes associated with the enterocytes of the small intestine called **brush border enzymes** (including lactase, maltase, and sucrase).

Protein digestion begins in the stomach with the enzyme **pepsin**, secreted by chief cells in the gastric glands as the inactive pre-enzyme **pepsinogen**. Pepsinogen becomes the active enzyme pepsin when it encounters an acidic environment. Pepsin begins digesting proteins into polypeptides and some free amino acids. The remainder of protein digestion occurs in the small intestine with pancreatic enzymes, such as *trypsin* and *chymotrypsin*, and also brush border enzymes, such as *carboxypeptidase* and *aminopeptidase*.

Most lipid digestion begins when lipids reach the small intestine. The process is more complicated than it is for protein or carbohydrate digestion because lipids are nonpolar molecules that do not dissolve in the water-based environment of the small intestine. This causes the lipids to clump together and form fat "globules" in the small intestine. In this form, it is extremely difficult for the enzyme **pancreatic lipase** (LY-payz) to catalyze the breakdown of lipids into monoglycerides and free fatty acids because it has only a small surface area on which to work. Therefore, the first step in lipid digestion is to break up fat globules into smaller pieces, a process called **emulsification** (Fig. 24.23).

Emulsification is accomplished by chemicals called **bile salts**, produced by the liver and stored in the gallbladder. Bile salts are amphipathic

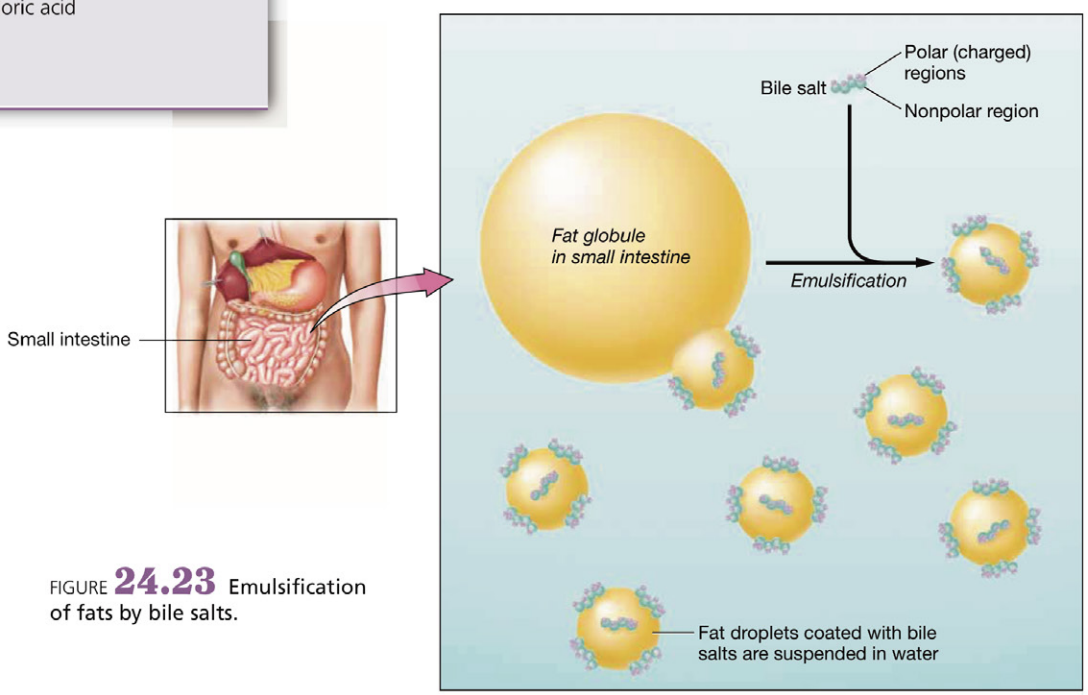

FIGURE **24.23** Emulsification of fats by bile salts.

molecules that have both nonpolar and polar parts. Notice in Figure 24.23 what happens to a fat globule when bile salts come into contact with it: The bile salts' nonpolar parts interact with the lipids, but their polar parts repel other lipids. The overall effect is that the fat globule is physically broken down into smaller fat pieces. This gives pancreatic lipase much more surface area on which to work, and the fats are digested into monoglycerides and free fatty acids.

When chemical digestion is complete, all three nutrients are absorbed through the plasma membranes of the enterocytes lining the intestinal villi. Both monosaccharides and amino acids are absorbed into the enterocytes via facilitated diffusion or secondary active transport mechanisms. These nutrients then exit the other side of the enterocytes and enter the capillaries in the core of the villus. Remember from Exercise 24-1 (p. 629) that all blood from the small intestine and other abdominal organs is delivered to the hepatic portal system before being delivered to the general circulation. Therefore, both monosaccharides and amino acids travel first to the liver via the hepatic portal vein, after which they enter the blood in the hepatic veins to be delivered to the inferior vena cava.

Lipid absorption, like lipid digestion, is more complicated because lipids are nonpolar and cannot be transported as free fatty acids through the water-filled plasma of the blood. In the small intestinal lumen, digested lipids remain associated with bile salts to form clusters of lipids and other nonpolar chemicals called **micelles** (my-SELLZ). Micelles escort the lipids to the enterocytes' plasma membranes; they are able to do so because of their polar outer surface, which allows them to move freely between the enterocytes' microvilli. The lipids then leave the micelles and enter the enterocytes by simple diffusion. Note that in the absence of bile salts, nearly all of the lipids will simply pass through the small intestine unabsorbed and be excreted in the feces.

In the enterocytes, lipids associate with other nonpolar substances and proteins to form protein-coated droplets called **chylomicrons** (ky-loh-MY-kronz). Chylomicrons exit the enterocytes into the core of the villus by exocytosis, but they are too large to enter blood capillaries. Instead, they enter the lacteal and join the lymph in the lymphatic system. For this reason, lipids are not delivered to the hepatic portal system like carbohydrates and amino acids. Chylomicrons travel within the lymphatic vessels until they enter the blood at the junction of the left subclavian vein and the left internal jugular vein.

In this exercise you will be examining the processes of chemical digestion using many of the enzymes we just discussed. You will also examine how various factors affect the efficiency of chemical digestion. When you have completed the procedures, answer Check Your Understanding question 6 (p. 662).

Procedure 1 Test Carbohydrate Digestion

In the following procedure you will test for carbohydrate digestion using a starch solution and the enzyme amylase. You will check for digestion using two reagents: Lugol's iodine, which turns dark blue in the presence of starch, and Benedict's reagent, which forms a precipitate (solid) in the presence of simple sugars. You may interpret the results of your tests as follows:

- If the solution turns dark blue with Lugol's iodine, *no or limited* carbohydrate digestion occurred because starch is still present (Fig. 24.24).
- If the solution develops a greenish-brownish red precipitate with Benedict's reagent, monosaccharides are present and carbohydrate digestion *did* occur (Fig. 24.25).

Safety Note

Safety glasses and gloves are required!

1. Obtain six glass test tubes and number them 1 through 6 with a Sharpie.
2. Place 3 mL of starch solution into tube 1 and tube 2.
3. Add 3 mL of amylase to tube 1.
4. Add 3 mL of distilled water to tube 2.
5. Set tubes 1 and 2 into a 37°C water bath and leave them in there for 30 minutes.

Reagent	Negative Reaction	Positive Reaction
Lugol's iodine		

FIGURE **24.24** Positive results for Lugol's iodine, which turns dark purple in the presence of starch.

6 Remove the tubes from the water bath and mix the contents of each tube thoroughly with stirring rods (be certain to use two separate rods so you don't contaminate the contents of the tubes).

7 Divide the mixture in tube 1 equally into tubes 3 and 4 (each tube should contain about 3 mL of the mixture).

8 Divide the mixture in tube 2 equally into tubes 5 and 6 (each tube should contain about 3 mL of the mixture).

9 Add two drops of Lugol's iodine solution to tubes 3 and 5. Record the results in Table 24.3.

10 Add 10 drops of Benedict's reagent to tubes 4 and 6. Swirl the tubes gently to mix the contents.

11 Place tubes 4 and 6 into a boiling water bath for 3 minutes. *Use caution* to prevent the mixture from splattering and burning you or your classmates.



FIGURE **24.25** Possible results for Benedict's reagent, in which a light blue color indicates no monosaccharides are present and a greenish-red color indicates monosaccharides are present.

12 Remove the tubes from the boiling water, and record the results of the test in Table 24.3.

TABLE **24.3** Results of Carbohydrate Digestion Experiment

Tube	Reaction with Lugol's Iodine
Tube 3 (starch + amylase)	
Tube 5 (starch + water)	
Tube	**Reaction with Benedict's Reagent**
Tube 4 (starch + amylase)	
Tube 6 (starch + water)	

13 Interpret your results:

a In which tube(s) did carbohydrate digestion occur? How do you know?

b In which tube(s) did no carbohydrate digestion occur? How do you know?

c What conclusions can we draw?

Procedure 2 Test Protein Digestion

Next you will examine protein digestion with the enzyme pepsin. Recall that pepsin is produced by the chief cells as the inactive enzyme *pepsinogen*, and that pepsinogen requires certain conditions to become active. You will assess for protein digestion with the chemical Biuret reagent, which turns blue in the presence of undigested proteins and lavender-purple in the presence of amino acids (Fig. 24.26).

1. Obtain four test tubes and number them 1 through 4 with a Sharpie.
2. Add about 3 mL of egg white (or albumin) to each test tube.
3. Add 3 mL of pepsinogen in 0.1 M NaOH (pH about 8) to tube 1.
4. Add 3 mL of pepsinogen in 0.5 M hydrochloric acid (pH about 2–3) to tube 2.
5. Add 3 mL of 0.1 M NaOH to tube 3.
6. Add 3 mL of 0.5 M hydrochloric acid to tube 4.
7. Place each tube in a 37°C water bath for one hour.
8. Remove the tubes and add 5 drops of Biuret reagent to each tube. Record the color change that you observe in each tube in Table 24.4.

Safety Note

Safety glasses and gloves are required!



FIGURE **24.26** Possible results with Biuret's test: light blue indicates no protein digestion, while light purple indicates amino acids are present.

TABLE **24.4** Results of Protein Digestion Experiment

Tube	Color of Mixture after Adding Biuret Reagent
Tube 1 (egg white + pepsinogen + NaOH)	
Tube 2 (egg white + pepsinogen + HCl)	
Tube 3 (egg white + NaOH)	
Tube 4 (egg white + HCl)	

9 Interpret your results:

a In which tube(s) did protein digestion occur? How do you know?

b In which tube(s) did no protein digestion occur? How do you know?

c What effect does pH have on protein digestion with pepsin? Why?

d What other effects does acid have in the stomach?

Procedure 3 Demonstrate Lipid Emulsification

Let's examine what happens during the process of emulsification. In this exercise you will use four substances to observe emulsification in action:

- *Lipids*: The source of lipids for this exercise is vegetable oil.
- *Emulsifying agent*: Detergents are considered to be emulsifiers because they have both polar parts and nonpolar parts, similar to bile salts. The emulsifying agent in this exercise will be a liquid detergent.
- *Distilled water.*
- *Sudan red stain*: This is a stain that binds only to lipids. The sole purpose of this stain is to make the lipids more visible during the procedure.

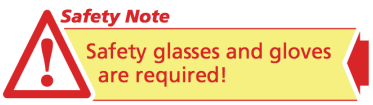

1 Obtain a glass test tube and add approximately 2 mL of distilled water to it.

2 Add about 2 mL of vegetable oil to the water.

3 Place a rubber stopper into the tube and shake it vigorously for 15 seconds. Allow it to stand for 2 minutes. What happens to the oil and water?

4 Add three or four drops of Sudan red stain, and shake the tube again for 15 seconds. What color is the oil? What color is the water?

5 Add about 1 mL of liquid detergent to the mixture and shake the tube vigorously for 15 seconds. Allow the tube to stand for 2 minutes. What has happened to the solution? Is it still two distinct colors? Explain your results.

Procedure 4 Test Lipid Digestion

In the following procedure you will be comparing the ability of four solutions to digest vegetable oil: lipase and bile, lipase alone, bile alone, and water. You will check for the presence of digestion using an indicator called **phenol red.** Phenol red appears pink at an alkaline (basic) pH, changes to an orange-red color at a neutral pH, and changes to a yellow color when the pH becomes acidic (Fig. 24.27). If fat digestion has occurred, fatty acids will be released that will decrease the pH of the contents of your tube and turn them orange-red or yellow. You may interpret your results in the following way:

Pink color = the pH is basic and no (or limited) fat digestion occurred
Red-orange color = the pH is neutral and some fat digestion occurred
Yellow color = the pH is acidic and significant fat digestion occurred

Safety Note
Safety glasses and gloves are required!

1. Obtain four glass test tubes and number them 1 through 4 with a Sharpie.
2. Add 3 mL of vegetable oil to each test tube.
3. Add 8–10 drops of the pH indicator phenol red to each test tube. The oil now should appear pink. If it does not appear pink, add drops of 0.1 M NaOH to each tube until the indicator turns pink.
4. Add 1 mL of lipase and 1 mL of bile to tube 1.
5. Add 1 mL of lipase to tube 2.
6. Add 1 mL of bile to tube 3.
7. Add 1 mL of distilled water to tube 4.
8. Place each tube in a 37°C water bath for 30 minutes.
9. Remove the tubes from the water bath and record the color of each tube in Table 24.5.
10. Interpret your results:
    - **a** In which tube(s) did lipid digestion occur? How do you know?



FIGURE **24.27** Possible results with phenol red test: pink indicates no/limited fat digestion, red-orange indicates some fat digestion, and yellow indicates significant fat digestion.

TABLE **24.5** Results of Lipid Digestion Experiment

Tube	Color	pH (acidic, neutral, or alkaline)
Tube 1 (oil + lipase + bile)		
Tube 2 (oil + lipase)		
Tube 3 (oil + bile)		
Tube 4 (oil + water)		

    - **b** In which tube(s) did limited or no lipid digestion occur? How do you know?
    - **c** What effect does bile have on lipid digestion? Why?

Exercise 24-4

Time to Trace!

MATERIALS

- ❑ Laminated outline of the human body
- ❑ Water-soluble marking pens

Now it's time to put all of the digestive anatomy and physiology together to get a "big picture" view of the digestive system. In this exercise you will trace the pathway that three different nutrients take from their ingestion at the mouth to their arrival at the heart. You will trace a cookie (primarily carbohydrates), an egg (primarily protein), and greasy fried food (primarily lipids).

Along the way, detail the following for each:

1. The *anatomical pathway* that each takes, from ingestion, through its passage through the alimentary canal, to its absorption into the blood, and finally to its passage through the blood until it reaches the heart.
2. The *physical* and *chemical processes* that break down each substance, including enzyme-catalyzed chemical digestion and processes of mechanical digestion, such as churning, chewing, and emulsification.

Some hints:

- Don't forget that carbohydrates and amino acids travel through the hepatic portal system before they enter the general circulation.
- Remember that digestion and absorption are quite different for lipids. For example, fats are not absorbed into the intestinal blood capillaries.
- Use the text in Exercise 24-3 (p. 649) and your list of enzymes that you completed in Pre-Lab Exercise 24-3 (p. 628) for reference.
- Refer to the tracing exercises from Unit 18 (p. 486) and Unit 21 (p. 553) to review the pathway of blood and lymph flow through the body.
- You may find it helpful to physically trace the pathway on a laminated outline of the human body to better visualize the processes.

Tracing Steps

1 Cookie: **Start:** mouth ➜ _____

_____

_____

_____

_____

_____

_____

_____

_____

_____

_____ ➜ heart **End**

2 Egg: **Start:** mouth ➜ _____

_____

_____

_____

_____

_____

_____

_____

_____

_____

_____ ➜ heart **End**

3 Greasy fried food: **Start:** mouth ➜ _____

_____

_____

_____

_____

_____

_____

_____

_____

_____

_____ ➜ heart **End**

24

Name _____

Section _____ Date _____

UNIT 24 REVIEW

Check Your Recall

1 Label the following structures on Figure 24.28.

- ❑ Cecum
- ❑ Esophagus
- ❑ Gallbladder
- ❑ Greater omentum
- ❑ Lesser omentum
- ❑ Liver
- ❑ Mesentery
- ❑ Parotid gland
- ❑ Rectum
- ❑ Sigmoid colon
- ❑ Sublingual gland
- ❑ Submandibular gland
- ❑ Transverse colon
- ❑ Vermiform appendix

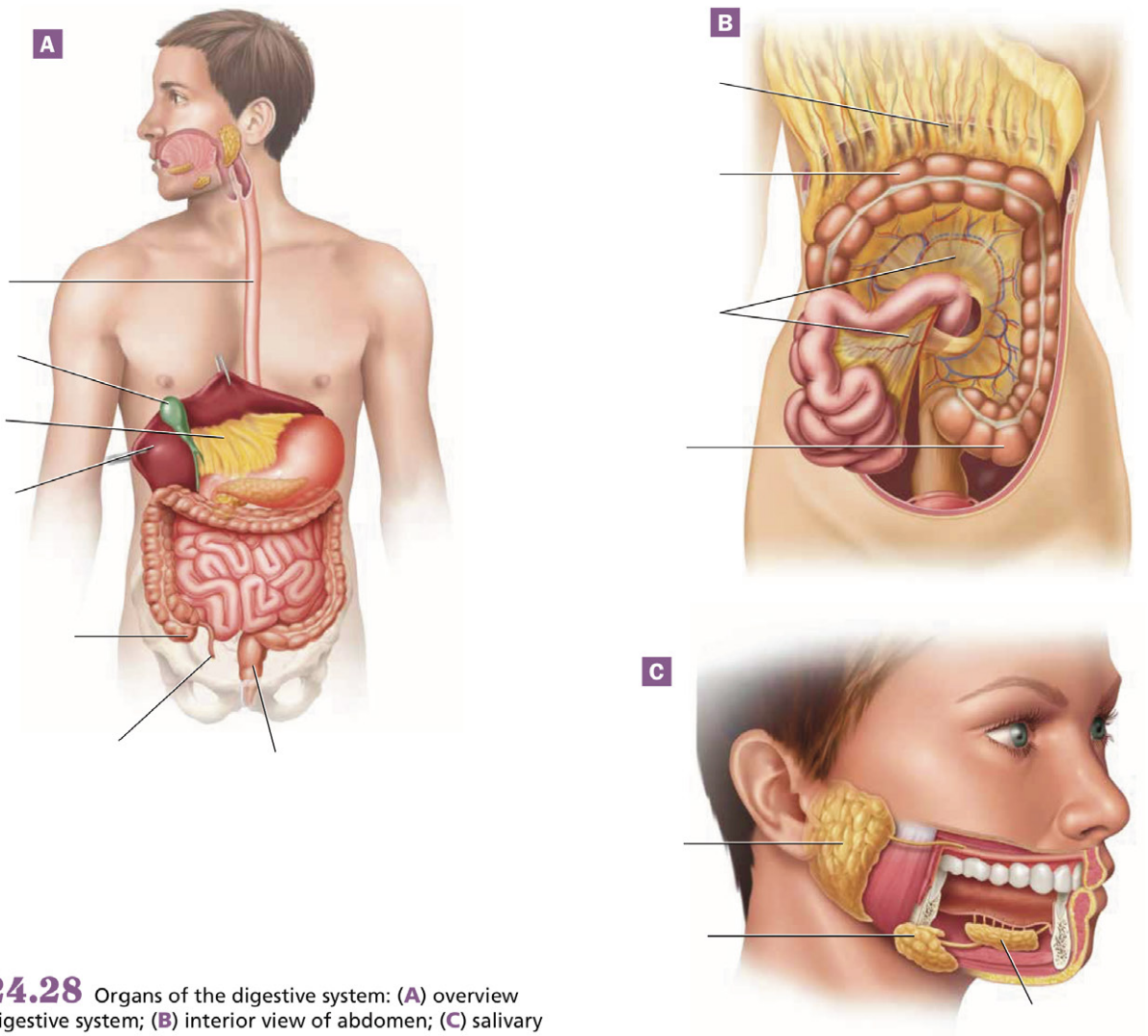

FIGURE **24.28** Organs of the digestive system: (**A**) overview of the digestive system; (**B**) interior view of abdomen; (**C**) salivary glands.

2 Label the following structures on Figure 24.29.

- ❑ Body
- ❑ Cardia
- ❑ Circular muscle layer
- ❑ Duodenum
- ❑ Fundus
- ❑ Gastroesophageal sphincter
- ❑ Pyloric sphincter
- ❑ Pylorus
- ❑ Rugae

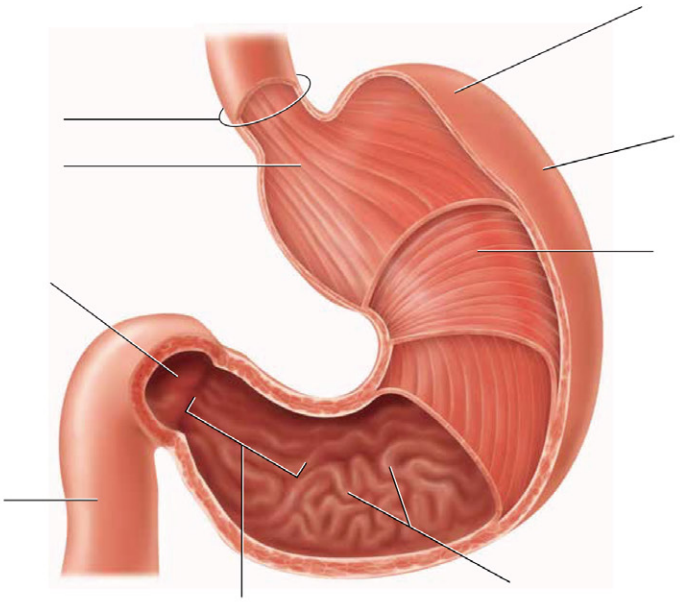

FIGURE **24.29** Anatomy of the stomach.

3 Which of the following organs is not an accessory organ of digestion?

a. Salivary glands.
b. Gallbladder.
c. Cecum.
d. Pancreas.

4 *True/False:* Mark the following statements as true (T) or false (F). If the statement is false, correct it so it becomes a true statement.

_____ a. The peritoneal cavity is located between the visceral peritoneum and the mesentery.

_____ b. The shortest segment of the small intestine is the duodenum.

_____ c. Filiform papillae are keratinized projections from the tongue that help physically break down food.

_____ d. Pancreatic islets are the exocrine portion of the pancreas.

_____ e. The ileocecal valve regulates flow from the stomach to the duodenum.

_____ f. The vermiform appendix is a blind-ended sac that contains lymphoid follicles.

5 *Fill in the blanks:* Bile is produced by the _____ and stored and concentrated in the _____.

Name _____

Section _____ Date _____

6 Label the following structures on Figure 24.30.

- ❑ Caudate lobe of liver
- ❑ Common bile duct
- ❑ Common hepatic duct
- ❑ Cystic duct
- ❑ Falciform ligament
- ❑ Gallbladder
- ❑ Hepatopancreatic ampulla
- ❑ Left lobe of liver
- ❑ Pancreas
- ❑ Pancreatic duct
- ❑ Porta hepatis
- ❑ Right lobe of liver
- ❑ Round ligament

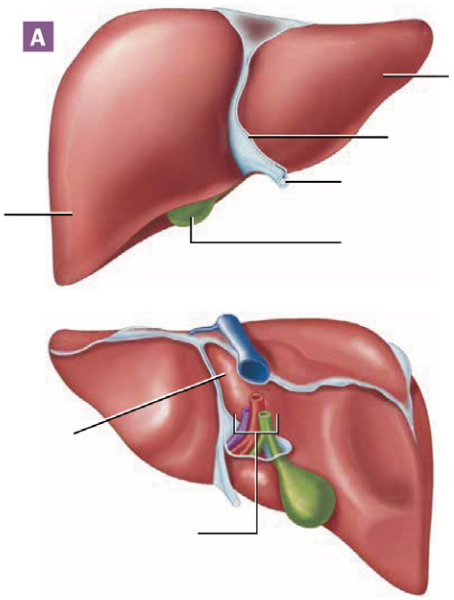

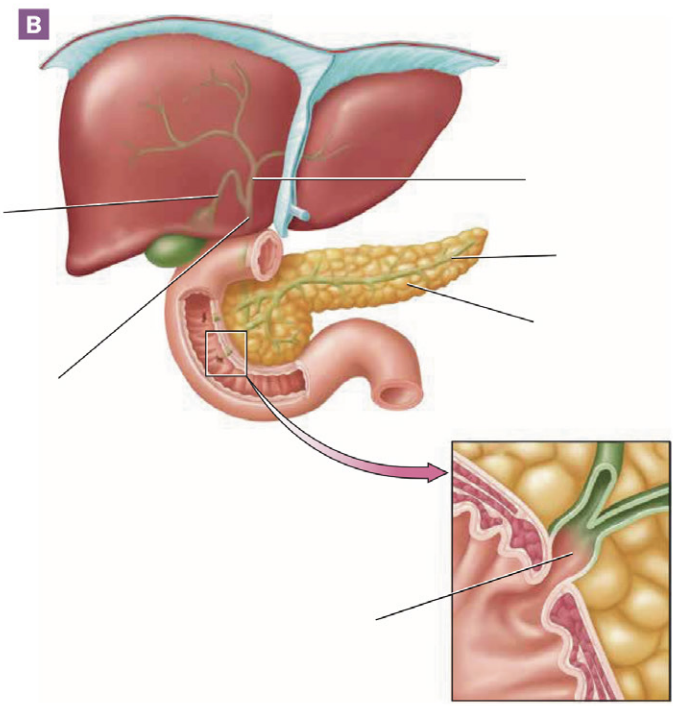

FIGURE **24.30** Accessory organs of the digestive system: (**A**) anterior and posterior views of the liver; (**B**) liver and associated accessory organs.

7 Label the following structures on Figure 24.31.

- ❑ Circular layer of smooth muscle
- ❑ Longitudinal layer of smooth muscle
- ❑ Lumen
- ❑ Mucosa
- ❑ Muscularis mucosae
- ❑ Serosa
- ❑ Submucosa

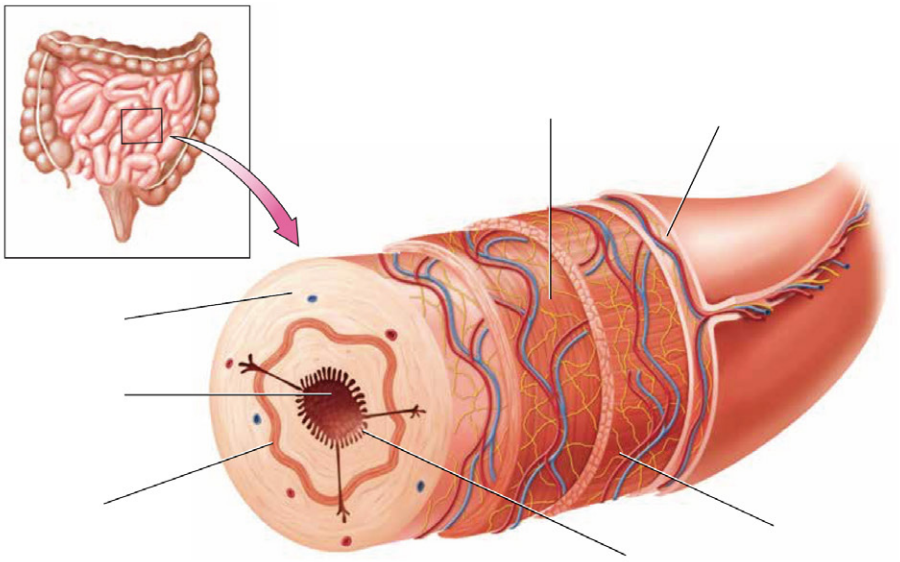

FIGURE **24.31** Tissue layers of the alimentary canal.

8 *Matching:* Match the following with the correct definition.

_____ Salivary amylase

_____ Bile salts

_____ Micelles

_____ Pepsin

_____ Chylomicrons

_____ Pancreatic lipase

_____ Hydrochloric acid

_____ Lacteal

A. Protein-coated lipid droplets that are absorbed
B. Protein-digesting enzyme(s) produced by the stomach
C. Emulsifies/emulsify fats
D. Clusters of bile salts and digested lipids in the small intestine
E. Required to activate pepsinogen
F. Begin(s) carbohydrate digestion in the mouth
G. Structure into which lipids are absorbed
H. Enzyme(s) that digest(s) lipids into free fatty acids and monoglycerides

9 Folds of the small intestinal mucosa are known as

a. microvilli.
b. circular folds.
c. intestinal crypts.
d. villi.

24

10 Explain the importance of emulsification in lipid digestion.

Name _____

Section _____ Date _____

Check Your Understanding

REVIEW

Critical Thinking and Application Questions

1 Eva has been diagnosed with *gallstones*, which are lumps of cholesterol and other components of bile. One of the gallstones is blocking her cystic duct, preventing the release of bile from the gallbladder.

a Will the gallstones prevent bile from being produced and released into the duodenum? Why or why not?

b Predict what might happen if a gallstone were to block Eva's pancreatic duct, preventing the release of pancreatic juice into the duodenum.

2 The condition known as *appendicitis* is an acute inflammation of the appendix, usually due to bacterial infection. What anatomical or histological feature does the appendix contain that makes it at risk for this type of condition? How does its location and shape complicate this? Explain.

3 If the ileocecal valve fails to close properly, the contents of the cecum can reflux back into the ileum. Why might this cause problems? (***Hint:*** What is found in the large intestine that is not normally found in the small intestine?)

4 If you go into your local grocery store, you are bound to find a host of gluten-free products made with synthetic proteins instead of the natural wheat-based protein gluten. About 1 to 3 percent of the population is sensitive to gluten. The most severe form of gluten intolerance is the autoimmune disease *celiac disease* (note that it is not caused by gluten, and you cannot get it from eating gluten). In individuals with celiac disease, the immune response to gluten antigens causes the flattening of the villi in the small intestine. How would this affect the ability of the small intestine to function? Predict the symptoms you would expect to see from celiac disease.

5 Sadaf has an ulcer of her large intestine that has *perforated*, meaning that it has developed a hole that has gone through all tissue layers.

a Through which tissue layers would the ulcer have had to pass to perforate completely?

b A major concern with large intestine perforation is peritonitis, or infection of the peritoneal fluid. Why is this a particular concern with the large intestine?

c Why could peritonitis have wide-ranging effects on Sadaf's other organs of the abdomen and digestive system? Are there any organs that would be unlikely to be directly affected by peritonitis? Explain.

6 Many dietary supplements contain digestive enzymes the manufacturers claim are necessary to digest food properly. What will happen to these enzymes in the stomach? (***Hint:*** Enzymes are proteins.) Will the enzymes continue to function once they have reached the small intestine? Why or why not?

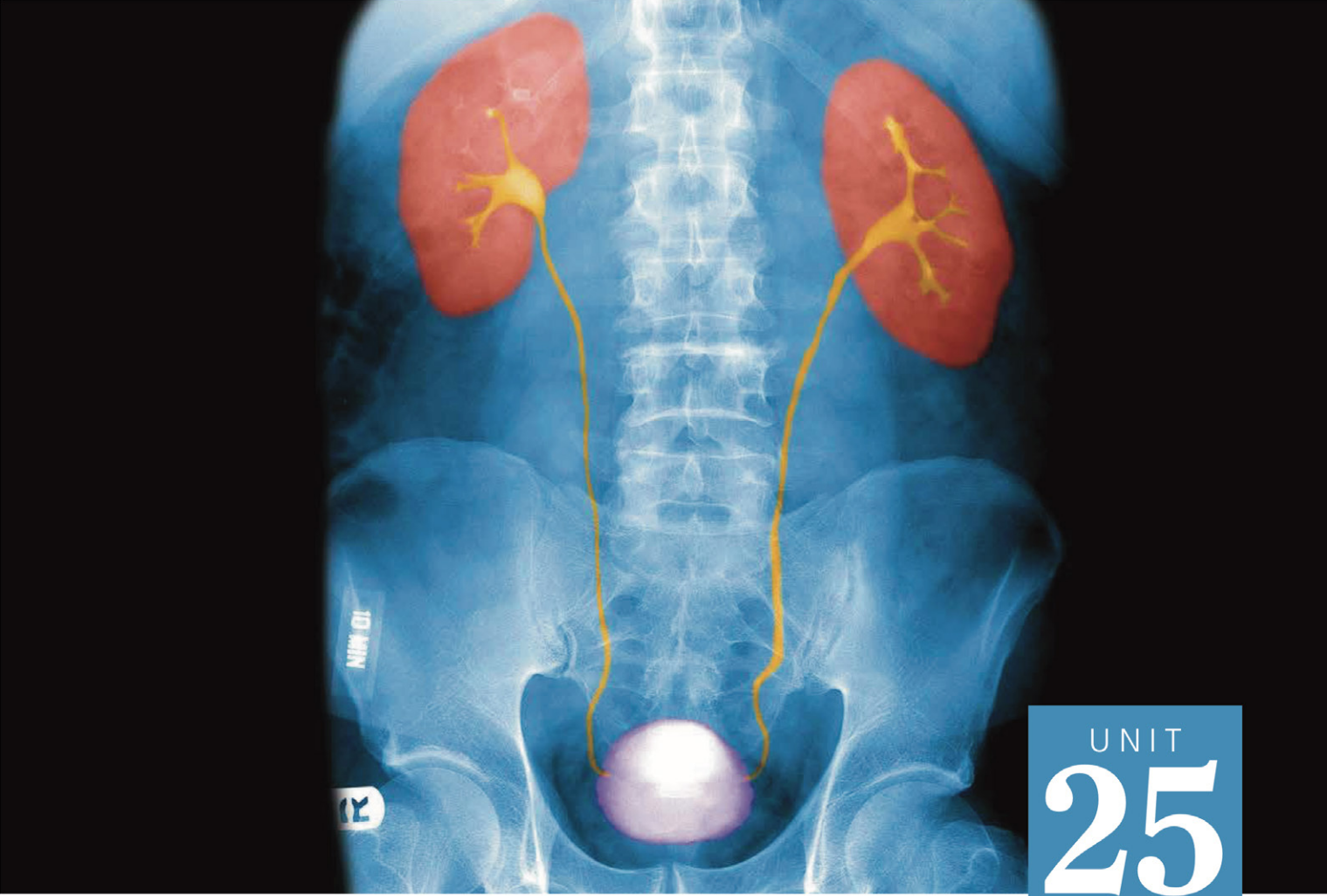

UNIT 25

Urinary System Anatomy

Once you have completed this unit, you should be able to:

1. Identify gross structures of the urinary system.
2. Identify structures of the nephron.
3. Identify the microscopic anatomy of the urinary system.

Name _____ Section _____ Date _____

PRE-LAB EXERCISES

Complete the following exercises prior to coming to lab, using this lab manual and your textbook for reference.

Pre-Lab Exercise 25-1



Key Terms

You should be familiar with the following terms before coming to lab.

Term	Definition

Gross Structures of the Kidney

Renal cortex _____

Renal medulla _____

Medullary pyramid _____

Renal column _____

Renal pelvis _____

Major and minor calyces _____

Other Structures of the Urinary System

Ureter _____

Urinary bladder _____

Urethra _____

25

Microanatomy of the Kidney

Nephron _____

Glomerulus _____

Name _____ Section _____ Date _____

Peritubular capillaries _____

Proximal tubule _____

Nephron loop _____

Distal tubule _____

Cortical collecting duct _____

Medullary collecting duct _____

Papillary duct _____

Pre-Lab Exercise 25-2

Structures of the Urinary System

Label and color the structures of the urinary system in Figures 25.1 and 25.2 with the terms from Exercise 25-1 (p. 669). Use your text and Exercise 25-1 in this unit for reference.

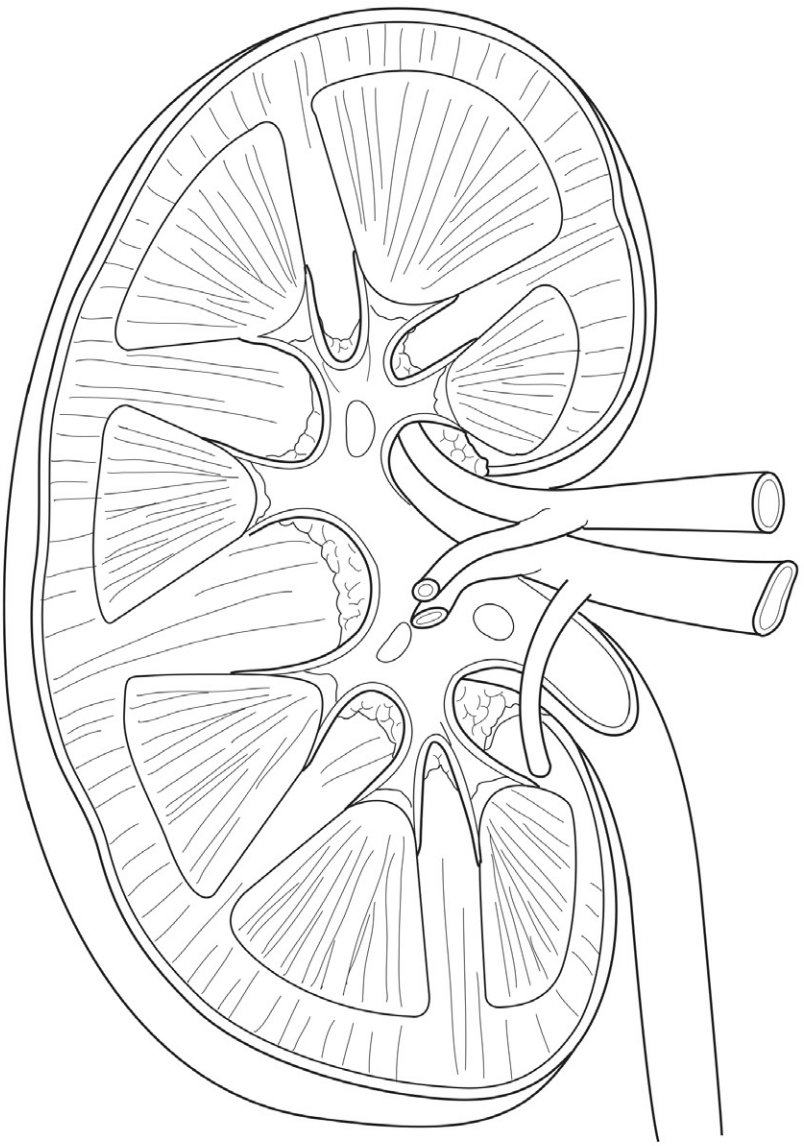

FIGURE **25.1** Right kidney, frontal section.

Name _____ Section _____ Date _____

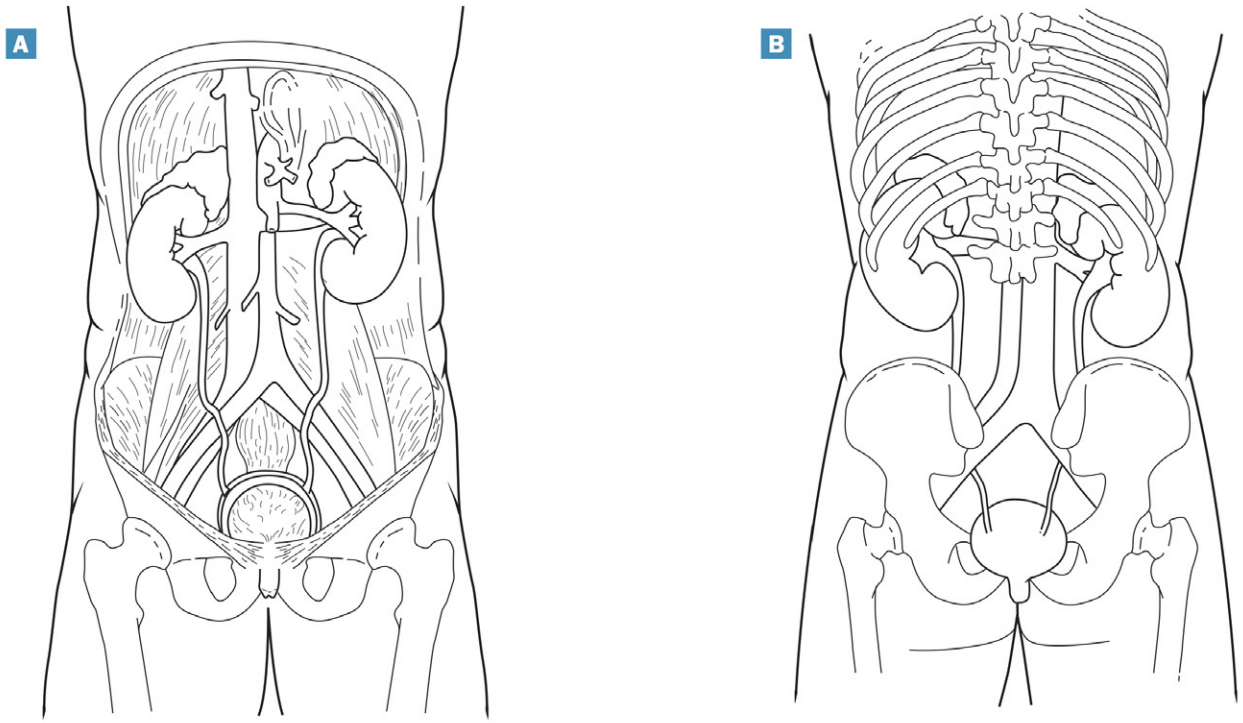

FIGURE **25.2** Organs of the urinary system: (**A**) anterior view; (**B**) posterior view.

Pre-Lab Exercise 25-3

Microanatomy of the Kidney

Label and color the microanatomy of the kidney in Figure 25.3 with the terms from Exercise 25-1 (p. 669). Use your text and Exercise 25-1 in this unit for reference.

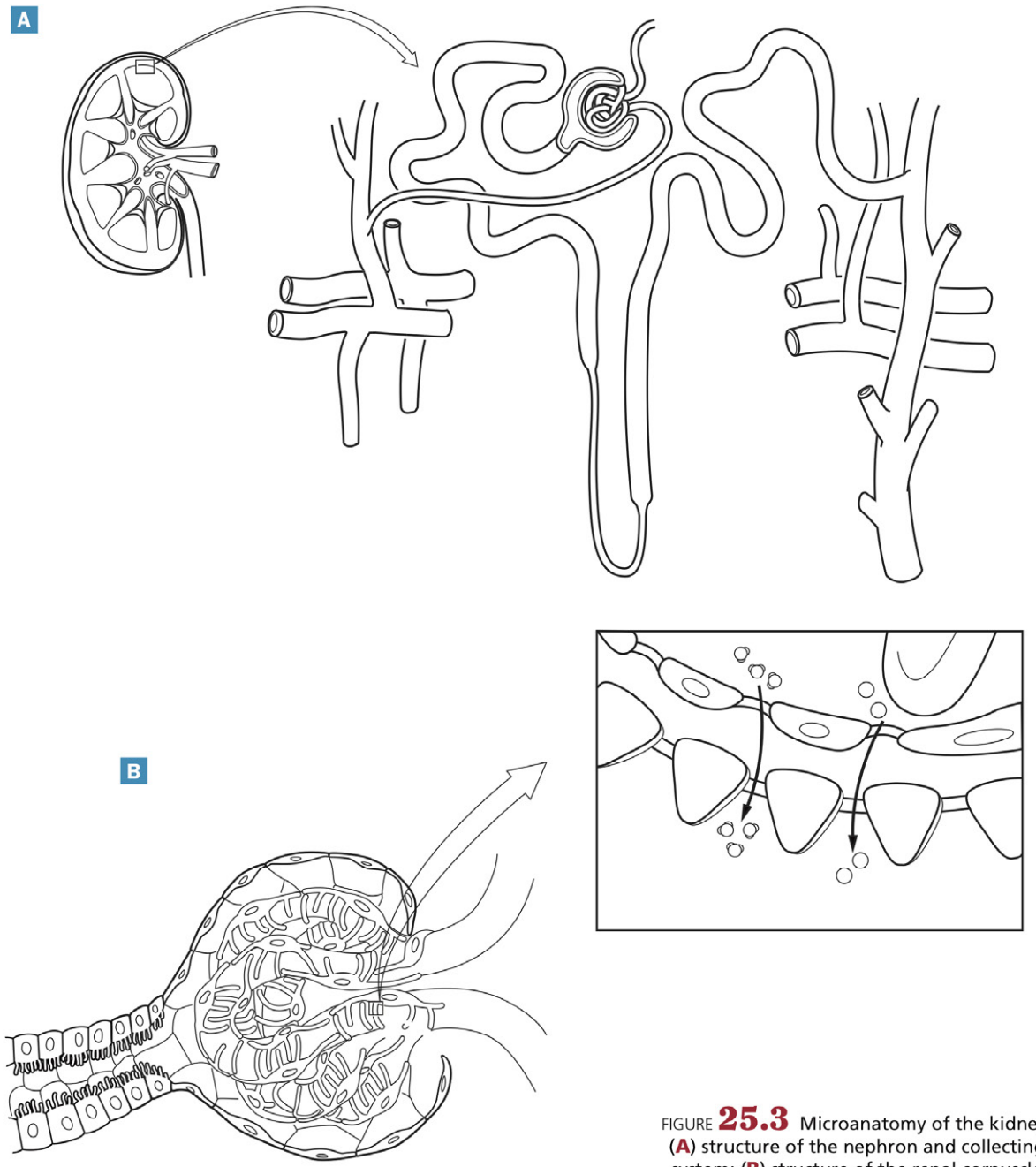

FIGURE **25.3** Microanatomy of the kidney: (**A**) structure of the nephron and collecting system; (**B**) structure of the renal corpuscle and filtration.

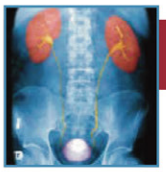

Color enhanced X-ray from an intravenous pyelogram.

EXERCISES

The **urinary system** is the group of organs that consists of the *kidneys* and the *urinary tract*—the *ureters*, *urinary bladder*, and *urethra*—and performs many functions critical to the maintenance of homeostasis. Most such functions are directly performed by the kidneys. For example, the kidneys filter the blood to remove *metabolic wastes*, which are chemicals produced by the body that the body cannot use for any purpose. The kidneys also regulate the body's fluid, electrolyte, and acid-base balance, as they can conserve or excrete water, specific electrolytes, and bicarbonate and hydrogen ions. Finally, the kidneys help the liver detoxify certain compounds, make glucose during times of starvation, and produce the hormone *erythropoietin*, which regulates blood cell formation.

In this unit you will become acquainted with the anatomy, histology, and basic physiology of the organs of the urinary system. In the next unit, we apply this anatomy to explore the physiology of the urinary system in greater depth.

Exercise 25-1

Urinary System Anatomy

MATERIALS

- ❑ Urinary system models
- ❑ Kidney models
- ❑ Nephron models
- ❑ Preserved kidney
- ❑ Dissection equipment
- ❑ Dissecting tray
- ❑ Colored pencils

The paired **kidneys** are situated against the posterior body wall posterior to the peritoneal membranes, meaning they are *retroperitoneal* (Fig. 25.4). Externally, they are encased within three layers of connective tissue: the superficial **renal fascia** (REE-nuhl), a layer of dense irregular collagenous connective tissue that anchors the kidneys to the posterior abdominal wall and the peritoneum; the **adipose capsule**, a thick layer of adipose tissue that wedges the kidneys in place; and the **renal capsule**, a very thin layer of dense irregular collagenous connective tissue that encases each kidney like plastic wrap. With the layers of connective tissue removed, the kidneys are bean-shaped and have a medial indentation where blood vessels and the ureter enter and exit, which is known as the **hilum** (HY-lum).

Internally, each kidney has three distinct regions that can be seen in a frontal section (Fig. 25.5):

1. **Renal cortex.** The most superficial region is known as the **renal cortex.** It is dark brown because it consists of many blood vessels that serve the tiny blood-filtering structures of the kidney, the **nephrons.**

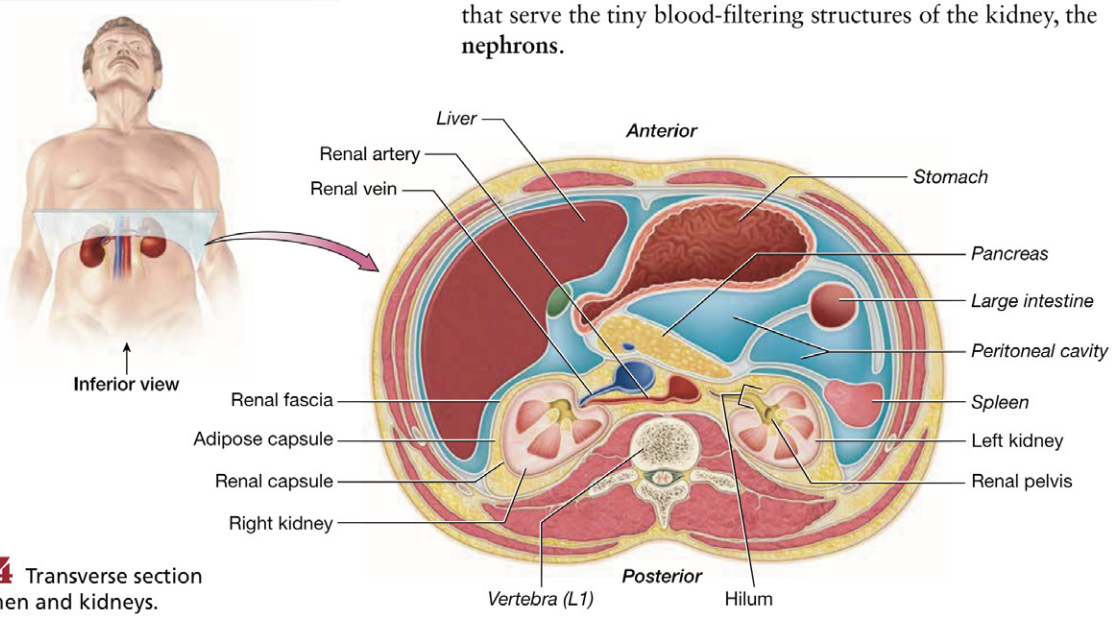

FIGURE **25.4** Transverse section of the abdomen and kidneys.

2. **Renal medulla.** The kidney's middle region is the **renal medulla**, which consists of triangular **renal pyramids.** The renal pyramids are separated from one another by inward extensions of the renal cortex called **renal columns.** Like the renal cortex, the renal columns contain many blood vessels. Each pyramid contains looping tubules of nephrons as well as structures that drain fluid from nephrons. These tubes give the pyramids a striped (or *striated*) appearance. The end or tip of a renal pyramid is known as a **renal papilla.**

3. **Renal pelvis.** Fluid from the renal papilla drains into tubes called **minor calyces** (KAY-lih-seez) that in turn drain into even larger **major calyces.** The major calyces drain into the kidney's innermost region, the **renal pelvis,** which serves as a basin for collecting urine.

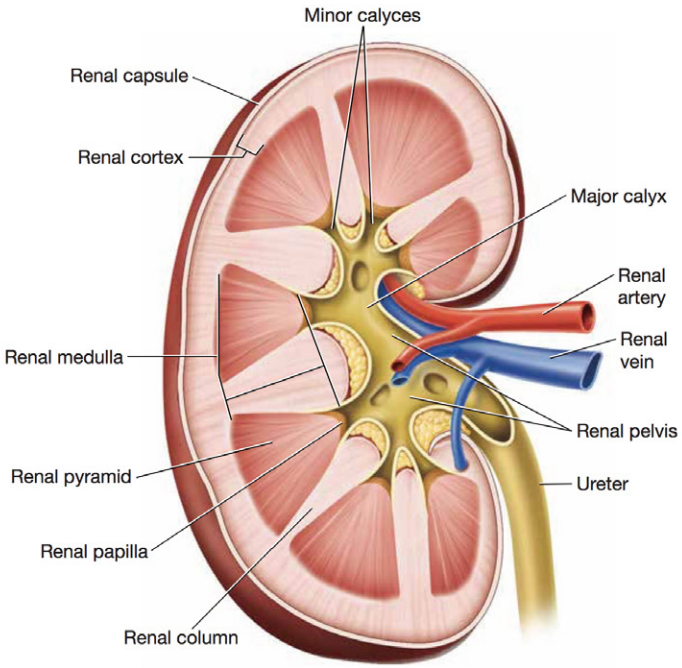

FIGURE **25.5** Right kidney, frontal section.

The blood flow through the kidney follows a unique pattern that allows it to carry out its function of maintaining the homeostasis of the blood. The large **renal arteries** deliver about 1,200 milliliters of blood per minute to the kidney to be filtered (Fig. 25.6). The renal arteries branch into progressively smaller arteries as they pass through the medulla to the cortex, including the **segmental arteries** in the renal pelvis, the **interlobar arteries** between the medullary pyramids, the **arcuate arteries** (ARK-yoo-it) that curve around the top of the pyramids, and, finally, the small **interlobular arteries** (also known as *cortical radiate arteries*) in the renal cortex. The interlobular arteries branch into tiny **afferent arterioles,** each of which supplies a ball of capillaries known as the **glomerulus** (gloh-MEHR-yoo-luhs). This is where the blood is filtered. Note that the glomerulus is not the primary site for gas and nutrient exchange for the tissues of the kidneys.

You learned in Unit 18 (p. 469) that a capillary bed generally drains into a venule, but notice in Figure 25.6B that the capillaries of the glomerulus drain into a second *arteriole* called the **efferent arteriole.** The efferent arteriole then branches to form a second capillary bed known as the **peritubular capillaries.** These capillaries surround the tubules of the nephron, where they provide them with oxygen and nutrients and also take substances reabsorbed by the tubules back into the blood. The peritubular capillaries then drain out through the small **interlobular veins,** which drain into **arcuate veins,** then into **interlobar veins** (also known as *cortical radiate veins*), and, finally, into the large **renal vein.** This pattern of blood flow allows the kidneys both to filter blood and to reclaim most of the fluid and solutes filtered.

Microscopically, each kidney is composed of more than a million tiny units called **nephrons** (NEF-rahnz). The nephron can be divided into two parts: the *renal corpuscle* and the *renal tubule.* The **renal corpuscle** itself consists of two parts: the glomerulus and the glomerular capsule (Fig. 25.7). As you've seen, the glomerulus is a ball of looping capillaries. The capillaries themselves are *fenestrated*, meaning that they have large slits or pores, which allows large volumes of fluid to rapidly exit them. The second portion of the renal corpuscle is the **glomerular capsule,** which has two layers: (1) the outer **parietal layer,** which is simple squamous epithelium; and (2) the inner **visceral layer,** which consists of cells called **podocytes** (POH-doh-syt'z) that surround the capillaries of the glomerulus. The space between the parietal and visceral layers is known as the **capsular space.** Fluid forced out of the glomerular capillaries enters this space; once in the capsular space, the fluid is called *filtrate.*

The podocytes of the visceral layer have extensions called **foot processes** that interlock to form narrow **filtration slits.** As you can see in Figure 25.7, the fenestrated glomerular endothelial cells, the podocytes, and their shared basal lamina together form a structure called the **filtration membrane.** The filtration membrane prevents large substances in the blood, such as blood cells and most proteins, from exiting the glomerular capillaries. However, water and small solutes such as electrolytes, glucose, amino acids, and urea easily cross the filtration membrane to enter the filtrate in the capsular space.

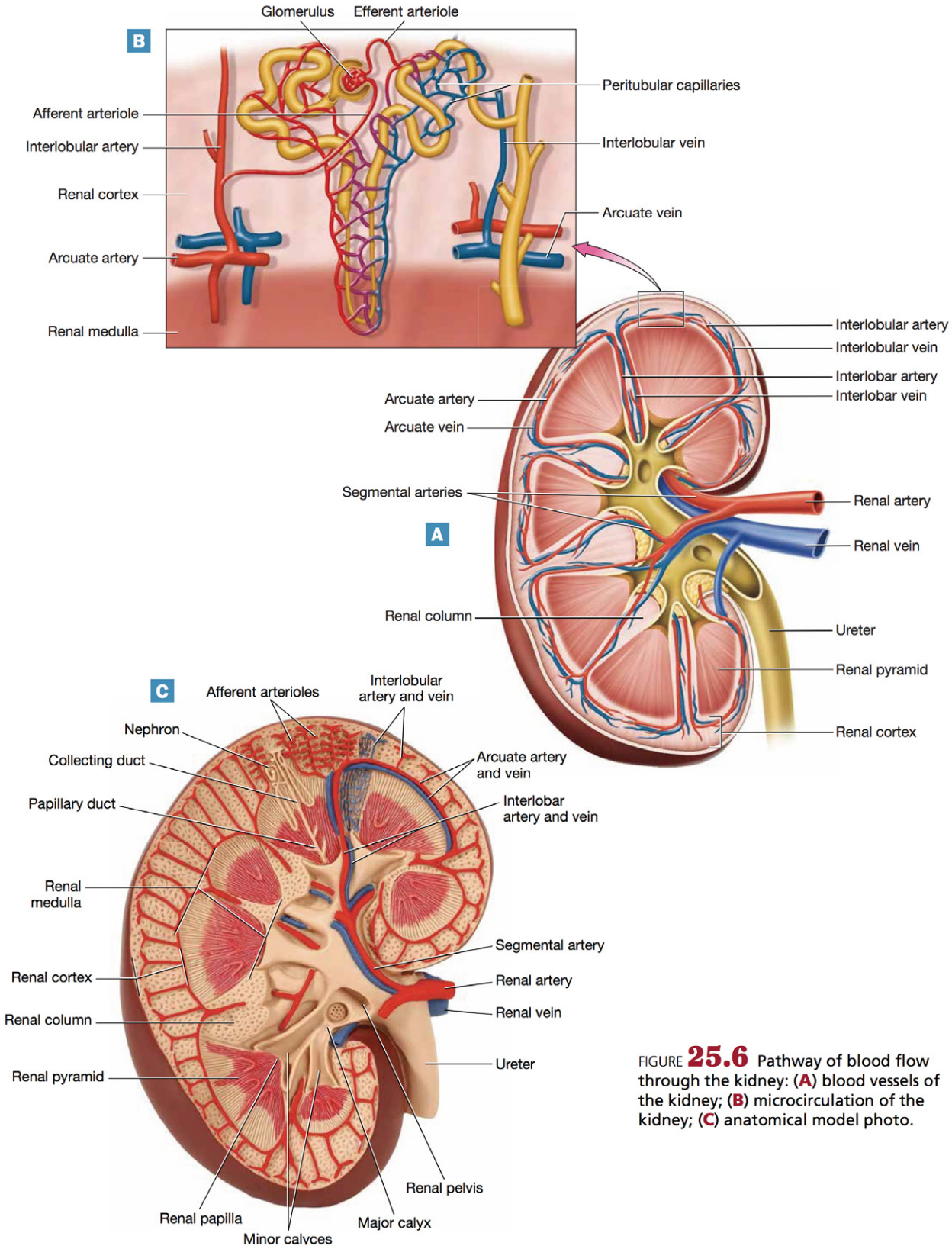

FIGURE **25.6** Pathway of blood flow through the kidney: (**A**) blood vessels of the kidney; (**B**) microcirculation of the kidney; (**C**) anatomical model photo.

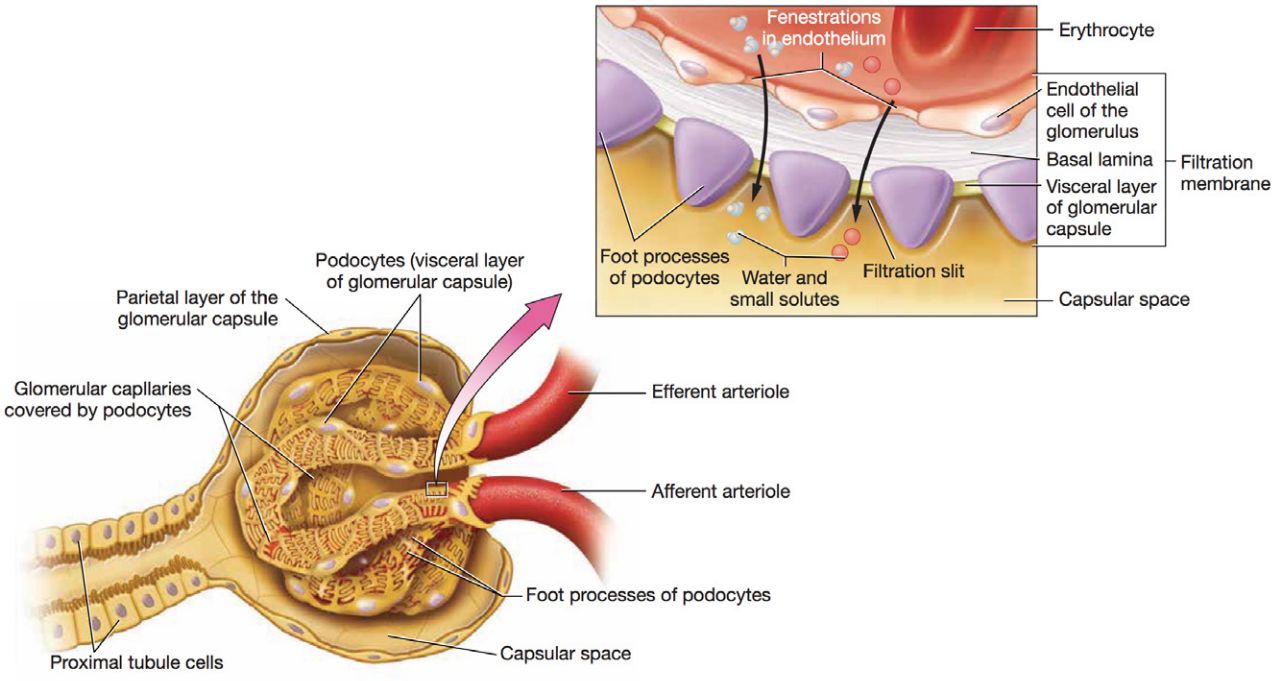

FIGURE **25.7** Structure of the renal corpuscle and filtration membrane.

From the capsular space, the filtrate next enters the **renal tubule**, which can be likened to the "plumbing" of the kidney. The renal tubule consists of three parts, shown in Figure 25.8: (1) the **proximal tubule** (sometimes called the *proximal convoluted tubule*), (2) the descending and ascending limbs of the **nephron loop**, and (3) the **distal tubule** (sometimes called the *distal convoluted tubule*). Note that the majority of the renal tubule is confined to the renal cortex; only the nephron loops of certain nephrons dip down into the renal medulla.

Several distal tubules drain into one **collecting duct**, which is part of a larger collecting system that is not part of the nephron. Collecting ducts in the renal cortex are **cortical collecting ducts**; those in the renal medulla are **medullary collecting ducts**. Near the renal papilla, medullary collecting ducts enlarge to form **papillary ducts**, which will empty into minor calyces.

At the junction between the ascending limb of the nephron loop and the distal tubule we find a group of tall, closely packed cells known as the **macula densa** (MAK-yoo-lah DEN-sah; Fig. 25.9). The macula densa comes into contact with a portion of the afferent arteriole that contains specialized cells called **juxtaglomerular** (jux-tah-gloh-MEHR-yoo-lur; **JG**) **cells**. The JG cells and macula densa together are called the **juxtaglomerular apparatus** (**JGA**). The JGA plays a role in controlling the flow of filtrate through the nephron and the blood pressure within the glomerulus.

As filtrate passes through the renal tubule and collecting system, it is heavily modified, and most of the water and solutes are reclaimed and returned to the blood. By the time the filtrate leaves the papillary ducts to enter the minor calyces, it is known as **urine**, which then drains into the major calyces and, finally, into the renal pelvis.

From the renal pelvis, urine enters the next organs of the urinary system, which are collectively called the **urinary tract**. The first portion of the urinary tract consists of the tubes called the **ureters** (YOOR-eh-terz; Figs. 25.9 and 25.10). Ureters are lined by a type of epithelium called **transitional epithelium**, and their walls contain smooth muscle that massages the urine inferiorly via peristalsis.

The ureters drain urine into the posteroinferior wall of the organ known as the **urinary bladder** at the **ureteral orifices** (yoo-REE-ter-uhl; Fig. 25.11). Like the ureters, the urinary bladder is lined with transitional epithelium and contains smooth muscle, sometimes called the **detrusor muscle** (dee-TROO-sur), in its wall. The majority of the urinary bladder contains folds called **rugae** (ROO-ghee) that allow it to expand when it is filled with urine. The smooth inferior portion of the urinary bladder wall features a triangular-shaped area known as the **trigone** (TRY-gohn). This opens into the final organ of the urinary system—the **urethra** (yoo-REETH-ruh). The urethra is surrounded by two rings of muscle—the involuntary

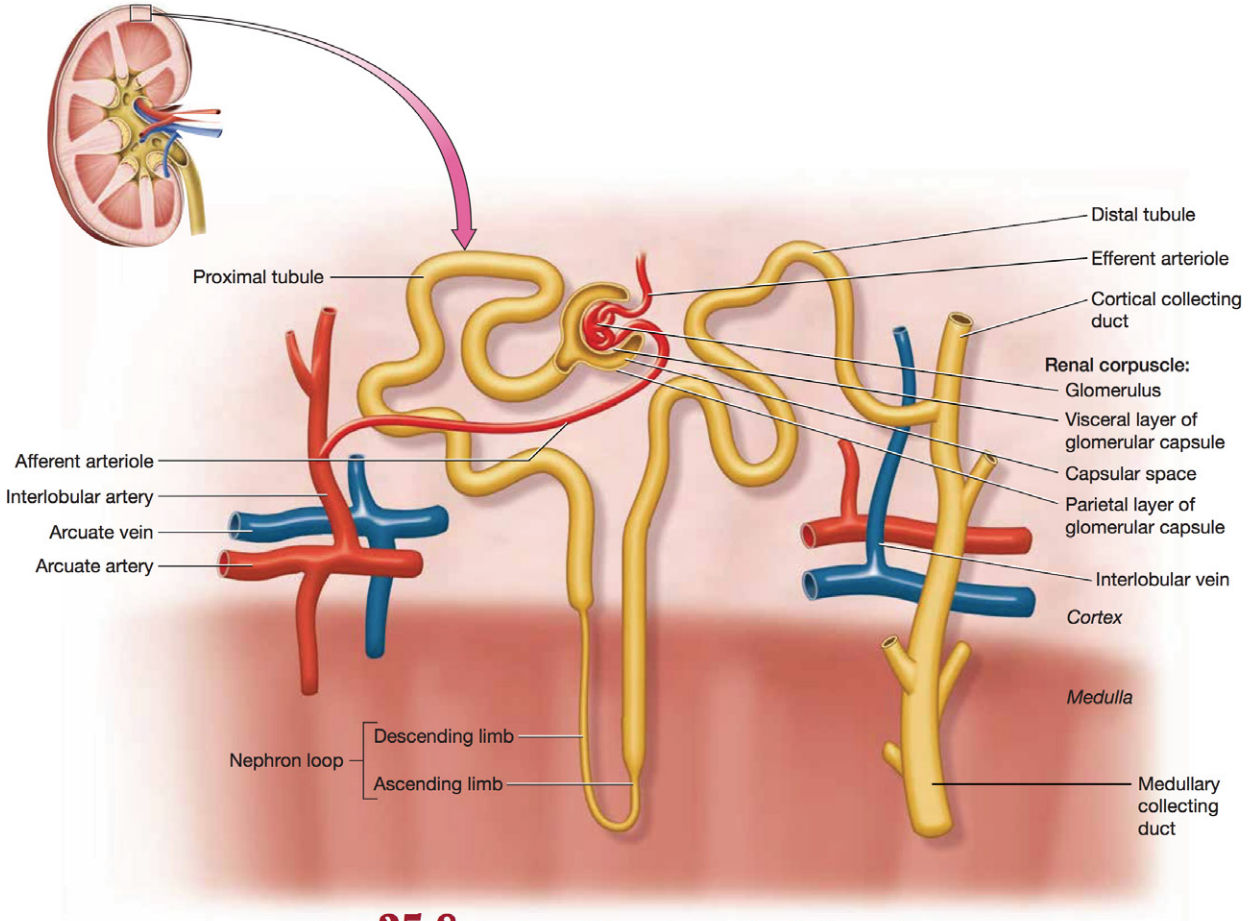

FIGURE **25.8** Structure of the nephron and collecting system.

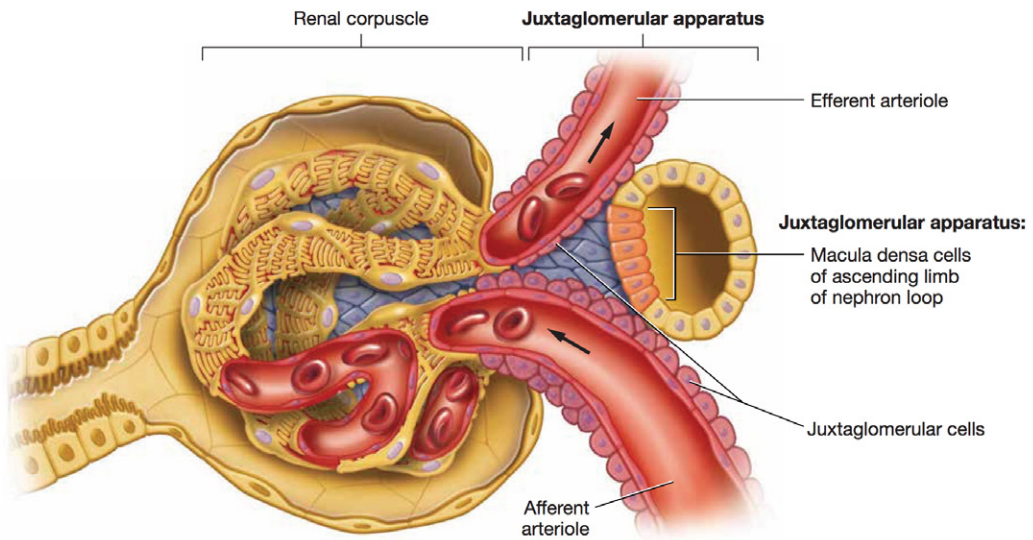

FIGURE **25.9** Juxtaglomerular apparatus.

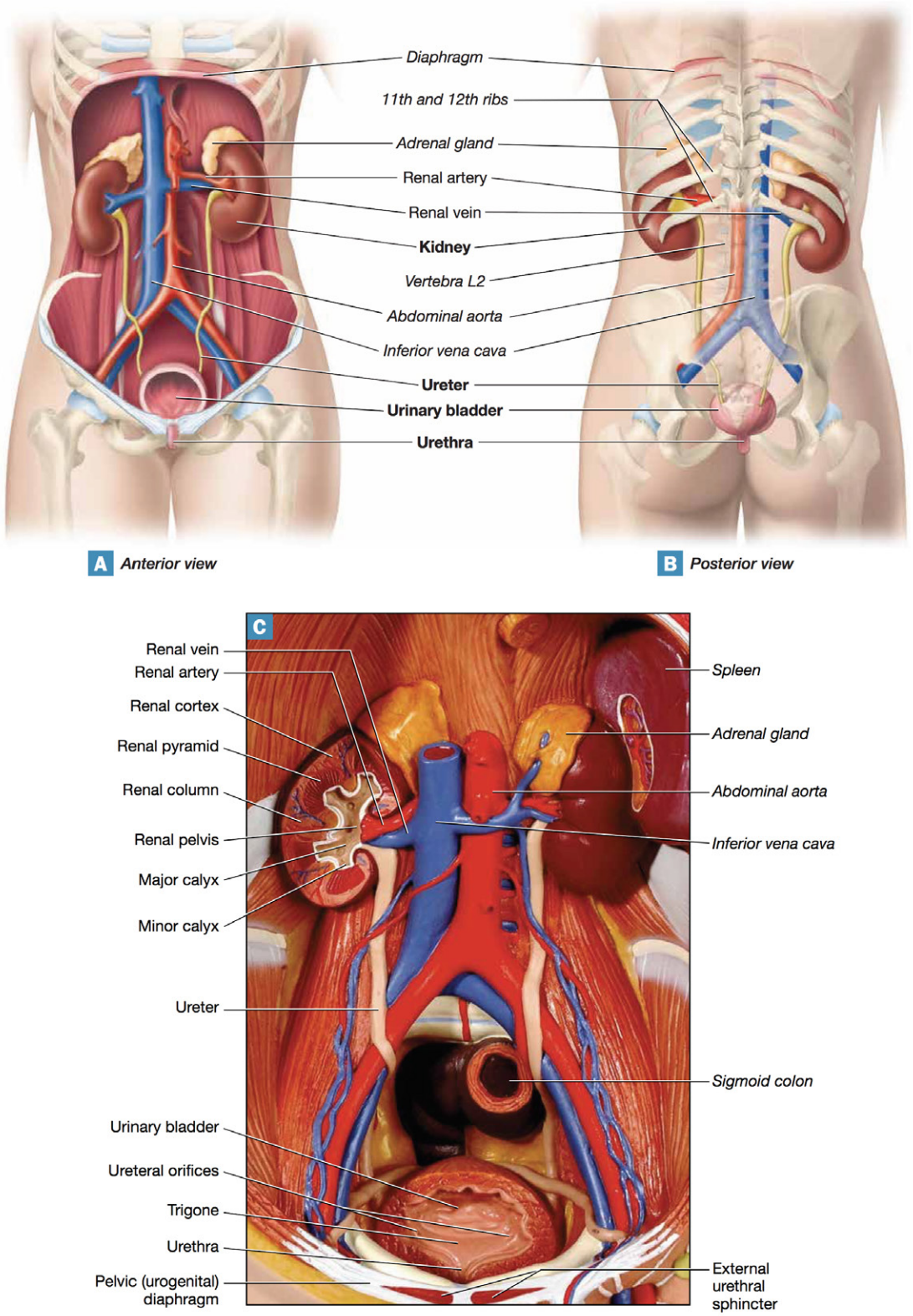

FIGURE **25.10** Organs of the female urinary system: (**A**) anterior view; (**B**) posterior view; (**C**) anatomical model photo.

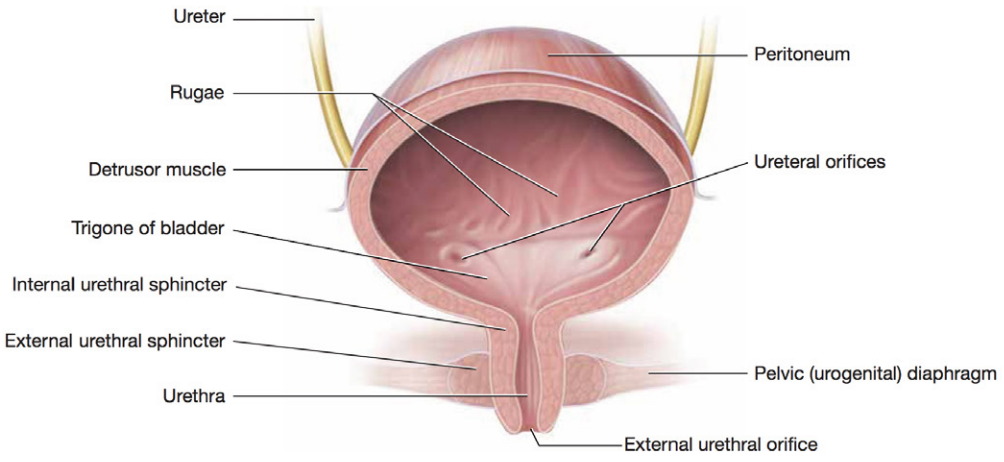

FIGURE **25.11** Female urinary bladder, frontal section.

internal urethral sphincter, composed of smooth muscle, and the voluntary **external urethral sphincter**, composed of skeletal muscle. The external urethral sphincter is an extension of the *levator ani muscle*, also known as the **pelvic** or **urogenital diaphragm**. When both of these sphincters relax, urine is expelled from the body through the **external urethral orifice** via a process called **micturition** (mik-choo-RISH-un).

Notice in Figure 25.12 that the male and female urethras are quite different. In females, the urethra is short, measuring only about 4 cm. In males, the urethra is much longer, about 20 cm, and has three divisions: the **prostatic urethra**, which passes through the *prostate gland*; the short **membranous urethra**, which passes through the pelvic diaphragm; and the **spongy urethra**, which passes through the penis. Another difference you may notice is the positon of the urinary bladder. The urinary bladder of the male is anterior to the rectum. The urinary bladder of the female sits anterior to the vagina and inferior to the uterus. This position is one of the reasons why pregnant women have to urinate so frequently—the enlarged uterus sits right on top of the urinary bladder.

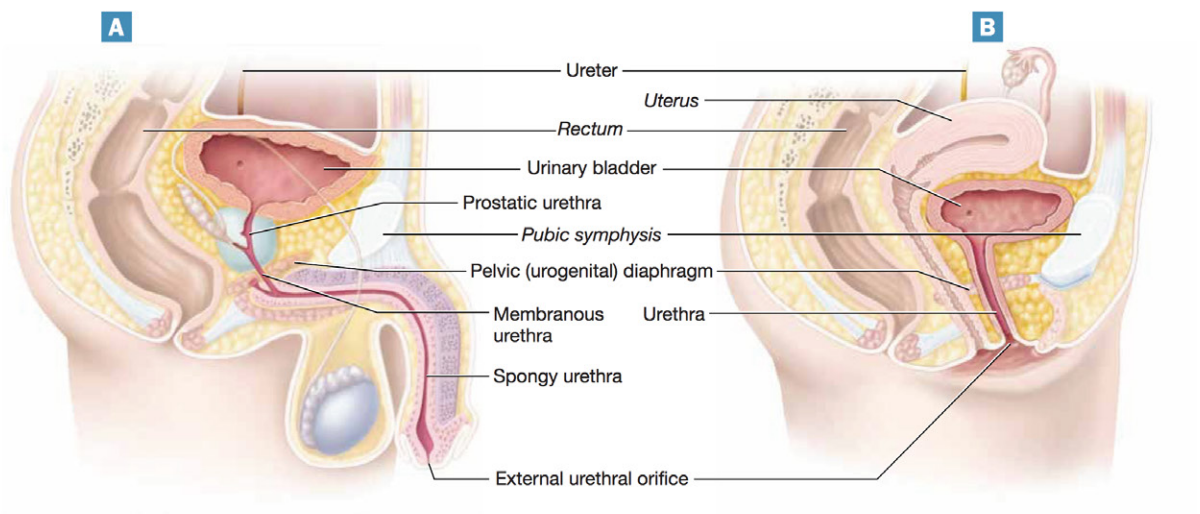

FIGURE **25.12** Organs of the male and female urinary systems, sagittal sections: (**A**) male urinary system; (**B**) female urinary system.

Procedure 1 Model Inventory for the Urinary System

Identify the following structures of the urinary system on models and diagrams, using your textbook and this unit for reference. As you examine the anatomical models and diagrams, record the name of the model and the structures you were able to identify on the model inventory in Table 25.1. When you have completed the activity, answer Check Your Understanding questions 1 through 4 (p. 687).

Kidney Anatomy

1. Surrounding connective tissue:
   a. Renal fascia
   b. Adipose capsule
   c. Renal capsule
2. Hilum
3. Regions:
   a. Renal cortex
   b. Renal medulla
      (1) Renal pyramids
      (2) Renal columns
      (3) Renal papilla
   c. Renal pelvis
      (1) Minor calyces
      (2) Major calyces
4. Blood supply:
   a. Renal artery
      (1) Segmental artery
      (2) Interlobar artery
      (3) Arcuate artery
      (4) Interlobular artery
   b. Renal vein
      (1) Interlobular vein
      (2) Arcuate vein
      (3) Interlobar vein

Structures of the Nephron and Collecting System

1. Renal corpuscle
   a. Glomerulus
      (1) Afferent arteriole
      (2) Efferent arteriole
      (3) Peritubular capillaries
   b. Glomerular capsule
      (1) Parietal layer
      (2) Visceral layer
      (3) Podocytes
      (4) Capsular space
2. Renal tubule
   a. Proximal tubule
   b. Nephron loop
      (1) Descending limb
      (2) Ascending limb
   c. Distal tubule
3. Collecting system
   a. Cortical collecting duct
   b. Medullary collecting duct
   c. Papillary duct
4. Juxtaglomerular apparatus
   a. Macula densa
   b. JG cells

Urinary Tract

1. Ureter
2. Urinary bladder
   a. Ureteral orifices
   b. Detrusor muscle
   c. Rugae
   d. Trigone
3. Urethra
   a. Internal urethral sphincter
   b. External urethral sphincter
      (1) Pelvic (urogenital) diaphragm
   c. External urethral orifice
   d. Prostatic urethra
   e. Membranous urethra
   f. Spongy urethra

TABLE **25.1** Model Inventory for Urinary Anatomy

Model/Diagram	Structures Identified

Procedure 2 Time to Draw the Urinary System

In the space provided, draw, color, and label one of the overview of the urinary system models that you examined. In addition, write the function of each structure that you label.

Procedure 3 Time to Draw A Nephron

In the space provided, draw, color, and label a nephron. In addition, write the function of each structure that you label.

Procedure 4 Kidney Dissection

In this exercise you will identify several of the structures you just identified on models and diagrams by dissecting a preserved kidney.

Safety Note

Safety glasses and gloves are required!

1 Obtain a fresh or preserved kidney specimen and dissection supplies.

2 If the thick surrounding connective tissue coverings are intact, note their thickness and amount of adipose tissue.

3 Use scissors to cut through the connective tissue coverings, and remove the kidney.

4 List surface structures you are able to identify (see Figure 25.13A for reference):

5 Distinguishing among the ureter, the renal artery, and the renal vein is often difficult. Following are some hints:

- **a** The renal artery typically has the thickest and most muscular wall, and it branches into several segmental arteries prior to entering the kidney.
- **b** The renal vein is thinner, flimsier, and often larger in diameter than the renal artery.
- **c** The ureter has a thick, muscular wall, but it does not branch after it leaves the kidney. Also, its diameter is usually smaller than either the renal artery or the renal vein.

Keeping these points in mind, determine the location of the renal artery, the renal vein, and the ureter on your specimen. Sketch the arrangement of the three structures in the space provided below.

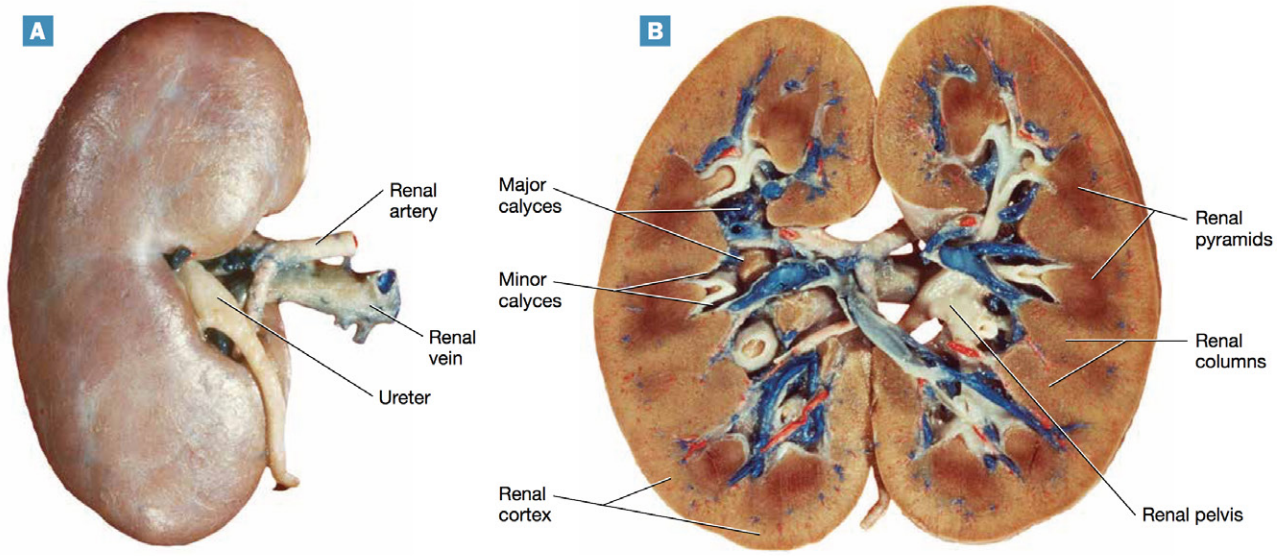

FIGURE **25.13** Preserved kidney: (**A**) anterior view; (**B**) frontal section.

6 Use a scalpel to make a frontal section of the kidney. Draw the kidney in the space provided below and label the structures you are able to identify (Fig. 25.13B).

Exercise 25-2

Urinary Organ Histology

MATERIALS

- ❑ Ureter slide
- ❑ Urinary bladder slide
- ❑ Renal cortex slide
- ❑ Renal medulla slide
- ❑ Light microscope
- ❑ Colored pencils

Like all hollow organs, the ureters and urinary bladder consist of several tissue layers (Figs. 25.14 and 25.15). The innermost layer is the **mucosa**, which is composed of transitional epithelium and a thin layer of loose connective tissue. Recall from Unit 5 (p. 97) that transitional epithelium is stratified epithelium with cells that differ in appearance on the apical and basal sides. The cells at the apical edge are dome-shaped (or sometimes squamous) in appearance, and those nearer the basal edge are typically cuboidal. The apical cells can change shape to accommodate stretching of the urinary bladder.

The middle layer of the ureters and urinary bladder is the **submucosa**, composed of loose connective tissue and numerous glands that secrete a watery mucus. This mucus plays a critical protective role, because it prevents the chemicals in the urine from damaging and ulcerating the epithelium. The third layer is the muscularis, composed of smooth muscle that contracts to propel urine through the urinary tract. The outermost layer is the **adventitia**, composed of dense irregular collagenous connective tissue.

In this exercise you will also examine the tissues in two different regions of the kidney—the renal cortex and the renal medulla. Both contain many tubules made of simple epithelia. The simple epithelia of the renal tubules provide an example of structure following function: A main function of these tubules is to reabsorb the water and solutes in the filtrate, and they could not perform this function efficiently with thick stratified epithelium. Another structural feature that aids in reabsorption is the presence of microvilli on the proximal tubule cells (and to a much lesser extent, the distal tubule). Microvilli dramatically

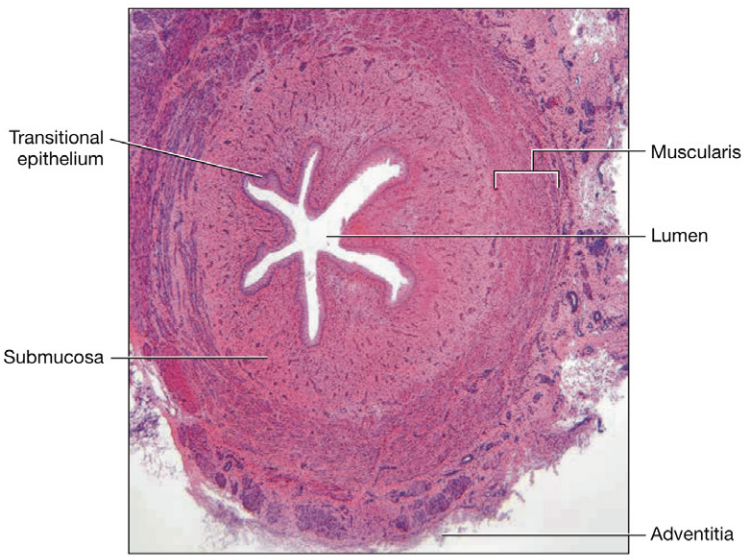

FIGURE **25.14** Tissues of the ureter.

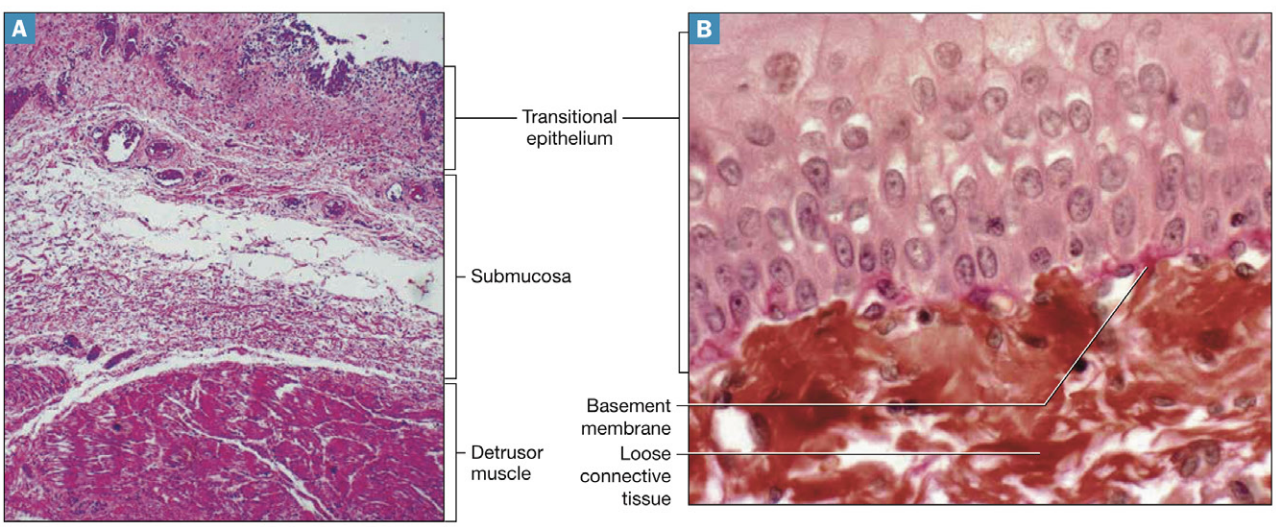

FIGURE **25.15** Urinary bladder: (**A**) bladder wall; (**B**) close-up of transitional epithelium.

increase the surface area available for reabsorption, which ensures that solutes and large volumes of water are reabsorbed rapidly from the filtrate.

Note in Figure 25.16A the abundance of small, ball-shaped glomeruli in the renal cortex. The glomeruli are surrounded by a space (the capsular space) lined by the ring of simple squamous epithelial cells that make up the parietal layer of the glomerular capsule (Fig. 25.16B). In between the glomeruli, note the presence of nephron tubules (the proximal and distal tubules and sections of nephron loops).

As you can see in Figure 25.16C, the renal medulla is composed mostly of collecting ducts and nephron loops. You will not see any glomeruli in the medulla, because they are confined to the cortex. This makes the renal cortex and renal medulla easily distinguishable.

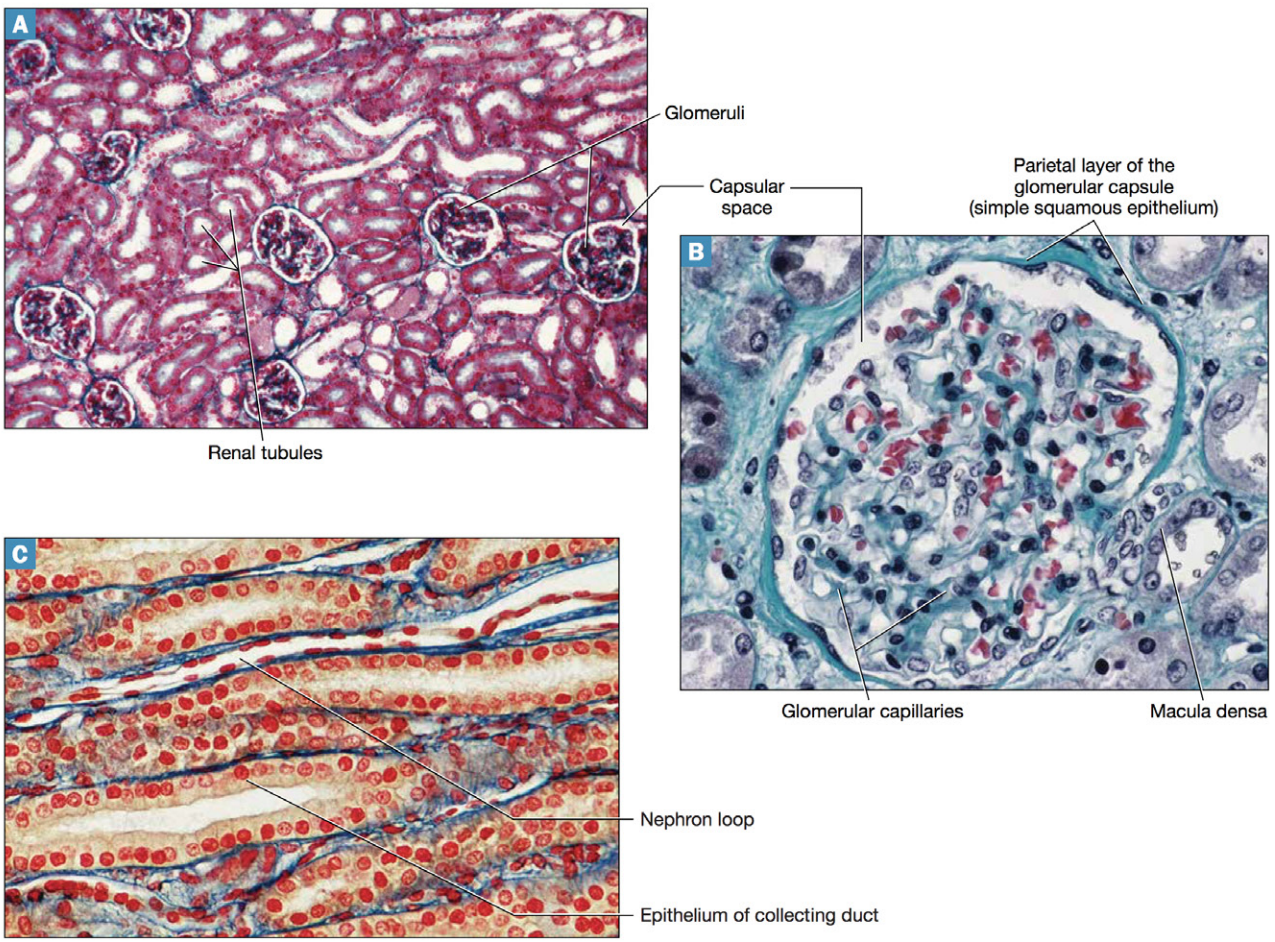

FIGURE **25.16** Tissues of the kidney: (**A**) renal cortex; (**B**) glomerulus; (**C**) renal medulla.

Procedure 1 Microscopy

Now you will view prepared slides of sections of the ureter, the urinary bladder, the renal cortex, and the renal medulla. Begin your examination of the slides on low power, and advance to medium and high power to observe details. Use colored pencils to draw what you see under the microscope, and label your drawing with the listed terms. When you have completed the activity, answer Check Your Understanding questions 5 through 7 (p. 688).

Ureter

Label the following on your drawing:

1. Transitional epithelium
2. Submucosa
3. Muscularis (smooth muscle)
4. Adventitia

Transitional epithelium (urinary bladder)

Label the following on your drawing:

1. Transitional epithelium
2. Submucosa
3. Muscularis (detrusor muscle)

Renal cortex

Label the following on your drawing:

1. Glomerulus
2. Glomerular capsule with simple squamous epithelium
3. Capsular space
4. Renal tubules

Renal medulla

Label the following on your drawing:

1. Nephron loop
2. Collecting ducts

Name _____

Section _____ Date _____

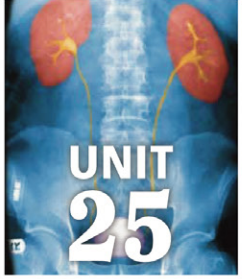

Check Your Recall

REVIEW

1 Label the following parts of the kidney on Figure 25.17.

- ❑ Major calyx
- ❑ Minor calyx
- ❑ Renal artery
- ❑ Renal capsule
- ❑ Renal column
- ❑ Renal cortex
- ❑ Renal medulla
- ❑ Renal pelvis
- ❑ Renal pyramid
- ❑ Renal vein
- ❑ Ureter

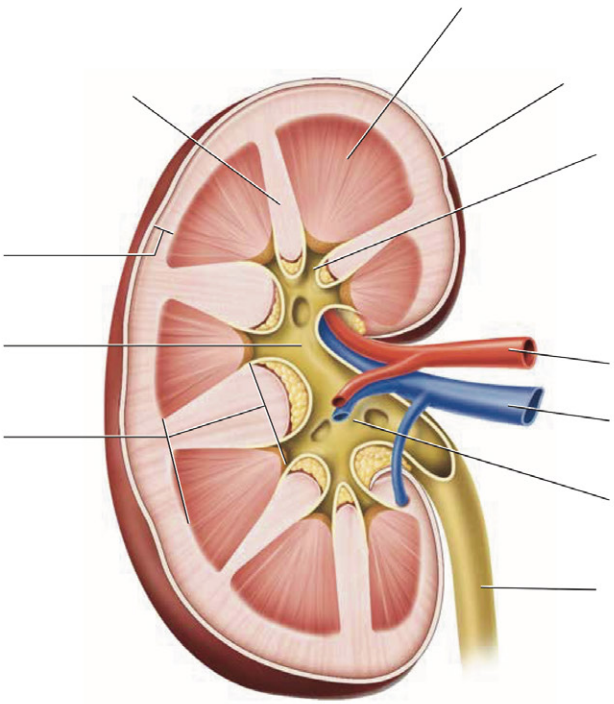

FIGURE **25.17** Right kidney, frontal section.

2 Label the following parts of the nephron on Figure 25.18.

- ❑ Afferent arteriole
- ❑ Cortical collecting duct
- ❑ Distal tubule
- ❑ Efferent arteriole
- ❑ Glomerular capsule
- ❑ Glomerulus
- ❑ Nephron loop
- ❑ Proximal tubule

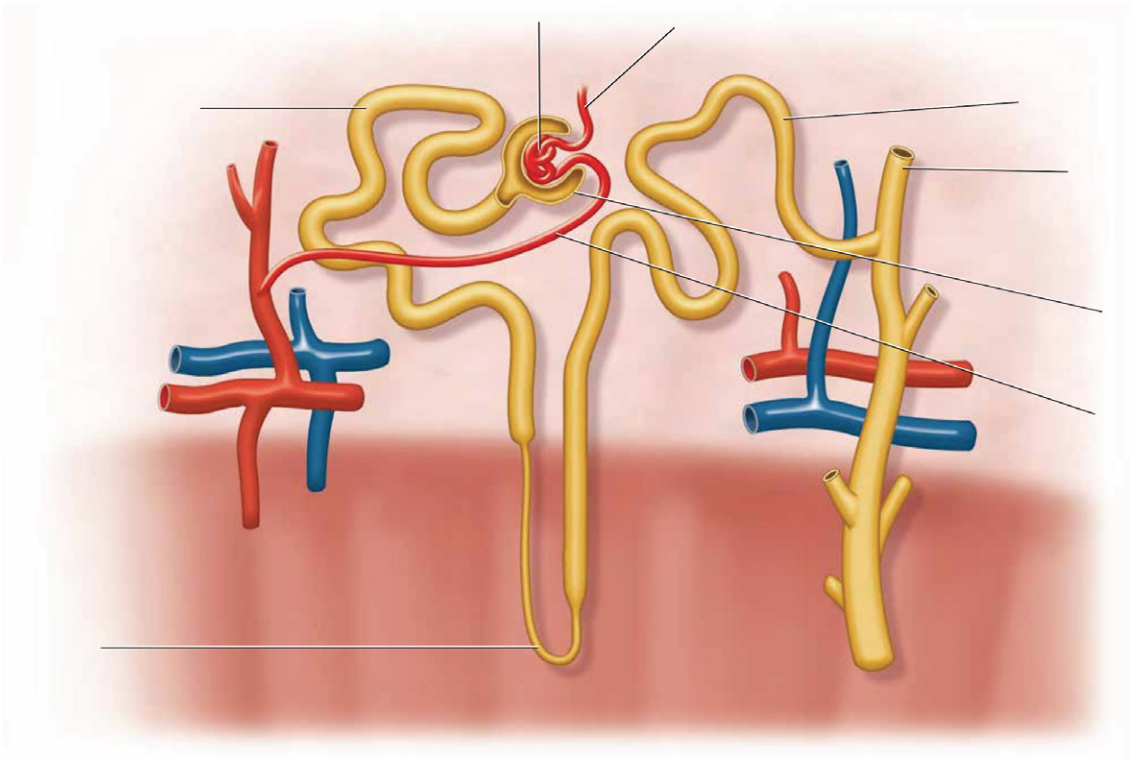

FIGURE **25.18** Structure of the nephron.

Name _____

Section _____ Date _____

3 Label the following parts of the urinary system on Figure 25.19.

- ❑ External urethral orifice
- ❑ Membranous urethra
- ❑ Pelvic (urogenital) diaphragm
- ❑ Prostatic urethra
- ❑ Spongy urethra
- ❑ Ureter
- ❑ Urinary bladder

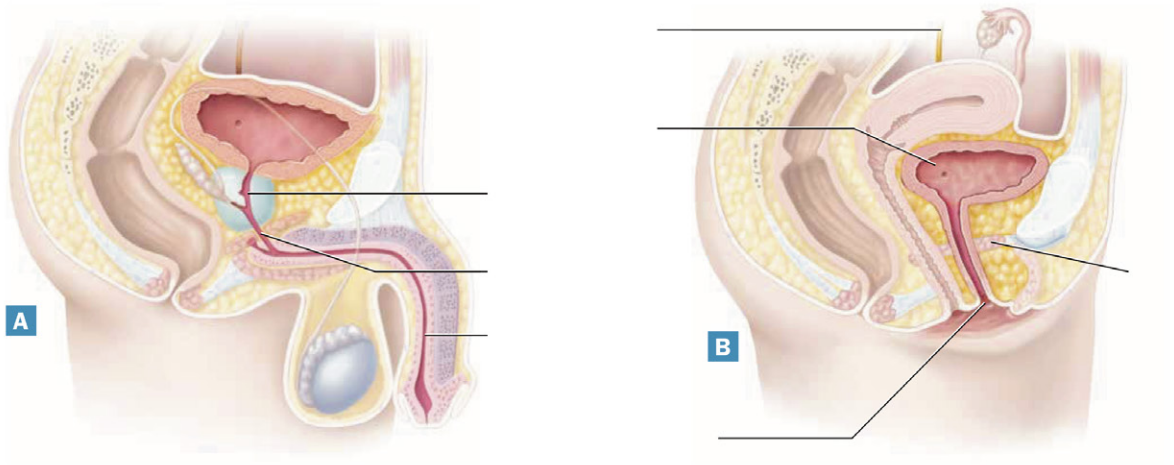

FIGURE **25.19** Organs of the male and female urinary systems, sagittal sections: (**A**) male; (**B**) female.

4 *True/False:* Mark the following statements as true (T) or false (F). If the statement is false, correct it to make it a true statement.

_____ a. The kidneys regulate erythrocyte formation through the production of the hormone glucagon.

_____ b. Renal corpuscles are confined to the renal medulla.

_____ c. Renal columns are extensions of the renal cortex into the renal medulla.

_____ d. The renal tubule consists of the proximal tubule, nephron loop, distal tubule, and collecting system.

5 The blood flow through the kidney is special because

a. its first capillary beds drain into arterioles.
b. its second capillary beds drain into arterioles.
c. it is supplied by three renal arteries.
d. it contains no capillary beds.

6 Number the following from the point the filtrate is first formed (with a number 1) to the point it drains into the renal pelvis (with a number 10).

_____ Major calyx

_____ Minor calyx

_____ Proximal tubule

_____ Cortical collecting duct

_____ Capsular space

_____ Nephron loop—descending limb

_____ Medullary collecting duct

_____ Nephron loop—ascending limb

_____ Papillary duct

_____ Distal tubule

7 Urine drains from the urinary bladder via the

a. ureteral orifices.
b. papillary calyces.
c. ureters.
d. urethra.

8 Glomeruli are located in the

a. renal cortex.
b. renal medulla.
c. renal pelvis.
d. Both a and b are correct.

9 The smooth muscle layer of the urinary bladder is also called the _____ muscle.

a. trigone
b. detrusor
c. levator ani
d. rugae

10 The urinary bladder and ureters are lined by

a. simple squamous epithelium.
b. transitional epithelium.
c. pseudostratified columnar epithelium.
d. stratified cuboidal epithelium.

25

Name _____

Section _____ Date _____

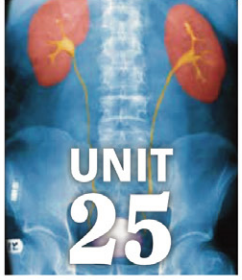

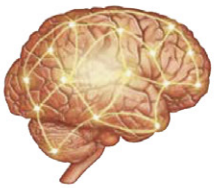

Check Your Understanding

REVIEW

Critical Thinking and Application Questions

1 Extreme starvation can lead to a loss of fat from the adipose capsule of the kidney. This leads to drooping of the affected kidney, a condition called *nephroptosis*. Explain why a loss of the adipose capsule can lead to nephroptosis.

2 Ana has advanced kidney disease. As part of her routine lab work, her physician monitors her complete blood count to check the number of erythrocytes in her blood. The most recent test demonstrated that Ana had a much lower erythrocyte count than normal, leading her physician to diagnose her with anemia. What is the relationship between Ana's kidney disease and her anemia?

3 Your lab partner wonders how the cells of the renal tubules and ducts of the collecting system obtain oxygen and nutrients when their capillary bed is located only in the renal corpuscle. What is your lab partner misunderstanding about the blood flow in the kidney? Explain his mistake to him.

4 Female patients suffer *urinary tract infections*, or bacterial infections of the urethra and urinary bladder, more frequently than do male patients. Why do you think this is so, considering the anatomy of the female and male urinary tracts?

5 The condition *interstitial cystitis* is characterized by insufficient mucus production by the mucosa and submucosa of the urinary bladder. What signs and symptoms would you expect to see with interstitial cystitis? Why?

6 Would the renal tubule and ducts of the collecting system be able to perform their functions if their epithelium were stratified rather than simple? Why or why not?

7 Predict how the functioning of the kidney might be affected if the microvilli in the proximal tubules were destroyed. Explain your reasoning.

25

UNIT
26

Urinary System Physiology

Once you have completed this unit, you should be able to:

1. Describe the process of glomerular filtration and the structure of the filtration membrane.
2. Model the physiology of the kidney and explain why only certain substances appear in the filtrate.
3. Perform and interpret urinalysis on simulated urine specimens.
4. Explain the possible causes of abnormalities detected on urinalysis.
5. Trace an erythrocyte, a glucose molecule, and a urea molecule through the gross and microscopic anatomy of the kidney.

Name _____ Section _____ Date _____

PRE-LAB EXERCISES

Complete the following exercises prior to coming to lab, using this lab manual and your textbook for reference.

Pre-Lab Exercise 26-1



Key Terms

You should be familiar with the following terms before coming to lab.

Term	Definition
Glomerular filtration	
Glomerular filtration rate (GFR)	
Filtration membrane	
Filtrate	
Tubular reabsorption	
Tubular secretion	
Urine	
Urinalysis	
Specific gravity	
Urobilinogen	
Ketones	

Name _____ Section _____ Date _____

Pre-Lab Exercise 26-2

Nephron Structure and Function

Review the structure of the nephron by labeling and color-coding Figure 26.1. Then use your textbook to determine which substances are absorbed or secreted from each region of the nephron and enter this information in the blank boxes to the side of the tubules. Place substances that are secreted into the urine in the boxes whose arrows are pointing toward the tubules. Place substances that are reabsorbed into the bloodstream in boxes whose arrows are pointing away from the tubules.

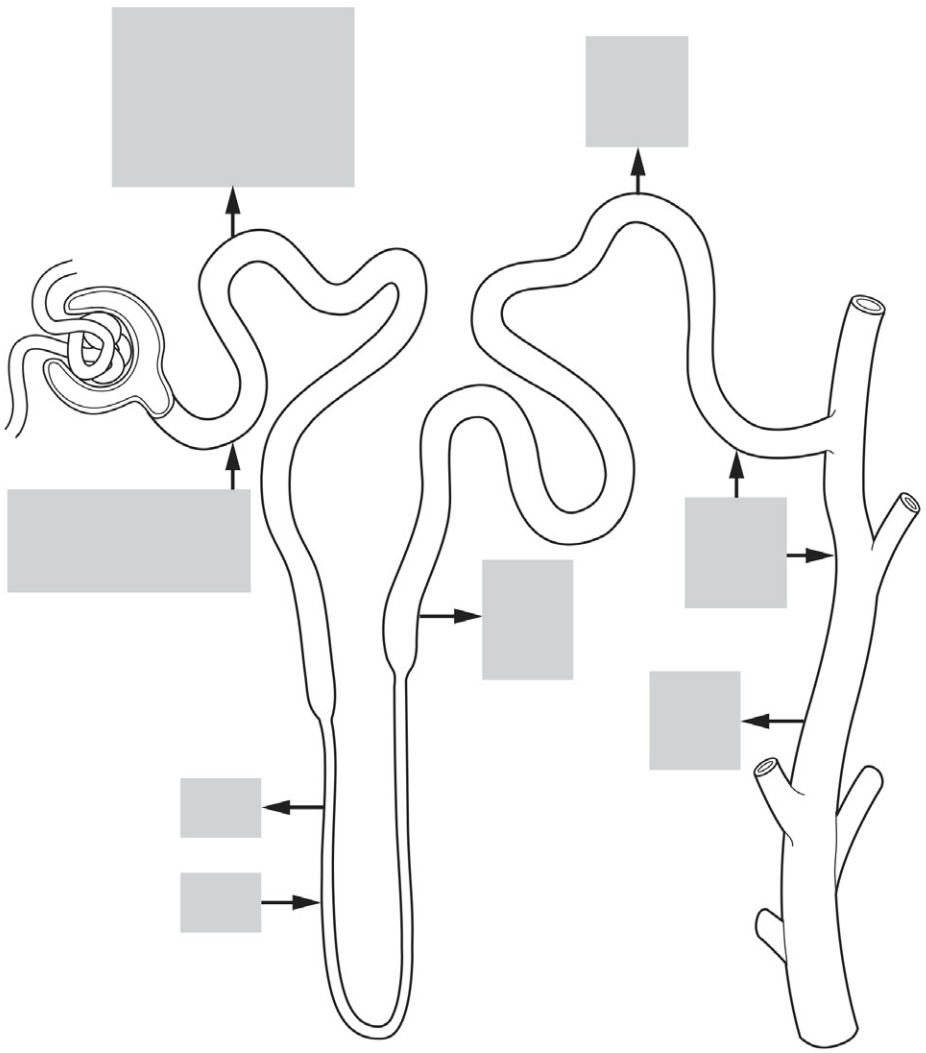

FIGURE 26.1 Nephron and collecting duct.

Pre-Lab Exercise 26-3



Glomerular Filtration and Tubular Reabsorption

Table 26.1 lists chemicals and cells found in blood. Do the following for each item, using your textbook for reference:

1. Determine whether each listed item is filtered at the glomerulus (i.e., if it is able to leave the blood and enter the nephron to become part of the filtrate under normal conditions).
2. If the substance is found in the filtrate, determine if the substance is reabsorbed into the blood or if it is found in the urine.
3. If the substance is reabsorbed into the blood, determine where this substance is reabsorbed in the nephron (e.g., the proximal tubule, the nephron loop, etc.).

TABLE 26.1 Substances Found in the Blood and Their Filtration and Reabsorption by the Nephron

Substance	Filtered in the Glomerulus? (yes/no)	Reabsorbed? (yes/no)	Location Where Reabsorption Takes Place
Erythrocyte			
Leukocyte			
Water			
Glucose			
Proteins			
Amino acids			
Urea			
Creatinine			
Sodium and chloride ions			
Potassium ions			
Uric acid			
Ketones			

Colored SEM of kidney stone crystals.

EXERCISES

The kidneys filter the blood in order to remove metabolic wastes and regulate the body's fluid, electrolyte, and acid-base balance. Recall from Unit 25 that the kidneys' filters are located within the glomerular capillaries. However, the glomerular capillaries can't filter the blood unless there is a force to push fluid and solutes through them and into the nephron tubule. This force is supplied by a pressure called the **net filtration pressure** (**NFP**).

The NFP is the combination of three forces (Fig. 26.2):

1. **Glomerular hydrostatic pressure** (**GHP**). The GHP is equal to the blood pressure in the glomerulus and averages about 50 mmHg. This pressure pushes fluid and solutes out of the glomerulus and into the capsular space.
2. **Colloid osmotic pressure** (**COP**). The COP is the pressure created by the presence of proteins and other solutes in the blood and averages about 30 mmHg; this pressure tends to oppose filtration and pulls water *into* the glomerular capillaries by osmosis.
3. **Capsular hydrostatic pressure** (**CHP**). The final pressure, the CHP, is the force of the fluid in the capsular space. It averages about 10 mmHg, and, like the COP, tends to oppose filtration, pushing water back into the blood in the glomerular capillaries.

As you can see in Figure 26.2, to get the NFP, simply subtract the two forces that oppose filtration from the one force that favors filtration:

$$\text{GHP} - (\text{COP} + \text{CHP}) = \text{NFP}$$
$$50 - (30 + 10) = 10 \text{ mmHg}$$

So there is a net pressure of 10 mmHg in the glomerulus that drives fluid from it into the capsular space. When the fluid enters the capsular space, it becomes a liquid called **filtrate**.

The rate of filtrate production averages about 120 mL/min, a value called the **glomerular filtration rate** (**GFR**). The GFR is determined largely by the three pressures that factor into the NFP. To put it simply, if the NFP increases, then the GFR generally also increases. The opposite is also true—if the NFP decreases, the GFR also generally decreases. Note that this is only true up to a point because there are many compensatory mechanisms that work to maintain a stable GFR. These compensatory mechanisms exist because the GFR is a critical determinant of kidney function; if the GFR is too low or too high, the kidneys will not be able to carry out their many functions.

The filtrate contains a number of substances our bodies need to reclaim, including water, glucose, amino acids, and many different ions. This reclamation occurs by a process known as **tubular reabsorption** (Fig. 26.3). About 99 percent of the water in the filtrate and most of the solutes are reabsorbed through the epithelium of the nephron tubules and

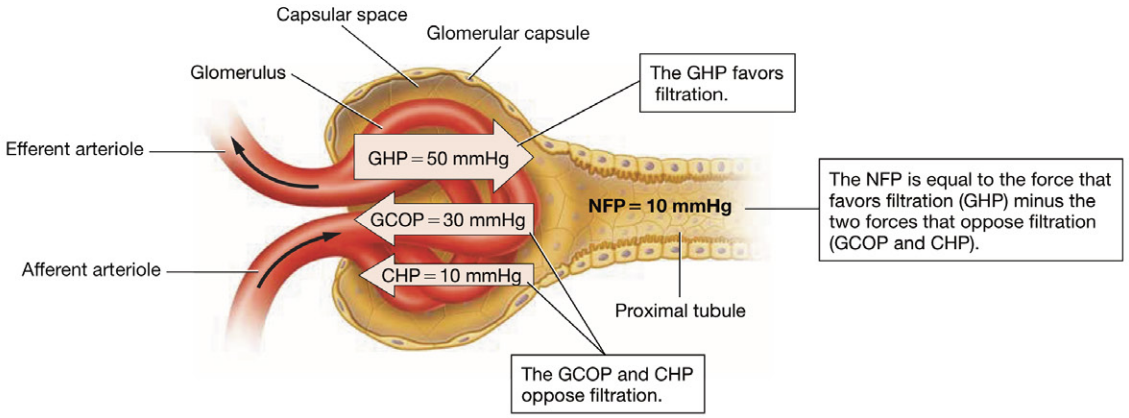

FIGURE **26.2** Net filtration pressure in the renal corpuscle.

returned to the blood. The importance of this function cannot be overstated. If the water were not reabsorbed in the renal tubules and the collecting ducts, we would lose our entire plasma volume in fewer than 30 minutes. This demonstrates another important reason to tightly regulate the GFR—if the GFR is too high, the nephron tubules will not have time to reabsorb all of the necessary substances in the filtrate, and we will lose much of our water and important solutes to the urine.

There are certain substances that aren't filtered at the glomerulus that need to be excreted in the urine, as well as substances that the body needs to excrete in greater amounts than are filtered. Notice in Figure 26.3 that such substances can move from the blood in the peritubular capillaries to the filtrate in the nephron tubules by a process known as **tubular secretion.** Examples of secreted substances include potassium ions, hydrogen ions, and uric acid.

In the following exercises you will examine the processes of filtration and reabsorption by constructing a model kidney and by testing samples of simulated urine (we cannot model secretion in the lab). In the final exercise you will trace the pathway of substances through the microanatomy of the kidney to contrast the filtration and reabsorption of erythrocytes, urea, and glucose.

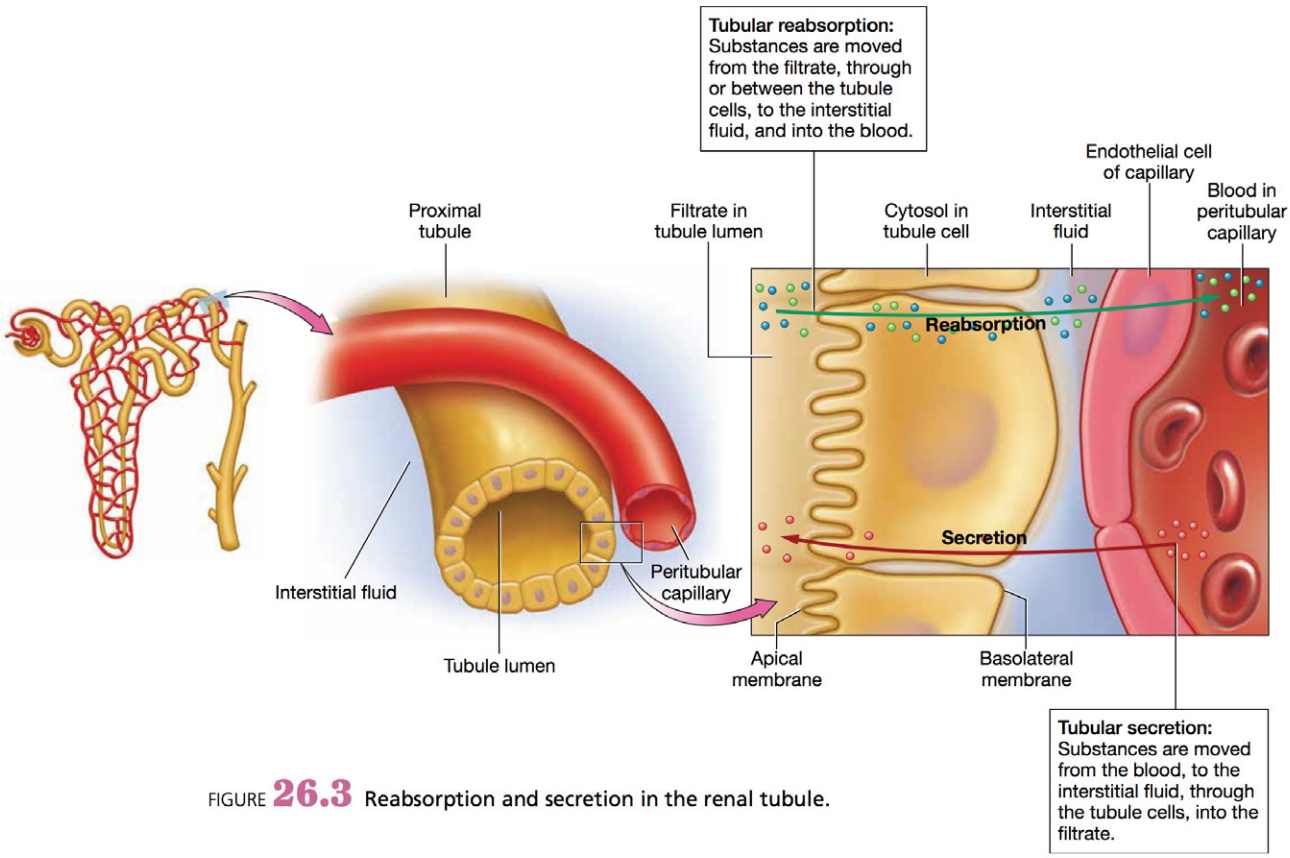

FIGURE **26.3** Reabsorption and secretion in the renal tubule.

Exercise 26-1

The Model Kidney

MATERIALS

- ❑ 4-inch piece of dialysis tubing
- ❑ 2 pieces of string
- ❑ Animal blood or simulated blood
- ❑ 200 mL beaker
- ❑ Deionized water
- ❑ URS-10 and bottle with key

The filtrate formed by glomerular filtration is similar in composition to blood, but it lacks the formed elements and most of the proteins we find in blood. This selectivity is possible because of a structure called the **filtration membrane,** which consists of a stack of three increasingly fine and selective filters. The first and leakiest filter is formed by the fenestrated endothelium of the glomerulus; the second filter is composed of the basal lamina around the endothelial cells, which contains interwoven collagen fibers; and the third and finest filter is formed by specialized cells called **podocytes** (POH-doh-syt′z; Fig. 26.4), which have specialized extensions called *foot processes* that interlace to form very narrow **filtration slits.**

The filtration membrane acts in a similar manner to the filter in your coffeemaker. Just as a coffee filter holds back the coffee grounds while allowing water and other solutes to pass through into your coffee, the filtration membrane prevents large items, such as proteins and cells, from leaving the blood while allowing small substances, such as water, glucose, amino acids, electrolytes, and metabolic wastes, to leave the blood and enter the filtrate. This selectivity is vitally important, as the nephron tubules and collecting system cannot reabsorb large proteins or cells; for this reason, any that entered the filtrate would be lost to the urine.

In this exercise you will examine the process of glomerular filtration and the selectivity of the filtration membrane by constructing a model kidney and by testing for substances that appear in the filtrate. A kidney is easily modeled with either animal blood or simulated blood and simple dialysis tubing, which has a permeability similar to that of the filtration membrane. Glomerular filtration is mimicked by immersing the blood-filled tubing in water. Substances to which the "filtration membrane" is permeable will enter the surrounding water (the "filtrate"), whereas those to which the membrane is not permeable will remain in the tubing.

The results of this test are analyzed using **urinalysis reagent test strips** (URS-10; Fig. 26.5). Each strip consists of 10 small, colored pads that change color in the presence of certain chemicals, such as glucose or hemoglobin. The strip is interpreted by watching the pads for color changes and comparing the color changes to a color-coded key on the side of the bottle. The color that is closest to the color on the strip is recorded as your result. Please note that for this exercise you will read only four of the 10 boxes: blood, leukocytes, protein, and glucose.

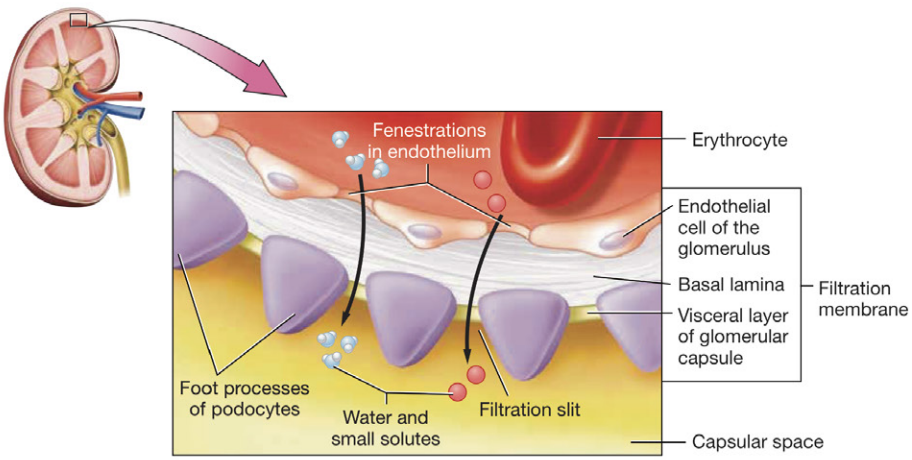

FIGURE **26.4** Structure of the filtration membrane.

FIGURE **26.5** URS-10 strip and vial.

Procedure 1 Making a Model Kidney and Testing Glomerular Filtration

Now let's construct our model kidneys. The model kidney must sit in water for 25 minutes while you wait for your results. While you wait, answer Check Your Understanding questions 1 through 4 (p. 705).

1 Cut a 4-inch piece of dialysis tubing.

2 Securely tie off one end of the tubing with string and open the other end of the tubing by wetting the end of the tube and rubbing it between your fingers.

3 Fill the dialysis tubing about half-full with either animal blood or simulated blood, and securely tie off the open end of the tube with string.

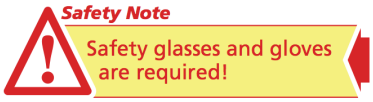

4 Place the tied-off tube in a 200 mL beaker containing about 150 mL of deionized water.

5 Leave the tubing in the water for approximately 25 minutes.

6 After 25 minutes have passed, remove the tubing from the water.

7 Dip a URS-10 strip in the water and remove it quickly. Turn the bottle on its side and compare the colors of the pads for glucose, blood, leukocytes, and protein. You will notice that on the side of the bottle, time frames are listed for each substance that is tested. Wait this amount of time to watch for a reaction; otherwise, you could obtain a false negative result. If you wait too long to read the results, though, the colors will tend to darken and may blend with adjacent colors.

8 Record your results below.

a Glucose: _____

b Erythrocytes (blood): _____

c Leukocytes: _____

d Protein: _____

9 Which substances were filtered out? Which substances stayed in the tubing? Explain your results.

_____

_____

_____

Exercise 26-2

Urinalysis

MATERIALS

- ❑ Samples of simulated urine
- ❑ Graduated cylinder or test tube
- ❑ URS-10 and bottle with key

For hundreds of years, healthcare providers have recognized the utility of urinalysis as a diagnostic tool. Historically, the urine was evaluated for color, translucency, odor, and taste (yes, taste!). Today, while these characteristics are still examined (except, thankfully, taste), we also utilize urinalysis test strips, as we did in Exercise 26-1 (p. 695), to test for the presence of various chemicals in the urine. Normal and abnormal readings both can give a healthcare provider a wealth of information about a patient's renal function and overall health.

In this exercise you will analyze different urine samples using a URS-10, as in Exercise 26-1. For each urine sample, one or more results will be read as abnormal. In the second part of the exercise, you will research potential causes of the abnormalities that you detected.

Procedure 1 Urinalysis Part One: Identifying Abnormalities

Test a minimum of five samples of simulated urine using your URS-10 test strips. Use a new strip for each sample, and take care to clean your graduated cylinder thoroughly between each sample that you test. Please note that this is *simulated* urine rather than real urine, although it contains the same chemicals as real urine and should be handled with equal caution.

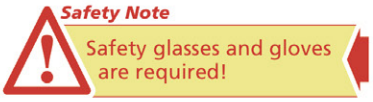

1. Randomly choose one sample of simulated urine, and pour approximately 3 mL of the sample into a test tube or graduated cylinder.
2. Submerge one URS-10 in the urine, and quickly remove it.
3. Compare the resulting colors and patterns on the test strip to those on the key on the bottle. Be sure to wait the appropriate amount of time to read the results.
4. Record your results in Table 26.2, and note any anomalous results.
5. Repeat this procedure for the remaining samples.

TABLE **26.2** Urinalysis Results

Reading	Sample 1	Sample 2	Sample 3	Sample 4	Sample 5
pH					
Leukocytes					
Nitrite					
Urobilinogen					
Protein					
Blood					
Specific gravity					
Ketones					
Bilirubin					
Glucose					

Procedure 2 Urinalysis Part Two: Researching Possible Pathologies

Each sample that you tested should have had at least one abnormality. Use your textbook and/or the Internet as a resource to determine which disease state(s) could lead to the abnormality you detected in each sample. Record your results in Table 26.3. After you have completed the activity, answer Check Your Understanding questions 5 and 6 (p. 706).

TABLE 26.3 Urinalysis Abnormalities and Disease States

Sample	Primary Abnormality	Potential Causes
1		
2		
3		
4		
5		

Exercise 26-3

Time to Trace!

MATERIALS

- ❑ Anatomical models of the kidney and nephron

Let's now trace the pathway of different substances through the vasculature and the microanatomy of the kidney. You will examine the path taken by (1) an erythrocyte (a red blood cell), (2) a molecule of glucose, and (3) a molecule of urea. The path that each takes differs in key ways—and it's your job to figure out how so.

Following are some hints to help you:

- Remember the basic rules of blood flow: You must pass through a capillary bed in order to get from an artery to a vein. Also recall that there are two capillary beds in the microcirculation of the kidney, the glomerulus and the peritubular capillaries.
- Table 26.1 in Pre-Lab Exercise 26-3 (p. 692) can be a big help, as it tells you three key pieces of information: (1) if the item is filtered at the glomerulus, (2) if a filtered item is reabsorbed, and (3) where reabsorption takes place.
- Don't overthink things. If an item isn't filtered at the glomerulus, that means it must stay in the blood, right? Similarly, if an item is filtered at the glomerulus, but is never reabsorbed, it must go through the whole nephron and collecting system to end up in the urine.
- Refer to Figure 26.6 for help with the pathway of blood flow through the kidney and the kidney's microanatomy.

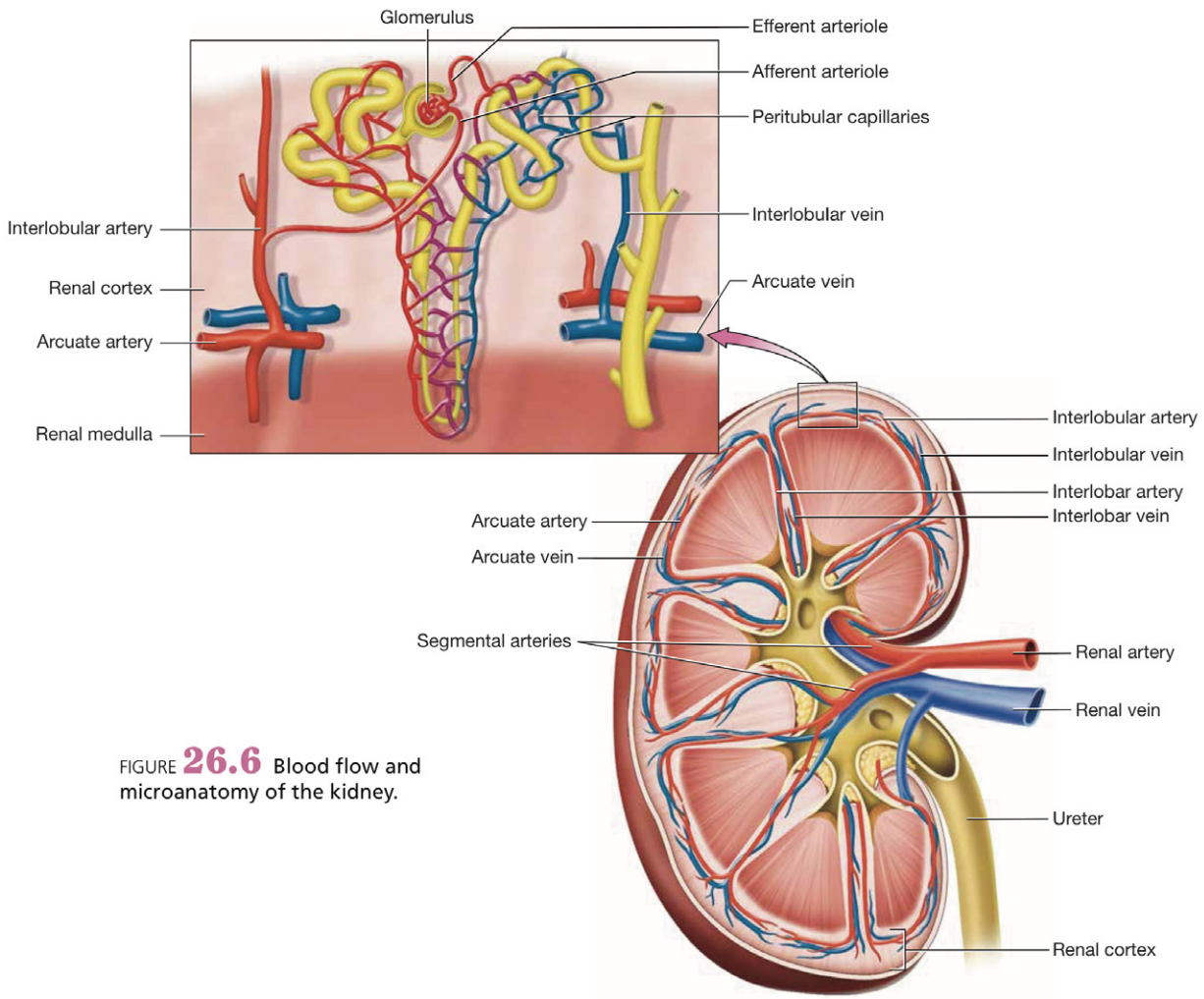

FIGURE **26.6** Blood flow and microanatomy of the kidney.

Procedure 1 Tracing Substances through the Kidney

Complete the following tracing procedures, using Figure 26.6 (p. 700) and Unit 25 for reference. When you have completed all three parts, answer Check Your Understanding question 7 (p. 706).

Part 1 Erythrocyte

Trace an erythrocyte from the renal artery to the renal vein.

_____ → _____ →
_____ → _____ →
_____ → _____ →
_____ → _____ →
_____ → _____ →
_____ → _____ →
_____.

Part 2 Glucose

Trace a molecule of glucose from the renal artery to the renal vein.

_____ → _____ →
_____ → _____ →
_____ → _____ →
_____ → _____ →
_____ → _____ →
_____ → _____ →
_____ → _____ →
_____.

Part 3 Urea

Trace a molecule of urea from the renal artery to its final destination outside the body of a female.

Part 3a Urea (Alternate)

Note that urea is sometimes recycled, meaning it is reabsorbed in the medullary collecting duct and secreted back into the filtrate at the thin limb of the nephron loop. Your instructor may want you to take this into account in your tracing of the urea molecule. If so, write the alternate path here:

Name _____

Section _____ Date _____

UNIT 26 REVIEW

Check Your Recall

1 *Fill in the blanks:* The pressure in the glomerulus that tends to favor filtration is known as the _____, and the two pressures that oppose filtration are the _____ and the _____.

2 The overall force that drives glomerular filtration is known as the

a. glomerular osmotic pressure.
b. capsular hydrostatic pressure.
c. glomerular filtration pressure.
d. net filtration pressure.

3 *Fill in the blanks:* The rate of filtrate formation is known as the _____ and averages about _____.

4 What is the purpose of tubular secretion?

a. To remove substances in the blood and place them into the filtrate.
b. To reclaim 99 percent of the water from the filtrate.
c. To reclaim electrolytes, glucose, and amino acids from the filtrate.
d. Both b and c are correct.
e. Both a and b are correct.

5 Which is the correct pathway that a substance takes when it is reabsorbed from the filtrate?

a. Filtrate → between or through tubule cells → interstitial fluid → blood in peritubular capillaries.
b. Blood in peritubular capillaries → interstitial fluid → between or through tubule cells → filtrate.
c. Filtrate → between or through tubule cells → interstitial fluid → blood in glomerular capillaries.
d. Filtrate → interstitial fluid → cytosol of tubule cells → blood in glomerular capillaries.

6 Which of the following is not a component of the filtration membrane?

a. Glomerular endothelial cells.
b. Podocytes.
c. Smooth muscle.
d. Basal lamina.

7 Why do you find glucose in the filtrate but not formed elements of the blood (erythrocytes, leukocytes, and platelets)?

8 *True/False:* Mark the following statements as true (T) or false (F). If the statement is false, correct it to make it a true statement.

_____ a. The fluid and solutes in the filtrate have been removed from the blood and are located in the renal tubule.

_____ b. The third and finest filter in the filtration membrane is created by the podocytes and their filtration slits.

_____ c. Nephron tubules can reabsorb large proteins and cells that enter the filtrate.

_____ d. Substances such as glucose, proteins, and erythrocytes are secreted into the filtrate.

9 Urinalysis can tell you

a. if there is an infection in the kidney or urinary tract.
b. if blood sugar is elevated.
c. if a person is dehydrated.
d. if a person's kidneys function normally.
e. All of the above.

10 Which of the following substances would you not expect to find in significant amounts in normal urine?

a. Sodium ions.
b. Proteins.
c. Urea.
d. Hydrogen ions.

Name _____

Section _____ Date _____

REVIEW

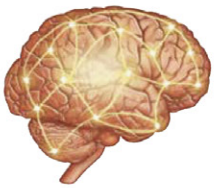

Check Your Understanding

Critical Thinking and Application Questions

1 Why didn't all of the substances exit your model kidney to enter the "filtrate?"

2 What other substances would you expect to find in the "filtrate" surrounding your model kidney? Explain.

3 Dialysis tubing comes in a variety of pore sizes. The size that you used in your experiment is relatively close to the filtration slits in the filtration membrane. How would your results have changed if you had used dialysis tubing with a pore size about 1,000 times larger than the tubing that you used? Why?

4 Calculate the net filtration pressure if the glomerular hydrostatic pressure measures 46 mmHg, the colloid osmotic pressure 34 mmHg, and the capsular hydrostatic pressure 10 mmHg. Does this differ from the normal value? If so, how? What effect, if any, would this have on the GFR?

5 Mr. Yien reports to the clinic after having passed reddish-colored urine this morning. He reports that he has been feeling very fatigued for several weeks and hasn't been urinating as much as usual. He also tells you that three years ago he had a kidney transplant. You order a urinalysis, which is positive for large amounts of blood and protein. What is potentially causing Mr. Yien's problems, given his medical history? Explain.

6 Poorly controlled *diabetes mellitus*, which results in a high blood glucose, often causes glucose and ketones to be found in the urine. Explain these findings. (You may need to use your textbook for help.)

7 In Exercise 26-3 (p. 700), you traced items that were filtered at the glomerulus. Now consider a hydrogen ion that is not filtered but is instead secreted from the peritubular capillaries into the filtrate at the distal tubule. Trace the pathway this hydrogen ion would take from the afferent arteriole to the point at which it exits the body of a male in the urine.

Start: Afferent arteriole → _____ → _____ →

_____ → _____ → _____ →

_____ → _____ → _____ →

_____ → _____ → _____ →

_____ → _____ → _____ →

_____ → _____ → Exits the body in the urine.

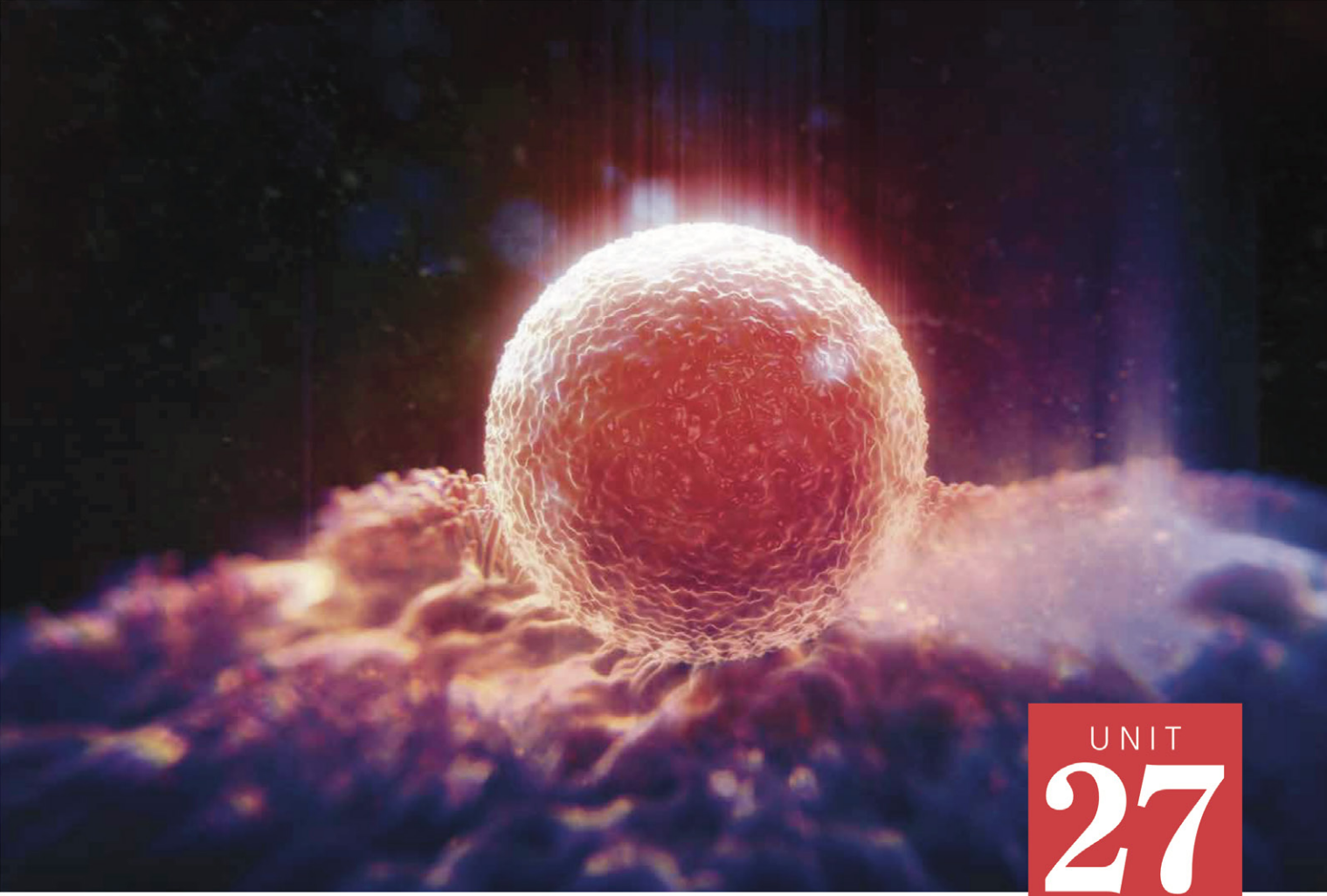

UNIT
27

Reproductive System

Once you have completed this unit, you should be able to:

1. Identify structures of the male and female reproductive systems.
2. Describe the histology of the ovary, seminiferous tubules, and spermatozoa.
3. Identify the stages of meiosis and describe how meiosis differs from mitosis.
4. Describe the processes of spermatogenesis and oogenesis.
5. Trace the pathway a developing gamete takes from its development to the time of fertilization.

Name _____ Section _____ Date _____

PRE-LAB EXERCISES

Complete the following exercises prior to coming to lab, using this lab manual and your textbook for reference.

Pre-Lab Exercise 27-1



Key Terms

You should be familiar with the following terms before coming to lab.

Term	Definition

Structures of the Male Reproductive System

Testes _____

Seminiferous tubules _____

Epididymis _____

Ductus deferens _____

Spermatic cord _____

Seminal vesicle _____

Prostate gland _____

Corpus spongiosum _____

Corpora cavernosa _____

Structures of the Female Reproductive System

Ovaries _____

Name _____ Section _____ Date _____

Ovarian follicles _____

Uterine tube _____

Uterus _____

Cervix _____

Vagina _____

Vulva _____

Mammary glands _____

Gametogenesis Terms

Meiosis I _____

Meiosis II _____

Haploid _____

Spermatogenesis _____

Oogenesis _____

Pre-Lab Exercise 27-2

Male Reproductive Anatomy

Label and color the structures of the male reproductive system in Figure 27.1 with the terms from Exercise 27-1 (p. 713). Use your text and Exercise 27-1 in this unit for reference.

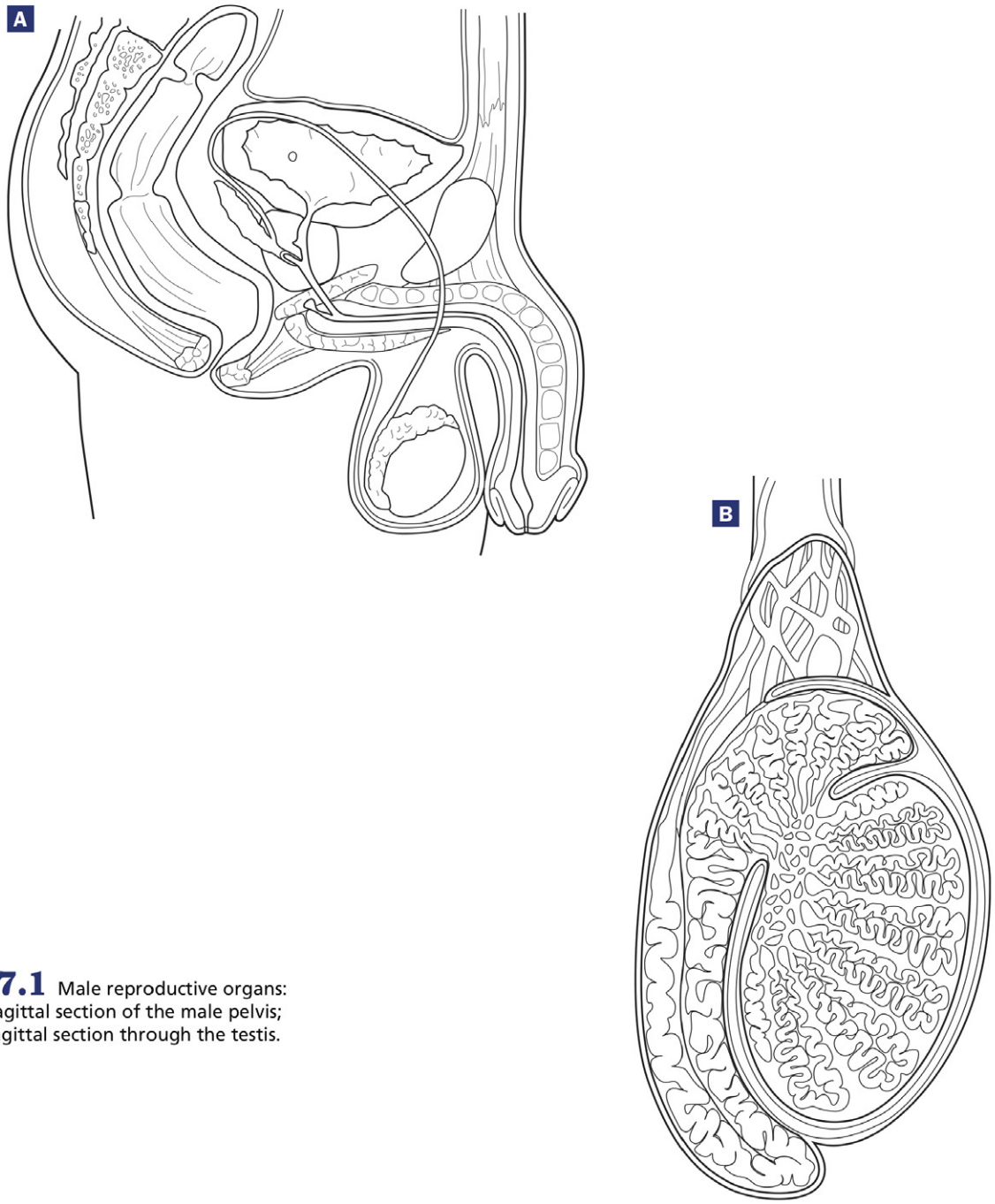

FIGURE **27.1** Male reproductive organs: (**A**) midsagittal section of the male pelvis; (**B**) midsagittal section through the testis.

27

Name _____ Section _____ Date _____

Pre-Lab Exercise 27-3

Female Reproductive Anatomy

Label and color the structures of the female reproductive system in Figure 27.2 with the terms from Exercise 27-2 (p. 717). Use your text and Exercise 27-2 in this unit for reference.

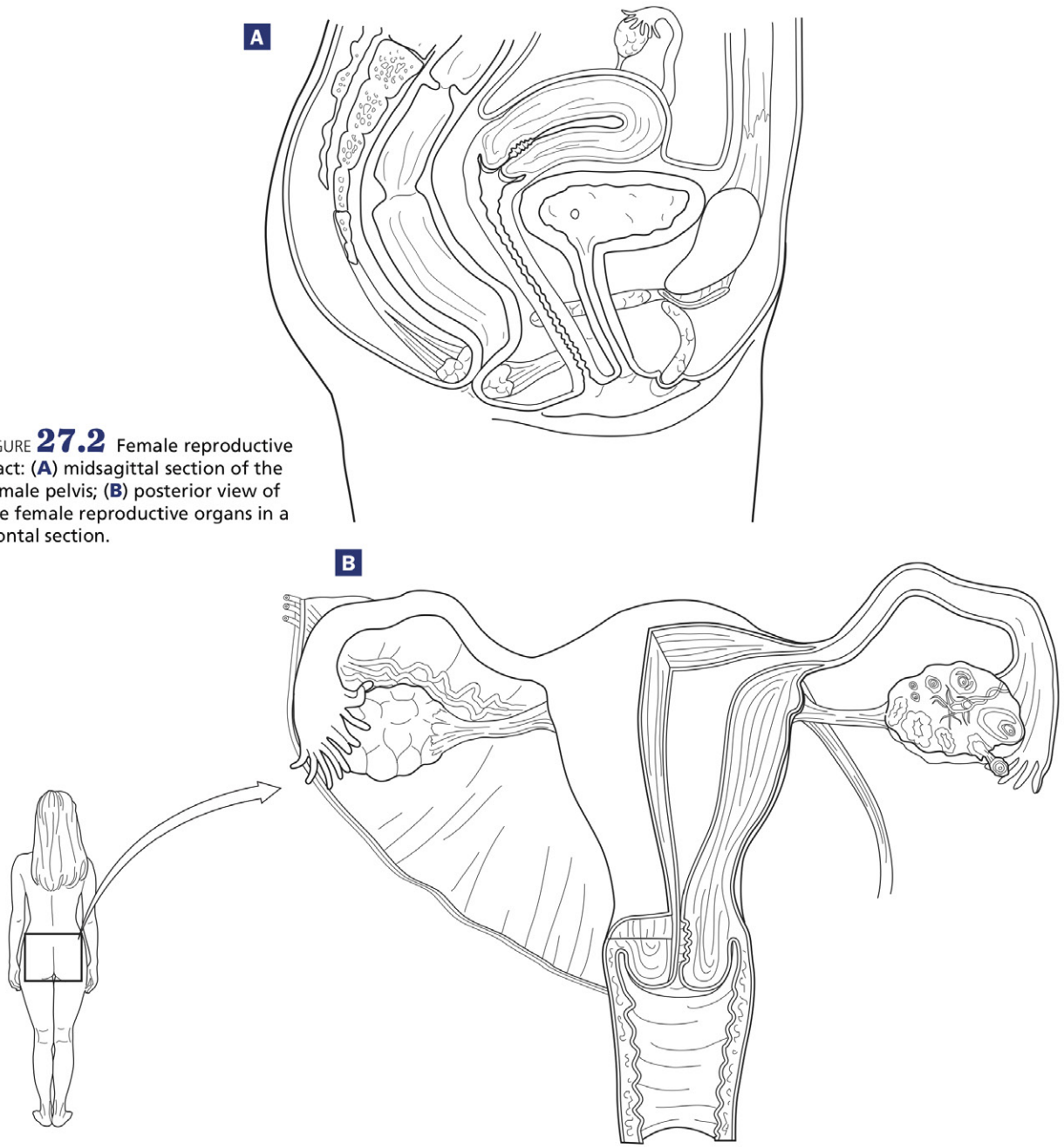

FIGURE **27.2** Female reproductive tract: (**A**) midsagittal section of the female pelvis; (**B**) posterior view of the female reproductive organs in a frontal section.

Pre-Lab Exercise 27-4

Stages of Mitosis

In this unit we will discuss the process of meiosis. Meiosis proceeds in a fashion similar to mitosis, so it's a good idea to review the discussion of mitosis before you begin the lab. Fill in Table 27.1 with the events occurring in the cell in each of the stages of mitosis.

TABLE **27.1** Stages of Mitosis

Stage of Mitosis	Events Occurring in the Cell
Prophase	
Metaphase	
Anaphase	
Telophase	

Ovum surrounded by cilia lining the uterine tubes.

EXERCISES

The other organ systems in the human body we have discussed all function in some manner to help maintain homeostasis of the body. The **reproductive system**, however, plays a lesser role in maintaining homeostasis but a greater role in perpetuating the species. The main organs of the reproductive system are the **gonads**—the testes and the ovaries—which produce **gametes** (GAM-eetz), or sex cells, for reproduction.

We begin this unit with the anatomy of the male (Ex. 27-1, p. 713) and female (Ex. 27-2, p. 717) reproductive systems. Then we turn to the main functions of these organs: **gametogenesis** (gah-meet-oh-JEN-uh-sis), the formation of new gametes.

Exercise 27-1

Male Reproductive Anatomy

MATERIALS

- ❑ Male reproductive models
- ❑ Human torso models

The **testes**, the gamete-producing organs of the male, are situated outside the body in a sac known as the **scrotum**, which is composed of skin, connective tissue, and a layer of smooth muscle called the **dartos muscle** (Fig. 27.3). They are located externally because sperm production requires a temperature of about 34°C (about 94°F), which is lower than body temperature. Along the midline, the scrotum has a connective tissue septum that divides it into two chambers, one for each testis. Smooth muscle tissue called the **cremaster muscle** (kreh-MASS-ter) surrounds each testis in the scrotum. This muscle tissue contracts to control the testes' distance from the body and, therefore, their temperature.

The layer of connective tissue deep to the scrotum extends up into the pelvic cavity to form a structure known as the **spermatic cord.** Notice in Figure 27.3 that the spermatic cord surrounds the cremaster muscle, the testicular artery, a group of veins draining the testis called the **pampiniform venous plexus,** a duct that transports sperm known as the *ductus deferens*, and nerves that supply the testes. The spermatic cord passes into the pelvic cavity through the *external inguinal ring*, which is the opening to a small passageway called the *inguinal canal* (IN-gwin-uhl).

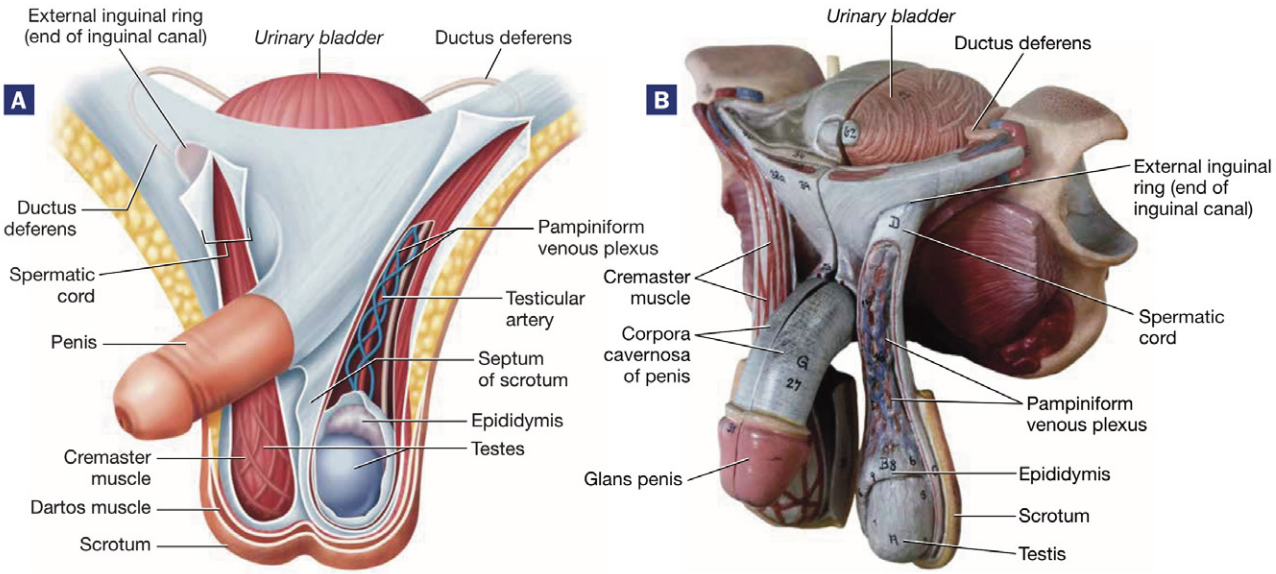

FIGURE **27.3** Structure of the scrotum and spermatic cord: (**A**) illustration; (**B**) anatomical model photo.

Deep to the cremaster muscle we find two more sheaths: the superficial **tunica vaginalis**, which is a serous membrane, and the deep **tunica albuginea** (al-byoo-JIN-ee-uh), which is connective tissue that divides the interior of each testis into lobules (Fig. 27.4). Each lobule contains a tightly coiled **seminiferous tubule** (sem-ih-NIF-er-us) where *spermatogenesis* (sper-mat-oh-JEN-ih-sis), or the formation of sperm cells, takes place.

The seminiferous tubules converge near the superior part of the testis to form a structure called the **rete testis** (REE-tee TES-tis). The rete testis exits the testis to join the first segment of the duct system of the male reproductive tract, the **epididymis** (ep-ih-DID-ih-miss; Figs. 27.4 and 27.5). There are three portions of the epididymis: the initial *head*, the middle *body*, and the final *tail*. Immature sperm produced by the seminiferous tubules migrate through each of these regions of the epididymis to finish their maturation, after which they move to a long tube called the **ductus** (or *vas*) **deferens** (DUK-tuss DEF-er-ahnz). Notice in Figure 27.5 that the ductus deferens ascends through the pelvic cavity and curls posteriorly and superiorly around the urinary bladder. On the posterior surface of the urinary bladder, the ductus deferens widens to form its terminal portion, the *ampulla*.

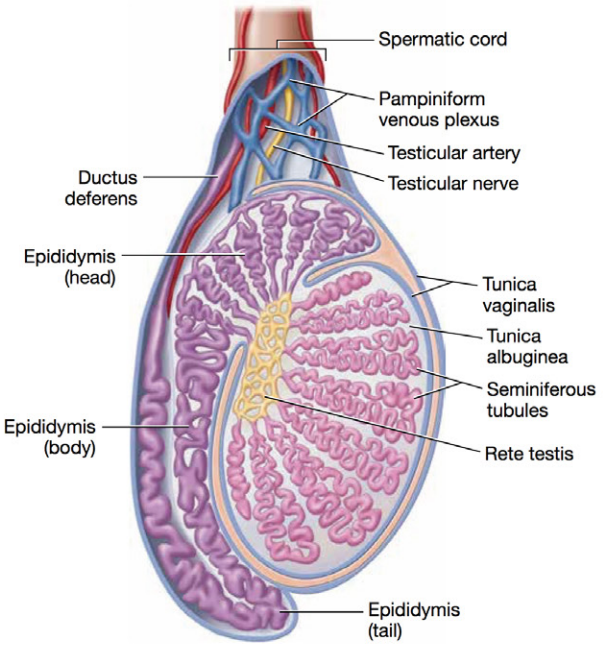

FIGURE **27.4** Midsagittal section through the testis.

The duct leaving the ampulla merges with a duct leaving a gland called the **seminal vesicle**. Together, the merged ducts form a short passage known as the **ejaculatory duct**. This duct passes through a gland on the inferior surface of the urinary bladder—the **prostate gland** (PRAW-stayt—be sure not to call it the "prostrate"). Here its contents drain into the first segment of the urethra, the **prostatic urethra**. Recall from the urinary unit that the prostatic urethra becomes the **membranous urethra** as it exits the prostate, and then becomes the **spongy urethra** as it enters the corpus spongiosum of the penis. The urethra terminates at the tip of the penis at the external urethral orifice.

The male reproductive tract includes three exocrine glands: the previously mentioned prostate gland and seminal vesicles, and a set of two small glands located at the root of the penis called the **bulbourethral glands** (bul-boh-yoo-REETH-ruhl;

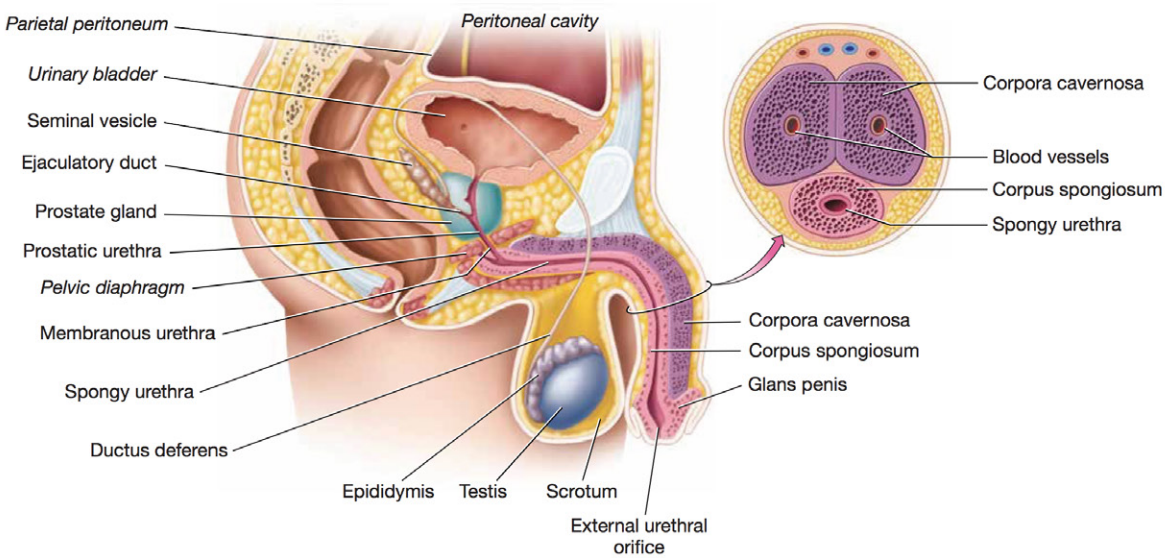

FIGURE **27.5** Midsagittal section through the male pelvis.

Figs. 27.5 and 27.6). The seminal vesicles and the prostate gland together produce about 90 percent of the volume of **semen,** a fluid that contains chemicals to nourish and activate sperm. The bulbourethral glands produce an alkaline secretion released prior to the release of sperm during ejaculation.

The **penis** is the male copulatory organ. It is composed of three erectile bodies: the single **corpus spongiosum** (KOHR-pus spun-jee-OH-sum) and the paired, dorsal **corpora cavernosa** (kohr-POHR-uh kah-ver-NOH-suh). The corpus spongiosum, which surrounds the spongy urethra, enlarges distally to form the **glans penis.** All three bodies consist of vascular spaces that fill with blood during an erection.

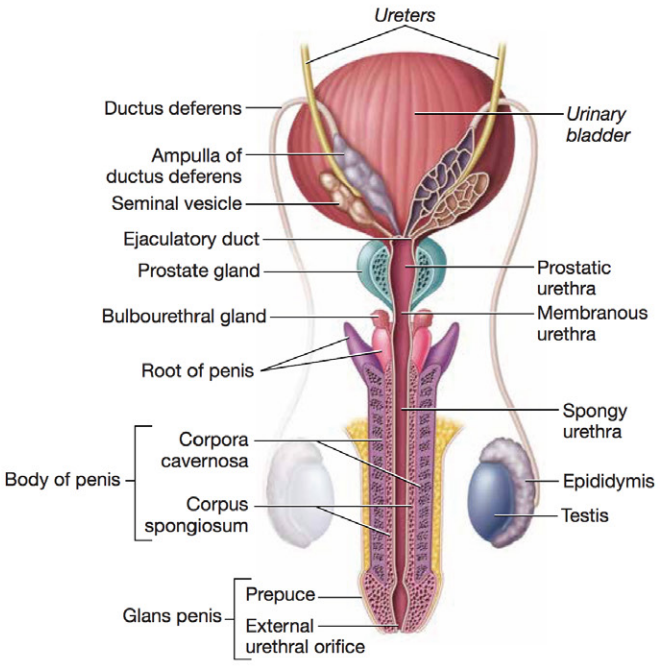

FIGURE **27.6** Posterior view of the male reproductive system with a frontal section of the penis.

Procedure 1 Model Inventory of the Male Reproductive System

Identify the following structures of the male reproductive system on models and diagrams using your textbook and this unit for reference. As you examine the anatomical models and diagrams, record the name of the model and the structures you were able to identify on the model inventory in Table 27.2. When you have completed the activity, answer Check Your Understanding questions 1 and 2 (p. 735).

1. Scrotum
2. Cremaster muscle
3. Spermatic cord
   a. Testicular artery
   b. Pampiniform venous plexus
   c. Inguinal canal
4. Testes
   a. Tunica vaginalis
   b. Tunica albuginea
   c. Seminiferous tubules
   d. Rete testis
5. Epididymis (head, body, tail)
6. Ductus deferens
7. Seminal vesicle
8. Ejaculatory duct
9. Prostate gland
10. Urethra
    a. Prostatic urethra
    b. Membranous urethra
    c. Spongy urethra
    d. External urethral orifice
11. Bulbourethral glands
12. Penis
    a. Corpus spongiosum
       (1) Glans penis
    b. Corpora cavernosa

TABLE **27.2** Model Inventory for the Male Reproductive System

Model/Diagram	Structures Identified

Exercise 27-2

Female Reproductive Anatomy

MATERIALS

- ❑ Female reproductive models
- ❑ Human torso models

The female reproductive organs are located in the pelvic cavity, with the exception of the almond-shaped **ovaries**, which are found in the peritoneal cavity (Figs. 27.7 and 27.8). The ovaries are the female gonads, which produce **oocytes** (OH-oh-syt′z) that travel through the reproductive tract to be fertilized. Oocytes are located within small sacs in the ovary called *follicles* that sit in the outer region of the ovary, the *ovarian cortex*. The inner region of the ovary, where we find primarily blood vessels, is the *ovarian medulla*.

Each ovary is held in place by several ligaments, including the **ovarian ligament**, which attaches the ovary to the uterus; a sheet of connective tissue called the **broad ligament**, which anchors it to the lateral pelvic wall (the part of the broad ligament attached to the ovary is called the *mesovarium*); and the **suspensory ligament**, which attaches the ovary to the postero-lateral pelvic wall. Notice in Figure 27.7 that the suspensory ligaments also carry with them the ovaries' blood supply.

The duct system of the female reproductive system begins with the **uterine tube**. The uterine tube is not directly connected to the ovary. For this reason, when an oocyte is released from the ovary, it is actually released into the pelvic cavity and the uterine tube must "catch" it and bring it into the tube. This is accomplished by fingerlike extensions of the tube called **fimbriae** (FIM-bree-ay) that wrap around the ovary. The next region of the uterine tube is the wide **infundibulum**, followed by the **ampulla**, and finally the **isthmus**, where it joins the uterus. Like the ovaries, the uterine tubes are anchored by the broad ligament (a segment called the *mesosalpinx*).

The uterine tubes join the superolateral portion of the **uterus** (YOO-ter-us), which is the organ in which a fertilized ovum implants, and in which a conceptus develops. As you can see in Figure 27.8, the uterus is situated posterior to the urinary bladder and anterior to the rectum. It is held in place by several ligaments: the broad ligament anchors it to the anterior and lateral pelvis (a part called the *mesometrium*); the **round ligaments** anchor it to the anterior abdominal wall (visible in Figure 27.8); and the **uterosacral ligaments** (yoo-ter-oh-SAY-kruhl) anchor it posteriorly to the sacrum.

The uterus has three regions: the dome-shaped **fundus**, the central **body**, and the narrow **cervix**. The opening of the cervix is known as the **cervical os**. The uterine wall is quite thick, and its thickness changes as it progresses through the 28-day uterine cycle. There are three layers to the uterine wall: the inner epithelial and connective tissue lining called the **endometrium** (en-doh-MEE-tree-um), in which a fertilized ovum implants; the middle, muscular **myometrium** (my-oh-MEE-tree-um), composed of smooth muscle tissue; and the outermost **perimetrium** (pehr-ee-MEE-tree-um), which is composed of a serous membrane on the posterior uterus and connective tissue on the anterior uterus.

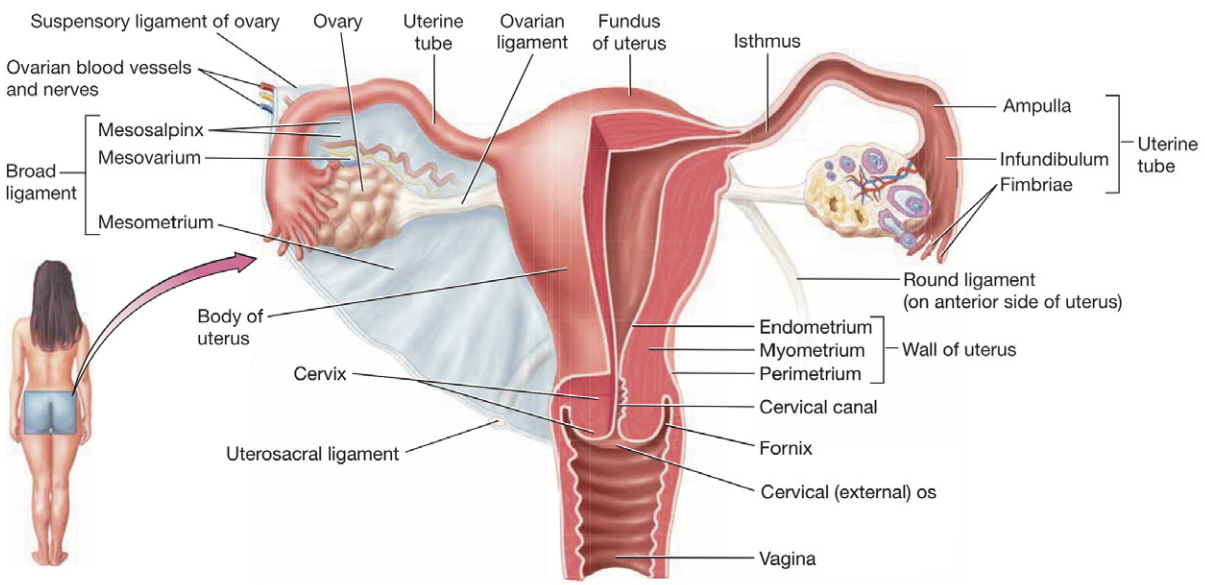

FIGURE **27.7** Posterior view of the female reproductive organs in a frontal section.

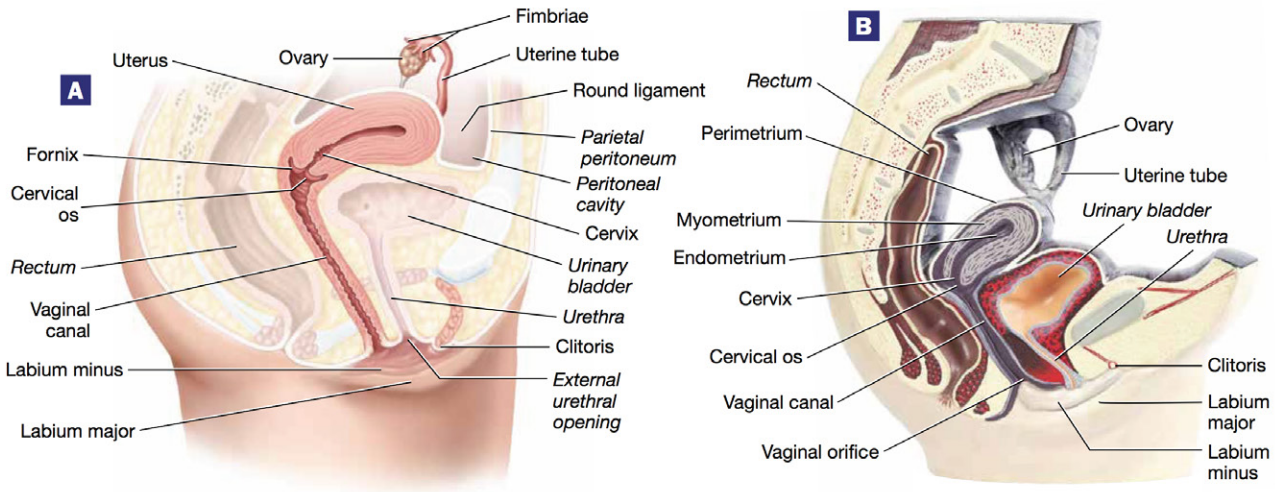

FIGURE **27.8** Midsagittal section of the female pelvis: (**A**) illustration; (**B**) anatomical model photo.

The **vagina** is a passage about 8–10 cm (3.1–3.9 in.) long that extends inferiorly from the cervical os and terminates at the **vaginal orifice**. The superior end of the vagina forms a recess around the cervical os called the **fornix**. Note that the vagina is entirely internal, although it is frequently and incorrectly referred to as the female's external genitalia. Flanking the vaginal orifice are the **greater vestibular glands**, which secrete mucus to lubricate the vaginal canal during coitus (Fig. 27.9).

The external genitalia of the female are collectively called the **vulva** (Fig. 27.9), although it is quite often incorrectly called the vagina. It begins with the **mons pubis** (MAHNS PYOO-biss), the rounded area over the pubic symphysis that is covered in pubic hair after puberty. Posterior to the mons pubis are the **labia majora** and **labia minora** (LAY-bee-ah; singular: labium major and minus, respectively). The labia majora are outer fatty skin folds that are analogous to the scrotum in the male; the thinner labia minora are folds of skin that enclose an area called the **vestibule**. Within the vestibule we find the urethral and vaginal orifices and the paraurethral glands. Anterior to the urethral orifice is the **clitoris** (KLIT-uhr-iss), which is composed of erectile tissue.

The **mammary glands** are not true reproductive organs—indeed, they are modified sweat glands and part of the integumentary system—but do have an associated reproductive function in milk production (Fig. 27.10; note that this figure shows a lactating mammary gland). Mammary glands are present in both males and females, but their anatomy is most appropriately discussed with female anatomy. Internally, mammary glands consist of 15–25 **lobes**, each of which has smaller **lobules** that contain milk-producing **alveoli**. Milk leaves the alveoli through **lactiferous ducts**, which join to form storage areas called **lactiferous sinuses**. Milk leaves through the **nipple**, which is surrounded by a darkly pigmented area called the **areola** (aehr-ee-OH-lah).

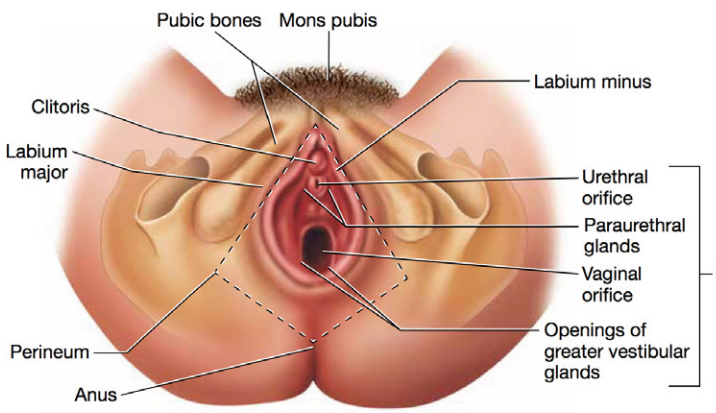

FIGURE **27.9** External female genitalia.

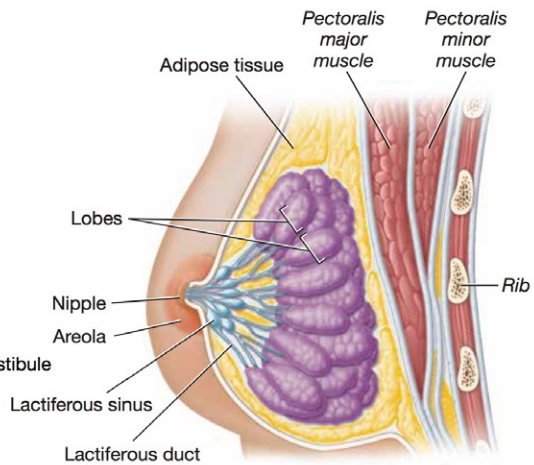

FIGURE **27.10** Structure of a lactating mammary gland.

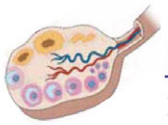

Procedure 1 Model Inventory of the Female Reproductive System

Identify the following structures of the female reproductive system on models and diagrams, using your textbook and this unit for reference. As you examine the anatomical models and diagrams, record the name of the model and the structures you were able to identify on the model inventory in Table 27.3. After you have completed the activity, answer Check Your Understanding questions 3 and 4 (pp. 735–736).

1. Ovary
   a. Ovarian follicles
   b. Ovarian cortex
   c. Ovarian medulla
   d. Ovarian ligament
   e. Broad ligament
   f. Suspensory ligament
2. Uterine tube
   a. Fimbriae
   b. Infundibulum
   c. Ampulla
   d. Isthmus
3. Uterus
   a. Round ligaments
   b. Uterosacral ligaments
   c. Fundus
   d. Body
   e. Cervix
      (1) Cervical os
   f. Layers
      (1) Endometrium
      (2) Myometrium
      (3) Perimetrium
4. Vagina
   a. Fornix
   b. Greater vestibular glands
5. Vulva
   a. Mons pubis
   b. Labia majora
   c. Labia minora
      (1) Vestibule
      (2) Urethral orifice
      (3) Vaginal orifice
   d. Clitoris
6. Mammary glands
   a. Lobe
   b. Lactiferous duct
   c. Lactiferous sinus
   d. Nipple
   e. Areola

TABLE **27.3** Model Inventory for the Female Reproductive System

Model/Diagram	Structures Identified

Exercise 27-3

Meiosis

MATERIALS

- ❑ Meiosis models
- ❑ Mitosis models
- ❑ Pop-bead chromosomes

As you may recall from Unit 4 (p. 69), somatic cells divide by a process called **mitosis**. During mitosis, a cell replicates its 23 pairs of homologous chromosomes and divides its DNA and organelles into two identical daughter cells (see Pre-Lab Exercise 27-4, p. 712, for a review of the stages). Each new diploid (DIH-ployd) cell is identical to the original cell. Gametogenesis (oogenesis and spermatogenesis), however, must proceed in a different way for two reasons:

1. If each gamete were to have the same genetic material, we all would be genetically identical to our siblings.
2. If each gamete were to have two pairs of chromosomes, our offspring would have four sets of chromosomes, and we would be tetraploid.

For these reasons, gametes undergo a process known as meiosis (MY-oh-sis) rather than mitosis.

In **meiosis**, gametes proceed through two rounds of cell division, and each gamete ends up with only one set of chromosomes, or a haploid cell (HAP-loyd). As you can see in Figure 27.11, meiosis begins in a manner similar to mitosis: The homologous chromosomes have replicated during the S phase of the cell cycle to yield pairs of sister chromatids. The cell then begins **meiosis I**. During middle to late prophase I, homologous chromosomes line up very tightly next to each other—a phenomenon called **synapsis**. Each synapse has two pairs of sister chromatids, and therefore the entire structure is called a **tetrad**. Within a tetrad, the homologous chromosomes overlap at points called **chiasmata** (ky-az-MAH-tah), or crossover. Near the end of prophase I, pieces of sister chromatids break and DNA is exchanged between homologous chromosomes at the points of crossover.

As meiosis I progresses, the homologous chromosomes line up along the equator of the cell, and then spindle fibers pull the homologous chromosomes to opposite poles of the cell. When telophase I and cytokinesis are complete, the resulting cells have 23 pairs of sister chromatids, and the amount of genetic material is halved because homologous chromosomes have been separated. The cells then proceed through the second round of division, **meiosis II**, during which the sister chromatids separate. At the end of telophase II, the result is four haploid gametes with only 23 individual homologous chromosomes.

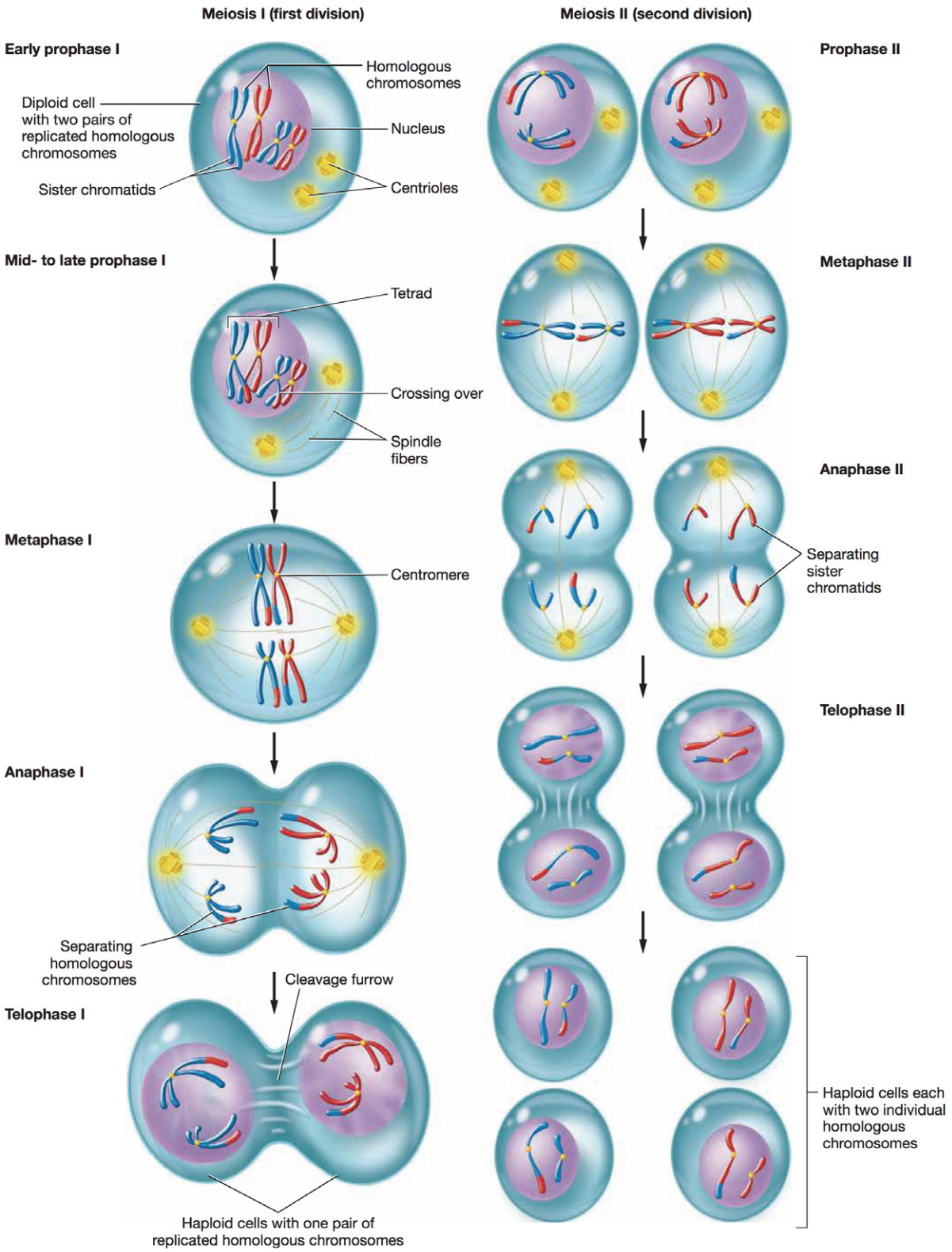

FIGURE **27.11** Meiosis. For simplicity, a cell with only two pairs of homologous chromosomes is shown.

Procedure 1 Model Meiosis

In the following procedure you will model meiosis with either a set of cell meiosis models or with pop-bead chromosomes. When you have completed the activity, answer Check Your Understanding question 5 (p. 736).

1. Obtain a set of meiosis and mitosis models.
2. Arrange the mitosis models in the correct order.
3. Now arrange the meiosis models in the correct order.
4. Compare the models of the two processes. List all differences you can see between meiosis and mitosis in the space provided.

27

Exercise 27-4

Histology of the Reproductive System

MATERIALS

- ❑ Testis slide
- ❑ Sperm slide
- ❑ Epididymis slide
- ❑ Ovary slide
- ❑ Light microscope
- ❑ Colored pencils

Gametogenesis is the process of producing sperm cells by the testes (spermatogenesis) and oocytes by the ovaries (oogenesis). **Spermatogenesis**, shown in Figure 27.12, begins with stem cells located at the outer edge of the seminiferous tubules along the basement membrane called **spermatogonia** (sper-mat-oh-GOH-nee-ah). Before puberty, these cells undergo repeated rounds of mitosis to increase their numbers. As puberty begins, some spermatogonia divide into two different cells—one cell that remains in the basement membrane as a spermatogonium and another cell that becomes a diploid **primary spermatocyte**. The primary spermatocyte then undergoes meiosis I and divides into two haploid **secondary spermatocytes** that migrate closer to the lumen of the tubule. The two secondary spermatocytes undergo meiosis II and give rise to four haploid **spermatids**.

Note in Figure 27.13 that most of the stages of spermatogenesis are identifiable on a microscope slide of the seminiferous tubules. On the inner edge of the tubule near the lumen are small, round cells with little cytoplasm. These are the spermatids. As we move to deeper layers of the tubule wall, we can see primary spermatocytes, and on the outer edge we can see the cuboidal spermatogonia. In between the tubules are small clusters of cells called **interstitial** (or *Leydig*) **cells**. These cells make **testosterone**, a hormone required for spermatogenesis to take place. Note that secondary spermatocytes are not visible in Figure 27.12.

Spermatids then move to the epididymis to mature into functional gametes by a process known as **spermiogenesis** (Fig. 27.14). Notice that the mucosal lining of the epididymis is pseudostratified columnar epithelium with long projections called **stereocilia**. These projections are nonmotile microvilli that help the sperm cells to complete spermiogenesis, absorb excess fluid, and pass nutrients to the developing cells. Notice also the smooth muscle cells lining the outside of the epididymis tubule, which function to propel the sperm cells along as they mature. By the time the cells reach the end of the epididymis, they are mature sperm cells (or spermatozoa) that contain three parts: the **head**, in which the DNA resides; the **midpiece**, which contains an axomere and mitochondria; and the **flagellum** (Fig. 27.15).

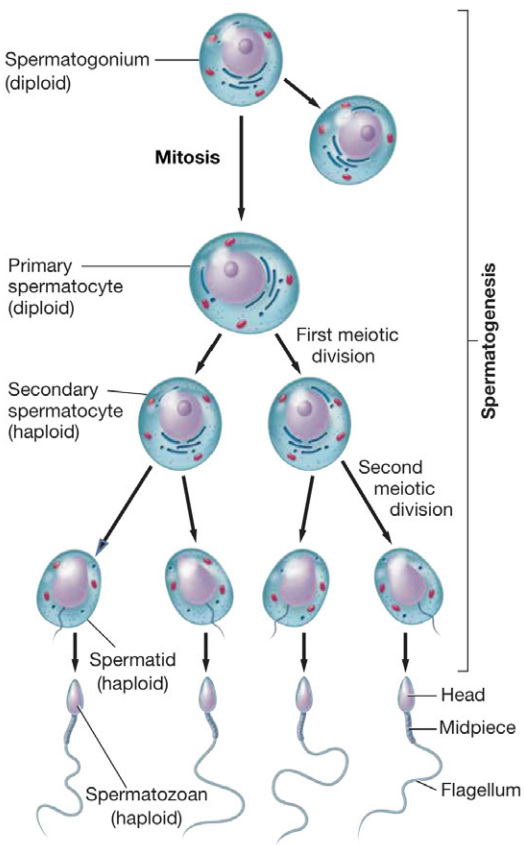

FIGURE **27.12** Spermatogenesis.

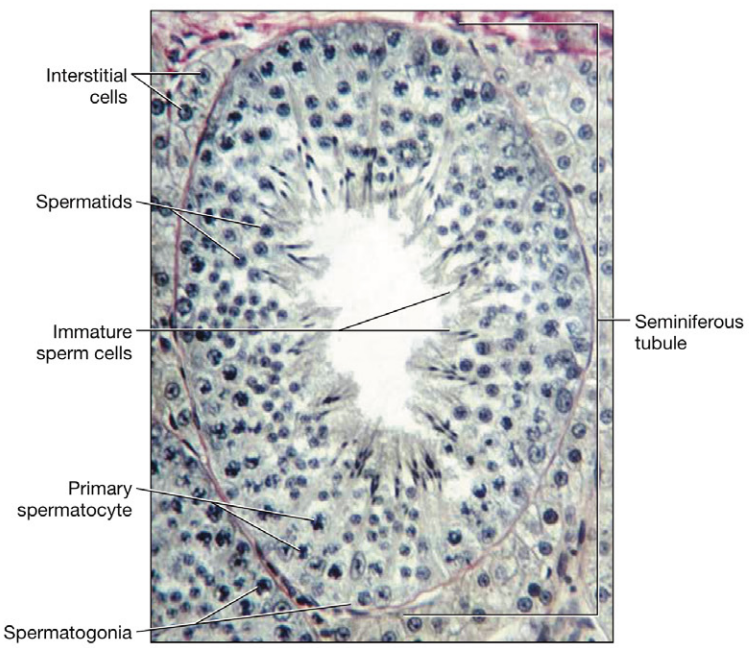

FIGURE **27.13** Seminiferous tubules, photomicrograph.

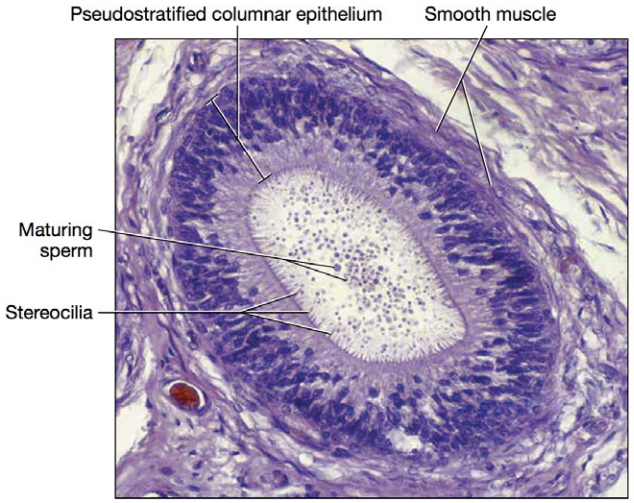

FIGURE **27.14** Epididymis, photomicrograph.

FIGURE **27.15** Mature sperm cells.

Like spermatogenesis, **oogenesis** (oh-oh-JEN-ih-sis) proceeds through meiosis to yield a haploid gamete, the **ovum** (Fig. 27.16). But the two processes differ in some notable ways:

- The number of oocytes is determined before birth. During the fetal period, stem cells called **oogonia** (oh-oh-GOHN-ee-uh) undergo mitosis, increasing their numbers to between five and seven million in each ovary. This is the total number of oogonia a woman will ever produce. Oogonia and later primary oocytes degenerate during the fetal period and childhood, and by the time a girl reaches puberty, between 80,000 and 400,000 primary oocytes remain in each ovary. This is in sharp contrast to spermatogenesis, which begins at puberty and continues throughout a male's lifetime.

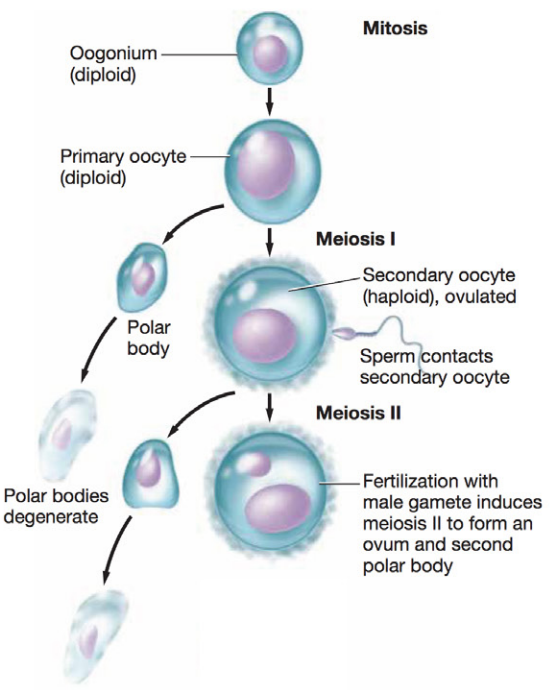

FIGURE **27.16** Oogenesis.

- Meiosis I begins during the fetal period but is arrested. Still during the fetal period, the oogonia become encased in a ring of cells known as a **primordial follicle,** then enlarge and become **primary oocytes** (see the ovary in Figure 27.17). The primary oocytes begin prophase I but are arrested at this stage. Meiosis I does not resume until puberty.
- The first meiotic division results in one **secondary oocyte** and one **polar body**. During childhood, some primordial follicles

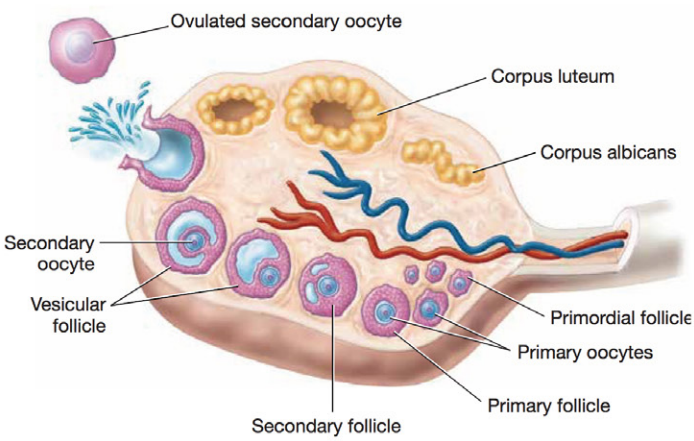

FIGURE **27.17** Ovary and ovarian follicles.

enlarge and begin developing into **primary follicles**. At puberty, rising levels of hormones, such as **estrogens**, trigger the beginning of the ovarian cycle, during which some primary follicles enlarge to become **secondary follicles**. As the cycle progresses, estrogens and follicle-stimulating hormone (FSH) usually trigger only one of the secondary follicles to continue growing. When the secondary follicle develops a large, fluid-filled space called the **antrum**, it is considered to be a **vesicular follicle**. Under the influence of luteinizing hormone (LH), the primary oocyte then completes meiosis I to produce a **secondary oocyte** and a small bundle of nuclear material called a **polar body**. The formation of a polar body allows the oocyte to conserve cytoplasm, which will have to sustain the newly formed conceptus for several days if fertilization occurs.

- The secondary oocyte undergoes meiosis II only if fertilization takes place. Rising levels of LH, called the *LH surge*, stimulate the secondary oocyte to begin meiosis II, but the process is arrested in metaphase II. The LH surge also stimulates rupture of the vesicular follicle and release of the secondary oocyte during ovulation. But the secondary oocyte only completes meiosis to form an ovum and a second polar body if fertilization occurs. If fertilization does not occur, the secondary oocyte degenerates.

You can easily see many of the different follicles on a slide of the ovary (Fig. 27.18). In addition, you can determine the stage of the oocyte by looking at the surrounding follicle: Primary oocytes are encased in primordial, primary, and secondary follicles, and secondary oocytes in vesicular follicles. Note that we cannot see oogonia in the ovary because these cells begin meiosis I and become primary oocytes during the fetal period.

A slide of the ovary also shows the endocrine gland that forms from the ruptured vesicular follicle, which is called a **corpus luteum** (KOHR-pus LOO-tee-um; Fig. 27.19). The corpus luteum secretes hormones, mostly **progesterone** as well as some estrogen, that maintain the endometrial lining in case fertilization takes place. When the corpus luteum stops secreting hormones, it is degraded by macrophages, leaving behind a white scar known as the **corpus albicans**.

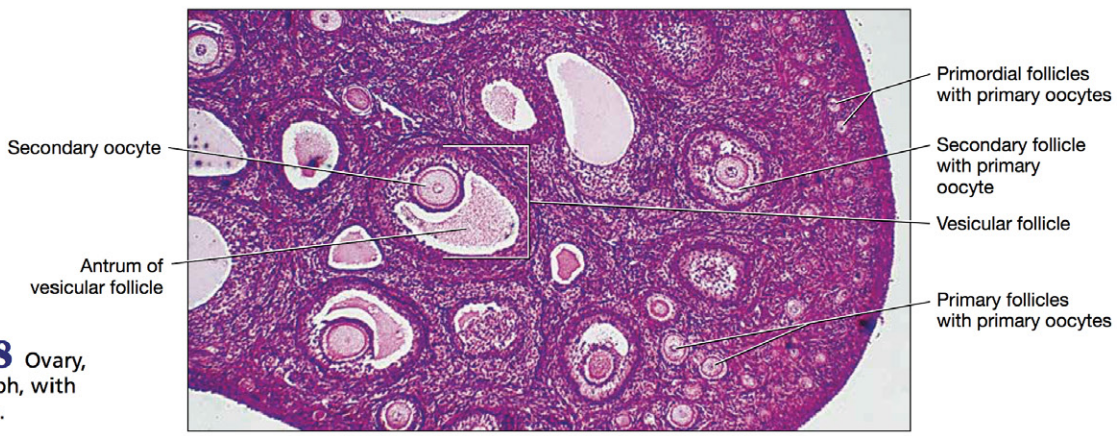

FIGURE **27.18** Ovary, photomicrograph, with ovarian follicles.

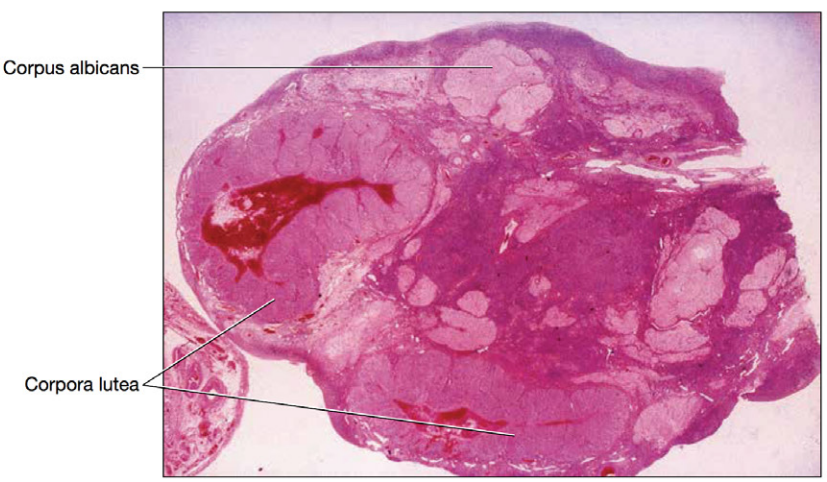

FIGURE **27.19** Ovary, photomicrograph, with corpus luteum and corpus albicans.

Procedure 1 Microscopy of Male Reproductive Structures

In this exercise you will examine prepared slides of the testes, epididymis, and a sperm smear. You will want to examine all three slides on high power, and you may wish to examine the sperm smear with an oil-immersion lens. Because sperm cells are so small, the slide will likely have a thread or some other marker to help you find them. As you examine the slides, use colored pencils to draw what you see, and label your drawings with the terms indicated. When you have completed the activity, answer Check Your Understanding question 6 (p. 736).

1 Testes

1. Seminiferous tubule
2. Spermatogonia
3. Primary spermatocytes
4. Spermatids
5. Interstitial cells

2 Epididymis

1. Maturing sperm
2. Stereocilia
3. Pseudostratified columnar epithelium
4. Smooth muscle

3 Mature sperm

1. Head
2. Midpiece
3. Flagellum

27

Procedure 2 Microscopy of the Ovary

Obtain a prepared slide of an ovary. Use your colored pencils to draw what you see, and label your drawing with the following terms. You will have the best results if you examine the slide on low power. Please keep in mind that you may have to examine multiple slides to see all the follicular stages. When you have completed the activity, answer Check Your Understanding question 7 (p. 736).

1. Primordial follicle
2. Primary follicle
   a. Primary oocyte
3. Secondary follicle
4. Vesicular follicle
   a. Secondary oocyte
   b. Antrum
5. Corpus luteum
   or corpus albicans



Procedure 3 Time to Trace!

In this exercise you will be tracing the gametes from their production in the male and female gonads to the point at which they meet to form a zygote. This tracing involves the anatomy of the male and female reproductive systems as well as the steps of gametogenesis.

STEP 1: Male Gamete

Trace the male gamete from its earliest stage—the spermatogonium in the seminiferous tubule—through the stages of spermatogenesis to a mature sperm. Then trace the mature sperm cell through the male reproductive tract until it exits the body and enters the uterine tube of the female reproductive tract. Trace the pathway using Figure 27.20, and also fill in the space provided.

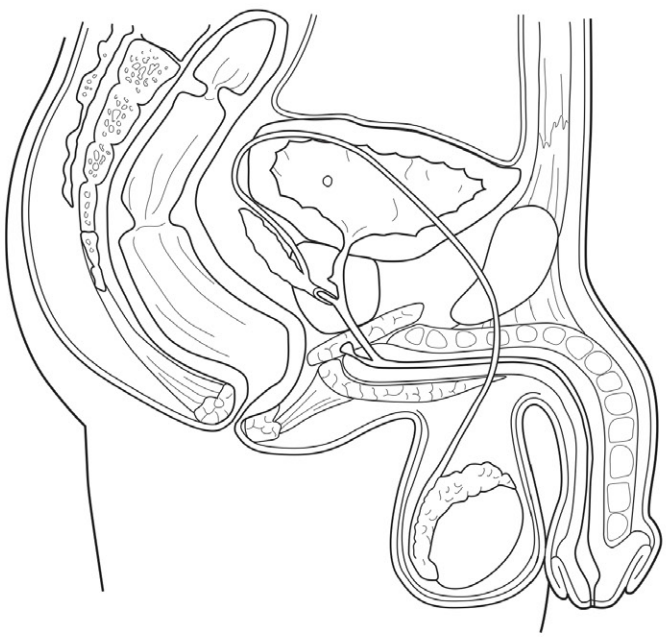

FIGURE **27.20** Male reproductive tract.

Start: Spermatogonium _____

_____

_____

_____

_____

_____

_____

_____ **End:** Uterine tube

STEP 2: Female Gamete

Trace the female gamete from its earliest stage, the oogonium in a primordial follicle, to the time at which it is ovulated and enters the uterine tube. Trace the pathway using Figure 27.21, and also fill in the space provided.

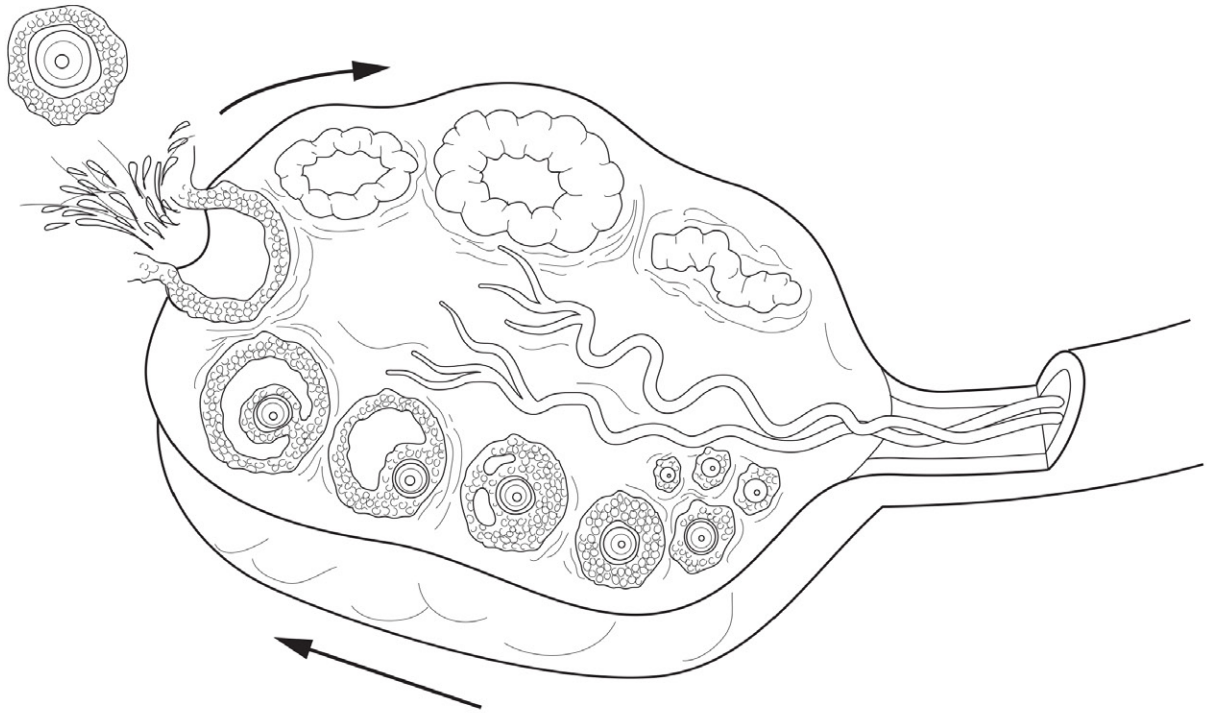

FIGURE **27.21** Ovary and ovarian follicles.

Start: Oogonium _____

_____

_____

_____

_____

_____

_____

_____ **End:** Uterine tube

27

Name _____

Section _____ Date _____

UNIT 27 REVIEW

Check Your Recall

1 Label the following structures on Figure 27.22.

- ❑ Cremaster muscle
- ❑ Ductus deferens
- ❑ External inguinal ring
- ❑ Pampiniform venous plexus
- ❑ Scrotum
- ❑ Spermatic cord
- ❑ Testicular artery

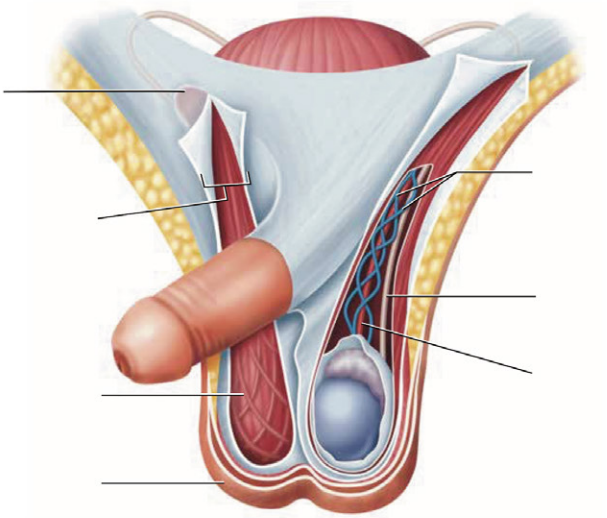

FIGURE **27.22** Male reproductive anatomy.

2 Label the following structures on Figure 27.23.

- ❑ Epididymis (head)
- ❑ Epididymis (tail)
- ❑ Rete testis
- ❑ Seminiferous tubules
- ❑ Tunica albuginea
- ❑ Tunica vaginalis

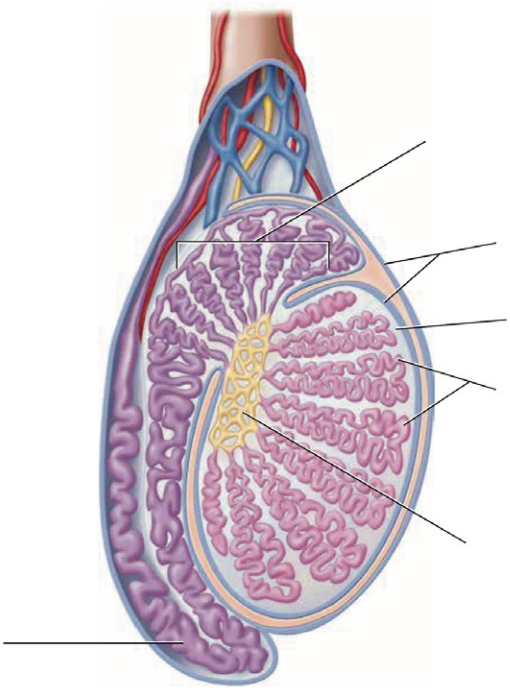

FIGURE **27.23** Midsagittal section through the testis.

3 Label the following structures on Figure 27.24.

- ❑ Corpora cavernosa
- ❑ Corpus spongiosum
- ❑ External urethral orifice
- ❑ Glans penis
- ❑ Membranous urethra
- ❑ Prostate gland
- ❑ Seminal vesicle
- ❑ Spongy urethra

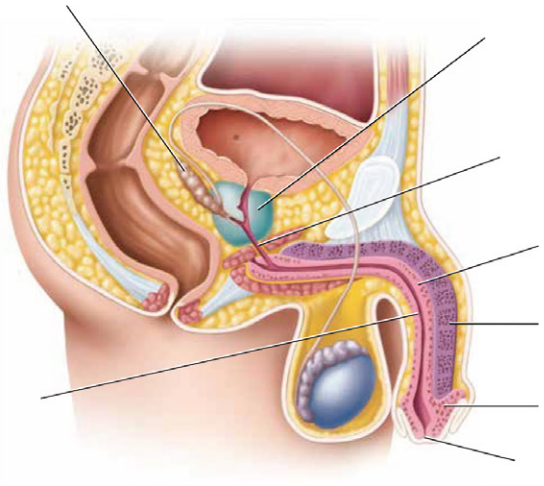

FIGURE **27.24** Midsagittal section through the male pelvis.

4 Label the following structures on Figure 27.25.

- ❑ Broad ligament
- ❑ Cervical os
- ❑ Cervix
- ❑ Endometrium
- ❑ Fimbriae
- ❑ Fornix
- ❑ Fundus of uterus
- ❑ Myometrium
- ❑ Ovarian ligament
- ❑ Perimetrium
- ❑ Uterine tube
- ❑ Vaginal canal

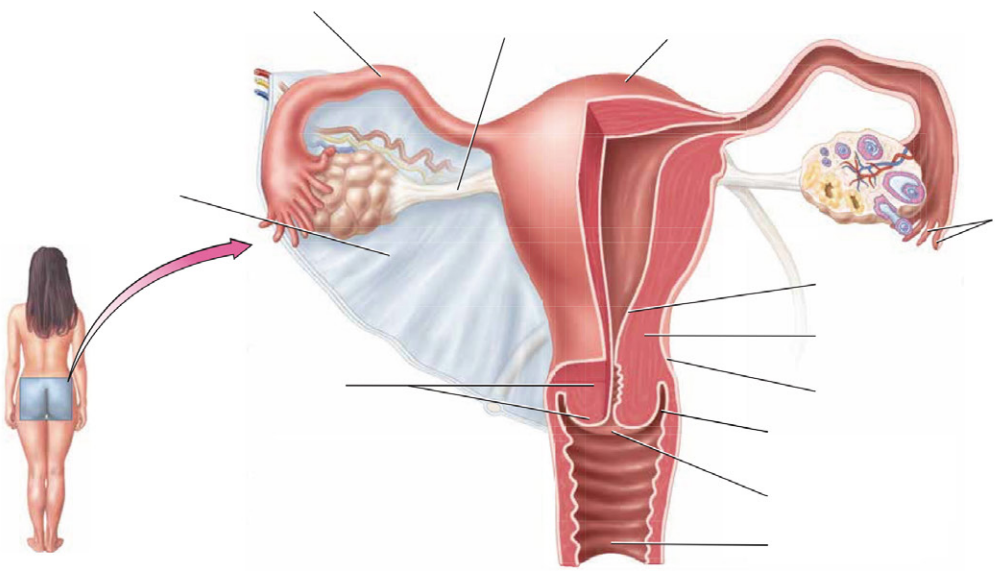

FIGURE **27.25** Posterior view of the female reproductive organs.

Name _____

Section _____ Date _____

5 Label the following structures on Figure 27.26.

- ❑ Adipose tissue
- ❑ Areola
- ❑ Lactiferous duct
- ❑ Lactiferous sinus
- ❑ Lobe
- ❑ Nipple

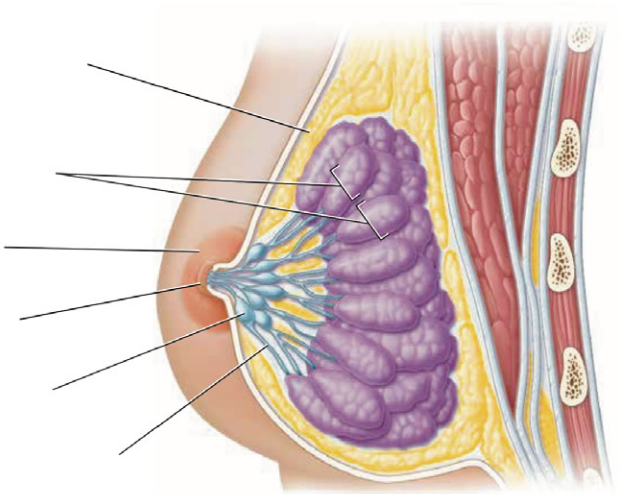

FIGURE **27.26** Structure of the lactating mammary gland.

6 *True/False:* Mark the following statements as true (T) or false (F). If the statement is false, correct it to make it a true statement.

_____ a. Gametes result from two rounds of cell division.

_____ b. Meiosis results in diploid cells.

_____ c. Homologous chromosomes overlap at points called chiasmata or crossover.

_____ d. The DNA replicates prior to the start of meiosis II.

7 Number the following events of spermatogenesis in the proper order, with number 1 next to the first event and number 5 next to the final event.

_____ Primary spermatocytes undergo meiosis I to yield two secondary spermatocytes.

_____ Spermatids migrate to the epididymis to undergo spermiogenesis.

_____ The two secondary spermatocytes undergo meiosis II to produce four haploid spermatids.

_____ Spermatogonia divide into more spermatogonia and primary spermatocytes.

_____ Spermatogonia undergo repeated rounds of mitosis.

8 Describe the ways in which oogenesis differs from spermatogenesis.

9 The endocrine organ that forms from the ruptured vesicular follicle is called the

a. corpus albicans.
b. polar body.
c. corpus luteum.
d. stereocilium.

10 Label the following structures on Figure 27.27.

- ❑ Corpus albicans
- ❑ Corpus luteum
- ❑ Primary follicle
- ❑ Primary oocyte
- ❑ Secondary follicle
- ❑ Secondary oocyte
- ❑ Vesicular follicle

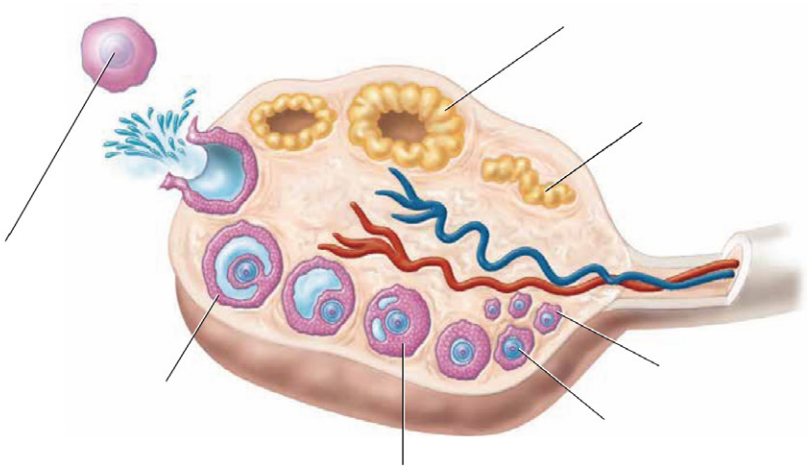

FIGURE **27.27** Ovary and ovarian follicles.

Name _____

Section _____ Date _____

REVIEW

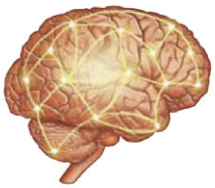

Check Your Understanding

Critical Thinking and Application Questions

1 During a vasectomy, the ductus deferens is sectioned and cauterized.

a How does this procedure render a male effectively sterile?

b Does a vasectomy stop sperm from being produced? Why or why not?

2 The condition *benign prostatic hypertrophy*, in which the prostate gland is enlarged, often results in urinary retention—the inability to completely empty the bladder. Considering the anatomy of the male genitourinary tract, explain this symptom.

3 Circe has been unable to get pregnant for two years in spite of fertility treatments, and so she is undergoing an exploratory surgical procedure to look for possible anatomical causes of her infertility. During the procedure, Circe's physician notes that her fimbriae are extremely short and face laterally rather than surrounding the ovaries. How does this explain her infertility?

4 One of the most common complaints of pregnant women is the need to urinate often. Explain this, considering the arrangement of the pelvic organs.

5 What would happen if DNA replication occurred again before meiosis II? Explain.

6 The condition *epididymitis*, which is generally caused by a bacterial infection, can result in damage to and scarring of the epididymis. Explain why this can lead to infertility.

7 If a sperm fertilized a polar body, do you think this would result in a viable offspring? Why or why not?

27

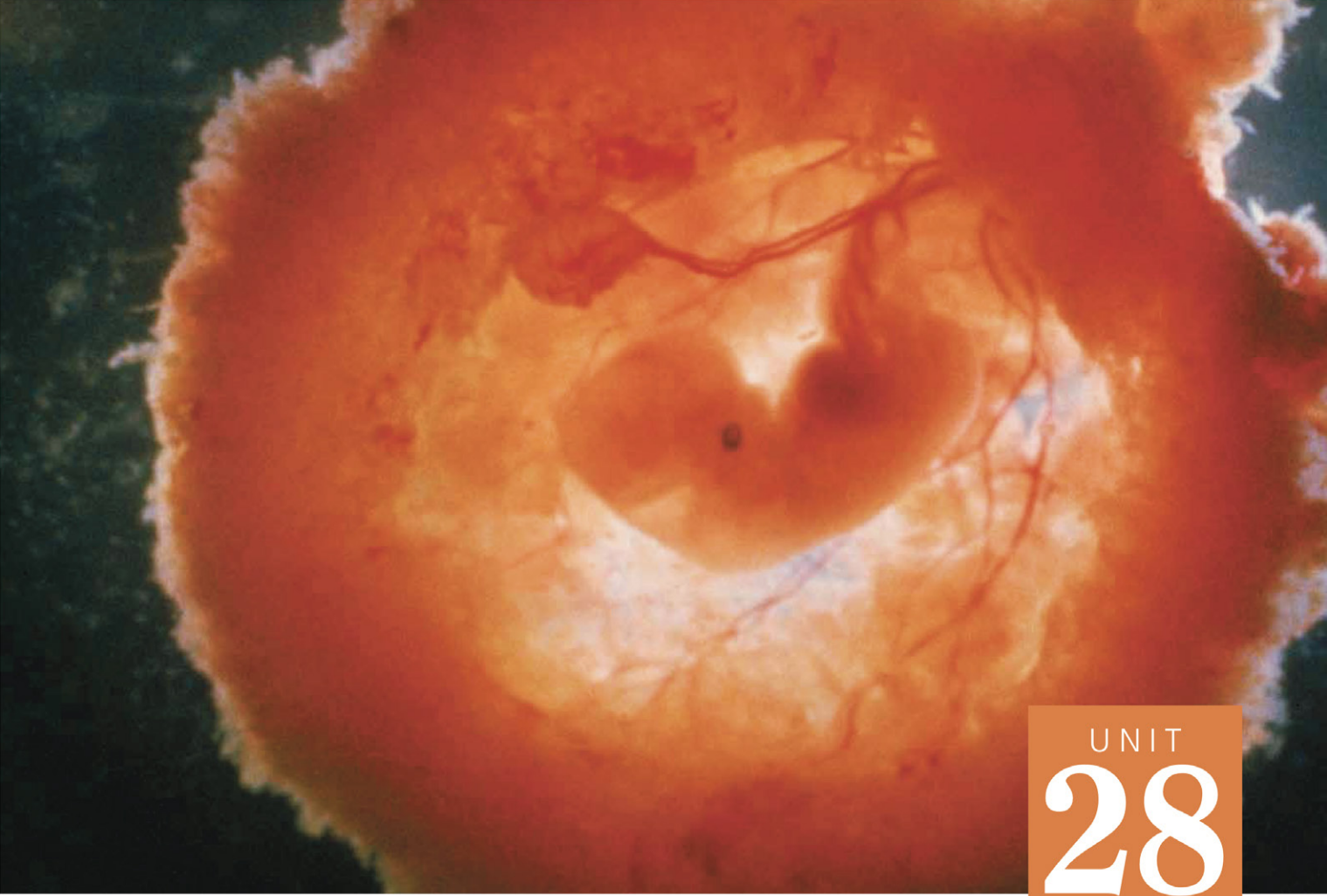

UNIT
28

Human Development and Heredity

Once you have completed this unit, you should be able to:

1. Trace a developing zygote (or conceptus) from fertilization to implantation.
2. Identify and describe structures and membranes associated with the fetus.
3. Identify and describe the stages of development and structures of the fetal circulation.
4. Define the terms phenotype and genotype and perform analyses to determine a subject's phenotype and genotype.
5. Describe dominant, recessive, and sex-linked traits and use Punnett squares to determine the probability of passing a trait to offspring.

Name _____ Section _____ Date _____

PRE-LAB EXERCISES

Complete the following exercises prior to coming to lab, using this lab manual and your textbook for reference.

Pre-Lab Exercise 28-1



Key Terms

You should be familiar with the following terms before coming to lab.

Term	Definition

Development

Fertilization _____

Zygote _____

Blastocyst _____

Embryo _____

Fetus _____

Fetal Structures

Chorion _____

Amnion _____

Placenta _____

Inheritance

Allele _____

Phenotype _____

Genotype _____

28

Name _____ Section _____ Date _____

Autosomal dominant _____

Autosomal recessive _____

Sex-linked trait _____

Pre-Lab Exercise 28-2

Fetal Membranes

Label and color the fetal membranes and structures in Figure 28.1 with the terms from Exercise 28-2 (p. 743). Use Exercise 28-2 and your text for reference.

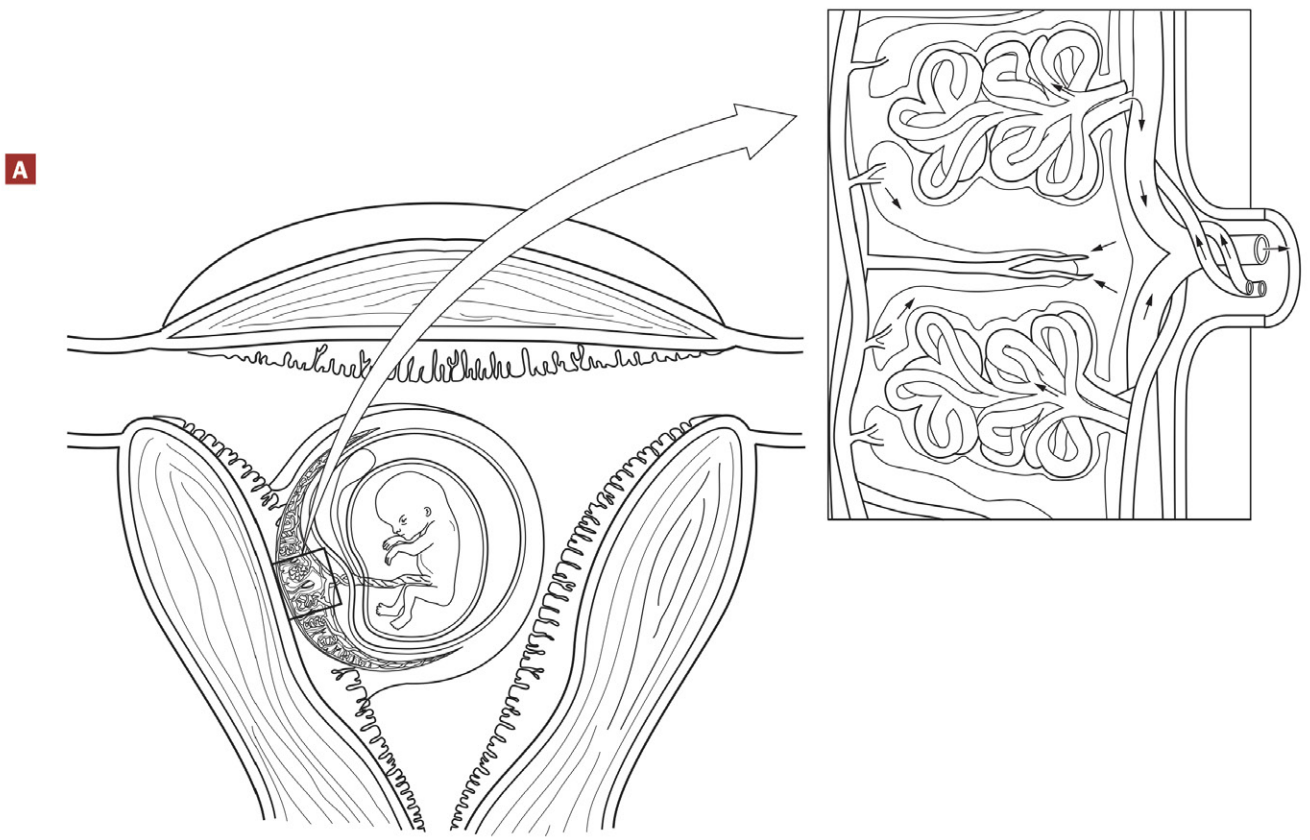

FIGURE **28.1** Embryo in membranes: (**A**) embryo in uterus; (**B**) chorionic villi.

Pre-Lab Exercise 28-3

Fetal Cardiovascular Anatomy

Label and color the structures of the fetal cardiovascular system in Figure 28.2 with the terms from Exercise 28-2 (p. 743). Use Exercise 28-2 and your text for reference.

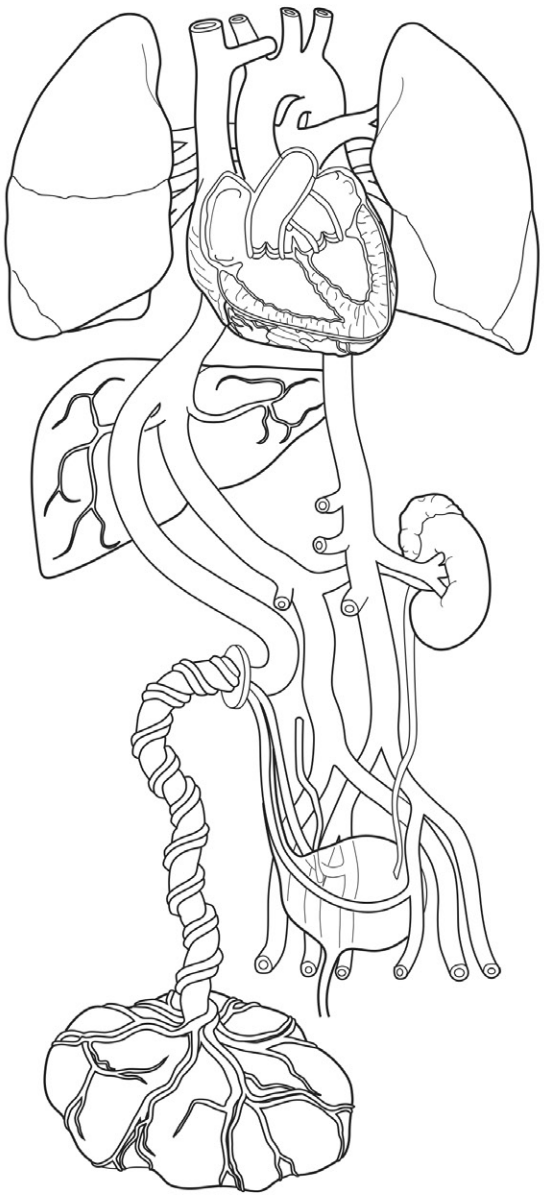

FIGURE **28.2** Fetal cardiovascular anatomy.

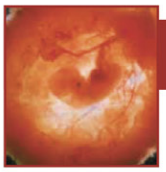

Human embryo at seven weeks of development.

EXERCISES

When two gametes—a sperm cell from a male and an ovum from a female—unite in a process known as **fertilization,** a diploid *zygote* (ZY-goh't) forms and the incredible process of development begins. In this unit we examine human development and the unique anatomy and structures of the developing human. We conclude by exploring the basics of **heredity**—the passing of traits from parents to offspring.

Exercise 28-1

Fertilization and Implantation

The first event in human development is fertilization, which generally takes place in the ampulla of the uterine tube when sperm cells encounter a secondary oocyte. Fertilization begins with a process called the **acrosomal reaction** (ak-roh-ZOH-muhl), in which the acrosomes in the heads of the sperm release digestive enzymes by exocytosis. The acrosomal enzymes digest the *corona radiata* and the *zona pellucida*, the secondary oocyte's outer coverings.

When the zona pellucida has been cleared, the head and midpiece of a single sperm enter the oocyte. Note that although mitochondria from the sperm cell (in the midpiece) enter the secondary oocyte, they are destroyed. For this reason, offspring have only maternal mitochondria.

As the sperm cell enters, the secondary oocyte completes meiosis II, yielding an ovum and a second polar body. The sperm and ovum nuclei swell to become **pronuclei**, and their nuclear membranes rupture. The two sets of exposed chromosomes then fuse to form a single-celled structure called a **zygote** (Fig. 28.3).

The zygote, also called a **conceptus** (kun-SEPT-uhs), undergoes multiple changes during the period of time known as **gestation,** the 40-week period extending from the mother's last menstrual period to birth. The changes that the conceptus undergoes include an increase in cell number, cellular differentiation, and the development of organ systems.

The increase in cell number begins about 30 hours after fertilization as the zygote travels down the uterine tube. At this time a process called **cleavage** occurs, in which the cell undergoes a series of mitotic divisions to produce two cells,

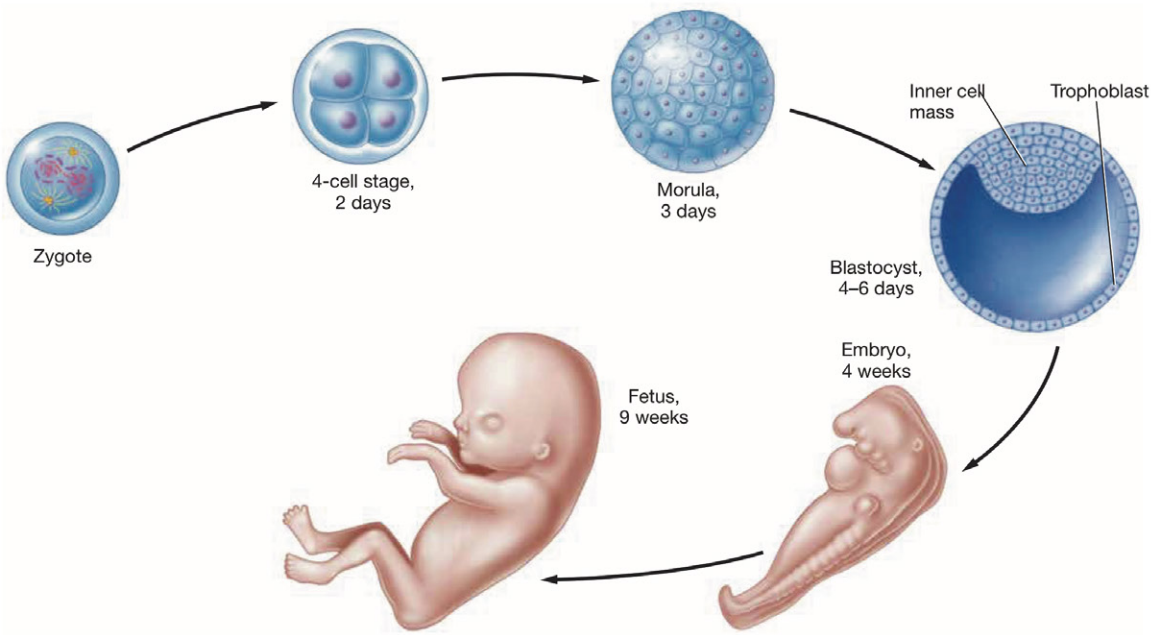

FIGURE **28.3** Stages of development.

then four, and so on. As cleavage begins, the conceptus starts to migrate from the ampulla of the uterine tube, through the isthmus to the uterus. At about day 3, the conceptus reaches the uterus as a 16-cell ball called a **morula** (MOHR-yoo-luh, which means "little mulberry"). The morula floats around the uterus for another 2 to 3 days and continues to divide until it becomes a hollow sphere called a **blastocyst** (BLAST-oh-sist). Notice in Figure 28.3 that the blastocyst has two populations of cells: the rounded **inner cell mass** (also called the *embryoblast*) and an outer layer of cells called the **trophoblast** (TROHF-oh-blast).

Around day 6, the blastocyst adheres to the endometrium and begins the process of **implantation**. The **implanting blastocyst** secretes digestive enzymes that eat away the endometrial lining, and the endometrium reacts to the injury by growing over and enclosing the blastocyst. The process of implantation is generally complete by the second week after fertilization, about the time a woman's menstrual period would begin if fertilization had not taken place.

Procedure 1 Time to Trace

Trace the events of development from fertilization to implantation. In your tracing, you will do two things: (1) describe the changes that the conceptus undergoes from the time that fertilization takes place until the time that it implants; and (2) trace the conceptus' location as these events occur. Trace the pathway using Figure 28.4, and also fill in the space provided. When you have completed the tracing, answer Check Your Understanding question 1 (p. 757).

Start: Sperm and secondary oocyte meet in uterine tube

End: Implanted blastocyst

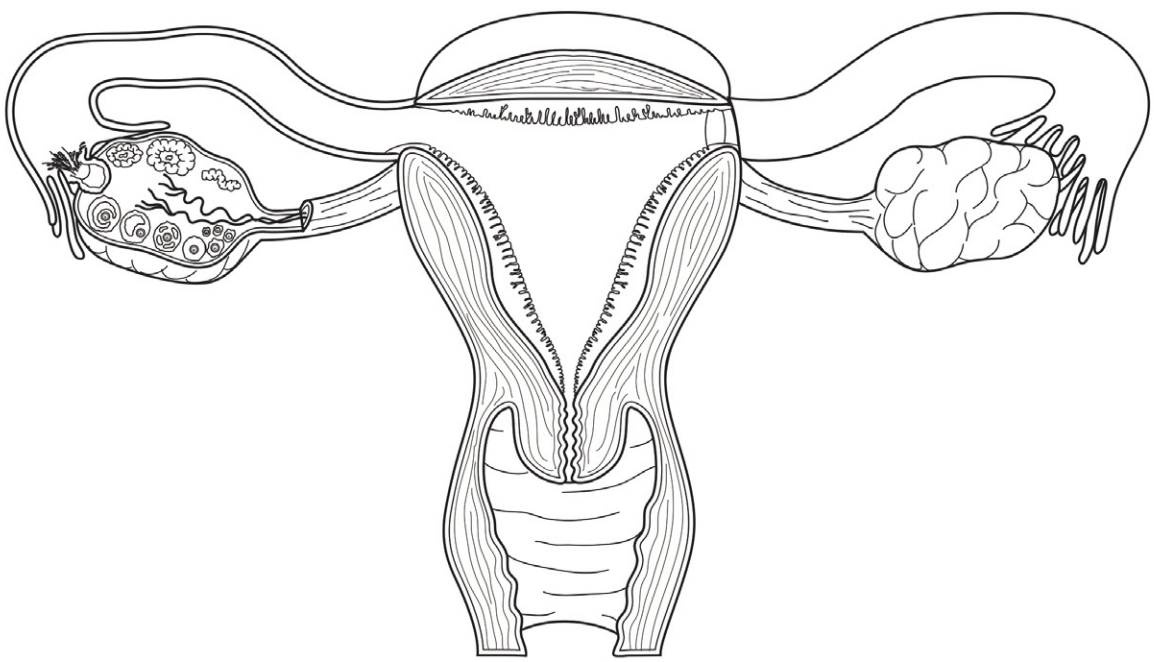

FIGURE **28.4** Female reproductive tract.

Exercise 28-2

Embryogenesis, Fetal Development, and Fetal Cardiovascular Anatomy

MATERIALS

- ❑ Sequence of embryonic development model
- ❑ Female reproductive system with fetus model
- ❑ Fetal circulation model

As the blastocyst implants, it begins undergoing a process known as **embryogenesis** (em-bree-oh-JEN-ih-sis) during which cellular differentiation takes place. During embryogenesis, the inner cell mass differentiates into three primary tissue layers known as **germ layers**, from which all other tissues arise. The outermost germ layer is called **ectoderm**, the middle germ layer is called **mesoderm**, and the innermost germ layer is called **endoderm**. These germ layers are formed by the end of the second week after fertilization, at which point the conceptus is considered an **embryo**.

The next six weeks of the embryonic period are marked by differentiation of the germ layers into rudimentary organ systems, formation of extraembryonic membranes, and the development of a structure called the *placenta* (Fig. 28.5). The first extraembryonic membrane to develop is the **yolk sac**, which serves as a source of cells for the digestive tract, the first blood cells and blood vessels, and *germ cells* (which are the precursors to gametes). Next, the innermost membrane called the **amnion** (AM-nee-ahn) develops. The amnion completely surrounds the conceptus and suspends it in **amniotic fluid** within the **amniotic cavity**.

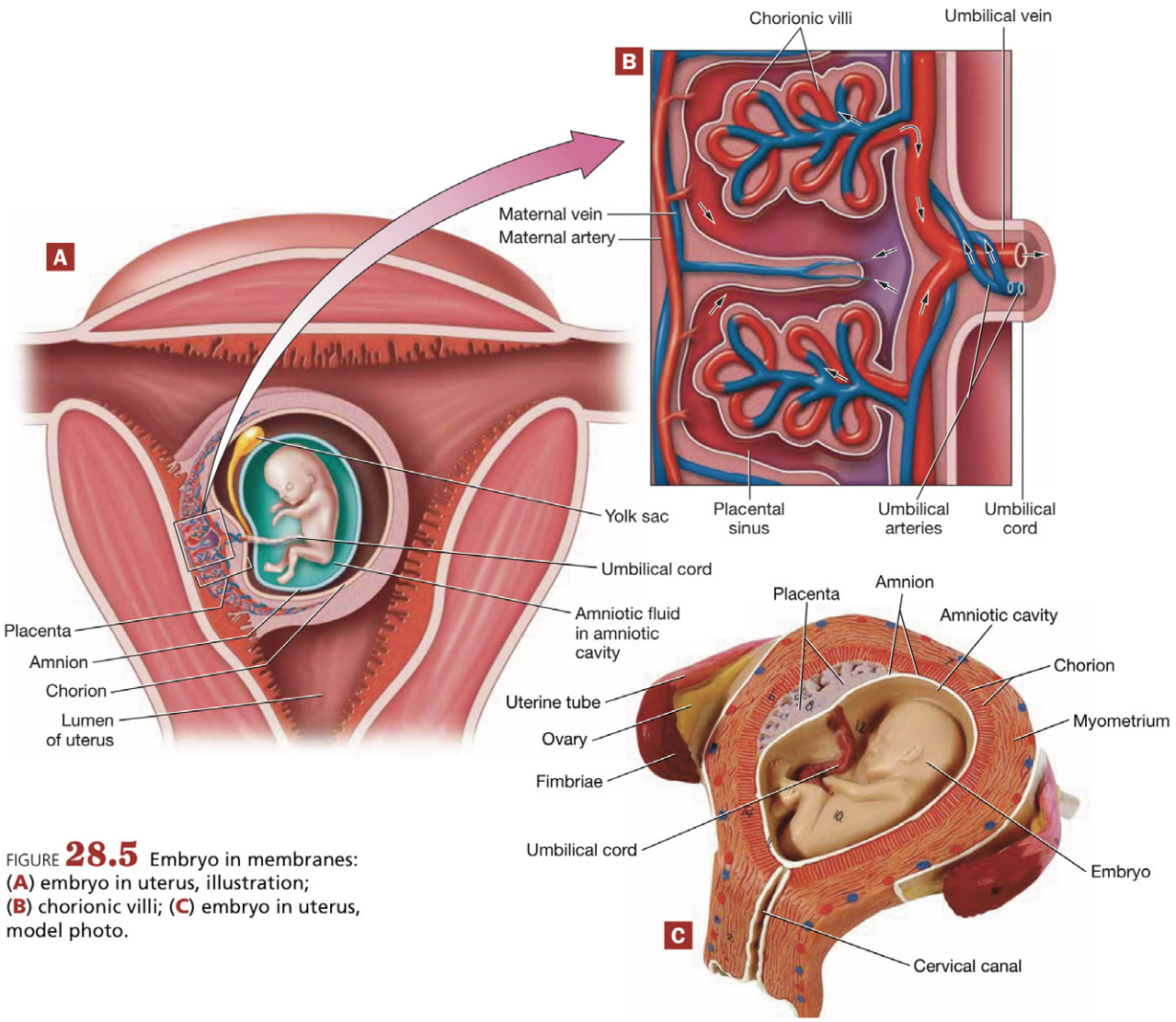

FIGURE **28.5** Embryo in membranes: (**A**) embryo in uterus, illustration; (**B**) chorionic villi; (**C**) embryo in uterus, model photo.

28

As the placenta and extraembryonic membranes form, the primitive organ systems develop. This process completes by the end of the eighth week after fertilization, at which point the conceptus is considered a **fetus**. For the duration of gestation, the organ systems become progressively more specialized and the fetus continues to grow and develop.

The **placenta** (plah-SIN-tuh) is the structure derived from embryonic and maternal tissues that provides oxygen and nutrients to the conceptus. It begins to form at day 11, when the trophoblast forms the outermost extraembryonic membrane, the **chorion** (KOHR-ee-ahn), the fetal portion of the placenta. As you can see in Figure 28.5B, the chorion develops elaborate projections called the **chorionic villi** (KOHR-ee-ahn-ik VILL-aye), which eat into uterine blood vessels to create the **placental sinus,** a space filled with maternal blood. Nutrients and oxygen delivered by *maternal arteries* diffuse from the placental sinus to the chorionic villi and are delivered to the conceptus by the large **umbilical vein.** Wastes are drained from the conceptus via the paired **umbilical arteries,** which drain into the chorionic villi, diffuse into the placental sinuses, and finally back into the *maternal veins*. The umbilical arteries and vein travel to and from the conceptus through the **umbilical cord.**

The fetus' cardiovascular system differs significantly from that of the neonate (Fig. 28.6). Within the fetal cardiovascular system are three **shunts** that bypass the relatively inactive liver and lungs and reroute the blood to other, more metabolically active organs. The three shunts include the following:

1. **Ductus venosus.** The **ductus venosus** (veh-NOH-suss) is a shunt that bypasses the liver. The umbilical vein delivers a small amount of blood to the liver but sends the majority of its oxygenated blood through the ductus venosus to the fetal inferior vena cava. This shunt closes about the time of birth and leaves behind a remnant called the *ligamentum venosum*.
2. **Foramen ovale.** The **foramen ovale** (oh-VAL-ay) is a hole in the interatrial septum that shunts blood from the right atrium to the left atrium. It allows blood to bypass the right ventricle and pulmonary circuit and go straight to the left heart and systemic circuit. The foramen ovale closes shortly after birth and leaves behind a dent in the interatrial septum called the *fossa ovalis*.
3. **Ductus arteriosus.** The **ductus arteriosus** (ahr-TEER-ee-oh-suss) is a vascular bridge between the pulmonary trunk and the aorta. It is a second shunt that allows blood to bypass the pulmonary circuit. When the ductus arteriosus closes after birth, it leaves behind a remnant called the *ligamentum arteriosum*.

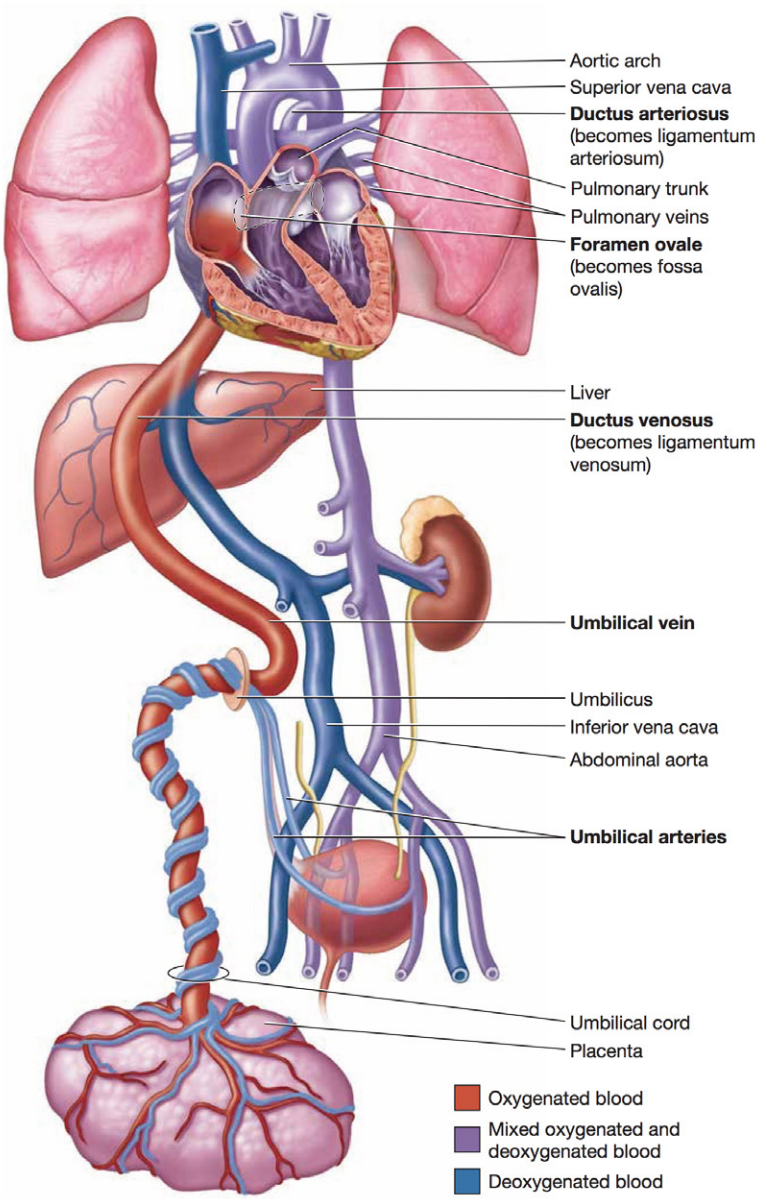

FIGURE **28.6** Fetal cardiovascular anatomy.

28

Notice how the pattern of oxygenation differs in the conceptus versus the neonate. The umbilical vein delivers oxygenated blood to the inferior vena cava, but the blood doesn't remain fully oxygenated for long: It soon begins to mix with deoxygenated blood coming in from the inferior vena cava, and it mixes with more deoxygenated blood from the superior vena cava when it enters the right atrium. For this reason, the blood traveling through the systemic arterial circuit of the conceptus is never fully oxygenated and is represented as purple in Figure 28.6 instead of red.

Procedure 1 Model Inventory of Fetal Development

Identify the following structures of development on models and diagrams, using your textbook and Exercises 28-1 (p. 741) and 28-2 for reference. As you examine the anatomical models and diagrams, record the name of the model and the structures you were able to identify on the model inventory in Table 28.1. When you have completed the activity, answer Check Your Understanding questions 2 through 4 (p. 757).

1. Stages of development
   a. Zygote
   b. Morula
   c. Blastocyst
      (1) Inner cell mass (embryoblast)
      (2) Trophoblast
   d. Implanted blastocyst
   e. Embryo
   f. Fetus
2. Fetal membranes
   a. Yolk sac
   b. Amnion
      (1) Amniotic cavity
      (2) Amniotic fluid
   c. Chorion
      (1) Chorionic villi
3. Vascular structures
   a. Placenta
      (1) Placental sinus
      (2) Maternal arteries and veins
   b. Umbilical cord
      (1) Umbilical vein
      (2) Umbilical arteries
   c. Ductus venosus
   d. Foramen ovale
   e. Ductus arteriosus

TABLE **28.1** Model Inventory for the Stages of Development and Fetal Structures

Model/Diagram	Structures Identified

Exercise 28-3

Heredity

MATERIALS

- ❑ Well plate
- ❑ Simulated blood of Ms. Rose, Ms. Magenta, Col. Lemon, Professor Purple, and Mr. Olive
- ❑ Anti-A, anti-B, and anti-Rh antisera
- ❑ PTC tasting papers
- ❑ Ishihara chart for color blindness

Heredity is defined as the passing of traits from parents to offspring. We refer to two properties of the cell when discussing traits:

1. **Phenotype** (FEE-noh-type) is the physical expression of a specific trait, such as hair color or blood type. Traits such as "blonde hair," "brown eyes," and "type A blood" refer to an individual's phenotype.
2. **Genotype** (JEE-noh-type) is the genetic makeup of an organism, or what a cell contains genetically. When someone performs DNA analysis, he or she is examining the genotype. We have two versions of each of our genes—one from the maternal side and one from the paternal side. The varying versions of a gene are known as **alleles** (uh-LEELZ). The genotype is described using letters to stand for each of the alleles that are inherited. For example, the allele that codes for free earlobes is written as *E*, whereas the allele that codes for attached earlobes is written as *e*. A person who inherits the same allele from both parents is said to be **homozygous** (hoh-moh-ZY-gus; e.g., the genotype *ee* is homozygous). A person who inherits different alleles from each parent is said to be **heterozygous** (het-er-oh-ZY-gus; e.g., the genotype *Ee* is heterozygous).

It is generally not possible to determine a person's precise genotype without doing DNA typing; however, if we know the phenotype, we can determine *possible* genotypes. Let's look at an example using blood groups:

- From each parent, we can inherit one of the following ABO alleles:
  - A allele: codes for A antigens.
  - B allele: codes for B antigens.
  - O allele: codes for neither A nor B antigen (please keep in mind that there is no "O" antigen).
- From each parent, we can inherit one of the following Rh factor alleles:
  - + allele: codes for the Rh antigen.
  - − allele: does not code for the Rh antigen.

We can put all of this information into a table to determine which phenotypes accompany the possible genotypes. Fill in the remainder of Table 28.2, following the pattern from the first two examples.

Notice from this table that we need only one of each of the A, B, and + alleles to express that phenotype. For this reason, an individual with an AO+− genotype will have an A+ phenotype in spite of having only one A allele and one + allele.

TABLE **28.2** Phenotype and Genotype

Genotype(s)	Phenotype
AA++, AA+−, AO++, AO+−	A+
AA−−, AO−−	A−
BB++, BB+−, BO++, BO+−	
	B−
OO++, OO+−	
	O−
	AB+
AB−−	

28

Procedure 1 Determining Paternity with Blood Typing

Blood typing is a simple and quick way to determine a child's possible paternity. Following is an example:

- Child's phenotype: B+
- Mother's phenotype: O−
- Potential Father 1's phenotype: AB+
- Potential Father 2's phenotype: O−

We start by first determining the possible genotypes of each person:

- Child's potential genotypes: BB++, BB+−, BO++, BO+−
- Mother's potential genotype: OO−−
- Father 1's potential genotypes: AB++, AB+−
- Father 2's potential genotype: OO−−

Now what we have to do is determine which alleles the child received from his mother. For the ABO gene, the mother can only give her child an O allele, because those are the only alleles she has to give. For the Rh gene, the mother can only give her child a − allele for the same reason. So, we can say definitively that the child received an O allele and a − allele from Mom.

The final step is to determine which allele(s) the child got from his father. The child has a B allele and a + allele that Mom couldn't have given him, so these B and + alleles must have come from Dad. Now let's look at both possible fathers' potential genotypes. We see that Father 1 does have a B allele but Father 2 does not. We see also that Father 1 has a + allele, but Father 2 does not. Therefore:

- We cannot exclude Father 1 as a potential father of the child.
- We *can* exclude Father 2 as a potential father of the child.

Notice here that we can't say for certain that Father 1 is indeed the child's father. All we can say is that he cannot be excluded and that further testing is necessary. We can say for certain, however, that Father 2 is completely excluded and does not need to be tested further.

For this procedure we return to our favorite cast of characters to sort out some sticky paternity issues using the genetics of blood typing. While investigating the murders from Unit 20 (Blood, pp. 540–542), the investigators discovered that Ms. Magenta was hiding a secret: She had a 20-year-old daughter named Ms. Rose. The investigators are uncertain as to Ms. Rose's paternity, but they are certain that there are three possible fathers—Col. Lemon, Mr. Olive, and Professor Purple. You must determine if any of these three men may be ruled out as Ms. Rose's father on the basis of their blood types.

Following is the procedure for testing the blood samples. When you have completed the activity, answer Check Your Understanding questions 5 and 6 (pp. 757–758).

1. Obtain a well plate, anti-A, anti-B, and anti-Rh antisera, and samples of blood from Ms. Magenta, Ms. Rose, Col. Lemon, Mr. Olive, and Professor Purple.
2. Place two drops of Ms. Magenta's blood into three separate wells.
3. Place one drop of anti-A antiserum into the first well and watch for a reaction. Record your results in Table 28.3.
4. Place one drop of anti-B antiserum into the second well and watch for a reaction. Record your results in Table 28.3.
5. Place one drop of anti-Rh antiserum into the third well and watch for a reaction. Record your results in Table 28.3.
6. Repeat this procedure with the blood of Ms. Rose, Col. Lemon, Mr. Olive, and Professor Purple. Record your results in Table 28.3.

Table **28.3** Blood Type Results

Blood Sample	Reaction with Anti-A?	Reaction with Anti-B?	Reaction with Anti-Rh?
Ms. Magenta			
Ms. Rose			
Col. Lemon			
Mr. Olive			
Prof. Purple			

7 Use your data from Table 28.3 to complete Table 28.4.

Table **28.4** Phenotypes and Potential Genotypes

Blood Sample	Blood Type (Phenotype)	Potential Genotypes
Ms. Magenta		
Ms. Rose		
Col. Lemon		
Mr. Olive		
Prof. Purple		

8 Interpret your results:

a Can any of the men be excluded as Ms. Rose's potential father? Explain.

b Can any of the men *not* be excluded as Ms. Rose's potential father? Explain.

Procedure 2 Completing Punnett Squares

The genetic effect known as **dominance** refers to the effect that different alleles have on an individual's phenotype. An allele that has the ability to suppress or mask another allele is known as the **dominant allele**, and the allele that is suppressed is known as the **recessive allele**. Dominant alleles are nearly always represented with capital letters and recessive alleles with lowercase letters.

The example of free and attached earlobes can be used to show the effect of dominant and recessive alleles on phenotype. The gene that codes for free earlobes is dominant and written as *E*, whereas the gene that codes for attached earlobes is recessive and written as *e*. Three different combinations of genes and two phenotypes are possible:

- ***EE***, or homozygous dominant individuals, will have free earlobes.
- ***Ee***, or heterozygous individuals, will have free earlobes.
- ***ee***, or homozygous recessive individuals, will have attached earlobes.

By using our knowledge of dominant and recessive alleles, we are able to predict the possible genotypes and phenotypes of a man and woman's offspring with a diagram called a **Punnett square**. In Figure 28.7 you can see an example of a Punnett square in which a man is heterozygous for free earlobes (*Ee*) and a woman is homozygous for attached earlobes (*ee*). As you learned in the reproductive unit, each gamete receives only one allele, and we can't know which allele the gamete will receive. For this reason, the Punnett square can only tell us the probability of having offspring with particular traits. In Figure 28.7, notice that we have a 50 percent chance of having offspring that are heterozygous with free earlobes (*Ee*) and a 50 percent chance of having offspring that are homozygous with attached earlobes (*ee*).

Now it's your turn to complete two simple Punnett squares. In the first Punnett square, you will determine the probability of a set of parents having offspring with

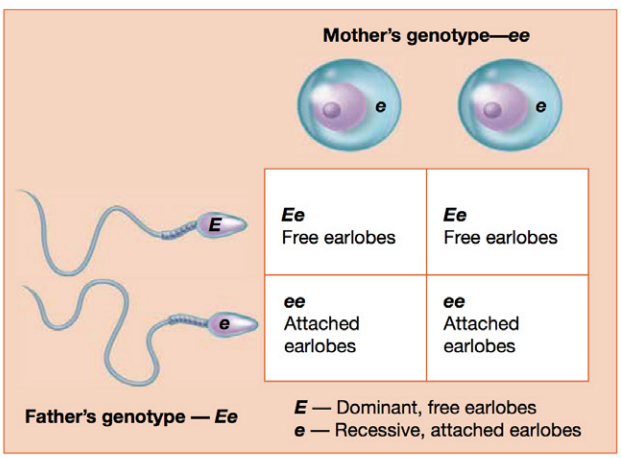

FIGURE **28.7** Punnett square for free and attached earlobes.

28

freckles. In the second, you will determine the probability of a set of parents having offspring with polydactyly (six fingers on one hand rather than five). When you have completed the Punnett squares, answer Check Your Understanding question 7 (p. 758).

1 Fill in the Punnett square in Figure 28.8 using the following:

- Dominant allele, codes for freckles (*F*)
- Recessive allele, does not code for freckles (*f*)
- Father's genotype: *Ff*
- Mother's genotype: *Ff*

What is the father's phenotype?

_____

What is the mother's phenotype?

_____

What is the probability the offspring will

a be homozygous dominant? _____

b be heterozygous? _____

c be homozygous recessive? _____

d have freckles? _____

e not have freckles? _____

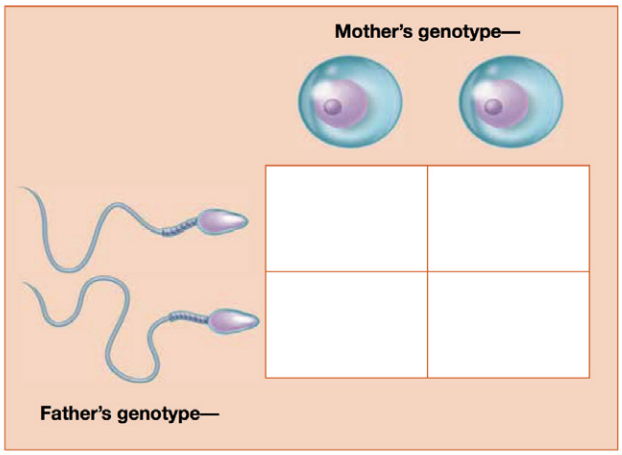

FIGURE **28.8** Punnett square.

2 Fill in the Punnett square in Figure 28.9 using the following:

- Dominant allele, codes for polydactyly (*P*; having six fingers on one hand)
- Recessive allele, does not code for polydactyly (*p*)
- Father's genotype: *PP*
- Mother's genotype: *pp*

What is the father's phenotype?

_____

What is the mother's phenotype?

_____

What is the probability the offspring will

a be homozygous dominant?

_____

b be heterozygous? _____

c be homozygous recessive?

_____

d have polydactyly? _____

e not have polydactyly? _____

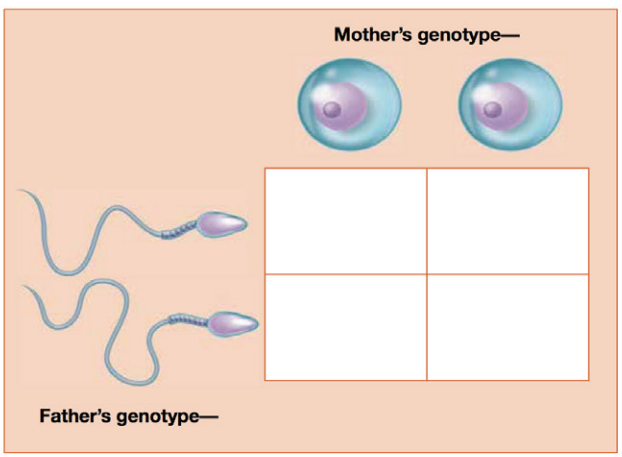

FIGURE **28.9** Punnett square.

Procedure 3 Testing the Ability to Taste PTC

A dominant allele found in about 75 percent of the population is one that determines the ability to taste **PTC** (phenylthiocarbamide), a bitter chemical found in foods such as Brussels sprouts and coffee. The remaining 25 percent of the population is homozygous for the recessive allele, *t*, and cannot taste PTC. In the following procedure, you will test your ability and that of your classmates to taste PTC. You will then pool your data to determine the percentage of tasters and nontasters in your class.

1. Obtain a piece of PTC paper and place it on your tongue.
2. If you can taste the PTC right away, you may remove the paper and dispose of it. If you do not taste it right away, leave the paper on your tongue for up to 1 minute. If you cannot taste the PTC after 1 minute, remove the paper and dispose of it.

   Were you able to taste PTC? _____
3. Pool the data from your class and record them:

   _____ Number of tasters

   _____ Percent of class that are tasters

   _____ Number of nontasters

   _____ Percent of class that are nontasters
4. Interpret your results:

   a. Which genotype(s) do the tasters have? _____

   b. Which genotype(s) do the nontasters have? _____

   c. How do the results from your class compare to the general population? _____

Procedure 4 Testing Color Vision

Recall that humans have 23 pairs of chromosomes: Chromosomes 1 through 22 are called **autosomes,** and the last pair consists of the two **sex chromosomes** known as **X** and **Y**. Females have the genotype XX and males have the genotype XY. Until now we have been discussing **autosomal traits,** or those that are passed down on autosomes. Certain traits, however, are passed down on the sex chromosomes, and these are known as **sex-linked traits**.

The inheritance of most autosomal traits is not influenced by sex; however, this is not the case with the inheritance of sex-linked traits. We can use the example of the blood disease hemophilia to see how this works. Hemophilia is the result of a recessive allele (*h*) found on the X chromosome. The normal allele is the dominant allele *H*. The possible genotypes with the resulting phenotypes include the following:

- A female with the genotype X^HX^H will *not* have the disease.
- A female with the genotype X^HX^h will *not* have the disease; however, she will be a "carrier" of the disease who is capable of passing the X^h allele to her offspring.
- A female with the genotype X^hX^h will have the disease.
- A male with the genotype X^HY will *not* have the disease.
- A male with the genotype X^hY will have the disease.

28

Notice here that because males have only one X chromosome, they require only one recessive allele on their single X chromosome to express the trait and have the disease. Conversely, females still require two recessive alleles to express the trait. For this reason, hemophilia is much more common in males than in females.

Another sex-linked trait is color blindness, or the inability to distinguish between certain colors. The allele for color blindness is a recessive allele on the X chromosome, X^b, and the allele for normal color vision is a dominant allele, X^B. The following procedure will allow you to test your vision for abnormalities in color vision, which may result from the presence of the X^b allele. The test uses a chart called an *Ishihara chart* that has a number embedded among a group of colored discs. A person with normal color vision will be able to read the number, whereas a person with color blindness will be able to see only randomly arranged colored dots. When you have completed the activity, answer Check Your Understanding question 8 (p. 758).

1 Obtain an Ishihara chart or use Figure 28.10. Hold the chart at a comfortable reading distance. Record what you see below:

_____

Was the test negative or positive for color blindness? (Note that "negative" means that your color vision was normal.)

_____



FIGURE **28.10** Ishihara chart.

2 Pool the results from your class and record the data:

_____ Number of females with normal color vision

_____ Number of females with impaired color vision

_____ Number of males with normal color vision

_____ Number of males with impaired color vision

3 Interpret your results:

a What is/are the genotype(s) for females with normal color vision? _____

b What is the genotype for females with impaired color vision? _____

c What is the genotype for males with normal color vision? _____

d What is the genotype for males with impaired color vision? _____

e How did the number of males with impaired color vision compare to the number of females with impaired color vision? Explain this finding.

_____

_____

Name _____

Section _____ Date _____

UNIT 28 REVIEW

Check Your Recall

1 *Matching:* Match the following terms with the correct definition.

_____ Chorion
_____ Blastocyst
_____ Fetus
_____ Acrosome
_____ Zygote
_____ Morula
_____ Amnion
_____ Embryo

A. A single-celled structure formed after fertilization
B. The end of a sperm that contains digestive enzymes
C. A hollow sphere of cells that implants into the endometrium
D. The conceptus from two weeks to eight weeks of development after fertilization
E. The innermost fetal membrane
F. The fetal membrane that contributes to the placenta
G. A 16-cell ball that reaches the uterus
H. The conceptus from nine weeks after fertilization to birth

2 Explain how oxygen, nutrients, and wastes are exchanged between maternal and fetal blood via the placenta.

3 *Fill in the blanks:* The outermost germ layer is the _____; the middle germ layer is the _____; and the innermost germ layer is the _____.

4 Label Figure 28.11 with the terms below.

- ❑ Aortic arch
- ❑ Ductus arteriosus
- ❑ Ductus venosus
- ❑ Foramen ovale
- ❑ Inferior vena cava
- ❑ Placenta
- ❑ Superior vena cava
- ❑ Umbilical arteries
- ❑ Umbilical vein

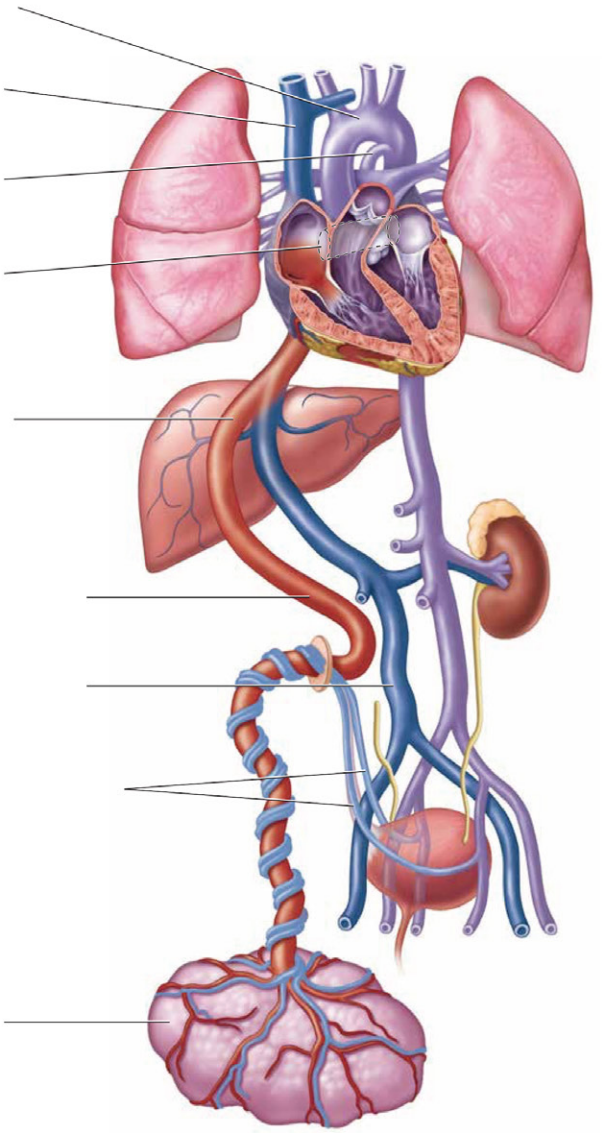

FIGURE **28.11** Fetal cardiovascular anatomy.

28

Name _____

Section _____ Date _____

5 Label Figure 28.12 with the terms below.

- ❑ Amnion
- ❑ Amniotic cavity
- ❑ Chorion
- ❑ Chorionic villi
- ❑ Maternal arteries and veins
- ❑ Placenta
- ❑ Placental sinus
- ❑ Umbilical arteries
- ❑ Umbilical vein
- ❑ Yolk sac

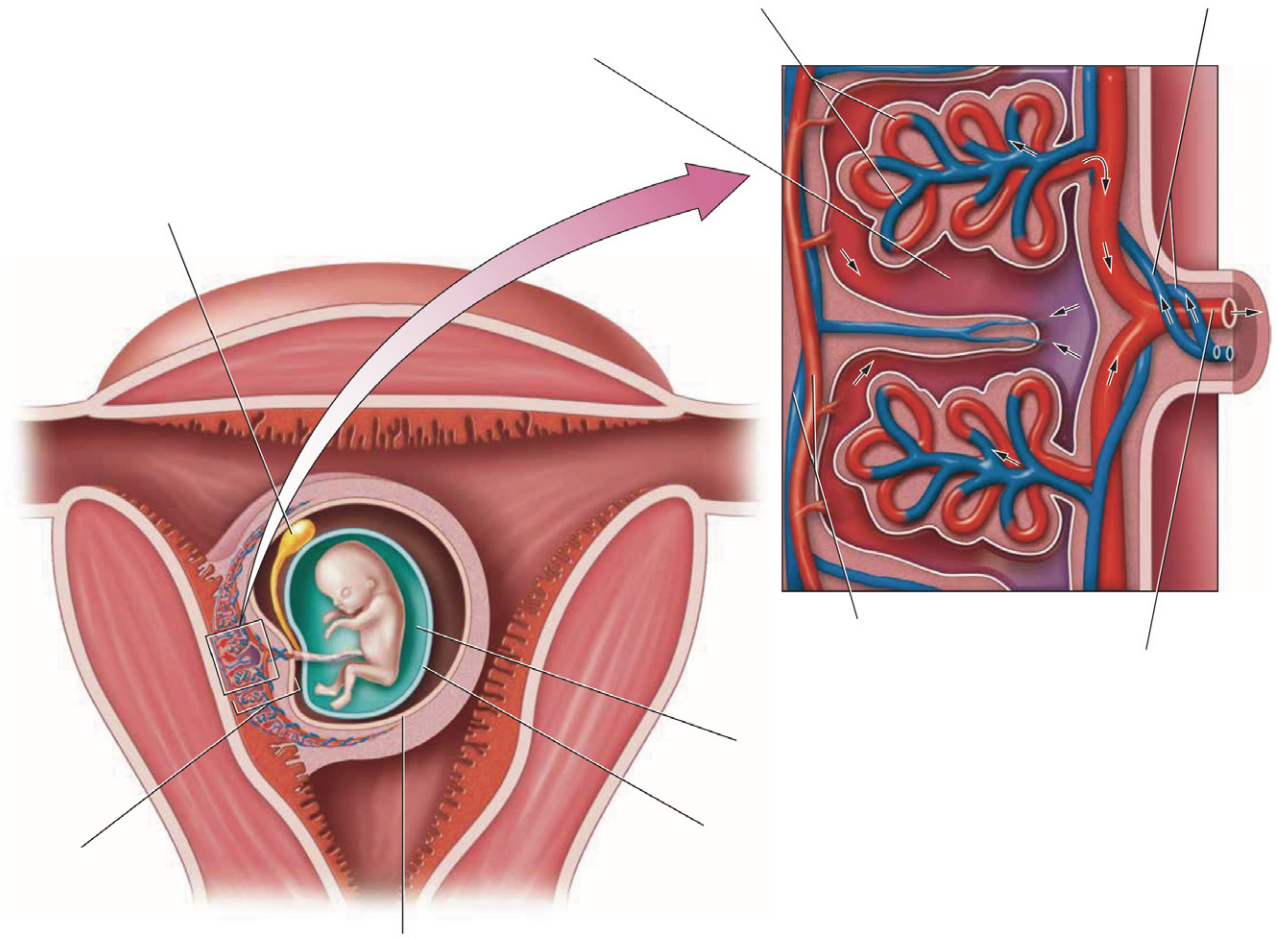

FIGURE **28.12** Embryo in membranes.

6 *True/False:* Mark the following statements as true (T) or false (F). If the statement is false, correct it to make it a true statement.

_____ a. The umbilical arteries carry oxygenated blood to the conceptus.

_____ b. The ductus arteriosus is a vascular shunt from the pulmonary trunk to the aorta.

_____ c. The ductus arteriosus and foramen ovale bypass the fetal lungs.

_____ d. The ductus venosus is a vascular bridge between the umbilical artery and the inferior vena cava.

7 The passing of traits from parents to offspring is known as

a. genotype.
b. phenotype.
c. heredity.
d. dominance.

8 *Fill in the blanks:* The _____ is the genetic makeup of an organism, and the _____ is the physical manifestation of a trait.

9 What is an allele?

_____

_____

10 *True/False:* Mark the following statements as true (T) or false (F). If the statement is false, correct it to make it a true statement.

_____ a. Sex-linked disorders tend to affect males more than females.

_____ b. The X and Y chromosomes are called autosomes.

_____ c. A person with two different alleles is homozygous for that trait.

_____ d. Blood typing cannot be used to conclusively prove paternity.

_____ e. A dominant allele will mask or suppress a recessive allele.

Name _____

Section _____ Date _____

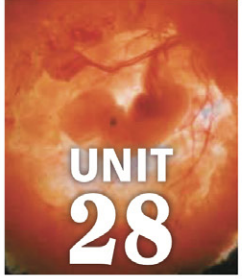

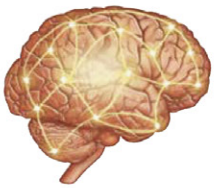

Check Your Understanding

REVIEW

Critical Thinking and Application Questions

1 Explain why diseases caused by mutations in mitochondrial DNA are inherited exclusively from one's mother.

2 When the ductus arteriosus fails to close after birth, it results in a condition called *patent ductus arteriosus*. Predict the signs and symptoms an infant would experience from this condition, and explain your reasoning.

3 Placental abruption is a condition in which the placenta is pulled away and separated from the wall of the uterus. Why could this prove life-threatening for both the mother and the fetus?

4 Active labor generally is considered to begin about the time the "water breaks." What is the "water," and which membranes rupture to release it? What could be the potential consequences if the membranes were to rupture too early?

5 Further investigation has revealed that Ms. Magenta is in fact *not* Ms. Rose's mother. Because of a freak baby-switching accident, Mrs. Feather is really Ms. Rose's biological mother. Mrs. Feather's blood type is determined to be B−. Col. Lemon, Professor Purple, and Mr. Olive remain Ms. Rose's potential fathers.

a What is Mrs. Feather's phenotype? What are her possible genotypes?

b Can any of the potential fathers be excluded? Explain.

6 In 1943, actor Charlie Chaplin was sued in court for child support by an actress named Joan Barry, who claimed Chaplin was the father of her child. Blood evidence was presented at the trial: Chaplin was blood type O, Barry was blood type A, and the child was blood type B (the Rh factor was not tested). Presented with this evidence, the jury ruled in favor of Barry, and ordered Chaplin to pay child support until the child's 21st birthday. Did the jury make the right decision? Why or why not?

7 Cystic fibrosis is an autosomal recessive genetic disorder that primarily manifests in the respiratory system. Amy undergoes genetic testing and finds that she is a carrier of the recessive gene (*f*, which codes for cystic fibrosis), meaning that she is heterozygous (*Ff*). Her husband Rory undergoes testing as well and learns that he is homozygous dominant (*FF*—*F* does not code for cystic fibrosis). They are seeking genetic counseling to find out their probability of having a child with cystic fibrosis. Use the Punnett square in Figure 28.13 to help them find answers.

What is the father's phenotype?

What is the mother's phenotype?

What is the probability the offspring will

a be homozygous dominant? _____

b be heterozygous? _____

c be homozygous recessive? _____

d have cystic fibrosis? _____

e not have cystic fibrosis? _____

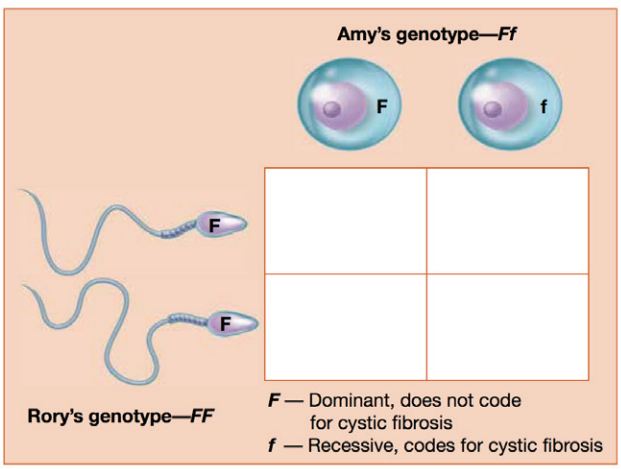

FIGURE **28.13** Punnett square.

8 You have just tested two patients' color vision, one male and one female, and found that both have color blindness. Can you conclusively determine the male's genotype? Can you conclusively determine the female's genotype? Explain why or why not for both patients. What are each patient's potential genotypes?

UNIT
29

The Big Picture of Human Anatomy and Physiology

Once you have completed this unit, you should be able to:

1. Find physiological connections between different organs and systems in the body.
2. Review the physiology of the organ systems we have covered.
3. Trace the pathway of the physiological response to a stimulus through various body systems.

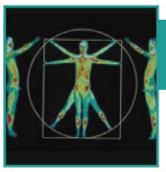

Thermographs based on Leonardo da Vinci's Vitruvian Man.

EXERCISES

At this point in our study of anatomy and physiology, we have examined each organ system and its individual organs and have studied how the parts fit together to make the whole. Along the way, we also have developed an appreciation for how the structure of the system, organ, tissue, and cell all follow the primary functions of each part. Now, in this last unit we will develop an appreciation for the big picture of how the organs work together to maintain homeostasis.

Exercise 29-1

Physiological Connections

MATERIALS

- ❑ Anatomical models: human torso
- ❑ Laminated outline of human body
- ❑ Water-soluble marking pens

In anatomy and physiology, the anatomical connections between organs and system are usually easy to see. All organs are connected by the cardiovascular system, bones are united by ligaments and cartilage, and accessory organs of the digestive system are joined to the alimentary canal by common ducts. However, what are sometimes difficult to see are the *physiological* connections that exist between all organs and organ systems.

One of your final tasks in this lab manual is to find physiological connections between seemingly unrelated groups of organs or tissues. The physiological connection between the salivary glands, stomach, and duodenum is easy to find, but the connection between the heart, bone, and thyroid may be a bit less obvious. Following are some hints, and an example, to make this task easier.

- Begin each exercise by listing the functions of each organ. Some functions are obvious, and others may require a bit of digging on your part. Take, for example, the skin. The skin has the obvious functions of protection and thermoregulation. But don't forget about its other tasks: The skin also synthesizes vitamin D when it is exposed to certain wavelengths of ultraviolet radiation, it excretes small amounts of metabolic wastes, and it serves immunological functions. These less-discussed functions are easy to overlook but are vitally important.
- Beware of the tendency to fall back to anatomical connections. When given the combination "lungs, kidneys, and blood vessels," you may be tempted to say that the lungs breathe in oxygen, delivered by the blood vessels to the kidneys. That's all true, but this is actually an anatomical connection. With some creative thinking on your part, you could come up with something much better. Remember that lung tissue makes angiotensin-converting enzymes, and, having said that, the connection between the blood vessels and the kidneys becomes more obvious (at least I hope it does).
- When in doubt, look to the endocrine system. Remember that many different organs, not just the organs discussed in the endocrine unit, make hormones. The heart, kidneys, and even adipose tissue all function in some respects as endocrine organs. For the organs that have a primary endocrine function, don't overlook some of the hormones they make. For example, the thyroid gland makes T3 and thyroxine but also calcitonin, which students tend to forget.

Here's an example of physiological connection:

Lungs, Kidney, Bone

Connection: The lungs have the function of *gas exchange*. When this exchange is inadequate, and oxygen intake is insufficient, the kidneys detect the decreased partial pressure of oxygen in the blood. The kidneys, in turn, make the hormone *erythropoietin*, which acts on the bone marrow to stimulate increased *hematopoiesis* and an increased rate of red blood cell maturation.

Wasn't that easy?

Now it's your turn.

Part 1: Skeletal Muscle, Parathyroid Glands, Bone

Hint: Think about how muscles contract.

Connection:

Part 2: Small Intestine, Lymphatic Vessels, Liver

Hint: How does the body process dietary lipids such as cholesterol?

Connection:

Part 3: Bone Marrow, Spleen, Liver

Hint: Think about the life cycle of erythrocytes.

Connection:

Part 4: Skin, Small Intestine, Parathyroid Glands

Hint: Think about other functions of the skin.

Connection:

Part 5: Sympathetic Nervous System, Pancreas, Liver

You're on your own for this one!!

Connection:

Exercise 29-2

Tracing—The Big Picture

Throughout this manual, you have done many different tracings of both anatomical and physiological processes. Let's now put many of those tracings together to get a bigger picture of how the body functions as a whole. We are going to trace the response to a stimulus you have likely experienced: an angry wasp coming toward you. The tracing has been broken up into parts so that it is easier to manage. As with other tracings, hints have been placed throughout to help you.

Part 1: Sight and Sound of Wasp to Perception and Interpretation in the Brain

In this first part, Professor Purple has just seen a wasp. You will trace the pathway light and sound takes from when he first sees and hears the wasp to the perception of these stimuli in the brain. You will trace the anatomical path the light and sound takes from the point where it enters his eye and ear to its interpretation in his brain. For the first pathway, don't forget about the liquids in the eyeball through which light passes.

Start (See Figures 15.7, p. 397, and 14.4, p. 369, for reference): See the wasp ➜ light enters the _____ ➜ _____ humor ➜ _____ ➜ _____ ➜ light hits the _____ ➜ hyperpolarization of the rods and cones ➜ propagation of _____ potential along the _____ nerve ➜ some axons cross over at the _____ ➜ _____ lobe ➜ perception and interpretation ➜ **End**

Start (See Figures 15.13, p. 403, for reference): Hear the wasp ➜ sound enters the _____ ➜ _____ canal ➜ _____ membrane ➜ malleus ➜ _____ ➜ _____ ➜ _____ window ➜ _____ ➜ _____ cells depolarize ➜ _____ potential propagated along the _____ ➜ _____ lobe ➜ perception and interpretation ➜ **End**

Part 2: Initiation of the Sympathetic Nervous System Response

Now let's trace Professor Purple's natural response to an angry wasp: fear. As you've learned, fear triggers activation of the sympathetic nervous system, which prepares the body for a fight or flight response.

Start (See Exercise 14-4, p. 381, for reference): Hypothalamus and cerebral cortex trigger the SNS response ➜ sympathetic postganglionic neurons release _____ onto target organs ➜ heart rate and force of contraction _____ ➜ smooth muscle in bronchioles _____ ➜ digestive and urinary functions _____ ➜ blood vessels to skeletal muscles _____ ➜ blood glucose _____ ➜ body primed for fight and flight ➜ **End**

Part 3: Sting and Inflammatory Response

In this next part of the exercise, poor Professor Purple has gotten stung by the wasp on his right hand. As with any tissue injury, a wasp sting leads to an inflammatory response, so you will be tracing the steps of this response.

Start (See Exercise 21-3, p. 567, for reference): Wasp stinger damages tissue ➜ damaged cells release _____ ➜ local blood vessels _____ ➜ capillary permeability _____ ➜ _____ (***Hint:*** a cell type) are attracted and activated ➜ _____ attract additional _____ (***Hint:*** another cell type) ➜ _____ ingest _____ ➜ warmth, redness, swelling, and pain of the inflammatory response ➜ **End**

Part 4: Ingestion and Delivery of Medication

Now Professor Purple has taken an acetaminophen tablet for the pain of his aching right hand. You will first trace the path the tablet takes through the organs of the alimentary canal to its absorption into the bloodstream. Next, you will trace its delivery to the lateral hand by arterioles and capillary beds via the radial artery. Remember that a substance absorbed molecule takes a long path to get to a systemic artery: It needs to go through a capillary bed, then through the hepatic portal system, then the systemic veins, next the heart and pulmonary circuit, and finally through the systemic arteries.

Start (See Figures 24.5, p. 630, 18.14, p. 481, 16.6, p. 428, and 18.6, p. 475, for reference): Ingested at the mouth ➜ _____ ➜ _____ ➜ _____ ➜ _____ ➜ enters the enterocyte ➜ diffuses into _____ ➜ _____ vein ➜ _____ vein ➜ _____ system ➜ _____ veins ➜ inferior vena cava ➜ _____ ➜ _____ ventricle ➜ _____ ➜ _____ artery ➜ _____ capillaries ➜ _____ ➜ _____ ➜ _____ ➜ ascending aorta ➜ _____ arch ➜ _____ ➜ _____ ➜ _____ ➜ _____ ➜ right radial artery ➜ **End**

Part 5: Excretion of the Medication

In this final part of the tracing, you are following the path Professor Purple's metabolized acetaminophen molecule takes as it leaves the body via the urinary system. You will start from the capillary beds of the liver, where the acetaminophen is metabolized, and trace it through the blood vessels to the kidneys. Once it reaches the kidneys, you will trace its pathway through the nephron and out of the body.

Start (See Figures 18.16, p. 484, 16.6, p. 428, 25.6, p. 671, and 25.10, p. 674, for reference): Capillary beds of the

hepatic portal system ➜ _____ veins ➜ _____ ➜

_____ atrium ➜ _____ ➜ _____ ➜

_____ artery ➜ _____ capillaries ➜ _____

➜ _____ ➜ _____ ➜ ascending aorta ➜ _____

arch ➜ _____ ➜ _____ ➜ _____

artery ➜ segmental artery ➜ _____ ➜ _____ ➜

_____ ➜ _____ arteriole ➜ filtration at the

_____ ➜ _____ ➜ _____ ➜

_____ tubule ➜ _____ ➜ _____

collecting duct ➜ papillary duct ➜ major and minor _____ ➜ _____

pelvis ➜ _____ ➜ _____ ➜ urethra ➜ **End**

Congratulations!

You've done what you may have thought was impossible—completed this manual! I truly hope it has been fun (at least a little!) and that you have enjoyed it as much as I have. Best wishes with your future plans, down whichever path they may take you.

Photo Credits

Unit 1

Opener: SPL/Photo Researchers
Fig. 1.6D: SPL/Photo Researchers
Fig. 1.9, Fig 1.10: Kent M. Van De Graaff and John Crawley, *A Photographic Atlas for the Anatomy and Physiology Laboratory,* 6E ©Morton Publishing
Fig. 1.13 A-B: Neil Borden/Photo Researchers
Fig. 1.13C: SPL/Photo Researchers
Fig. 1.21A: Edward Elliot/Photo Researchers
Fig. 1.21B: Scott Camazine/Photo Researchers
Fig. 1.21C: SPL/Photo Researchers

Unit 2

Opener: SPL/Photo Researchers
Figure 2.5: SPL/Photo Researchers
Figure 2.6: Justin Moore
Figure 2.7: SPL/Photo Researchers
Fig. 3.1: Courtesy of Olympus America

Unit 3

Opener: Rafe Swan/Photo Researchers
Fig. 3.1: Courtesy of Olympus America
Fig. 3.2: SPL/Photo Researchers

Unit 4

Opener: SPL/Photo Researchers
Fig. 4.4B: SPL/Photo Researchers
Fig. 4.7: GIPhotoStock/Photo Researchers
Fig. 4.9A-C: David Phillips/Photo Researchers
Fig. 4.11: Michael Abbey/Photo Researchers
Fig. 4.12: Stem Jems/Photo Researchers

Unit 5

Opener: SPL/Photo Researchers
Fig. 5.2A: Biophoto Assoc./Photo Researchers
Fig. 5.3B: Biophoto Assoc./Photo Researchers
Fig. 5.3D: Biophoto Assoc./Photo Researchers and Meckes/Ottawa/Photo Researchers
Fig. 5.4A: David Phillips/Photo Researchers
Fig. 5.4 B: Biophoto Assoc./Photo Researchers
Fig. 5.4C-D: SPL/Photo Researchers
Fig. 5.5A: Biophoto Assoc./Photo Researchers
Fig. 5.5B: Sci Photog/Photo Researchers
Fig. 5.5C: Spike Walker/Photo Researchers and SPL/Photo Researchers
Fig. 5.6A: Biophoto Assoc./Photo Researchers and SPL/Photo Researchers
Fig. 5.6B: Biophoto Assoc./Photo Researchers and David Phillips/Photo Researchers
Fig. 5.6C: Biophoto Assoc./Photo Researchers
Fig. 5.7A: Erin Amerman
Fig. 5.7B: Spike Walker/Photo Researchers
Fig. 5.7C: Chuck Brown/Photo Researchers
Fig. 5.8: SPL/Photo Researchers
Fig. 5.9: Biophoto Assoc./Photo Researchers
Fig. 5.10A: Eric Grave/Photo Researchers
Fig. 5.10B: SPL/Photo Researchers
Fig. 5.10C: Getty Images
Fig. 5.10D: Biophoto Assoc./Photo Researchers
Fig. 5.11: Spike Walker/Photo Researchers
Fig. 5.12A: Biophoto Assoc./Photo Researchers/So. Ill. Univ.
Fig. 5.12B: Biophoto Assoc./Photo Researchers/Sci Photog/Alvin Telser
Fig. 5.13A: Biophoto Assoc./Photo Researchers
Fig. 5.13B: Biophoto Assoc./Photo Researchers
Fig. 5.13C: Biophoto Assoc./Photo Researchers
Fig. 5.13D: Biophoto Assoc./Photo Researchers
Fig. 5.13E: Erin Amerman
Fig. 5.13F: SPL/Photo Researchers
Fig. 5.13G: Eric Grave/Photo Researchers
Fig. 5.13H: Spike Walker/Photo Researchers

Unit 6

Opener: SPL/Photo Researchers
Fig. 6.3: Biophoto Assoc./Photo Researchers
Fig. 6.6A: Garry DeLong/Photo Researchers
Fig. 6.6B: Gary Delong/Photo Researchers
Fig 6.7: Biophoto Assoc./Photo Researchers
Fig. 6.8: Fabrication Enterprises

Unit 7

Opener: SPL/Photo Researchers
Fig. 7.3: SPL/Photo Researchers
Fig. 7.6: Justin Moore
Fig. 7.8: A. Travelogue/Photo Researchers
Fig. 7.9A: Neil Borden/Photo Researchers
Fig. 7.9B: Biophoto Assoc./Photo Researchers

Unit 8

Opener: SPL/Photo Researchers
Fig. 8.4: VideoSurgery/Photo Researchers
Fig. 8.5: David Bassett/Photo Researchers
Fig. 8.6: Getty Images
Fig. 8.7: SPL/Photo Researchers
Fig. 8.8: VideoSurgery/Photo Researchers
Fig. 8.13A-B: Martin Shields/Photo Researchers
Fig. 8.21B: VideoSurgery/Photo Researchers
Fig. 8.23B: VideoSurgery/Photo Researchers
Fig. 8.27A-B: VideoSurgery/Photo Researchers
Fig. 8.28B: Kent M. Van De Graaff and John Crawley, *A Photographic Atlas for the Anatomy and Physiology Laboratory,* 6E ©Morton Publishing and VideoSurgery/ Photo Researchers
Fig. 8.29B: Kent M. Van De Graaff and John Crawley, *A Photographic Atlas for the Anatomy and Physiology Laboratory*, 6E ©Morton Publishing and VideoSurgery/ Photo Researchers
Fig. 8.42: SPL/Photo Researchers

Unit 9

Opener: Neil Borden/Photo Researchers
Fig. 9.6A: VideoSurgery/Photo Researchers

Unit 10

Opener: SPL/Photo Researchers
Fig. 10.3: SPL/Photo Researchers
Fig. 10.10: SPL/Photo Researchers

Unit 11

Opener: SPL/Photo Researchers
Fig. 11.7: SPL/Photo Researchers
Fig. 11.4: Video Surgery/Photo Researchers
Fig. 11.6B: Mike Leboffe
Fig. 11.12A: SPL/Photo Researchers
11.12B: Biophoto Assoc./Photo Researchers

Unit 12

Opener: SPL/Photo Researchers
Fig. 12.2: Spike Walker/Photo Researchers
Fig. 12.7: Biophoto Assoc./Photo Researchers
Fig. 12.9: SPL/Photo Researchers

Unit 13

Opener: SPL/Photo Researchers
Fig. 13.8: Biophoto Assoc./Photo Researchers
Fig. 13.9B: BSIP/Photo Researchers
Fig. 13.9C: SPL/Photo Researchers
Fig. 13.13: Kent M. Van De Graaff and John Crawley, *A Photographic Atlas for the Anatomy and Physiology Laboratory*, 6E ©Morton Publishing
Fig. 13.14: Kent M. Van De Graaff and John Crawley, *A Photographic Atlas for the Anatomy and Physiology Laboratory*, 6E ©Morton Publishing
Fig. 13.15: Kent M. Van De Graaff and John Crawley, A Photographic Atlas for the Anatomy and Physiology Laboratory, 6E ©Morton Publishing
Fig. 13.16: Martin Rotker/Photo Researchers

Unit 14

Opener: SPL/Photo Researchers
Fig. 14.3: Biophoto Assoc./Photo Researchers
Fig. 14.8: BSIP/Photo Researchers
Fig. 14.13: SPL/Photo Researchers

Unit 15

Opener: SPL/Photo Researchers
Fig. 15.8: Kent M. Van De Graaff and John Crawley, *A Photographic Atlas for the Anatomy and Physiology Laboratory*, 6E ©Morton Publishing
Fig. 15.9: Kent M. Van De Graaff and John Crawley, *A Photographic Atlas for the Anatomy and Physiology Laboratory,* 6E ©Morton Publishing
Fig. 15.10: Kent M. Van De Graaff and John Crawley, *A Photographic Atlas for the Anatomy and Physiology Laboratory*, 6E ©Morton Publishing

Unit 16

Opener: Sci Photog/Photo Researchers
Fig. 16.7: Michael Ross/Photo Researchers
Fig. 16.8: Biophoto Assoc./Photo Researchers
Fig. 16.9: Biophoto Assoc./Photo Researchers

Unit 17

Opener: SPL/Photo Researchers
Fig. 17.8: Justin Moore
Fig. 17.9: Justin Moore
Fig. 17.10: Justin Moore
Fig. 17.12: SPL/Photo Researchers

Unit 18

Opener: SPL/Photo Researchers
Fig. 18.16: BSIP/Photo Researchers
Fig. 18.17: BSIP/Photo Researchers
Fig. 18.18: BSIP/Photo Researchers
Fig. 18.23: SPL/Photo Researchers

Unit 19

Opener: Edward Elliot/Photo Researchers
Fig. 19.2: Bruce Levy/*Journal of Bone and Joint Surgery* 92(12), September 15, 2010, Fig. 2 copyright ©JBJS
Fig. 19.4: Andy Levin/Photo Researchers

Unit 20

Opener: SPL/Photo Researchers
Fig. 20.1: Biophoto Assoc./Photo Researchers
Fig. 20.2: Biophoto Assoc./Photo Researchers and Michael Ross/Photo Researchers
Fig. 20.4: Justin Moore
Fig. 20.5: BSIP/Photo Researchers
Fig. 20.7: Biophoto Assoc./Photo Researchers

Unit 21

Opener: SPL/Photo Researchers
Fig. 21.5B: BSIP/Photo Researchers
Fig. 21.7A: Michael Abbey/Photo Researchers
Fig. 21.5B-C: Biophoto Assoc./Photo Researchers
Fig. 21.5 D: SPL/Photo Researchers

Unit 22

Opener: Eye of Science/Photo Researchers
Fig. 22.2B: BSIP/Photo Researchers
Fig. 22.4B: BSIP/Photo Researchers
Fig. 22.3B: Video Surgery/Photo Researchers
Fig. 22.4 B: Video Surgery/Photo Researchers
Fig. 22.6B: BSIP/Photo Researchers
Fig. 22.8A: Erin Amerman
Fig. 22.8B: Biophoto Assoc./Photo Researchers
Fig. 22.9: Biophoto Assoc./Photo Researchers
Fig. 22.10: Biophoto Assoc./Photo Researchers
Fig. 22.11A-B: Justin Moore

Unit 23

Opener: SPL/Photo Researchers
Fig. 23.3: SPL/Photo Researchers
Fig. 23.5: Justin Moore

Unit 24

Opener: SPL/Photo Researchers
Fig. 24.5B: BSIP/Photo Researchers
Fig. 24.5C: Visuals Unlimited
Fig. 24.7B: BSIP/Photo Researchers
Fig. 24.7C: Visuals Unlimited
Fig. 24.11B: BSIP/Photo Researchers
Fig. 24.11C: Video Surgery/Photo Researchers
Fig. 24.17: Biophoto Assoc./Photo Researchers
Fig. 24.18: Biophoto Assoc./Photo Researchers
Fig. 24.19B: Biophoto Assoc./Photo Researchers
Fig. 24.20: Biophoto Assoc./Photo Researchers
Fig. 24.21B: Spike Walker/Photo Researchers
Fig. 24.22: Getty Images
Fig. 24.24: SPL/Photo Researchers
Fig. 24.25: GIPhotoStock/Photo Researchers
Fig. 24.26: Michael Leboffe
Fig. 24.27: Justin Moore

Unit 25

Opener: Medical Body Scans/Photo Researchers
Fig. 25.6B: BSIP/Photo Researchers
Fig. 25.10C: BSIP/Photo Researchers
Fig. 25.13A-B: Video Surgery/Photo Researchers
Fig. 25.14: Garry Delong/Photo Researchers
Fig. 25.15A: SPL/Photo Researchers
Fig. 25.15B: Biophoto Assoc./Photo Researchers
Fig. 25.16A: Erin Amerman
Fig. 25.16B: SPL/Photo Researchers
Fig. 25.16C: Biophoto Assoc./Photo Researchers

Unit 26

Opener: SPL/Photo Researchers
Fig. 26.5: Scott Camazine/Photo Researchers

Unit 27

Opener: Science Picture Co/Photo Researchers
Fig. 27.3B: Julie Dermansky/Photo Researchers
Fig. 27.8B: SPL/Photo Researchers
Fig. 27.13: Biophoto Assoc./Photo Researchers
Fig. 27.14: Biophoto Assoc./Photo Researchers
Fig. 27.15: Michael Abbey/Photo Researchers
Fig. 27.18: Erin Amerman
Fig. 27.19: Biophoto Assoc./Photo Researchers

Unit 28

Opener: Petit Format/Photo Researchers
Fig. 28.5C: BSIP/Photo Researchers

Unit 29

Opener: SPL/Photo Researchers

Index

abdomen, 657 (Fig. 24.28), 669 (Fig. 25.4)
  arteries, 476 (Fig. 18.7), 499 (Fig. 18.28)
  veins, 478, 481 (Fig. 18.14)
abdominopelvic cavity, 631
accessory structures, 137. *See also* skin
acetylcholine, 381, 514
acid-base balance, 693
acinar cells, 644
action potential, 301, 317, 324, 425, 518
adenine, 53
adipose tissue, 425, 669
adrenal cortex, gland, and medulla, 425, 426, 428 (Fig. 16.5), 430 (Fig. 16.8), 441 (Fig. 16.12)
agglutination, 537, 567
agranulocytes, 534
alimentary canal, 638, 641 (Fig. 24.16), 649
  mucosa/MALT, 641
  muscularis externa, 641
  serosa or adventia, 641
  submucosa, 641
  tissue layers, 660 (Fig. 24.31)
alleles, ABO, 746
alveoli/alveolar sac, 585, 586, 590, 594 (Fig. 22.10), 600
amino acids, 649, 650
anal canal, 638
anatomical position, 5 (Fig. 1.2), 12 (Fig. 1.5)
anatomical sections, 5, 21
anatomy and physiology (A&P), definition, 5
aneurysm, abdominal aortic, 504
ankle, 202, 203 (Fig. 8.30)
ankle-brachial index (ABI), 516 (Fig. 19.5)–517
antagonists, 428
antibodies, 534, 537, 567, 568, 570
antigens (A and B), 534, 537, 567, 568, 570
  ELISA test, 570, 571 (Fig. 21.9)
antigen-antibody reactions, 537–538 (Fig. 20.4)
antiserum, 537, 538 (Fig. 20.4)
aorta, 453, 473
  abdominal, 475–476
  thoracic, 475
appendicitis, 661
appendicular skeleton, 179 (Fig. 8.3), 196
  clavicle, 196–197 (Fig. 8.21)
  pectoral girdle, 196 (Fig. 8.20)
  scapula, 196 (Fig. 8.20)
arteries/arterioles, 453, 511, 471, 473, 474 (Fig. 18.3), 484 (Fig. 18.16), 491 (Fig. 18.23), 492
  abdomen, 476 (Fig. 18.7), 499 (Fig. 18.28)
  aorta, 473
  brain, 473, 475 (Fig. 18.5), 497 (Fig. 18.26)
  carotid, 473
  coronary, 453, 455
  diseases, 512
  femoral, 476
  head and neck, 473, 475 (Fig. 18.4), 477, 497 (Fig. 18.26)
  iliac, 476
  lower limb, 476 (Fig. 18.8), 477, 498 (Fig. 18.27)
  popliteal, 476
  renal, 670
  systemic circuit, 478
  tissue wall, 491
  trunk, 477
  tunica interna, media, and externa, 491, 492
  upper limb and thorax, 473, 475 (Fig. 18.6), 477, 498 (Fig. 18.27)
articulations, 231. *See also* joint(s)
asthma, 612
atherosclerosis, 516
atlas of skeleton, 193 (Fig. 8.15)
atom, orbital model (chlorine), 41 (Fig. 2.2)
ATP synthesis, 585
atrioventricular (AV) node and bundle, 518
auscultation, 511
autonomic nervous system (ANS), 366, 367, 381, 508 (Table 19.1), 509
  effects on blood pressure and heart rate, 512, 515
  parasympathetic nervous system (PSNS), 366 (Table 14.3), 381, 514
  sympathetic nervous system (SNS)—"fight or flight," 366 (Table 14.3), 381, 514
autosomal traits, 751
autosomes, 751
axial region/axis, 7, 193 (Fig. 8.15)
axial skeleton, 179 (Fig. 8.3), 194, 217 (Fig. 8.36)
  coccyx, 204
  lumbar vertebra, 194 (Fig. 8.15)
  ribs, 204
  sacrum, 194 (Fig. 8.15), 204
  sternum, 194
  vertebrae/vertebral column, 191 (Fig. 8.14), 192, 193 (Fig. 8.15), 204
axons, CNS, 320 (Fig. 12.6), 321, 322, 324

bacteria
  epididymitis, 736
  in intestine, 563
basement membrane, 137, 723
basophils, 534 (Fig. 20.2)
bell-jar model, 610 (Fig. 23.3)
Benedict's reagent, 650, 651 (Fig. 24.25)
bicarbonate ion, 615
bile/bile salts, 637, 649 (Fig. 24.23)–650
bitter orange (synephrine), 388
blood, 114. *See also* formed elements
  antigens and antibodies, 546
  hemoglobin, 547, 548
  homeostasis, 670
  pH and pH homeostasis, 615
  plasma, 533
  smear, peripheral, 549 (Fig. 20.7)
blood donation/transfusion, 531, 533, 543, 544 (Table 20.4)
blood draw, 495
blood flow (systemic, coronary, pulmonary), 473, 486
  through kidney, 700 (Fig. 26.6)
blood groups (ABO and Rh factor alleles), 746
blood pressure, 506
  definition, 513
  diastolic, 513
  measuring, 513–514 (Fig. 19.4), 515
  systolic, 513
  testing, 382
blood substances and their filtration and reabsorption, 692 (Table 26.1)
blood testing simulated, 538–539
blood typing/types, 531, 533, 537, 539 (Table 20.3)
  ABO and Rh factor, 537 (Fig. 20.3), 543
  to determine paternity, 747
  murder mysteries, 540–542, 544 (Table 20.5)–545
  well plate diagram (Fig. 20.5), 539
  your own blood, 546
blood vessels, 473, 511
body cavities, 5, 13, 16 (Table 1.2), 31 (Fig. 1.16)
  abdominopelvic (quadrants), 14 (Fig. 1.7), 16 (Table 1.2)
  anterior (ventral) (thoracic and abdominopelvic), 13 (Fig. 1.6), 14
  posterior, 13 (Fig. 1.6)
  thoracic, 16 (Table 1.2)
bonds
  chemical, 51
  covalent (polar covalent and nonpolar covalent), 42 (Fig. 2.3), 49, 50
  ionic, 40, 49
bone(s), 159, 163, 207, 760. *See also* femur; foot and ankle; leg; lower limb; osseous tissue; skull; upper limb; wrist
  adult long (femur), 158 (Fig. 7.2), 166 (Fig. 7.8), 170
  carpal, 198
  child, 167 (Fig. 7.9A)
  compact, 157 (Fig., 7.1), 159 (Fig. 7.3), 160 (Fig. 7.4), 161, 169 (Fig. 7.10)
  coxal, 199, 200 (Fig. 8.26), 205, 221 (Fig. 8.40)
  cranial, 180–181, 189
  epiphyseal plate, 166, 167 (Fig. 7.9)
  ethmoid, 187 (Fig. 8.11), 189
  facial, 180, 187–188, 190
  forearm (Fig. 8.23), 197, 198 (Fig. 8.23)
  hyoid, 195 (Fig. 8.18), 204, 587
  lacrimal, 188
  markings, 164 (Table 7.2)
  nasal, 188
  occipital, 189

pelvic, male and female, 201 (Fig. 8.27)
periosteum, 159
sesamoid, 165, 202
shapes, 164, 165 (Fig. 7.7)
sphenoid, 189
spongy, 160, 161 (Fig. 7.5)
sutural, 165
tarsals and metatarsals, 202, 206
temporal, 189, 403
tissues, 159, 163
wrist, 198
Boyle's law, 609
brain, 336 (Figs. 13.1, 13.2), 337 (Figs. 13.3, 13.4), 340 (Figs. 13.7, 13.8), 344 (Fig. 13.12), 353–354 (Figs. 13.19, 13.20, 13.21). *See also* meninges; spinal cord
arachnoid mater, 345
brainstem, 342 (Fig. 13.10), 345
cerebellum, 342, 345
cerebrospinal fluid (CSF), 339–340, 344 (Fig. 13.12)
cerebrum, 340, 341, 345
choroid plexuses, 339
corpus callosum (white matter), 341, 345
coverings, 343, 345
and cranial nerves, 369 (Fig. 14.4)
diencephalon (thalamus, hypothalamus, epithalamus), 341–342 (Fig. 13.10), 345
dural sinuses, 343
dura mater, 342, 345, 351
gray matter (cerebral cortex), 341, 345, 350, 351
horns, 350–351
hypothalamus, 345
midsagittal section, 341 (Fig. 13.9)
nervous system/tissue, 125, 317
pia mater, 345, 351
structures, 334
sulci, 345
thalamus, 345
ventricles, 339 (Fig. 13.6), 345
white matter, 341, 351
bronchial tree, 588 (Fig. 22.6), 594
bronchioles, 584 (Fig. 22.1), 590, 594 (Fig. 22.9), 600, 612
buffers/buffered solutions, 46 (Table 2.3)
bursae, 235

calcitonin, 428
calcium
homeostasis, 427
ions, 24
cancer
cells, 568
capillary(ies), 473, 493
bed, 670
glomerular, 670
peritubular, 670
and refill time, 511 (Fig. 19.3)–512
kidney, 670
segmental, 670
carbaminohemoglobin, 615
carbohydrates and carbohydrate digestion, 649, 650
carbon dioxide
in blood, 615
gas exchange, 585, 609
carbonic acid-bicarbonate buffer system, 615
carbonic anhydrase, 615
cardiac conduction system, 451, 518 (Fig. 19.6), 524 (Fig. 19.10)
cardiac muscle tissue and cells, 121, 122 (Fig. 5.10), 305 (Figure 11.12), 306, 462, 518
cardiovascular system, 509, 585, 760. *See also* blood pressure; heart
cartilage
bone, 159, 760
cricoid, 587
elastic, 114, 115 (Fig 5.7C)
fibrocartilage, 114, 115 (Fig. 5.7B)
hyaline, 114, 115 (Fig. 5.7A), 587, 594, 594
larynx, 587, 590
thyroid, 587
zone of reserve, 166
catalyst, 47
catecholamines (epinephrine, norepinephrine), 428
cell(s). See also muscle, smooth; goblet cells; neuroglial cells; plasma membrane
acinar (exocrine), 430, 644
bacterial, 568
cardiac muscle, 122 (Fig. 5.10), 518
contractile, 518
cytoplasm, 75, 723
daughter, 88, 720
definition, 75
endocrine, 644
ependymal, 340
epithelial, 103
follicle, 427
generalized, 77 (Fig. 4.4), 78, 93 (Fig. 4.13)
memory and memory T, 567, 568
mother, 88
myocytes, 121
nucleus, nuclear envelope, nuclear membrane, and nuclear pores, 78
olfactory receptor. 408
organelles, 75, 76
osteogenic, 159
pacemaker, 518
parafollicular, 427
plasma, 567
plasma membrane, 75, 76 (Fig. 4.3)
SEM, 77 (Fig. 4.4)
sister, 88, 720
cell cycle, 88 (Fig. 4.10), 89 (Fig. 4.11), 94 (Fig. 4.14)
interphase, 88, 89 (Fig. 4.11)
telophase of mitosis, 89 (Fig. 4.12)
white blood, 89 (Fig. 4.12), 533
central nervous system (CNS), 319 (Fig. 12.5), 320 (Fig. 12.6). *See also* brain; spinal cord
centrioles, 78
centromere, 88
centrosome, 78
cerebral cortex, 395
chemical
bonds, 51
digestion, 650
reactions, 47
chemicals/chemistry principles, 43
acids and bases, 44
amphipathic, 49
chemical solubilities, 43, 51, 52 (Table 2.5)
chemosenses/chemoreceptors, 408
chiasmata, 720
chlorine atom, 41
cholesterol, 75
chondrocytes, 114
chromatid, sister, 88, 720
chromatin, 78, 88
chromosomes
homologous, 88, 720
sex, X and Y, 751
cilia, 75, 340
clavicle, 197 (Fig. 8.22)
Clostridium tetani/tetanospasmin/tetanus, 332
coccyx, 191, 204
collagenopathies, 131
colon, 638
color blindness, 752
color vision, testing, 751
compound light microscope. *See* microscope
concentration gradient, defined, 81
connective tissue, 101 (Fig. 5.1), 111, 121, 669 (Fig. 25.4)
adipose, 111–112 (Fig. 5.5C), 159
cartilage, 114, 115 (Fig. 5.7)
dense (regular, irregular, elastic), 111, 113 (Fig. 5.6), 159, 563, 669
diseases, 131
ECM, 111
fibroblasts, 111
loose (areolar), 111–112 (Fig. 5.5A)
male, 713
reticular, 111, 112 (Fig. 5.5B)
skin, 137
COPD (chronic obstructive pulmonary disease), 612
covalent bonds, 42 (Fig. 2.3), 49
cranial
meninges, 350
nerves, 363 Table 14.1), 367, 369 (Fig. 14.4)–370, 371–372
cricothyroidotomy, 597
cytokines/cytokinesis, 88, 568, 720
cytoplasm, 75 (cytosol, cytoskeleton, organelles), 75, 319, 725
cytosine, 53
cytoskeleton, 75
cytosol, 75, 84

deoxyribonucleic acid (DNA), 53 (Fig. 2.9), 746
dermis, 137
diabetes mellitus, 444, 516
diaphragm, 610
diencephalon, 425
diffusion
across a plasma membrane, 81 (Fig. 4.6)
concentration gradient, 81 (Fig. 4.6)
definition, 81
example with dye in agar, 81 (Fig. 4.7)
rate, 82
digestion/digestive system, 622–623, 624 (Fig. 24.1), 629, 630 (Fig. 24.5), 644. *See also* small intestine; stomach
accessory organs, 629, 644, 659
alimentary canal (GI tract), 629, 629–630, 631–633, 760
chylomicrons, 650
enzymes, 628 (Table 24.1), 642, 649, 652, 662
hormones, 642
hydrochloric acid, 642
mesentery and greater omentum, 629, 631 (Fig. 24.7)
micelles, 650
mucosa and submucosa, 646
muscularis exerna, 641, 646
organs, 657 (Fig. 24.28)
peritoneal cavity, 629, 630 (Fig. 24.6)
peritoneal membranes, 629, 630 (Fig. 24.6), 669
protein, 649
serosa or adventia, 646
serous membrane, 629
tracing, 655–656
directional terms, 6 (Fig. 1.3)
medial/lateral, 8

proximal/distal, 7
superficial/deep, 8
DNA
extracting, 43, 53, 54 (Fig. 2.10)
in meiosis, 720
in mitosis, 720
in nucleus, 78
Dopler probe, 516
duodenum, 637 (Fig. 24.15), 647, 760
duodenal glands, 643, 647
dysrhythmia (arrthythmia), 519

ear (outer, middle, and inner), 391, 394 (Fig. 15.4), 403 (Fig. 15.13), 415 (Fig. 15.20)
auditory ossicles, 403
auricle, 403
bony labyrinth, 403
cochlea, 403, 404
incus, 403
inner, 404 (Fig. 15.14)
malleus, 403
middle, 404
otitis media, 417
outer, 404
stapes, 403
ECM (extracellular matrix), 101, 102 (Fig. 5.2), 103, 159, 160
electrocardiogram (ECG)/ electrocardiograph, 509, 518–519 (Fig. 19.7)–520 (Table 19.5, Fig. 19.8), 521 (Fig. 19.9), 525 (Fig. 19.11)
electrolyte, 693
electronegativity, 42
electrophysiology, 506–507
ELISA test, 570 (Fig. 21.8), 571 (Fig. 21.9)
embryo, embryogenesis and fetal development, 743 (Fig. 28.5), 745
amnion, amniotic fluid, and amniotic cavity, 743
chorionic villi, 739 (Fig. 28.1), 743 (Fig. 28.5), 745
genesis, 743
germ layers (ectoderm, mesoderm, and endoderm), 743
in membranes, 755 (Fig. 28.12)
organ development, 744
placenta, 743, 744, 745
in uterus, 739 (Fig. 28.1)
yolk sac, 743
emulsification of fats, 649 (Fig. 24.23)
endocrine system, 439 (Fig. 16.10), 760. *See also* hormones
definition, 425
glands, 429, 725
organs and tissues, 420–421, 422 (Fig 16.1), 425–426 (Fig. 16.2), 428
pancreatic islets, 644
endomysium, 121
endoplasmic reticulum (RER and SER), 76
enterocytes, 650
enzymes, 425
acetylcholinesterase, 302
acrosomal, 741
amylase, 650
brush border (lactate, maltase, sucrose), 649
digestive, 628 (Table 14.1), 642, 662, 742
effects on chemical reactions, 3
lipase, 47
pepsinogen, 652
salivary lipase, 649
eosin dye, 534
eosinophil, 534 (Fig. 20.2)
epidermis
callus, 151
layers, 137, 138 (Fig. 6.3). *See also* skin
epididymitis, 737
epiglottis, 587
epinephrine, 381
epithelial tissue/epithelia, 101 (Fig. 5.1), 107, 159, 510 [check title of this procedure]
basement membrane, 103
cells, 103
keratinocytes, 105
osseous, 159, 160
pseudostratified ciliated columnar epithelium, 104 (Fig. 5.3D), 586, 723
simple and simple columnar), 103 (Fig. 5.3)–104 (Fig. 5.4), 646
simple ciliated columnar from uterine tube, 104 (Fig. 5.3C)
simple cuboidal, 104 (Fig. 5.3B), 594
simple squamous, 103 (Fig. 5.3A), 131, 594, 681
skin, 137
stratified, 105–106, 107 (Fig. 5.4), 593
stratified squamous, 564, 587, 641
subcutaneous, 137
transitional (urinary), 105, 107 (Fig. 5.4D), 672
equilibrium, 81 (Fig. 4.6)
Romberg test, 407
erythroblastosis fetalis (hemolytic) disease, 552
erythrocytes, 84, 533 (Fig. 20.1), 537
agglutination, 546 (Fig. 20.6)
in kidney, 700
esophagus, 126 (Fig. 5.12), 593, 632, 638, 641, 642 (Fig. 24.17), 647
estrogens, 725
exocrine glands/functions, 138, 428, 635
exocytosis, 324, 650
extracellular fluid (ECF), 84
eye, 392 (Fig. 15.2), 397
accessory structures, 398
astigmatism, 402 (Fig. 15.12)
lacrimal apparatus/lacrimal glands, 188, 395 (Fig. 15.5)–396
LASIK procedure, 417
lens, 396, 397
macular degeneration, 417
muscles, 121, 393 (Fig. 15.3; Table 15.1), 396 (Fig. 15.6)
optic disc (blind spot), 397
structures, 390, 395 (Fig. 15.5)–396
eyeball, 392 (Fig. 15.1), 396, 397 (Fig. 15.7), 413 (Fig. 15.19)
aqueous humor, 396
blind spot, 401 (Fig. 15.11), 401 (Fig. 15.11)
cornea, 387
dissection, 399 (Figs. 15.8, 15.9, 15.10)
lens, 398
retina, 397
rods and cones, 397, 400
tunics, 396–397 (Fig. 15.7), 398
eyelids (palpebrae), 395
lacrimal apparatus (lacrimal caruncle; lacrimal gland), 395 (Fig. 15.5)
tears, 395

facial
bones, 187–188
muscles, 262 (Fig. 10.3)
fatty acids/free fatty acids, 47, 650
female reproductive system and organs, 711, 717 (Fig. 27.7), 732 (Fig. 27.25)
ampulla, 717
cervix, 717, 719
clitoris, 719
corpus luteum and corpus albicans, 725 (Fig. 27.18, 27.19)
duct system, 717
erectile tissue, 718
external genitalia, 718 (Fig. 27.9)
fimbriae, 717
gamete, 729 (Fig. 27.21)
infundibulum, 717
isthmus, 717
labia majora and minora, 718
ligaments, ovarian, suspensory, and uterosacral, 717
mammary glands and milk, 718 (Fig. 27.10), 719, 733 (Fig. 27.26)
mons pubis, 718
oocytes, primary and secondary, 717, 724, 725, 741
oogenesis, 724 (Fig. 27.16)
oogonia, 724, 725
ova, ovaries, ovarian ligament, ovarian cycle, ovarian follicles, 717, 719, 724 (Fig. 27.17), 725 (Figs. 27.18, 27.19), 727, 729, 734 (Fig. 27.27), 741
ovulation, 725
paraurethral glands, 718
pelvis, 718 (Fig. 27.8)
perimetrium, 717
peritoneal cavity, 717
pelvis/pelvic cavity, 718 (Fig. 27.8)
puberty, 718, 724, 725
rectum, 717
reproductive tract, 742 (Fig. 28.4)
sacrum, 717
uterine (fallopian) tube, 719
uterus/uterine tubes, 717, 719, 742
vagina/vaginal canal, 718, 719
vestibule/vestibular glands, 718, 719
vulva, 718, 719
female urinary system 674 (Fig. 25.10), 675 (Fig. 25.12), 685 (Fig. 25.19B)
femur, 166 (Fig. 7.8), 170 (Fig. 7.11), 201, 202 (Fig. 8.28), 206
fertilization, 725, 741
acrosomal reaction, 741
blastocyst, 742
and implantation, 742
morula, 742
fetal pig
body cavities, 15 (Fig. 1.8), 17 (Fig. 1.9), 18 (Fig. 1.10)
fetus, 738, 744, 745
blastocyst, 741 (Fig. 28.3)
cardiovascular system and blood, 740, 744 (Fig. 28.6)–745, 754 (Fig. 28.11)
development stages, 741 (Fig. 28.3)
membranes, 739, 745
shunts (ductus venosus, foramen ovale, and ductus arteriosus), 744
umbilical cord and vein, 745
fibers
collagen (Fig. 5.5)
muscle, 121, 295
protein, 101–102
reticular, collagen, and elastic, 114
skeletal muscle, 308 (Fig. 11.14)
spindle, 720

fibroblasts, 111, 114
fibula, 206
filtration
membrane, 695 (Fig. 26.4)
basal lamina, 695
glomerular, 695
podocytes, 695
filaments, actin and intermediate, 75
fingerprinting, 146
Galton points, 146 (Fig. 10)
flagella, 75
fontanels, 188
foot and ankle, 202, 203 (Fig. 8.30)
formed elements (blood), 530, 532 (Table 20), 533, 534 (Fig. 20.2)
erythrocytes, 533 (Fig. 20.1)
granulocytes, 534
leukocytes, 533–534
agranulocytes (lymphocytes; monocytes), 534
granulocytes, 534
platelets, 533 (Fig. 30.1)
foramina, 184 (Fig. 8.7), 187

gallbladder, 636, 637 (Fig. 24.15), 638
ducts, 637
gallstones, 661
gametes, 720, 741
haploid, 720
gametogenesis, 709, 713, 720, 723
gas transport, 607, 609
gastric glands, 642 (Fig. 24.18), 649
gastroesophageal sphincter, 632
genotype, 746, 748
gestation, 741
glands. *See also* gastric glands; parathyroid gland; pituitary glands; salivary glands; small intestine; thyroid gland
adrenal, 425, 428, 429, 430 (Fig. 16.8)
bulbourethral, 714, 715
ductless, 425
duodenal, 643, 647
endocrine, 425, 725
exocrine, 138, 429, 635, 714
hormone secretion, 425
hypothalamus, 427 (Fig. 16.3)
lacrimal, 395
mammary, 426, 718 (Fig. 27.10)
ovaries, 425, 429
pancreas, 425, 429, 430–431
pineal, 425, 426
prostate, 714
sebaceous, 138, 139 (Fig. 5.4), 143, 395
sweat, 138, 143
tarsal, 396
testes, 425, 429
thymus, 425, 429
thyroid, 760
vestibular, 718
glomerular filtration, 695, 696
and tubular reabsorption, 692 (Table 26.1), 693
glucose, 51, 444, 700
glycerol, 47
glycolipids, 75
glycoproteins, 75, 534, 537
goblet cells, 586, 593 (Fig. 22.8), 593 (Fig. 22.8), 594, 642
Golgi apparatus, 76
granulocytes, 534, 568
ground substance, 101, 102 (Fig. 5.2), 126
guanine, 53

hair (shaft, root, papilla, follicle), 138, 140 (Fig. 6.5)
head and neck
arteries, 475 (Fig. 18.4), 477, 497 (Fig. 18.26)
midsagittal section, 560 (Fig. 21.5), 587 (Fig. 22.4), 600
veins, 478 (Fig. 18.10), 482, 500 (Fig. 18.29)
hearing
aid, 418
Rinne test, 406 (Fig. 15.16)
Weber test, 373 (Fig. 14.6), 405 (Fig. 15.15)
heart, 448–449 (Fig. 17.2), 451–452 (17-4, 17.5), 463 (17.13), 464 (Fig. 17.14), 465 (Fig. 17.15)
aorta, 453
atria, 455
auscultation, 509 (Fig. 19.1), 510 (Table 19.2)
bradycardia, 509
capillary beds and refill time, 511 (Fig. 19.3)–512
cardiac veins, 455
chambers, 453–454
coronary arteries, 455
dissection, 453, 454 (Fig. 17.6)
great vessels, 453, 455
hormones, 425
isovolumetric contraction and relaxation, 509
murmur, 309
sheep, 457, 458, 459 (Figs. 17.8, 17.9, 17.10)
sounds and pulses, 506, 509
stenosis, 509
tissue layers (epicardium, myocardium, endocardium), 452
valves, 454 (Fig. 17.7), 455, 465 (Fig. 17.15)
vena cavae, superior and inferior, 453
ventricles, 455
heart rate response, measuring/testing, 382, 514 (Fig. 19.4)
hematoxylin dye, 534
hemipelvis, 199
hemoglobin, 533, 547, 615
hemophilia, 751, 752
hepatic portal system, 650
ducts, 637
veins, 481 (Fig. 18.14), 650
heredity, 741, 746
genotype, 746
phenotype, 746
homeostasis, 317, 425, 427, 514, 557, 669, 670, 713
hormones, 423–424 (Table 16.1), 425, 760. *See also* insulin; kidneys; stomach
ACTH, 426, 428
ADH, 426
adrenocorticotropic, 426
antidiuretic (ADH), 425, 426, 444
calcitonin, 427
corpus luteum, 725 (Fig. 27.19)
definition, 425
follicle-stimulating (FSH), 725
glucagon, 428–429
growth (GH), 426
hypothalamus, 427 (Fig. 16.3), 425
luteinizing,(LH), 725
melatonin, 426
oxytocin, 426
parathyroid (PTH), 428
prolactin, 425
reproductive (luteinizing and follicle-stimulating), 426, 725
steroid, 428
thymosin and thymopoietin, 428
thyroid-stimulating (TSH), 426, 427
thyroxine (T4), 427
triiodothyronine (T3), 427
tropic, 426
human
anterior and posterior views, 12 (Fig. 1.5), 19 (Fig. 1.11), 33–35 (Fig. 1.18–1.20)
development, 741
organ systems, 5
tooth, 646 (Fig. 24.22)
human musculature, 255–258 (Fig. 10.1), 271–272 (Fig. 10.21, 10.22)
abdominal, 263 (Fig. 10.7), 264 (Fig. 10.8)
anterior thorax, 263 (Fig. 10.6)
arm, 265–266 (Figs. 10.11, 10.12), 274
facial, 261–262 (Fig. 10.2–10.3), 273, 281 (Fig. 10.24)
foot and toes, 274
forearm and hand, 274
head and neck, 259 (Table 10.1), 262, 264 (Fig. 109A), 273
leg, 270 (Fig. 10.20), 274
lower limb, 260 (Table 10.1), 285 (Fig. 10.28)
mastication (masseter and temporalis), 262 (Fig. 10.3)
neck/splenius muscles, 262 (Fig. 10.4), 264 (10.9A)
scapula, 265, 274
skeletal, 255–258 (Fig. 10.1), 261 (Fig. 10.2), 273
thigh, 270, 274
thorax, abdomen, and back, 259 (Table 10.1)
trapezius, 265
trunk, 264 (Fig. 10.9), 265 (Fig. 10.10), 274, 282–283 (Figs. 10.25–10.26)
upper limb, 260 (Table 10.l1), 266 (Figs. 10.l1, 10.12), 284 (Fig. 10.27)
humerus, 197 (Fig. 8.22)
hyaline cartilage, 114, 115 (Fig. 5.7A), 587, 594, 594
hydrocarbon chains, 47
hydrochloric acid, 45, 642
hydrogen ion concentration, 39, 43
hypermagnesemia, 311
hypertension, 516
hyperthyroidism, 444
hyperventilation and hypoventilation, 615
hypothalamus, 425–426 (Fig. 16.3), 429

ilium, 205, 563
immune response, 567, 568
adaptive (acquired) immunity, 567
cell-mediated, 567–568
humoral, 567
immune system, 555, 557, 558
lymph nodes, 558
thymus, 558
infundibulum, 425
innate immunity, 567
antimicrobial proteins, 567
granulocytes and macrophages, 567
inflammatory mediators, 567
surface barriers, 567, 568
insulin, 428, 429, 644
integument/integumentary system, 137. *See also* skin
accessory structures (hair, glands, nails), 137, 138, 139 (Fig. 6.4), 140 (Fig. 6.5)
intercalated discs, 121
intestinal
lumen, 650
villi, 650

iodine, 427
ischium, 205
Ishihara chart, 752 (Fig. 28.10)

joint(s), 126 (Fig. 5.12). *See also* knee joint; lower limb; shoulder joint; synovial joints; upper limb
  ankle, 202
  cartilaginous, 231 (Fig. 9.4), 232, 243 (Fig. 9.8)
  fibrous, 231 (Fig. 9.4)–232
  functional classes, 226, 231, 234 (Table 9.1)
  structural classes, 226, 231 (Fig. 9.4)–232, 233 (Fig. 9.5), 234 (Table 9.1)

keratin/keratinocytes, 105, 137
kidneys, 664, 669 (Fig. 25.4), 670 (Fig. 25.5), 679 (Fig. 25.13), 679, 683. *See also* urinary system/tract
  acid-base balance, 669
  adipose capsule, 669
  bicarbonate and hydrogen ion regulation, 669
  blood flow/arteries, 670, 671 (Fig. 25.6), 676
  calyces, minor and major, 670
  capillaries, peritubular, 670, 700
  collecting ducts, medullary collecting ducts, and papillary ducts, 672, 676
  connective tissue, 669 (adipose capsule and renal capsule), 669
  detoxification, 669
  electrolyte regulation, 669
  erythropoietin, 669
  filtrate/filtration, 670, 672 (Fig. 25.7), 693
  filtration membrane, 695
  foot processes, 670
  glomerulus/glomerular capsule/glomerular capillaries, 670, 672, 681 (Fig. 25.16B), 695, 700
  glucose making, 669
  hilium, 669
  juxtaglomerular apparatus (JGA), 672
  hormone production, 669
  macula densa/juxtaglomerular apparatus, 672, 673 (Fig. 25.9), 681 (Fig. 25.16)
  metabolic waste removal, 669
  microanatomy, 700
  model, 695–696
  nephrons (renal corpuscle and renal tubule), 670, 672, 673 (Fig. 25.8), 676, 684 (Fig. 25.18), 700
  filtration and tubular reabsorption, 692 (Fig. 26.1)
  structure and function, 691 (Fig. 26.1)
  net filtration pressure (NFP), 693 (Fig. 26.2)
  regions (renal cortex, renal medulla, and renal pelvis), 669–670, 676
  renal capsule/renal corpuscle, 669, 672 (Fig. 25.7), 693
  renal cortex and renal medulla, 680, 681 (Fig. 25.16A,C), 682
  tissues, 681 (Fig. 25.16)
  veins, interlobular, arcuate, interlobar, and renal, 478, 670, 676
knee joint, 202, 229 (Fig. 9.2), 238–239 (Fig. 9.6), 248 (Fig. 9.9)
  injuries, 240

lacteal, 557, 650
lacunae, 114
lamellae, 159 (Fig. 7.3) , 161 (Fig. 7.5)
large intestine, 563, 633, 634 (Fig. 24.11), 638
  anal canal, 633
  cecum, 633, 634 (Fig. 24.11)
  colon, 633
  rectum, 633
  sphincters, 633
larynx, 583 (Fig. 22.1), 584, 587, 588 (Fig. 22.5), 590
latrotoxin (widow spiders), 311
leg, *See also* knee joint
  ankle and tarsals, 202
  femur, 201, 202 (Fig. 8.28)
  metatarsal, 202
  muscles, 201, 268, 270 (Figs. 10.19, 10.20)
  "shin," 202
  talus, 202
  tarsals/heel, 202, 203 (Fig. 8.30)
  tibia and fibula, 202, 203 (Fig. 8.29)
  veins, 478
leucocytes, 534
ligaments
  connecting bones, 760
  cricothyroid, 587
  denticulate 350
  falciform, 636
  periodontal, 644
  round (liver), 636
  shoulder, 241–242
lipase/lipid digestion
  emulsification, 649 (Fig. 24.23)
  experiment, 47 (Fig. 2.7)
  pancreatic, 650
  testing with phenol red, 654 (Fig. 2.27)
lipids
  absorption, 650
  in alimentary canal, 649
  digestion, testing, 654
  emulsification, 653
  in enterocytes, 650
  as nonpolar molecules, 649
liver, 636 (Fig. 24.14), 637 (Fig. 24.15), 638
  as accessory digestive organ, 644, 659 (Fig. 24.30)
  bile and bile duct, 637
  falciform and round ligaments, 636
  hepatic portal system/vein, 636–637, 650
  hepatocytes/hepatic duct, 644
  lobules, 644, 645 (Fig. 24.21A), 648
  making proteins, 567
  pig, 645 (Fig. 24.21)
  porta hepatis, 636
  portal triads, 644, 648
  vessels (bile duct, portal venule, hepatic arteriole), 644
long bones. *See* femur
lower limb (thigh, patella, leg ankle, foot), 201, 205, 222 (Fig. 8.41)
  ankle and tarsals, 202, 203 (Fig.8.30)
  arteries, 476 (Fig. 18.8), 477, 516
  femur, 201, 202 (Fig. 8.28)
  foot and toes, 202, 203 (Fig. 8.30), 269
  muscles, 201, 260 (Table 10.1)
  nerve plexuses, 386 (Fig. 14.16)
  phalanges, 202
  tibia and fibula, 202, 203 (Fig. 8.29)
  toes, 202
  veins, 478, 481 (Fig. 18.15), 482, 500 (Fig. 18.30)
Lugol's iodine test, 650 (Fig. 24.24)
lungs, 585 (Fig. 22.2), 586 (Fig. 22.3), 590, 594 (Fig. 22.10), 610
  alveoli, 585, 586, 610
  atmospheric pressure, 610
  bell-jar model, 610 (Fig. 23.3)
  conducing zone, 586
  cricothyroidotomy, 597–598 (Fig. 22.11)
  expiration, 610, 612
  gas exchange, 586, 609
  hilum, 586
  intrapulmonary pressure, 610
  pressure-volume relationships, 609 (Fig. 23.2)
  respiratory membrane, 131
lymphatic system, 554, 556 (Fig. 21.1), 557, 558 (Fig. 21.2), 563–564 (Fig. 21.7), 573 (Fig. 21.10). *See also* immune response; spleen
  capillaries, 557
  cisterna chyli, 557
  ducts, 557
  functions, 557–558
  thymus, 558, 560
  trunks, 557
  MALT, 559, 563
  palatine tonsil, 564 (Fig. 21.7)
  Peyer's patch, 563, 564 (Fig. 21.7)
  tonsils, 559, 560 (Fig. 21.5)
lymph nodes, 558–559 (Fig. 21.3), 560, 563, 563, 564 (Fig. 21.7), 565, 568
lymphocytes, 534 (Fig. 20.2), 559
  B lymphocytes, 563, 567, 568
  T lymphocytes, 559, 563, 567–568
lysosomes, 76

macrophages, 559, 563, 567, 568, 725
magnification, 63
male reproductive system, 715 (Fig. 2.6)
  bulbourethral glands, 715
  connective tissues, 713
  cremaster muscle, 713, 715
  dartos muscle, 713 (Fig. 27.3)
  ductus deferens, 713, 715
  epididymis, 714, 724 (Fig. 27.14)
  ejaculatory duct/ejaculation, 714, 715
  exocrine glands, 714
  epididymis, 714, 715, 726
  gamete, 728
  glans penis, 715
  inguinal canal, 713
  interstitial cells, 723
  organs, 710 (Fig. 27.1)
  pampiniform venous plexus, 713
  pelvis, 715 (Fig. 27.5), 732 (Fig. 27.24)
  penis, 715 (Fig. 27.6)
  prostrate gland, 714, 715
  puberty, 723
  reproductive tract, 714
  scrotum, 713, 715, 731, 731 (Fig. 27.22)
  semen, 715
  seminal vesicle, 714, 715
  seminiferous tubules, 723 (Fig. 27.13)
  sperm and sperm cells (spermatozoa), 714, 723, 724 (Fig. 27.15), 726, 728, 741
  spermatic cord, 713, 715, 731 (Fig. 27.22)

spermatocyte, 723
spermatids, 723 (Fig. 27.12)
spermatogenesis, 723 (Fig. 27.12), 728
spermatoginia, 723
spermiogenesis, 723
stereocilia, 723
structures, 708
testes/ rete testis, 713, 714 (Fig. 27.4), 715, 723, 726, 731 (Fig. 27.23)
testerone, 723
tunica vaginalis and tunica albuginea, 714
urethra, prostatic, membranous, and spongy, 714, 715
X chromosome, 752
male urinary system/urethra 675 (Fig. 25.12), 685 (Fig. 25.19)
MALT (mucosa-associated lymphatic tissue), 559, 641, 646
mandible (jaw bone), 187, 190
Marfan syndrome, 131
maxillae (jaw bone), 187–188, 190
mediastinum, 451
meiosis, 712, 720, 721 (Fig. 27.11), 724
in fetal period, 724
haploid spermatocytes, 723
telophase I and II, 720
melanin/melanocytes, 137
meninges
brain, 337 (Fig. 13.4), 342–343 (Fig. 13.11), 350, 351
spinal, 349, 350 (Fig. 13.17)
Merkel cells, 137
metabolic wastes, 669
microorganisms/pathogens, 567
microscope, 60
cell smear, 68 (Fig. 3.2)
compound light, 61 (Fig 3.1)
depth of field, 67
hints to use, 65
objective lens, 60, 63
ocular lens, 60, 63
oil immersion lens, 60, 63
microtubules, 75
microvilli, 75, 647, 680
mitochondria, 76, 77 (Fig. 4.5), 741
mitosis, 720
before puberty, 723
interphase, 88, 89 (Fig. 4.11A)
stages, 74 (Table 4.1), 88, 89 (Fig. 4.11B), 712
telophase, 89 (Fig. 4.12)
monocytes, 534 (Fig. 20.2)
monofilament, 145 (Fig. 6.8)
monoglyceride, 47, 649, 650
monosaccharides, 51, 650
mouth, 631–632 (Fig. 24.8), 638
gums, 631
lips, 631
palates, hard and soft, 631
teeth, 631
tongue, 631
mucous membranes, 567
multiple sclerosis, 332
muscle tissue/muscles, 101 (Fig. 5.1), 121, 122 (Fig. 5.10). 271–272 (Fig. 10.21–10.22) *See also* eye; human musculature; skeletal muscle; smooth muscle
abdominal, 263, 264 (Fig. 10.8), 365
adductor, 268 (Fig. 10.16)
arm, 265, 267 (Figs. 10.13, 10.14), 274
arrector pili, 138
biceps brachii and triceps brachii, 276 (Fig. 10.23)
cardiac, 121, 122 (Fig. 5.10B), 294 (Table 11.1), 305 (Fig. 11.12), 306, 462 (17.12)
ciliary, 417
cremaster, 713
diaphragm, 261, 263, 585, 609
eye, 121, 393 (Fig. 15.3; Table 15.1), 396 (Fig. 15.6), 397
facial, 261 (Fig. 10.2)–262 (Fig.10.3), 273, 281 (Fig. 10.24)
fibers, 295
foot and toes, 269, 274
forearm, hand, and fingers, 266, 267 (Fig. 10.12), 274, 276
gluteal region, 268 (Fig. 10.15)
head and neck, 259 (Table 10.1), 261–262 (Figs. 10.2, 10.3, 10.4), 273
insertions, 259 (Table 10.1), 261, 276
inspiratory, 609–610
intercalated discs, 305
intercostal, 263 (Fig. 10.5), 375, 609, 610
leg, 201, 268, 270 (Figs. 10.19, 10.20), 274
lower limb, 260 (Table 10.l), 269 (Figs. l0.17, Fig. 10.19))
mastication, 262
neck (splenius), 262, Fig. 10.4)
origins, 259 (Table 10.1), 261, 276
papillary, 455
pharynx and larynx, 587
postural of back/erector spinae, 264
scapula, 265, 274
skin, 137
spindles, 380
splenius (neck), 262
striations, 122 (Fig. 5.10), 296
thigh, 268, 274
thorax, abdomen, and back, 259 (Table 10.1), 263 (Fig. 10.6)
trapezius, 262, 265
trunk, 263–264 (Fig. 10.9)–265 (Fig. 10.10), 274
upper limb, 260, 266 (Figs. 10.11, 10.12)
wrist, 266
myasthenia gravis, 311
myelin sheath, 319, 320 (Figs. 12.6, 12,7), 321, 322
myocytes, 121
myofilaments, 121

nails, 137, 140 (Fig. 6.5B)
nasal cavity, 187, 188, 586, 590
mucosa, 593 (Fig. 22.8)
nares (nostrils), 586, 590
nasal conchae, 586, 590
olfactory epithelium 408 (Fig. 15.17)
paranasal sinuses, 590
pseudostratified ciliated columnar epithelium, 586
neck
splenius muscles, 262
veins, 478
nephrons, 664–665, 670
glomerular filtration and reabsorption, 692, 693
structure and function, 691
tubules, 695
nephroptosis, 687
nerve plexuses, 375 (Fig. 14.7), 377 (Fig. 14.9)–378 (Figs. 14.10, 14.11), 379, 385 (Fig. 14.15), 386 (Fig. 14.16)
nerves. *See also* nerve plexuses; peripheral nerves; spinal nerves
anterior rami, 375 (Fig. 14.7), 385 (Fig. 14.15)
cranial, 363 Table 14.1), 367, 369 (Fig. 14.4)–370, 371–372
intercostal, 375, 379
olfactory, 371, 408
optic, 401
nervous system, 315, 317, 339, 425. *See also* central nervous system
nervous tissue, 101 (Fig. 5.1), 124, 315, 317 (Fig. 12.2), 321
net filtration pressure (NFP), 693 (Fig. 26.2)
neuroglial cells, 125 (Fig. 5.11), 317, 318–319 (Fig. 12.5)
neuromuscular diseases—drop foot, 288
neuromuscular junction (NMJ), 294 (Fig. 11.3), 299 (Fig. 11.7), 300, 324
neurons/neuroglia/neuronal synapse, 125, 317, 315 (Fig. 12.5), 321, 324 (Fig. 12.8), 327 (Fig. 12.9) 329 (Fig. 12.11)
neurotransmitters (EPSP & IPSP), 324, 381, 425
neutrophils, 534 (Fig. 534), 568
Nissl bodies, 124
node of Ranvier, 321
norepinephrine, 381, 514
nose/nasal bones, 188
nuclear membrane, 88
nucleotides, 53
nucleus, cell
nuclear envelope, and nuclear pores, 78
nucleolus, 78
ribosomal RNA, 78

olfaction/olfactory, 408, 409
chemoreceptors, 408
epithelium, 408 (Fig. 15.17)
nerves, 371, 409
oligodendrocytes, 319, 320 (Fig. 12.6), 322
oligosaccharides, 649
optic nerves, 371
organelles, 75, 76
organology, 126
organs and organ systems, 5, 23 (Table 1.4), 24, 25 (Table 1.5), 26–28 (Fig. 1.14)
endocrine, 420, 422 (Fig. 16.1), 425, 426 (Fig. 16.2)
functions, 760
hormone secretion, 425
neuroendocrine, 425, 426
oropharynx, 587, 559
osmosis, 84 (Fig. 4.8)
osseous tissue, 159, 160. *See also* bone(s)
organic and inorganic components, 163
osteoblasts, 159
osteons, 160
ovaries, 425, 426, 429, 727
oxygen in body, 585, 615

pacemaker cells, 518
paclitaxel (Taxol), anticancer drug, 96
palatine tonsil, 563, 564 (Fig. 21.7)
pancreas, 428 (Fig. 16.6), 429, 430–431 (Fig. 16.9), 637 (Fig. 24.15), 638, 644 (Fig. 24.20
acinar cells (Fig. 24.20), 644
pancreatic amylase, 649
pancreatic islets, 644
pancreatic lipase, 649–650
paranasal sinuses, 586
parasympathic nervous system (PSNS), 381
parathyroid gland, 425, 428, 429
patent ductus arteriosus, 757
pathogens, 567
patella/patellar tendon and ligament, 268, 206

pectoral girdle, 196 (Fig. 8.20), 205
clavicle, 196–197 (Fig. 8.21), 205
scapula, 196 (Fig. 8.20), 205, 219 (Fig. 8.38)
pelvic girdle/pelvis/hemipelvis, 199 (Fig. 8.25), 200 (Fig. 8.26)
determining sex, 200, 201 (Fig. 8.27)
ilium, 200, 205
ischium, 200
pelvis, 205
pubis, 201
pepsin and pepsinogen, 649, 652
perception, 395
pericardium, 451
periosteum, 159
peripheral artery disease (PAD), 516
peripheral blood smear, 535
peripheral nerves/peripheral nervous system (PNS), 125, 317, 361, 362 (Fig. 14.1)
autonomic nervous system, 381
cranial nerves, 367
motor (efferent) division, 367
resistance, 515
sensory (afferent) division, 367
spinal nerves, 367 Fig. 14.3), 383
peristalsis, 632, 672
peritoneum, 638
peroxisomes, 76
Peyer's patch, 563
pH
antacid effectiveness, 45 (Table 2.2)
blood, 615
normal for blood, 44
paper and indicator strip, 44 (Fig. 2.5)
scale, 39, 43 (Fig. 2.4), 45
stomach, 45
of water, 616 (Table 23.3)
phagocytes, 559, 567
pharynx (throat), 586–587, 632, 638
laryngopharynx, 587 (Fig. 22.4A), 590, 593, 632
nasopharynx, 586, 587 (Fig. 22.4A), 590
oropharynx, 586, 587 (Fig. 22.4A), 590, 632
phenol red, 47, 654
phenotypes, 746, 748
phospholipids/phosopholipid bilayer, 49, 75, 76 (Fig. 4.3)
pituitary gland, 425, 426, 427 (Fig. 16.3), 429
adenohypophysis, 425
neurohypophysis, 425
planes of section, 21 (Figs. 1.12, 1.13)
plasma membrane, 72 (Fig. 4.1), 75, 76 Fig. 4.3), 650
pleural membranes, 586, 610
plexuses (cervical, brachial, lumbar, sacral), 375 (Fig. 14.7), 377 (Fig. 14.9)–378 (Figs. 14.10, 14.11), 379
polysaccharides, 51, 101, 649
protein(s)
actin, 296
in alimentary canal, 649
antimicrobial, 567, 568
digestion, 649, 652
enzymes, 47, 649, 652
filaments, 75
integral, 75
keratin, 105
in nucleus of cell, 78
peripheral, 75
troponin and tropomyosin, 296, 301
proteoglycans/protein aggregates, 101
PTC taste procedure, 751
pubis, 205
pulmonary ventilation, volumes and capacities, 585, 606, 607, 608, 609, 615. *See also* respiratory volumes
measuring, 612
pulse points, 494 (Fig. 18.24, 495 (Table 18.3)
Punnett square, 749 (Fig. 28.7), 750 (Figs. 28.8, 28.9), 758 (Fig. 28.13)
pupillary response, 372 (Fig. 14.5)
Purkinje fiber system, 518
pyrogens, 567

radius, 8, 195 (Fig. 8.23)
rectum, 638
reflex, 380. *See also* spinal reflexes
regional terms, 9 (Fig. 1.4), 10–11 (Table 1.1)
reproductive system, 713. *See also* female reproductive system; male reproductive system
respiratory
diseases, 612
membrane, 131, 594
processes, 606, 609
system, 580, 582–584 (Fig. 22.1), 585, 586. *See also* lungs
respiratory tract, 580–581, 585 (Fig. 22.2), 586, 587, 593
bronchiole, 594 (Fig. 22.9)
epithelium, 593
goblet cells, 593 (Fig. 22.8)
inspiration, 612
nasal mucosa, 593 (Fig. 22.8)
pseudostratified ciliated columnar epithelium, 593
trachea, 593–594
respiratory volumes and capacities, 607–608, 611 (Fig. 23.4)
Rh antigens and anti-Rh antibodies, 546
Rh factor alleles, 746
ribosomes/ribosomal RNA, 76, 78
ribs, 194, 195 (Fig. 8.17), 204
Rinne test, 406 (Fig. 15.16)
RNA in cells, 78
Romberg test, 407

salivary glands, 635, 636 (Fig. 24.13), 638, 657 (Fig. 24.28), 760
sarcoplasm, 296
scapula, 205
Schwann cells, 319, 320 (Fig. 12.6), 322
selectively permeable membrane, 84
seminiferous tubules, 723 (Fig. 27.13)3e
sensation, definition, 395
sensory receptors, error of localization, 410 (Table 15.5)
serous membranes/serous fluid, 13, 19 (Table 1.3)
parietal layer, 13
visceral layer, 13
sex chromosomes X and Y, 751
sex-linked traits, 751
sheep brain, 346 (Figs. 13.13, 13.14), 347 (Fig. 13.15)
shoulder joint, 241 (Fig. 9.7), 249 (Fig. 9.10)
biceps brachii tendon, 242
ligaments, 241–242 (Fig. 9.7)
rotator cuff, 242
skeletal muscle, 121, 122 (Fig. 5.10A), 261, 273, 290, 292, 293 (Figs. 11.1, 11.2), 294, 295 (Fig.11.4), 296, 297, 307 (Fig. 11.13)
acetylcholinesterase, 302
action potential, 301
ATP hydrolysis, 302
crossbridge cycle, 301–302 (Fig. 11.9)
esophagus, 631
fibers/fiber microanatomy, 295, 296 (Fig.11.5), 297, 302, 308
motor neurons, 301
myofibrils/myofilaments, 296
neuromuscular junction, 301 (Fig. 11.8)
sarcomere/sarcolemma/sarcoplasm, 291, 301
sphincter, urethral, 675
tissue, 298 (Fig. 11.6)
skeletal system/skeleton, experiments, 159, 177–178 (Fig. 8.2), 213 (Fig. 8.32). See also muscles
articulated, 208 (Fig. 8.31)
atlas, 193 (Fig. 8.15)
axial and appendicular, 179 (Fig. 8.3), 191
depolarization, 301
measuring length-tension relationship, 303 (Fig. 11.10), 304 (Fig. 11.11)
muscle action potential, 301
skin, 135 (Fig. 6.1), 137, 139 (Fig. 6.4), 149 (Fig. 6.11)
dermis, 137, 140, 143
epidermis, 137, 138 (Fig. 6.3), 140, 143
eponychium (cuticle), 140
error of localization, 410 (Table 15.5)
functions, 760
hair, 136 (Fig. 6.2), 140 (Fig. 6.5), 144 (Fig. 6.7)
hypodermis, 137
nail, 136 (Fig. 6.2), 140 (Fig. 6.5)
sensory receptors, 145, 410
as surface barrier, 567
thick (Palmar) and thin, 142 (Fig. 6.6A,B), 143 (Table 6.2)
skull, 175–176 (Fig. 8.1), 180, 181 (Fig. 8.4), 214 (Fig. 8.33)
adult, 188
bones, cranial and facial, 180, 181–186 (Figs. 8.4–8.9)
calvaria, 180, 186 (Fig. 8.10)
fetal, 188 (Fig. 8.13)
sutures, 180
small intestine, 563, 626 (Fig. 24.3), 632, 633 (Fig. 24.10), 638, 643 (Fig. 24.19)
digestion, 649
duodenum, 643 (Fig. 24.19B)–644, 647
folds, 643 (Fig. 24.19A)
lumen, 650
villi and microvilli, 644
smell sense, 391
cribriform plate, 418
smooth muscle, 121, 122, Fig. 5.10 C, D), 294 (Table 11.1), 305 (Fig. 11.12)
respiratory tract, 594, 641, 642
sphincter, 675
urinary tract, 672, 675
solute, solvent, and solubility, 49, 84 (Fig. 4.8)
chemical solubilities, testing, 51, 52 (Table 2.5)
hydrophilic and hydrophobic, 50
starch solubility, testing, 51
steroids, 75
spermatogenesis, 723 (Fig. 27.12
sphygmomanometer, 382, 512, 516
spinal cord, 125, 317, 335, 338 (Fig. 13.5), 339, 343–344 (Fig. 13.12), 349 (Fig. 13.16), 350 (Fig. 13.18), 355 (Figs. 13.22, 13.23)
dura mater, 342, 345, 349, 350

medulla oblongata, 342
pia mater, 350
spinal meninges, 349, 350 (Fig. 13.17)
spinal nerves, 367
anterior rami, 364 (Fig. 14.2), 365 (Table 14.2), 375 (Fig. 14.7), 385 (Fig. 14.15)
intercostal, 375
plexuses, 364 (Fig. 14.2), 375 (Figs. 14.7, 14.8)–376, 377 (Fig. 14.9), 378 (Figs. 14.10, 14.11), 379, 385 (Fig. 14.15)
spinal reflexes, testing, 380 (Figs. 14.2, 14.13)
spindle fiber, 88
spirometer/spirometry, 611, 612 (Fig. 23.5)
spleen, 478, 559 (Fig. 21.4), 563 (Fig. 21.7)
central arteries, 559
red and white pulp, 563
T and B lymphocytes, 559
sternum, 194, 204
stethoscope, 510 (Fig. 19.2)
stomach, 625 (Fig. 14.2), 632, 633 (Fig. 24.9), 638, 642 (Fig. 24.18), 760
chyme, 632
fundus, 647
gastric glands and pits, 642 (Fig. 24.18), 649
gastroesophageal reflux (heartburn), 45
hormone gastrin, 425
mesentery and greater omentum, 629, 631 (Fig. 24.7)
pH, 45
protein digestion, 649
pyloric sphincter, 632
rugae, 632
sympathetic nervous system (SNS), 366 (Table 14.3), 381, 514
synapse, 315–316, 325
synapsis, 720
synovial joints, 228 (Fig. 9.1), 231 (Fig. 9.4), 232, 233 (Fig. 9.5), 235
classification, 237 (Table 9.2)
motions, 243 (Fig. 9.8)
structural and functional classifications, 234
synovitis, 251 types 236, 237 (Table 9.2)
types 236, 237 (Table 9.2)

tarsals, 206
taste, 391, 408
buds, 408, 409
papillae, 408, 409
teeth (incisors, canines, and molars), 635 (Fig. 24.12), 638, 648
alveoli, 635
"baby teeth," 635
cementum, 644
crown, 644
dentin, 644
enamel, 644
human, 646 (Fig. 24.22)
permanent, 635
pulp and pulp cavity, 644
root and root canal, 644
tendons and tendon sheaths, 235
Achilles tendon, 269
patellar reflex, 380 (Fig. 14.13)
testes, 425, 426, 429
thoracic
aorta, 475
cavity, 447 (Fig. 17.1), 451 (Fig. l7.3), 585, 610, 632
region, 9
vertebrae 192, 193 (Fig. 8.15D)
thymine, 53
thymus and thymus hormones, 425, 428
thyroid cartilage, 587
thyroid gland, 425, 427 (Fig. 16.4), 429, 430 (Fig. 16.7), 431, 440 (Fig. 16.11)
tibia, 202, 203 (Fig. 8.29), 206
tissue gas exchange, 609
tissue perfusion, 511
tissue types, 101 (Fig. 5.1). *See also* adipose tissue; bone; blood, connective tissue, epithelial tissue; muscle tissue; nervous tissue; skeletal muscle
toes, 203 (Fig. 8.30)
tongue, 408 (Fig. 15.18), 635, 638
papillae, 408
taste buds, 408
tonicity, 84, 85 (Fig. 4.9)
tonsils, 578
lingual, 559, 560, 632
palatine, 556 (Fig. 21.1), 564 (Fig. 21.7), 560, 564, 632
pharyngeal (adenoid), 567, 560
touch receptor distribution, 145
toxins, 567
tracings, 763
trachea, 586, 588 (Fig. 22.6), 590, 593 (Fig. 22.8)
mucosa, submucosa, and adventitia, 593–594
triglycerides, 47 (Fig. 2.6)
tubular reabsorption, 693, 694 (Fig. 26.3)
two-point discrimination test, 411 (Table 15.6)

ulna, 8, 198 (Fig. 8.23), 205
upper limb (arm, forearm, wrist, hand), 194, 220 (Fig. 8.39)
arteries, 475 (Fig. 18.6), 477
carpals, 205
humerus, 197 (Fig. 8.22), 205
muscles, 260, 284 (Fig. 10.27), 266 (Figs. 10.11, 10.12)
nerves, 377 (Fig. 14.9)
radius and ulna, 198 (Fig. 8.23)
scapula, 205, 219 (Fig. 8.38)
veins, 482, 500 (Fig. 18.30)
urea, 700
ureters, 672, 676, 680 (Fig. 25.14), 682
urinalysis, 697
reagent test strips, 695 (Fig. 26.5), 697
urinary bladder, 672, 676, 680 (Fig. 25.15)
adventitia, 680
detrusor muscle, 672
female, 675 (Figs. 25.11, 25.12)
male, 675 (Fig. 25.12)
muscularis, 680
rugae, 672
sphincter, internal and external, 675
submucosa, 680
transitional epithelium, 672, 680 (Fig. 25.15), 682
trigone, 672
urinary system/tract, 664, 667, 669, 672. *See also* kidneys
female, 674 (Fig. 25.10), 675 (Fig. 25.12), 685 (Fig. 25.19B)
glomeruli in renal cortex, 681 (Fig. 25.16)
juxtaglomerular apparatus, 673 (Fig. 25.9)
male, 675 (Fig. 25.12), 685 (Fig. 25.19A)
nephron, 668, 673 (Fig. 25.8)
peristalsis, 672
renal pelvis, 672
urethra, 672, 675, 676
urine expulsion through micturition, 675

vascular. *See also* blood vessels
disease/bruits, 511
examination, 511, 512
veins, 472 (Fig. 18.2), 479 (Fig. 18.9), 484 (Fig. 18.16), 491 (Fig. 18.23)
abdominal and hepatic portal system, 478, 481 (Figs. 18.13, 18.14), 501 (Fig. 18.31)
axillary, 478
azygos system, 478
basilica, 478
brachial, 478
brain (dural sinuses), 480 (Fig. 18.11)
cardiac, 453, 455
cephalic, 478
cerebral, 478
exterior jugular, 478
femoral, 478
gastric, 478
head and neck, 480 (Fig. 18.10) 482, 500 (Fig. 18.29)
hepatic portal, 478, 481 (Fig. 18.14), 650
iliac, 478
interlobar and interlobular, 670
internal, 478
jugular, 478, 650
lower limb, 481 (Fig. 18.15), 482, 500 (Fig. 18.30)
median antebrachial, 478
median cubital, 478
mesenteric, 478
popliteal, 478
pulmonary, 453
radial and ulnar, 478
renal, 478
sinuses, 478, 480 (Fig. 18.11)
splenic, 478
subclavian, 478, 650
superficial, 495, 496 (Fig. 18.25)
thorax, 480 (Fig. 18.12)
tibial, anterior and posterior, 478
trunk, 477, 482
tunica interna, media, and externa, 491, 493
umbilical, 745
upper limbs, 482 (Fig. 18.12), 500 (Fig. 18.30)
vena cava, superior and inferior, 7, 453, 478, 745
ventilation, 615
ventricles, 453
vertebral column, 191 Fig. 8.14),192, 204, 216 (Fig. 8.35)
atlas, 192, 193 (Fig. 8.15B)
axis, 193 (Fig. 8, 199 (Fig. 8.24).15C)
cervical vertebrae, 192, 193 (Fig. 8.15 A-C), 204
lumbar vertebrae, 192, 194 (Fig. 8.15E). 204
sacrum, 194 (Fig. 8.15), 204
thoracic vertebrae, 192, 193 (Fig. 8.15D), 204
transverse foramina, 192
vasoconstriction/vasodilation, 514
vocal folds or vocal cords, 587

Weber test, 373 (Fig. 14.6)
white blood cells, 89 (Fig. 4.12), 533
differential, 536 (Table 20.2)
wrist, 198, 266

xiphoid process (sternum), 194

zona pellucida, 741
zygote (conceptus), 741